



ELSEVIER

Contents lists available at ScienceDirect

JSES International

journal homepage: www.jseinternational.org

Arthroscopic bursectomy less effective in the degenerative shoulder with chronic subacromial pain

Hamez Gacaferi, MD ^{a,b}, Arjen Kolk, MD ^b, Cornelis P.J. Visser, MD, PhD ^{a,*}

^a Department of Orthopedics, Alrijne Hospital, Leiden, the Netherlands

^b Department of Orthopedics, Leiden University Medical Center (LUMC), Leiden, the Netherlands

ARTICLE INFO

Keywords:

Shoulder
rotator cuff
subacromial pain syndrome
SAPS
subacromial impingement syndrome
SAIS
arthroscopy

Level of evidence: Level IV; Case Series;
Treatment Study

Background: Varying results after surgery in patients with subacromial pain syndrome (SAPS) have raised the question on whether there is a subgroup of patients that can benefit from surgery. Therefore, we aimed to identify preoperative and peroperative factors associated with a favorable patient-reported outcome after arthroscopic bursectomy in patients with SAPS.

Methods: Patients with chronic SAPS who underwent arthroscopic bursectomy after failed conservative management were included (n = 94). Patients were evaluated at the baseline, and 2 weeks, 8 weeks, 6 months, and 1 year after surgery. The primary outcome was the Western Ontario Rotator Cuff index (WORC) score one year after surgery. The secondary outcome measure was a visual analog scale for pain. Mixed model analyses were used to identify prognostic factors.

Results: The mean WORC (mean difference 39%, 95% confidence interval (CI) 32.8–45.3, $P < .001$) and visual analog scale pain scores (mean difference 41 mm points, 95% CI 3.37–4.88, $P < .001$) significantly improved one year after surgery. Nineteen patients (20%) developed a postoperative frozen shoulder. A longer duration of preoperative complaints and the peroperative identification of degenerative glenoid cartilage were associated with significantly worse WORC scores, with -0.086% per month (95% CI -0.156 to -0.016 , $P = .016$) and -20% (95% CI -39.4 to -1.26 , $P = .037$), respectively.

Conclusion: We identified demographic and clinical factors that predict the course after arthroscopic subacromial bursectomy. We found that arthroscopic bursectomy is less effective in patients with SAPS with a degenerative shoulder. This finding suggests that an improved treatment effect of arthroscopic subacromial bursectomy can be expected in patients with chronic SAPS if intra-articular pathologies such as glenohumeral osteoarthritis are sufficiently excluded.

© 2020 The Authors. Published by Elsevier Inc. on behalf of American Shoulder and Elbow Surgeons. This is an open access article under the CC BY-NC-ND license (<http://creativecommons.org/licenses/by-nc-nd/4.0/>).

Shoulder pain is a global disease burden and it covers 10–18% of all visits at the general practitioner.^{16,31,37,49} Most complaints are attributed to subacromial pain syndrome (SAPS), more commonly known as subacromial impingement syndrome, which affects patients between the ages of 30 and 60 years.¹⁶ A variety of entities, including bursitis, supraspinatus tendinopathy, partial tear of the rotator cuff (RC), biceps tendinitis, and degeneration of the acromioclavicular (AC) joint have all been described in literature as part of SAPS.^{10,11,23} Patients with SAPS encounter severe impairment on daily life activities, including work.^{49,50} Although most patients are treated with conservative strategies, some patients remain symptomatic and therefore receive surgical treatment (subacromial decompression surgery).^{7,11,18}

Institutional Review Board approval was received from the Medical Ethical Committee of Leiden University Medical Centre (LUMC) (Ref: P15.348).

* Corresponding author: Cornelis P. J. Visser, MD, PhD, Department of Orthopedics, Alrijne Hospital, 2334 CK Leiden, the Netherlands.

E-mail address: cpjvisser@alrijne.nl (C.P.J. Visser).

<https://doi.org/10.1016/j.jseint.2020.10.021>

2666-6383/© 2020 The Authors. Published by Elsevier Inc. on behalf of American Shoulder and Elbow Surgeons. This is an open access article under the CC BY-NC-ND license (<http://creativecommons.org/licenses/by-nc-nd/4.0/>).

At the beginning of this decade, there was an increase in arthroscopic subacromial decompression, making it one of the most frequently performed interventions in orthopedics.^{21,52} Yet, studies report inconsistent results with a substantial group of patients still experiencing pain or impaired shoulder function after surgery.^{5,26,28} Moreover, randomized studies failed to prove a clinically important difference favoring surgical bursectomy with or without subacromial decompression over conservative management with physiotherapy.^{2,27,34} Controversial results urged the orthopedic shoulder community to search for factors characterizing patients who are more likely to benefit from surgery.^{23,38,44} We therefore aimed to evaluate if there are factors that can predict the course after arthroscopic subacromial bursectomy in patients with SAPS.

To answer this question, we conducted a prospective cohort study to identify preoperative and peroperative prognostic factors associated with a favorable patient-reported outcome in patients with SAPS after arthroscopic bursectomy. Peroperative factors can then possibly be identified preoperatively with other methods in future patients. Bursectomies (without acromioplasty) might be

considered effective by those who support the idea of an intrinsic cause of SAPS, as it removes the inflamed bursa, while considering the changes of the acromion to be secondary.^{12,39} Second, resection of adhesions might improve subacromial motion and might provide a better clearance of subacromial tissues, with an increase in subacromial space.^{6,48} Because a number of patients develop a frozen shoulder after shoulder surgery (ranging from 5 to 34% in literature), our secondary aim was to identify predictive factors for the development of postoperative frozen shoulder.^{13,29,42}

Materials and methods

Study design and participants

In this prospective cohort study, we recruited all patients with chronic SAPS who underwent an arthroscopic bursectomy at a secondary referral center (Alrijne Hospital, Leiderdorp) between May 2013 and February 2015.

Patients were eligible for inclusion in case of chronic SAPS, which was defined as nontraumatic shoulder pain for at least 6 months, that was localized around the humeral head and the lateral upper arm, which increased during elevation of the arm.¹¹ Physical examination revealed a positive sign for all of the following tests: Jobe test, Hawkins-Kennedy test and painful supraspinatus and infraspinatus resistance tests (without muscle weakness).^{11,23} Furthermore, all patients had conservative therapies before they were eligible for surgery, that is, a positive reaction to at least one subacromial corticosteroid infiltration and multiple sessions of physiotherapy. Finally, conventional radiographs of the shoulder and ultrasounds were made to assess the RC and exclude other pathologies like radiographic glenohumeral osteoarthritis. An additional magnetic resonance imaging of the shoulder was made if the physical examination and ultrasound were inconclusive. All diagnoses were made by a senior orthopedic surgeon specialized in arthroscopic shoulder surgery (CV). As per literature, the SAPS entity includes patients with bursitis, supraspinatus tendinopathy, partial tear of the RC, biceps tendinitis, with or without degeneration of the AC joint.^{10,11} Patients with both SAPS symptoms and osteoarthritis of the AC joint were considered eligible and underwent an additional distal clavicle resection. Osteoarthritis of the AC joint was confirmed through a positive AC compression test, signs of osteoarthritis on conventional radiographs, and positive marcainization test.

Exclusion criteria were a full-thickness RC tear (either on preoperative radiographic/ultrasound imaging or during surgery), preoperative restriction in passive shoulder motion (frozen shoulder), history of frozen shoulder at the affected side, glenohumeral osteoarthritis, concomitant tenodesis/tenotomy, labral deficits during surgery (such as SLAP/Bankart lesions), interfering complaints deriving from a degenerative cervical spine, and patients under the age of 30 years.

The Medical Ethical Committee of the Leiden University Medical Centre approved the study protocol (protocol number P15.348). Written informed consent was obtained from all participants.

A total of 111 patients with SAPS were screened to participate in this study. Subsequently, 16 patients were excluded before surgery for the following reasons: 7 patients had a full-thickness RC tear on preoperative radiologic/ultrasonic imaging, 3 had signs of cervical radiculopathy, and 6 patients had surgery cancelled for various reasons. During surgery a full-thickness RC tear was found in two patients, resulting in 93 participating subjects (Figure 1). One year after surgery, 20 patients were lost to follow-up, leaving 73 patients (78%) for analysis.

Intervention

All patients underwent surgery under general anesthesia. Patients were positioned in the lateral decubitus position with their arm in traction. Two portals were created in the shoulder. First, a dorsal portal was created to inspect the glenohumeral joint. A lateral portal was created lateral to the front edge of the acromion. In case of AC pathology, an additional anterior portal was made below and in line with the AC joint. Bursectomy was performed through the lateral portal with a radiofrequency ablator (VAPR®, DePuy Synthes). Fibrotic and thickened soft tissue attached to the undersurface of the acromion was removed routinely. In case of osteoarthritis of the AC joint, a distal clavicle resection was done with a bur (Linvatec). Finally, the wounds were closed with wound closure strips and skin glue. In addition, 20 mL of levobupivacaine 0.5% was injected in the bursal space. The senior orthopedic surgeon specialized in arthroscopic shoulder surgery (CV) performed all of the surgical interventions.

All patients underwent subacromial bursectomy for signs of SAPS: subacromial inflammation (n = 88) with or without bursal RC lesions (n = 44). Concomitant findings were osteoarthritis of the AC joint (n = 53), a hooked acromion (n = 15) and biceps tendinopathy (n = 7) for which a distal clavicle resection, subacromial decompression or biceps tenotomy were performed.

Postoperatively patients were discharged from the hospital with a rehabilitation sling for two weeks and were allowed to use their arm for activities of daily living. Furthermore, patients were allowed to start with physiotherapy after the outpatient check-up 2 weeks after surgery. Physiotherapy started with performing gently guided active exercises to prevent stiffness due to inactivity. On the other hand, patients were advised to minimize exercises to avoid pain because pain can lead to immobility and stiffness, which in turn might evoke capsulitis (postoperative frozen shoulder). After 6 weeks, physiotherapy was targeted at shoulder proprioception and shoulder muscle strength to improve shoulder movements.

Evaluation of potential prognostic factors

Preoperative demographic determinants at the baseline were age (years), duration of preoperative complaints (months), sex (male/female), history of trauma (yes/no), involved side (left/right), hand dominance (left/right), involved in sports (yes/no), workers compensation (yes/no), diabetes mellitus (yes/no), hypothyroidism (yes/no), cardiovascular disease (yes/no), Dupuytren's contracture (yes/no), and the American Society of Anesthesiologists (ASA) score (ASA 1, 2, or 3).^{4,8,16,29,38,46} Furthermore, anteroposterior oblique internal rotation view (Grashey view) and outlet view radiographs of the shoulder joint were evaluated. The radiographic assessment consisted of measuring the acromion-humerus distance, the radius of the humeral head, the glenoid length, the acromial slope angle and the critical shoulder angle (CSA).^{1,3,10,15,24,40} (Appendix 1). Baseline characteristics can be found in Table I.

Finally, we prospectively scored the following findings during the operation (Table II): degenerative glenoid (\geq Outerbridge grade II chondropathy; yes/no), degenerative humeral head cartilage (\geq Outerbridge grade II chondropathy; yes/no), labral lesion (yes/no), articular RC lesion (yes/no), inflammation in the axillary fold (yes/no), subacromial bursitis (normal/inflammatory/adhesive), thickness of the coracoacromial ligament (yes/no; meaning thicker than the thickness of the radiofrequency ablator (>5 mm), acromial osteophytes (yes/no), osteoarthritis of the AC joint (yes/no), biceps tendinopathy (yes/no), and bursal RC lesion (yes/no), respectively.^{10,22,32,35,45}

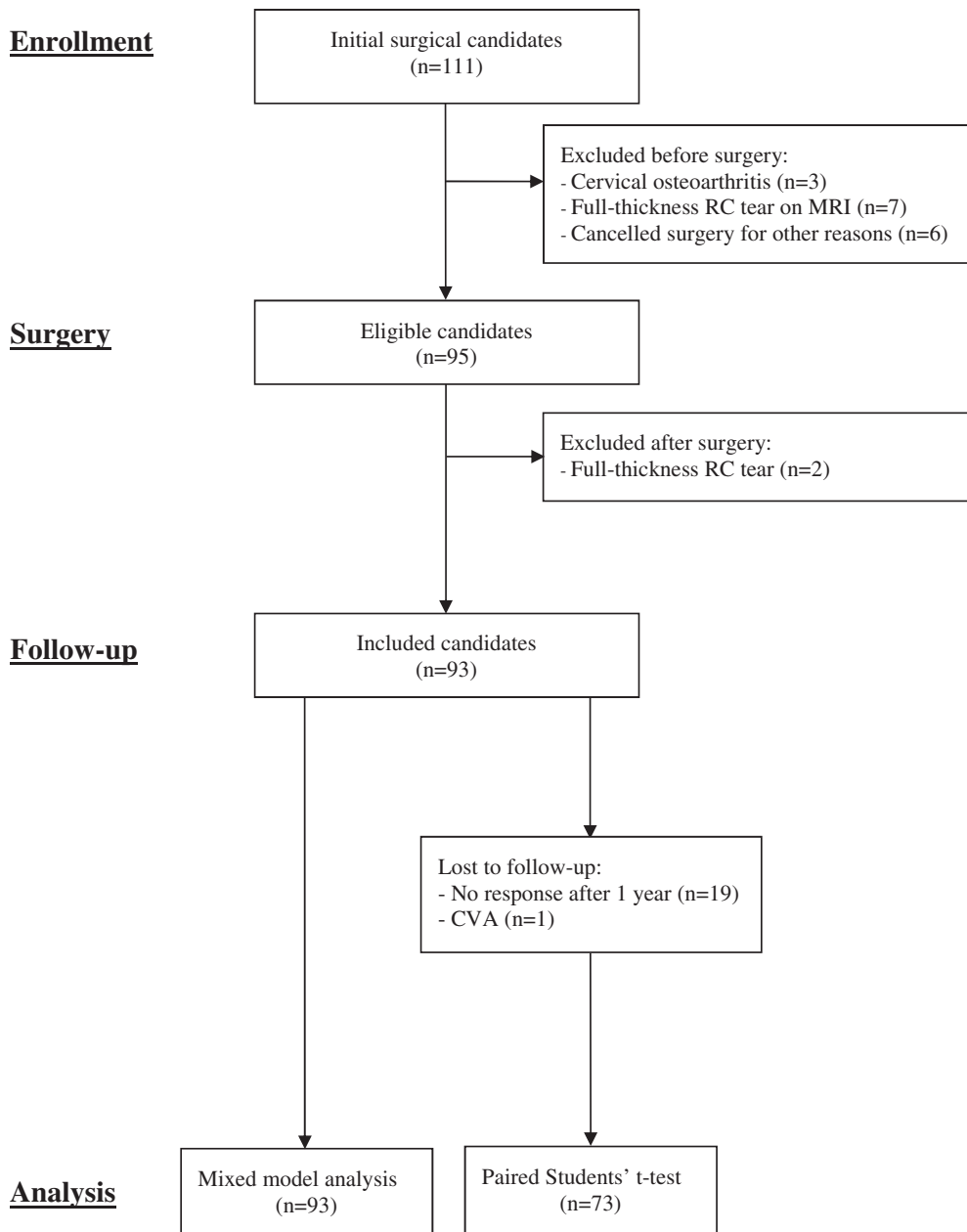


Figure 1 Flow diagram. n, number; RC, rotator cuff; MRI, magnetic resonance imaging; CVA, cerebrovascular accident.

Outcome measures

Patients were evaluated at the baseline and at standardized follow-up visits at 2 weeks, 8 weeks, and 6 months. One year after surgery, questionnaires were sent via regular mail, with an additional reminder via post, including a phone call, if the participants did not respond after 3 months.

The primary outcome was the Western Ontario Rotator Cuff index (WORC) score and it was obtained at the baseline and during the standardized follow-up visits at 8 weeks, 6 months, and one year after surgery. Secondary outcomes were the visual analog scale (VAS) for pain (0 to 100 mm, 100 mm indicated severe pain), which was obtained at the baseline and after one year. In addition, the development of a postoperative frozen shoulder was recorded at the standardized follow-up visits at 8 weeks and 6 months. A postoperative frozen shoulder was defined as described by Koor-evaar et al (2017): an initially successful postoperative

rehabilitation process after shoulder surgery is followed by worsening of (night) pain at the deltoid insertion with a painful restriction of active and passive movement, limited to <100° elevation, <30° external rotation and internal rotation limited to L5 or less.²⁹

Finally, additional questions about patient satisfaction and rehabilitation (including number of physiotherapy visits) were evaluated after one year (Appendix 2).

Statistical analysis

Parametric continuous data were expressed as means and 95% confidence intervals (CIs) and nonparametric data were expressed as median and interquartile range. Categorical data were expressed as numbers and percentages. A paired Student t-test was used to compare the preoperative and one-year postoperative WORC and VAS scores.

Table I
Baseline characteristics

Baseline characteristics	n = 93
Age, mean (SD), y	55 (9.5)
Duration preoperative complaints, median (range), m	23 (6–480)
Sex (female), n (%)	58 (62)
Result of traumatic event, n (%)	18 (19)
Right side involved, n (%)	53 (57)
Right hand dominance, n (%)	64 (69)
Active in sports, n (%)	47 (51)
Workers compensation, n (%)	12 (13)
Comorbidity:	
Diabetes mellitus, n (%)	10 (11)
Hypothyroidism, n (%)	5 (5.4)
Cardiovascular disease, n (%)	13 (14)
Dupuytren’s contracture, n (%)	7 (7.5)
ASA score:	
1, n (%)	62 (67)
2, n (%)	25 (27)
3, n (%)	6 (6.5)
Radiology characteristics	
Acromion-humerus distance, mean (SD), cm	11 (1.6)
Radius humerus head, mean (SD), cm	26 (2.9)
Glenoid length, superior to inferior, mean (SD), cm	39 (4.0)
Critical Shoulder Angle, mean (SD), degrees	33 (4.4)
Acromial slope angle, mean (SD), degrees	154 (10)

n, number; SD, standard deviation; y, years; m, months; ASA, American Society of Anesthesiologists classification.

A linear mixed model analysis was used to determine prognostic factors for the change in WORC score. To model the within patient variance, a random intercept in combination with a heterogeneous first-order autoregressive (ARH1) covariance structure was chosen. The dependent variable was the WORC score measured at the baseline, 8 weeks, 6 months, and 1 year. Follow-up time (baseline, 8 weeks, 6 months, and 1 year) was included as the repeated factor. The demographic, radiographic, and peroperative factors were modeled as fixed effects. Linear regression analysis was used to identify prognostic factors influencing pain experienced at 1 year after surgery, with the VAS score as the dependent factor. Finally, a logistic regression analysis was performed to study the factors that may predict the occurrence of a frozen shoulder. For each of the analyses, independent factors in univariable analysis with a correlation of $P < .15$ qualified for multivariable analysis (WORC), multiple linear regression (VAS), and multiple logistic regression models (frozen shoulder). A two-sided P value of $< .05$ was considered to be statistically significant. Statistical analyses were performed using IBM SPSS statistics (version 25.0, IBM Inc., Armonk, NY, USA).

Table II
Peroperative characteristics

Peroperative characteristics	n = 93
Degenerative glenoid cartilage*, n (%)	14 (15)
Degenerative humeral head cartilage*, n (%)	9 (9.7)
Labral lesion, n (%)	2 (2.2)
Articular RC lesion, n (%)	3 (3.2)
Inflamed axillary fold, n (%)	27 (29)
Subacromial bursa:	
Normal bursa, n (%)	5 (5.4)
Inflammatory bursitis, n (%)	25 (27)
Adhesive bursitis, n (%)	63 (68)
Thick CA ligament (>5 mm under acromion), n (%)	24 (26)
Osteophytes acromion, n (%)	11 (12)
Osteoarthritis of the AC joint, n (%)	53 (57)
Biceps tendinopathy, n (%)	7 (7.5)
Bursal RC lesion, n (%)	44 (47)

n, number; RC, rotator cuff; CA, coracoacromial; mm, millimetre; AC, acromioclavicular.

* Chondropathy \geq grade 2.

Results

Demographics

The mean age of the included group was 55 years (SD 9.5) and most (n = 58, 62%) of included patients were women (Table I). The median duration of preoperative complaints was 23 months (range 6–480). One year after surgery, the mean WORC significantly improved from 40% at the baseline to 79% (mean difference 39%, 95% CI 32.8–45.3, $P < .001$) (Figure 2). The mean VAS score significantly improved from 58 mm at the baseline to 17 mm (mean difference 41 mm points, 95% CI 3.37–4.88, $P < .001$) at 1-year follow-up. Finally, 19 patients (20%) developed a postoperative frozen shoulder within one year after arthroscopic bursectomy.

The vast majority of patients (80%) were happy with the surgery, and knowing the postoperative results 86% would choose surgery again (Appendix 3). Approximately 57% started working within 10 weeks after surgery. Most patients received between 20 and 30 physiotherapy treatments. Finally, 5 months after surgery 85% of the patients quit physiotherapy.

WORC score

The following factors qualified for our multivariable linear mixed model analysis: duration of preoperative complaints, radius of the humeral head, glenoid length, (female) sex, diabetes mellitus, and workers compensation (Appendix 4). Mixed model analysis showed that having workers compensation was predictive for a worse baseline WORC score (Table III). A longer duration of preoperative complaints and the peroperative identification of degenerative glenoid cartilage had a negative impact on the improvement of the WORC score, with -0.086% per month (95% CI -0.156 to -0.016 , $P = .016$) and -20% (95% CI -39.4 to -1.26 , $P = .037$), respectively.

Pain (VAS)

Duration of preoperative complaints, involved side, hand dominance, degenerative glenoid cartilage, degenerative humeral head cartilage, and labral lesion qualified for our multivariable linear regression analysis (Appendix 5). A longer duration of preoperative complaints was an independent predictor for an unfavorable course of pain, indicated by 1 mm (95% CI 0.005 to 0.018, $P = .001$) higher VAS for pain per month of complaints (Table IV).

Frozen shoulder

Sex, workers compensation, and CSA met our predefined criteria in the univariable logistic regression (Appendix 6). Multiple logistic regression analysis showed that a greater CSA had lower odds for the development of a postoperative frozen shoulder, with an odds ratio of 0.86 (95% CI 0.743 to 0.993, $P = .04$) (Table V). On the other hand, having workers compensation was an independent risk factor for the development of a postoperative frozen shoulder with an odds ratio of 4.4 (95% CI 1.07 to 18.0, $P = .04$).

Discussion

We conducted a prospective cohort study to identify preoperative and peroperative prognostic factors associated with favorable patient-reported outcomes after arthroscopic bursectomy in patients with chronic SAPS. One year after surgery, the mean WORC and VAS for pain scores improved significantly. About 19 patients (20%) developed a postoperative frozen shoulder. A longer duration of preoperative complaints and the peroperative identification of

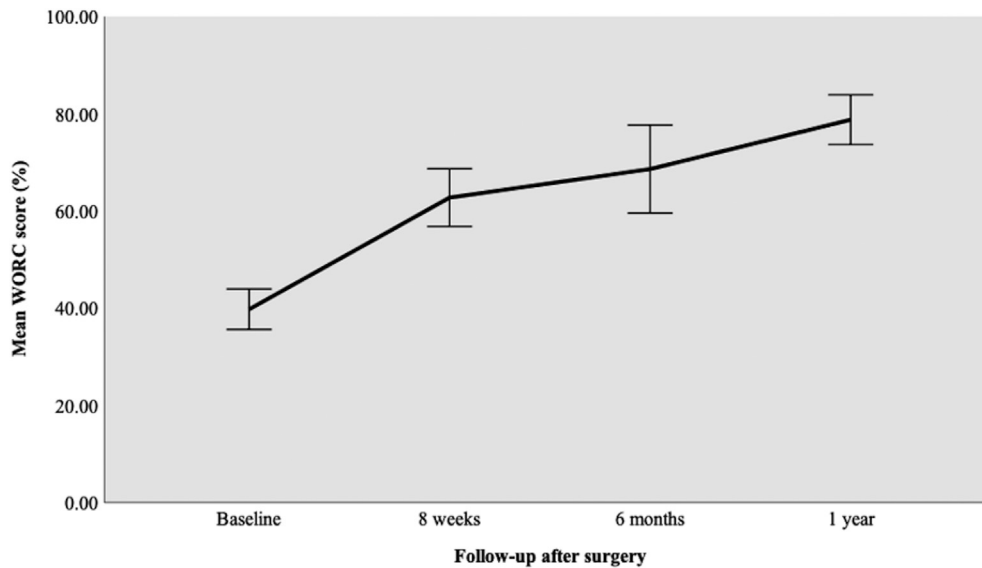


Figure 2 WORC score after arthroscopic bursectomy. Error bars: 95% confidence interval. WORC, Western Ontario Rotator Cuff index.

Table III Mixed model analysis WORC

Mixed models analysis WORC				
Factors	Estimate	95% CI		P value
		Lower bound	Upper bound	
Baseline*				
Age, y	-0.12	-0.670	0.424	.656
Duration of symptoms, m	-0.030	-0.0786	0.0194	.232
Radius humerus head, cm	0.71	-2.32	3.75	.641
Glenoid length, cm	0.18	-1.63	1.98	.846
Sex (female)	-0.53	-19.0	17.9	.954
Workers compensation	-12	-25.4	1.90	.0900
Diabetes mellitus	5.8	-9.09	20.7	.439
Biceps pathology	9.9	-7.86	27.6	.270
Degenerative glenoid cartilage	3.1	-11.4	17.6	.670
Follow-up*				
Age, y	-0.0024	-0.757	0.752	.995
Duration of symptoms, m	-0.086	-0.156	-0.0164	.0160
Radius humerus head, cm	1.2	-3.15	5.46	.596
Glenoid length, cm	-0.11	-2.77	2.56	.938
Sex (female)	15	-11.1	40.4	.263
Workers compensation	-5.1	-24.4	14.3	.606
Diabetes mellitus	-7.4	-27.8	12.9	.470
Biceps pathology	-20	-43.7	4.13	.104
Degenerative glenoid cartilage	-20	-39.4	-1.26	.0370

CI, confidence interval; y, years; m, months; cm, centimetre; WORC, Western Ontario Rotator Cuff index. Bold values indicate $P < .05$.

* Mixed model analysis: follow-up time (baseline, 8 weeks, 6 months, and 1 year), age, duration of preoperative complaints, radius humeral head, glenoid length, sex, workers compensation, diabetes mellitus, biceps tendinopathy, age × follow-up time, duration of preoperative complaints × follow-up time, radius humeral head × follow-up time, glenoid length × follow-up time, sex × follow-up time, workers compensation × follow-up time, diabetes mellitus × follow-up time, and biceps tendinopathy × follow-up time were investigated as fixed effects.

Table IV Multiple linear regression analysis VAS

Factors	Mean	95% CI		P value
		Lower bound	Upper bound	
Constant	-2.0	-5.18	1.13	.203
Duration of preoperative complaints	0.012	0.00500	0.0180	.001
Involved side (left)	0.64	-0.705	1.99	.341
Hand dominance (left)	0.91	-0.730	2.54	.270
Degenerative glenoid cartilage	-1.1	-3.70	1.59	.426
Degenerative humeral cartilage	-2.0	-4.94	0.849	.161
Labral lesion	-0.70	-3.96	2.55	.666

CI, confidence interval; VAS, visual analog scale. Bold values indicate $P < .05$.

Table V
Multiple logistic regression analysis: predictors for frozen shoulder

Factors	OR	95% CI for OR		P value
		Lower bound	Upper bound	
Sex (female)	2.5	0.716	9.04	.149
Critical shoulder angle	0.86	0.743	0.993	.0400
Workers compensation	4.4	1.07	18.0	.0400
Constant	67	-	-	.103

OR, odds ratio; CI, confidence interval.

Bold values indicate $P < .05$.

degenerative glenoid cartilage resulted in significantly worse results. A longer duration of preoperative complaints was also an independent predictor for an unfavorable course of pain. Finally, we found that a greater CSA was associated with lower odds for the development of a postoperative frozen shoulder, whereas having workers compensation was an independent risk factor.

In line with literature, we found that longer duration of preoperative complaints was associated with an unfavorable course of SAPS after surgical bursectomy.^{20,25,33,36} Interestingly, the preoperative identification of glenoid degeneration was also identified as a negative predictor for patient-reported outcomes after arthroscopic subacromial bursectomy. These results indicate that arthroscopic bursectomy on the nondegenerative shoulder joint results in better patient-reported outcomes compared with the degenerative shoulder. Our findings are in line with literature on knee arthroscopy, which shows unfavorable results for arthroscopy in degenerative knees with a degenerative meniscus tear.⁴³ This led to an adjustment of the guidelines, advising against arthroscopic meniscectomy for degenerative meniscus tears.⁴³ Recent literature on SAPS also showed no beneficial effect of bursectomy or arthroscopic decompression over (placebo) arthroscopy only, leading to guidelines advocating conservative treatment for SAPS.^{2,17,34,51} Although shoulder function and pain improved in most of our patients following this procedure, and there was a high satisfaction rate (80%), we acknowledge that this still might be due to a surgical placebo effect as shown by randomized studies.^{2,27,34} Rather than continuing arthroscopy in all patients, we have to identify and select the correct patient that benefits from surgery.¹⁷ Like in knee arthroscopy, our results indicate that arthroscopic subacromial bursectomy provides better outcomes in shoulders without degeneration. A logical explanation would be that the patients suspected to suffer from subacromial pain, are in fact having complaints due to glenohumeral chondropathy.

Nineteen patients (20%) developed a postoperative frozen shoulder in this study which is in line with numbers in literature (5%–32%).^{4,13,29,42} Our prospective design and strict diagnostic criteria contributed to a close observation of shoulder motion, and thus a more precise estimation of the prevalence of postoperative frozen shoulders, making information bias less likely.²⁹ Remarkably, most frozen shoulders developed 6 weeks after surgery with initially a good start. We argue whether this might be due to (over)use in combination with the regenerating subacromial bursa after surgery. Furthermore, our findings suggested that workers compensation might be predictive for developing a postoperative frozen shoulder. In most upper extremity surgery (and orthopedic surgery in general), patients receiving workers compensation have worse prognosis after surgery than patients without workers compensation.^{9,14} The exact reason for this effect is unknown, but it has been argued that these worse results may be due to psychological effects caused by injustice and victimisation.¹⁴ We did find that a greater CSA on the preoperative shoulder radiograph was a protective factor for the development of a postoperative frozen shoulder. Although the CSA has

been associated with several shoulder pathologies, it has not been associated with frozen shoulder.^{19,47} Factors such as hypothyroidism and diabetes mellitus have been associated with both idiopathic as well as postoperative frozen shoulders.^{4,41,53} We did not find an association between a postoperative frozen shoulder and these previous identified risk factors for a frozen shoulder. This could be due to a low prevalence of these risk factors in our study leading to an underpowered analysis to detect an effect.

Our findings should urge surgeons to reconsider arthroscopic bursectomy in SAPS patients with intra-articular pathology (such as degenerative joint cartilage). Given that the intra-articular pathology was identified during surgery, rather than during preoperative assessment or imaging, it might be worthwhile to assess the degree of degeneration before surgery with different methods (such as magnetic resonance imaging scan). Although conservative treatment should be pursued in most patients with SAPS, it could be considered in patients who were unsuccessfully treated with conservative options. New prognostic studies may further help identify subgroups within this SAPS group that will benefit from arthroscopic bursectomy after failed conservative management. Future research should include bigger cohorts for the investigated prognostic factors to avoid underpowered studies. Once identified, these subgroups could then be investigated in randomized placebo-controlled surgical trials (such as the CSAW and FIMPACT studies) to address the effectiveness of surgical procedures in these specific subgroups.^{2,34}

This study has several limitations. First, inherent to all cohort studies, we are only able to adjust for known associations and thus leaving room for confounding. We therefore tried to include various potential prognostic factors which have been previously described in literature to minimize confounding. Second, the loss of follow-up might have contributed to attrition bias. Despite our efforts, our loss to follow-up is substantial (22%). However, our follow-up rate is considered acceptable (78%), and for this reason, we believe that the loss of follow-up has not severely altered our conclusions.³⁰ Furthermore, besides arthroscopic bursectomy, some patients received additional surgical procedures, clouding associations between arthroscopic bursectomy and patient-reported outcome. Finally, the number of patients with hypothyroidism, Dupuytren's contracture, and cardiovascular disease was low, resulting in a limited power.

Conclusion

This study identified both demographic and clinical factors that predict the course after arthroscopic subacromial bursectomy. After failed conservative treatment, most patients had an improvement in WORC and VAS pain scores after arthroscopic bursectomy. A greater CSA was associated with lower odds for the development of a postoperative frozen shoulder, whereas having workers compensation was an independent risk factor. We found that arthroscopic bursectomy is less effective in patients with SAPS with a degenerative shoulder. This finding suggests that an improved treatment effect of arthroscopic subacromial bursectomy can be expected in patients with chronic SAPS if intra-articular pathologies such as glenohumeral osteoarthritis are sufficiently excluded.

Disclaimer

The authors, their immediate families, and any research foundations with which they are affiliated have not received any financial payments or other benefits from any commercial entity related to the subject of this article.

No funding was disclosed by the author(s).

Supplementary data

Supplementary data to this article can be found online at <https://doi.org/10.1016/j.jseint.2020.10.021>.

References

- Aydin A, Yildiz V, Kalali F, Yildirim OS, Topal M, Dostbil A. The role of acromion morphology in chronic subacromial impingement syndrome. *Acta Orthop Belg* 2011;77:733–6.
- Beard DJ, Rees JL, Cook JA, Rombach I, Cooper C, Merritt N, et al. Arthroscopic subacromial decompression for subacromial shoulder pain (CSAW): a multi-centre, pragmatic, parallel group, placebo-controlled, three-group, randomised surgical trial. *Lancet* 2018;391:329–38. [https://doi.org/10.1016/S0140-6736\(17\)32457-1](https://doi.org/10.1016/S0140-6736(17)32457-1).
- LU Bigliani, Ticker JB, Flatow EL, Soslowky LJ, Mow VC. The relationship of acromial architecture to rotator cuff disease. *Clin Sports Med* 1991;10:823–38.
- Blonna D, Fissore F, Bellato E, La Malfa M, Calo M, Bonasia DE, et al. Subclinical hypothyroidism and diabetes as risk factors for postoperative stiff shoulder. *Knee Surg Sports Traumatol Arthrosc* 2017;25:2208–16. <https://doi.org/10.1007/s00167-015-3906-z>.
- Bouchard A, Garret J, Favard L, Charles H, Ollat D. Failed subacromial decompression. Risk factors. *Orthop Traumatol Surg Res* 2014;100:S365–9. <https://doi.org/10.1016/j.otsr.2014.09.006>.
- Codman EA. The shoulder rupture of the supraspinatus tendon and other lesions in or about the subacromial bursa. Boston: T.Todd Co.; 1934.
- Cummins CA, Sasso LM, Nicholson D. Impingement syndrome: temporal outcomes of nonoperative treatment. *J Shoulder Elbow Surg* 2009;18:172–7. <https://doi.org/10.1016/j.jse.2008.09.005>.
- Dalboe A, Frost P, Andersen JH, Svendsen SW. Surgery for subacromial impingement syndrome in relation to occupational exposures, lifestyle factors and diabetes mellitus: a nationwide nested case-control study. *Occup Environ Med* 2017;74:728–36. <https://doi.org/10.1136/oemed-2016-104272>.
- de Moraes VY, Godin K, Tamaoki MJ, Faloppa F, Bhandari M, Belloti JC. Workers' compensation status: does it affect orthopaedic surgery outcomes? A meta-analysis. *PLoS One* 2012;7:e50251. <https://doi.org/10.1371/journal.pone.0050251>.
- de Witte PB, de Groot JH, van Zwet EW, Ludewig PM, Nagels J, Nelissen RG, et al. Communication breakdown: clinicians disagree on subacromial impingement. *Med Biol Eng Comput* 2014;52:221–31. <https://doi.org/10.1007/s11517-013-1075-0>.
- Diercks R, Bron C, Dorrestijn O, Meskers C, Naber R, de Ruiter T, et al. Guideline for diagnosis and treatment of subacromial pain syndrome: a multidisciplinary review by the Dutch Orthopaedic Association. *Acta Orthop* 2014;85:314–22. <https://doi.org/10.3109/17453674.2014.920991>.
- Donigan JA, Wolf BR. Arthroscopic subacromial decompression: acromioplasty versus bursectomy alone—does it really matter? A systematic review. *Iowa Orthop J* 2011;31:121–6.
- Evans JP, Guyver PM, Smith CD. Frozen shoulder after simple arthroscopic shoulder procedures: What is the risk? *Bone Joint J* 2015;97-B:963–6. <https://doi.org/10.1302/0301-620X.97B7.35387>.
- Fujihara Y, Shauver MJ, Lark ME, Zhong L, Chung KC. The Effect of Workers' Compensation on Outcome Measurement Methods after Upper Extremity Surgery: A Systematic Review and Meta-Analysis. *Plast Reconstr Surg* 2017;139:923–33. <https://doi.org/10.1097/PRS.00000000000003154>.
- Garving C, Jakob S, Bauer I, Nadjar R, Brunner UH. Impingement Syndrome of the Shoulder. *Dtsch Arztebl Int* 2017;114:765–76. <https://doi.org/10.3238/arztebl.2017.0765>.
- Greving K, Dorrestijn O, Winters JC, Groenhof F, van der Meer K, Stevens M, et al. Incidence, prevalence, and consultation rates of shoulder complaints in general practice. *Scand J Rheumatol* 2012;41:150–5. <https://doi.org/10.3109/03009742.2011.605390>.
- Haddad FS, Corbett SA, Hatrick NC, Tennent TD. The assault on arthroscopy: is there a middle ground? *Bone Joint J* 2019;101-B:4–6. <https://doi.org/10.1302/0301-620X.101B1.BJJ-2018-1377>.
- Henkus HE, de Witte PB, Nelissen RG, Brand R, van Arkel ER. Bursectomy compared with acromioplasty in the management of subacromial impingement syndrome: a prospective randomised study. *J Bone Joint Surg Br* 2009;91:504–10. <https://doi.org/10.1302/0301-620X.91B4.21442>.
- Heuberger PR, Plachel F, Willinger L, Moroder P, Laky B, Pauzenberger L, et al. Critical shoulder angle combined with age predict five shoulder pathologies: a retrospective analysis of 1000 cases. *BMC Musculoskelet Disord* 2017;18:259. <https://doi.org/10.1186/s12891-017-1559-4>.
- Inderhaug E, Kalsvik M, Kollevold KH, Hegna J, Solheim E. Long-term results after surgical treatment of subacromial pain syndrome with or without rotator cuff tear. *J Orthop* 2018;15:757–60. <https://doi.org/10.1016/j.jor.2018.03.004>.
- Judge A, Murphy RJ, Maxwell R, Arden NK, Carr AJ. Temporal trends and geographical variation in the use of subacromial decompression and rotator cuff repair of the shoulder in England. *Bone Joint J* 2014;96-B:70–4. <https://doi.org/10.1302/0301-620X.96B1.32556>.
- Jung JY, Jee WH, Chun HJ, Kim YS, Chung YG, Kim JM. Adhesive capsulitis of the shoulder: evaluation with MR arthrography. *Eur Radiol* 2006;16:791–6. <https://doi.org/10.1007/s00330-005-0020-5>.
- Kappe T, Knappe K, Elsharkawi M, Reichel H, Cakir B. Predictive value of pre-operative clinical examination for subacromial decompression in impingement syndrome. *Knee Surg Sports Traumatol Arthrosc* 2015;23:443–8. <https://doi.org/10.1007/s00167-013-2386-2>.
- Katthagen JC, Marchetti DC, Tahal DS, Turnbull TL, Millett PJ. The Effects of Arthroscopic Lateral Acromioplasty on the Critical Shoulder Angle and the Anterolateral Deltoid Origin: An Anatomic Cadaveric Study. *Arthroscopy* 2016;32:569–75. <https://doi.org/10.1016/j.arthro.2015.12.019>.
- Ketola S, Lehtinen J, Rousi T, Nissinen M, Huhtala H, Arnala I. Which patients do not recover from shoulder impingement syndrome, either with operative treatment or with nonoperative treatment? *Acta Orthop* 2015;86:641–6. <https://doi.org/10.3109/17453674.2015.1033309>.
- Klintberg IH, Svantesson U, Karlsson J. Long-term patient satisfaction and functional outcome 8–11 years after subacromial decompression. *Knee Surg Sports Traumatol Arthrosc* 2010;18:394–403. <https://doi.org/10.1007/s00167-009-0963-1>.
- Kolk A, Thomassen BJW, Hund H, de Witte PB, Henkus HE, Wassenaar WG, et al. Does acromioplasty result in favorable clinical and radiologic outcomes in the management of chronic subacromial pain syndrome? A double-blinded randomized clinical trial with 9 to 14 years' follow-up. *J Shoulder Elbow Surg* 2017;26:1407–15. <https://doi.org/10.1016/j.jse.2017.03.021>.
- Konradsen LA, Jensen CH. Arthroscopic subacromial decompression results in normal shoulder function after two years in less than 50% of patients. *Dan Med J* 2015;62.
- Koorevaar RC, Van't Riet E, Ipskamp M, Bulstra SK. Incidence and prognostic factors for postoperative frozen shoulder after shoulder surgery: a prospective cohort study. *Arch Orthop Trauma Surg* 2017;137:293–301. <https://doi.org/10.1007/s00402-016-2589-3>.
- Kristman V, Manno M, Cote P. Loss to follow-up in cohort studies: how much is too much? *Eur J Epidemiol* 2004;19:751–60. <https://doi.org/10.1023/b:ejep.0000036568.02655.f8>.
- Linsell L, Dawson J, Zondervan K, Rose P, Randall T, Fitzpatrick R, et al. Prevalence and incidence of adults consulting for shoulder conditions in UK primary care: patterns of diagnosis and referral. *Rheumatology (Oxford)* 2006;45:215–21. <https://doi.org/10.1093/rheumatology/kei139>.
- Mengiardi B, Pfirrmann CW, Gerber C, Hodler J, Zanetti M. Frozen shoulder: MR arthrographic findings. *Radiology* 2004;233:486–92. <https://doi.org/10.1148/radiol.2332031219>.
- Miyazaki AN, Fregoneze M, da Silva LA, do Val Sella G, Garotti JE, Checchia SL. Evaluation of the results from non-arthroplastic treatment (arthroscopy) for shoulder arthrosis. *Rev Bras Ortop* 2015;50:389–94. <https://doi.org/10.1016/j.rboe.2015.06.008>.
- Paavola M, Malmivaara A, Taimela S, Kanto K, Inkinen J, Kalske J, et al. Subacromial decompression versus diagnostic arthroscopy for shoulder impingement: randomised, placebo surgery controlled clinical trial. *BMJ* 2018;362:k2860. <https://doi.org/10.1136/bmj.k2860>.
- Park GY, Lee JH, Kwon DG. Ultrasonographic measurement of the axillary recess thickness in an asymptomatic shoulder. *Ultrasonography* 2017;36:139–43. <https://doi.org/10.14366/usg.16032>.
- Patel VR, Singh D, Calvert PT, Bayley JL. Arthroscopic subacromial decompression: results and factors affecting outcome. *J Shoulder Elbow Surg* 1999;8:231–7.
- Rekola KE, Keinänen-Kiukaanniemi S, Takala J. Use of primary health services in sparsely populated country districts by patients with musculoskeletal symptoms: consultations with a physician. *J Epidemiol Community Health* 1993;47:153–7.
- Rudbeck M, Jensen SL, Fonager K. Arthroscopic subacromial decompression and predictors of long-term sick leave benefit and permanent benefits. *J Shoulder Elbow Surg* 2013;22:1167–72. <https://doi.org/10.1016/j.jse.2012.12.003>.
- Sano H, Ishii H, Trudel G, Uthoff HK. Histologic evidence of degeneration at the insertion of 3 rotator cuff tendons: a comparative study with human cadaveric shoulders. *J Shoulder Elbow Surg* 1999;8:574–9.
- Saupe N, Pfirrmann CW, Schmid MR, Jost B, Werner CM, Zanetti M. Association between rotator cuff abnormalities and reduced acromio-humeral distance. *AJR Am J Roentgenol* 2006;187:376–82. <https://doi.org/10.2214/AJR.05.0435>.
- Schiefer M, Teixeira PFS, Fontenelle C, Carminatti T, Santos DA, Rigli LD, et al. Prevalence of hypothyroidism in patients with frozen shoulder. *J Shoulder Elbow Surg* 2017;26:49–55. <https://doi.org/10.1016/j.jse.2016.04.026>.
- Seo SS, Choi JS, An KC, Kim JH, Kim SB. The factors affecting stiffness occurring with rotator cuff tear. *J Shoulder Elbow Surg* 2012;21:304–9. <https://doi.org/10.1016/j.jse.2011.04.011>.
- Siemieniuk RAC, Harris IA, Agoritsas T, Poolman RW, Brignardello-Petersen R, Van de Velde S, et al. Arthroscopic surgery for degenerative knee arthritis and meniscal tears: a clinical practice guideline. *BMJ* 2017;357:j1982. <https://doi.org/10.1136/bmj.j1982>.
- Singh HP, Mehta SS, Pandey R. A preoperative scoring system to select patients for arthroscopic subacromial decompression. *J Shoulder Elbow Surg* 2014;23:1251–6. <https://doi.org/10.1016/j.jse.2014.05.030>.
- Slattery C, Kweon CY. Classifications in Brief: Outerbridge Classification of Chondral Lesions. *Clin Orthop Relat Res* 2018;476:2101–4. <https://doi.org/10.1007/s11999.0000000000000255>.
- Smith SP, Devaraj VS, Bunker TD. The association between frozen shoulder and Dupuytren's disease. *J Shoulder Elbow Surg* 2001;10:149–51.

47. Spiegl UJ, Horan MP, Smith SW, Ho CP, Millett PJ. The critical shoulder angle is associated with rotator cuff tears and shoulder osteoarthritis and is better assessed with radiographs over MRI. *Knee Surg Sports Traumatol Arthrosc* 2016;24:2244-51. <https://doi.org/10.1007/s00167-015-3587-7>.
48. Steenbrink F, de Groot JH, Veeger HE, Meskers CG, van de Sande MA, Rozing PM. Pathological muscle activation patterns in patients with massive rotator cuff tears, with and without subacromial anaesthetics. *Man Ther* 2006;11:231-7. <https://doi.org/10.1016/j.math.2006.07.004>.
49. van der Windt DA, Koes BW, de Jong BA, Bouter LM. Shoulder disorders in general practice: incidence, patient characteristics, and management. *Ann Rheum Dis* 1995;54:959-64.
50. van der Windt DA, Thomas E, Pope DP, de Winter AF, Macfarlane GJ, Bouter LM, et al. Occupational risk factors for shoulder pain: a systematic review. *Occup Environ Med* 2000;57:433-42.
51. Vandvik PO, Lahdeoja T, Ardern C, Buchbinder R, Moro J, Brox JJ, et al. Subacromial decompression surgery for adults with shoulder pain: a clinical practice guideline. *BMJ* 2019;364:l294. <https://doi.org/10.1136/bmj.l294>.
52. Vitale MA, Arons RR, Hurwitz S, Ahmad CS, Levine WN. The rising incidence of acromioplasty. *J Bone Joint Surg Am* 2010;92:1842-50. <https://doi.org/10.2106/JBJS.1.01003>.
53. Zreik NH, Malik RA, Charalambous CP. Adhesive capsulitis of the shoulder and diabetes: a meta-analysis of prevalence. *Muscles Ligaments Tendons J* 2016;6: 26-34. <https://doi.org/10.11138/mltj/2016.6.1.026>.