

“Triple-Fix” Arthroscopic Biceps Tenodesis: Indications and Technique



Wood W. Dale, M.D., S. Gray McClatchy, M.D., and Larry D. Field, M.D.

Abstract: Pathology of the long head of the bicep tendon is a common cause of anterior shoulder pain and frequently is treated surgically using either tenodesis or tenotomy. Tenodesis often is the preferred technique for younger, more active patients and laborers, especially when cosmesis and preservation of function are clinical priorities. However, the security of the tenodesis varies with fixation methods and techniques, and failure of the tenodesis can have both cosmetic and symptomatic consequences. Traditional arthroscopic tenodesis also can be technically challenging, as it usually requires extra-articular identification of the bicep tendon within the bicipital groove. The arthroscopic surgical technique described is an approach that has been routinely employed by the senior author for approximately 8 years that allows for accurate and reproducible exposure of the biceps tendon within the bicipital groove along with secure, anatomic tenodesis of the long head of the bicep tendon.

The long head of the bicep tendon is a common source of anterior shoulder pain. Symptoms occurring as a consequence of biceps pathology are generated due to biceps tendinitis, a partial biceps tear, biceps instability, and SLAP lesions.¹ Frequently, these types of biceps tendon lesions are surgically managed using either tenodesis or tenotomy. Biceps tenodesis has been compared with tenotomy regarding cosmesis, complications, and functional outcomes, but many of these studies have failed to demonstrate statistically different outcomes for these and other parameters.²⁻⁴ In addition, studies comparing tenodesis techniques also have often failed to clearly demonstrate superiority of one technique over others.²⁻⁵ Frequently, the decision regarding tenodesis or

tenotomy is selected based on the surgeon’s discretion and individual patient factors (age, sex, activity level, and habitus). Tenotomy is technically easier, cheaper, and quicker to perform than tenodesis. However, tenodesis has the potential benefit of improved cosmesis due to the decreased risk of developing a “Popeye” deformity and is considered by many shoulder surgeons to be a better choice for younger patients with high physical demands and in patients who are cognizant of cosmetic appearance.^{2,3} Tenodesis also carries a lower risk of postoperative biceps cramping or spasms than tenotomy.¹

Many different surgical techniques have been described to accomplish long head of the bicep tendon (LHBT) tenodesis. However, each technique has its potential advantages and drawbacks. Several authors have examined the biomechanical properties of tenodesis techniques and found widely varying load-to-failure results based on fixation methods.^{6,7} To minimize complications resulting from tenodesis fixation failure, ensuring that the surgeon employs a secure tenodesis method is important. This article describes a technique developed by the authors that combines an efficient and reproducible method to expose the extra-articular biceps tendon with a secure arthroscopic tenodesis using a triple-loaded suture anchor that allows for “triple-fix” augmented fixation.⁸

Surgical Technique (With Video Illustration)

Following induction of general anesthesia, the patient is placed in the beach-chair position and bony

From the University of Mississippi Medical Center (W.W.D) and Mississippi Sports Medicine and Orthopaedic Center (G.M., L.D.F.), Jackson, Mississippi, U.S.A.

The authors report the following potential conflicts of interest or sources of funding: L.D.F. reports consulting income from Smith & Nephew and research and educational support from Arthrex, Mitek, and Smith & Nephew. Full ICMJE author disclosure forms are available for this article online, as supplementary material.

Address correspondence to Larry D. Field, M.D., Mississippi Sports Medicine and Orthopaedic Center, 1325 E. Fortification St., Jackson, MS 39202. E-mail: LField@msmcc.com

© 2022 THE AUTHORS. Published by Elsevier Inc. on behalf of the Arthroscopy Association of North America. This is an open access article under the CC BY-NC-ND license (<http://creativecommons.org/licenses/by-nc-nd/4.0/>).

2212-6287/211578

<https://doi.org/10.1016/j.eats.2022.01.002>

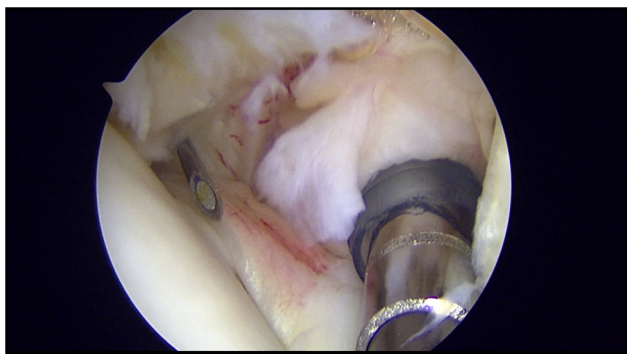


Fig 1. For the left shoulder in the beach-chair position, as viewed from the posterior portal, the spinal needle is shown localizing the biceps tendon at its exit into the bicipital groove (indicated by an arrow).

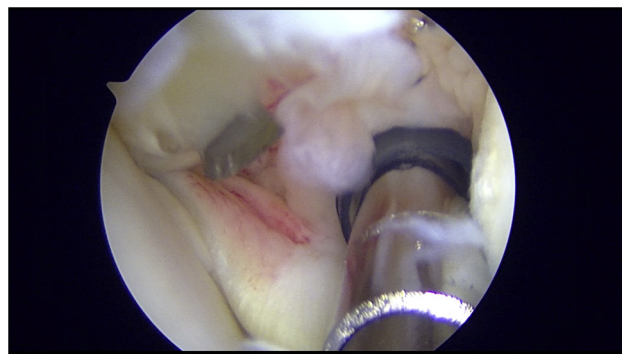


Fig 2. For the left shoulder in the beach-chair position, as viewed from the posterior glenohumeral joint portal, a #15-blade is used to incise the most lateral portion of the rotator interval capsule and the superior portion of the transverse humeral ligament (indicated by an arrow).

landmarks are palpated and marked for standard arthroscopic portal placement. The posterior portal is established, and the glenohumeral joint is inspected. The anterior–superior portal location is then localized using an 18-gauge spinal needle centered within the rotator interval (*Video 1*). The spinal needle is removed, and a plastic trocar and cannula are placed into the anterior superior portal. The LHBT and superior labrum are carefully inspected for pathology. Likewise, the upper border of the subscapularis is evaluated carefully as well. A probe or shaver blade is used to pull the biceps tendon into the glenohumeral joint to the extent possible so as to allow for assessment of this extra-articular portion of the biceps tendon. The glenohumeral joint is then thoroughly inspected, and any intra-articular pathology is addressed at this point. An 18-gauge spinal needle is then used to localize the LHBT at its exit point from the glenohumeral joint as it enters the bicipital groove (*Fig 1*). A scalpel with attached #15 blade is then advanced percutaneously in parallel with the spinal needle until the blade is seen to perforate the tissue immediately anterior to the biceps tendon at the location where the biceps enters the bicipital groove (*Fig 2*). This perforation is then extended distally in parallel with and directly over the biceps tendon as the tendon travels more distally through the bicipital groove. Care is taken carefully observe the path of the scalpel blade so as not to inadvertently damage the biceps tendon immediately adjacent to the scalpel. Arthroscopic scissors (Arthrex, Naples, FL) are then placed through the anterior superior portal and are used to release approximately 80% of the LHBT at its origin on the superior glenoid, leaving the remaining tendon attached to ensure that the tenodesis is performed while the biceps remains in its anatomic location (*Fig 3*). This near-complete release of the tendon makes subsequent release of the remaining intact biceps tendon origin easier to

accomplish since, after the tenodesis is completed, the remaining intact proximal biceps tendon is released blindly by advancing the open suture scissors along the proximal biceps tendon until the origin is reached and the scissors closed.

Following incision of the bicipital groove and partial release of the biceps tendon at its origin, the sub-acromial space is entered and any indicated procedures such as bursectomy, acromioplasty, and rotator cuff repair are accomplished. After completion of such procedures, the “slit” in the transverse humeral ligament overlying the bicipital groove that had been created earlier in the procedure is easily identified (*Fig 4*). An arthroscopic shaver (4.5-mm DYONICS INCISOR Plus PLATINUM; Smith & Nephew, Memphis, TN) is then used to excise the transverse humeral ligament tissue that overlies the biceps tendon within the bicipital groove. In addition, either the arthroscopic shaver or a curette is then used to abrade the bony bicipital groove. Next, the biceps tendon is then grasped

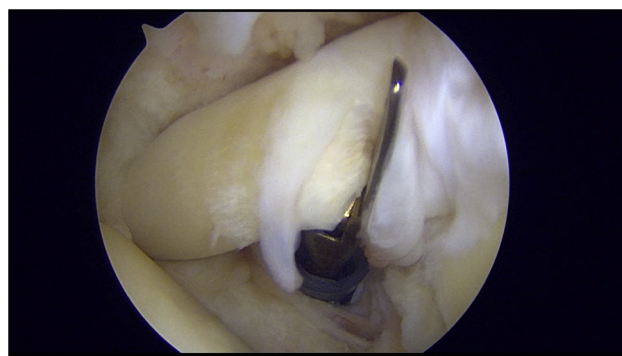


Fig 3. Partial tenotomy of the proximal biceps tendon at its origin on the superior glenoid using arthroscopic suture scissors in this left shoulder in the beach chair position as viewed from the posterior portal.

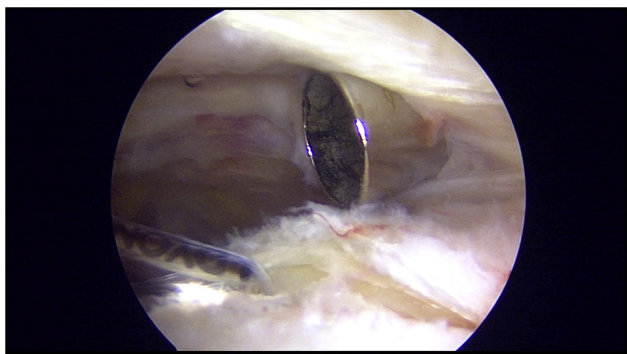


Fig 4. For the left shoulder in the beach-chair position, as viewed from the lateral subacromial portal, the biceps tendon is localized by identifying the incision of the transverse humeral ligament (indicated by an arrow).

using an arthroscopic ratcheted grasper and translated laterally out of the biceps groove. This maneuver provides excellent exposure of the bicipital groove so that an awl punch and tap can be used to create a hole that accommodates the placement of a triple loaded suture anchor (HEALICOIL REGENESORB; Smith & Nephew) (Fig 5). The ratcheted grasper is then used to translate the biceps tendon medial to the biceps groove. This maneuver exposes the suture anchor sutures and greatly facilitates retrieval of these sutures. The limb of the first of the 3 sutures is retrieved in a circumferential pattern around the biceps. The second suture anchor suture is passed around the LHBT using a girth hitch or "luggage tag" construct. The third suture anchor suture is passed through the biceps tendon substance using a suture passer (Mitek IDEAL Suture Grasper; Depuy Synthes, West Chester, PA) and then similarly fashioned to create another girth hitch (Fig 6). The

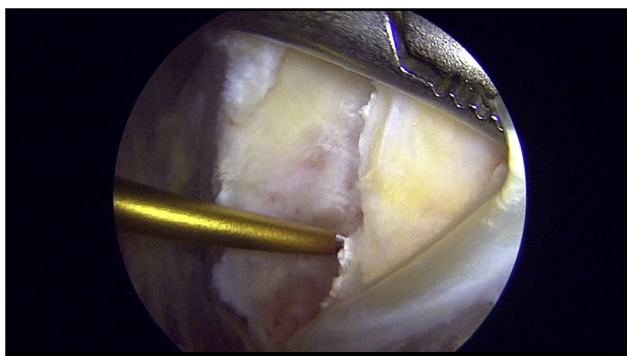

Fig 5. For the left shoulder in the beach-chair position, as viewed from the lateral subacromial portal, lateral retraction of the long head of the bicep tendon exposes the bicipital groove bony architecture and helps facilitate accurate suture anchor placement (indicated by an arrow).

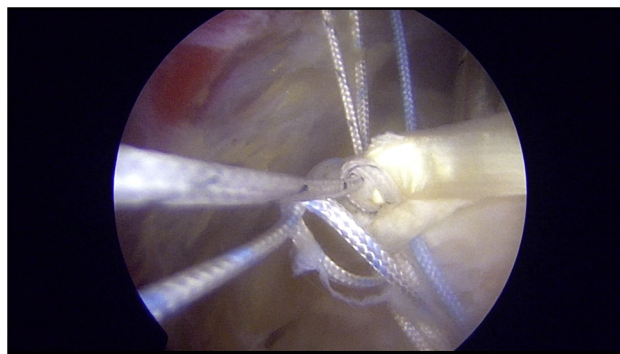


Fig 6. For the left shoulder in the beach-chair position, as viewed from the lateral subacromial portal, 3 sutures passed using a circumferential suture (arrow "A"), a luggage tag suture that surrounds the entire biceps tendon (arrow "B"), and a transtendinous luggage tag suture (arrow "C") are demonstrated.

circumferential suture pair is tied using a sliding knot, and the 2 girth hitch suture pairs are tied using non-sliding knots by alternating half hitches and posts. Also, since the biceps is tenodesed in situ, an anatomic tenodesis has been accomplished. Once all knots are tied, the same arthroscopic scissors, used earlier to partially tenotomize the biceps, are then advanced through the "slit" with the scissor blades in the open position following the biceps proximally into the glenohumeral joint while arthroscopically visualizing from lateral subacromial portal, and the proximal biceps tenotomy is completely "blindly" by closing the scissor blades once the scissors reach the most proximal aspect of the biceps tendon. The proximal stump of the LHBT is then debrided using the arthroscopic shaver (Fig 7). The limited incision through the rotator interval capsule may be optionally reapproximated side-to-side repair using suture passed across the incision and tied (FiberWire #2; Arthrex) although the authors rarely close this rotator interval incision. Figure 8 shows final secure tenodesis of the LHBT.

Discussion

Biceps tenodesis is a common procedure that is carried out with increasing frequency as the prevalence of biceps pathology is better recognized and more often treated.⁹ Tenodesis can be performed either arthroscopically or open. Arthroscopic tenodesis obviates the requirement to perform an additional open procedure with its inherent risks and carries a decreased risk of nerve injury or surgical-site pain and tenderness compared with open tenodesis.¹ Open biceps tenodesis has been shown to have the benefit of a shorter surgical time and lower costs in some studies compared

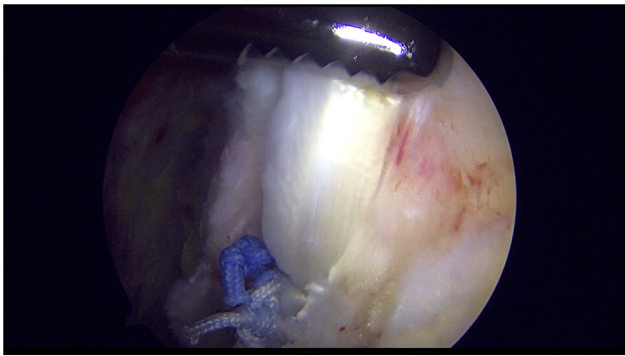


Fig 7. For the left shoulder in the beach-chair position, viewed from the lateral subacromial portal, the remaining long head of the bicep tendon stump that is present following release of the biceps tendon at its origin is debrided.

with arthroscopic treatment.¹⁰ In addition, open treatment secures the biceps tendon distal to the bicipital groove compared with arthroscopic treatment. Tenodesis of the biceps tendon within the bicipital groove has been reported to potentially contribute to residual anterior shoulder “groove pain.”¹¹ Despite these potential drawbacks related to both open and arthroscopic techniques for biceps tenodesis, multiple studies comparing postoperative outcomes of arthroscopic versus open approaches have failed to show superiority of one technique over the other.^{1,11} However, open biceps tenodesis has shown a slightly greater complication rate in some studies, including a greater risk of wound complications and the potential for more serious iatrogenic complications such as nerve and vascular injury.¹² Table 1 details advantages, disadvantages, and limitations of the authors’ described tenodesis technique.

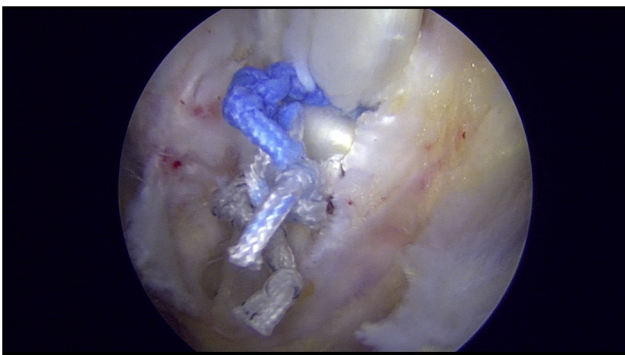


Fig 8. For the left shoulder in the beach-chair position, viewed from the lateral subacromial portal, the completed biceps tenodesis is shown.

Table 1. Advantages, Disadvantages, and Limitations

Advantages
Provides secure, triple-fixation of the LHBT
Facilitates identification of the LHBT in the subacromial space
Allows for anatomic tensioning of the LHBT tenodesis
Provides secure tenodesis of the biceps tendon
Disadvantages and limitations
Does not address all pathology contained within the bicipital groove
Risk of inadvertent complete transection of the biceps tendon before tenodesis
Cost of additional suture anchor for tenodesis

LHBT, long head of the bicep tendon.

One of the challenges related to arthroscopic tenodesis within the bicipital groove is identification of the groove itself from a subacromial viewing perspective. No consistent landmarks are present in the subacromial space that can reliably guide the surgeon to the bicipital groove. Often, the surgeon must rely on arthroscopically assisted palpation of the anterior humeral head structures along with trial and error to localize the bicipital groove. The described “slit” technique greatly simplifies the ease of identifying the bicipital groove, making this step very reliable and efficient.⁸ Table 2 further lists technique suggestions and precautions.

Another challenge associated with both arthroscopic and open tenodesis techniques relates to the difficulty in reliably and accurately determining the proper tension of the biceps to ensure anatomic tenodesis. Leaving the biceps attached to the superior glenoid until the tenodesis is completed, as is carried out in the described technique, eliminates this challenge since anatomic tenodesis is assured. Nonanatomic positioning of the biceps tendon may lead to a Popeye deformity even if the biceps tenodesis heals uneventfully.^{2,3,13} Similarly, excessive, supraphysiologic tension due to nonanatomic overly proximal translation of the biceps tendon can cause biceps asymmetry and also may lead to postoperative biceps symptoms or tenodesis failure. The described technique avoids improper tensioning because the biceps tenodesis is completed in situ before releasing the biceps proximally.

Tenodesis of the LHBT must be secure to help avoid post-operative fixation failure and subsequent Popeye deformity. Diaz et al.⁶ studied the biomechanical properties of six different fixation methods and found increased fixation strength with cortical button and with double-loaded suture anchor fixation methods. Using a suture anchor with additional sutures for fixation theoretically increases construct strength and load-to-failure without increased technical difficulty. The additional sutures serve to distribute the load as well as capture additional tendon fibers. The described

Table 2. Pearls and Pitfalls

Well-planned suture management is important when performing triple-fixation of the biceps.
Percutaneous outside-in incision of the rotator interval requires precise triangulation to avoid iatrogenic injury. Needle localization of the biceps tendon before performing the release is important.
Leaving the spinal needle in place while performing the release can serve as a guide for appropriate location and trajectory of the rotator interval incision.
Transection of the LHBT at its origin, from the subacromial space, can be difficult. Partial release of the biceps tendon during glenohumeral arthroscopy facilitates this step.
The biceps tendon is at risk for inadvertent complete release during partial release or percutaneous outside-in incision of the rotator interval.
Lateral retraction of the LBHT during suture anchor placement followed by medial retraction of the LHBT during fixation aids with suture passage.

LHBT, long head of the bicep tendon.

technique uses a triple-loaded suture anchor and employs 3 distinct suture passage patterns designed to maximize fixation strength: a circumferential suture, a luggage tag suture placed around the biceps tendon, and a second luggage tag suture placed through the biceps tendon.

References

1. Deng ZJ, Yin C, Cusano J, et al. Outcomes and complications after primary arthroscopic suprapectoral versus open subpectoral biceps tenodesis for superior labral anterior-posterior tears or biceps abnormalities: A systematic review and meta-analysis. *Orthop J Sports Med* 2020;8. 232596712094532. <https://doi.org/10.1177/2325967120945322>.
2. Belk JW, Kraeutler MJ, Houck DA, Chrisman AN, Scillia AJ, McCarty EC. Biceps tenodesis versus tenotomy: A systematic review and meta-analysis of level I randomized controlled trials. *J Shoulder Elbow Surg* 2021;30: 951-960. <https://doi.org/10.1016/j.jse.2020.11.012>.
3. Zhu XM, Leroux T, Ben-David E, et al. A meta-analysis of level I evidence comparing tenotomy vs tenodesis in the management of long head of biceps pathology. *J Shoulder Elbow Surg* 2021;30:961-968. <https://doi.org/10.1016/j.jse.2021.02.002>.
4. Patel KV, Bravman J, Vidal A, Chrisman A, McCarty E. Biceps tenotomy versus tenodesis. *Clin Sports Med* 2016;35: 93-111. <https://doi.org/10.1016/j.csm.2015.08.008>.
5. Frost A, Zafar MS, Maffulli N. Tenotomy versus tenodesis in the management of pathologic lesions of the tendon of the long head of the biceps brachii. *Am J Sports Med* 2009;37: 828-833. <https://doi.org/10.1177/0363546508322179>.
6. Diaz M, Shi BY, Baker MC, Binkley MT, Belkoff SM, Srikumaran U. Open biceps tenodesis: A biomechanical comparison of 6 fixation techniques. *Orthopedics* 2020;43: e102-e108. <https://doi.org/10.3928/01477447-20200107-03>.
7. Zhong M, Zhu W, Lu W. What method of fixation is superior for biceps tenodesis? *Orthopedics* 2020;43:201. <https://doi.org/10.3928/01477447-20200604-01>.
8. Mazoch MJ, Frevert WF, Field LD. Identifying and exposing the proximal biceps in its groove: The "slit" technique. *Arthrosc Tech* 2017;6:e1285-e1290. <https://doi.org/10.1016/j.eats.2017.05.008>.
9. Vellios EE, Nazemi AK, Yerasosian MG, et al. Demographic trends in arthroscopic and open biceps tenodesis across the United States. *J Shoulder Elbow Surg* 2015;24:e279-285. <https://doi.org/10.1016/j.jse.2015.04.021>.
10. DeFroda SF, Li L, Milner J, Bokshan SL, Owens BD. Cost comparison of arthroscopic rotator cuff repair with arthroscopic vs. open biceps tenodesis. *J Shoulder Elbow Surg* 2021;30:340-345. <https://doi.org/10.1016/j.jse.2020.05.031>.
11. Duchman KR, DeMik DE, Uribe B, Wolf BR, Bollier M. Open versus arthroscopic biceps tenodesis: A comparison of functional outcomes. *Iowa Orthop J* 2016;36:79-87.
12. Gowd AK, Liu JN, Garcia GH, et al. Open biceps tenodesis associated with slightly greater rate of 30-day complications than arthroscopic: A propensity-matched analysis. *Arthroscopy* 2019;35:1044-1049. <https://doi.org/10.1016/j.arthro.2018.11.036>.
13. Hsu AR, Ghodadra NS, Provencher MT, Lewis PB, Bach BR. Biceps tenotomy versus tenodesis: A review of clinical outcomes and biomechanical results. *J Shoulder Elbow Surg* 2011;20:326-332. <https://doi.org/10.1016/j.jse.2010.08.019>.