

Evaluation of anesthesia management, feasibility and efficacy of peroral endoscopic myotomy (POEM) for achalasia performed in the endoscopy unit

Authors

Dennis Yang¹, Davinderbir Pannu¹, Qing Zhang¹, Jeffrey D. White², Peter V. Draganov¹

Institutions

¹ Division of Gastroenterology, Hepatology and Nutrition, University of Florida, Gainesville, Florida, United States
² Department of Anesthesia, University of Florida, Gainesville, Florida, United States

submitted 15. March 2015
accepted after revision 17. March 2015

Bibliography

DOI <http://dx.doi.org/10.1055/s-0034-1391965>
Published online: 5.5.2015
Endosc Int Open 2015; 03: E289–E295
© Georg Thieme Verlag KG
Stuttgart · New York
E-ISSN 2196-9736

Corresponding author

Peter V. Draganov
Division of Gastroenterology,
University of Florida
1329 SW 16th Street, Room
#5251
Gainesville, Florida 32608
United States
Fax: +1-352-627-9002
peter.draganov@medicine.ufl.edu

Introduction: Data on anesthesia management and outcomes associated with peroral endoscopic myotomy (POEM) performed exclusively in the endoscopy unit are limited. In this prospective study, we evaluated the safety of anesthesia management, and the feasibility and efficacy of POEM performed exclusively in the endoscopy unit.

Methods: A single-center prospective study of consecutive patients with achalasia treated with POEM in an endoscopy unit was performed. Safety of anesthesia management and POEM were determined by procedure-related adverse events. Feasibility was assessed by completion rate. Short-term efficacy was established by clinical success (Eckardt score ≤ 3) and by comparing Eckardt and dysphagia scores before and after POEM.

Results: Patients (n=52) underwent POEM under general anesthesia with endotracheal intubation and positive pressure ventilation. Aspiration was prevented by keeping patients on a clear liquid

diet before the procedure without requiring a prior esophagogastroduodenoscopy for esophageal content clearance. POEM completion rate was 96% (50/52 patients). There was no post-POEM bleeding. Postprocedure leak was observed in one patient (3%). Four patients (7.7%) experienced mucosal injury, three of them were treated uneventfully endoscopically and one required laparoscopic repair. Clinical success was achieved in 88% of patients. There was a significant decrease in the mean Eckardt score (8.1 to 1.4) and dysphagia score (2.4 to 0.4) ($P < 0.0001$) at the one month follow up after POEM.

Conclusion: Anesthesia management of POEM is safe in the endoscopy unit and aspiration can be prevented without requiring prior esophagogastroduodenoscopy for esophageal content clearance. Overall, POEM performed by a gastroenterologist in the endoscopy unit was feasible and effective for the treatment of achalasia.

Abbreviations

ASGE	American Society of Gastrointestinal Endoscopy
ASA	American Society of Anesthesiology
BMI	body mass index
EGD	esophagogastroduodenoscopy
LES	lower esophageal sphincter
NPO	nil per os
POD	postoperative day
POEM	peroral endoscopic myotomy
PPI	proton pump inhibitor

Introduction

Achalasia is the most common primary esophageal motility disorder, characterized by aperistalsis of the esophageal body and incomplete relaxation of the lower esophageal sphincter (LES). Given the relatively low efficacy of pharmacological

therapies, serial endoscopic pneumatic balloon dilations and Heller myotomy have been regarded as the most durable treatment options because they aim to permanently disrupt the LES to facilitate the passage of ingested food [1–2]. A novel endoscopic technique for the treatment of achalasia was initially described by Parsricha et al. in a porcine model [3]. Inoue and colleagues in 2010 translated this technique into clinical practice and coined the term peroral endoscopic myotomy (POEM) [4]. Since then, there have been multiple studies demonstrating the excellent short-term safety and efficacy of this endoscopic technique for the treatment of achalasia [5–13].

POEM is a technically complex procedure with potential serious adverse events. To date, POEM procedures are performed primarily in the surgical operating room, traditionally an environment perceived to be more adept at managing potential adverse events associated with this technique (e.g., massive hemorrhage, tension pneumothorax,

License terms



and esophageal perforation). While the transition of POEM into the endoscopy unit would intuitively seem to be the next step for its mainstream adoption for the treatment of achalasia, there is an ongoing need for data on performance parameters and safety of this procedure in the endoscopy suite setting. However, the literature on anesthesia management of POEM has been limited to a single Japanese retrospective case series of 28 patients [14]. Thus, there is an ongoing need for data on the safety of sedation and anesthesia of patients undergoing POEM, particularly in the endoscopy suite setting. In this prospective study, we report our (1) initial experience with anesthesia management and intraprocedural monitoring of patients undergoing POEM (2), and the feasibility and (3) efficacy of POEM for the treatment of achalasia when performed in an endoscopy unit.

Methods



Patient population

This single-center prospective study was approved by the Institutional Review Board at the University of Florida (trial number: NCT01832779, <http://www.clinicaltrials.gov>). All patients 18 years and older with a diagnosis of achalasia and symptoms with an Eckardt score > 3 [15] who were able to provide informed consent were included. All patients signed procedure and research informed consent. We excluded patients with esophageal/gastric varices, active gastrointestinal malignancy, pregnancy, those unable to provide informed consent, and those considered unfit for general anesthesia or esophagogastroduodenoscopy (EGD). Prior interventions such as Heller myotomy, pneumatic dilation, botulinum toxin injections, or previous gastric surgeries (e.g., Roux-en-Y gastric bypass, sleeve gastrectomy) were not considered contraindications.

To establish a diagnosis of achalasia and to rule out secondary causes, patients underwent a comprehensive preoperative evaluation, which included symptom assessment (based on the Eckardt and dysphagia scoring systems), high resolution manometry, EGD, and esophagram [16, 17].

Preparation for POEM

Patients were maintained on a clear liquid diet for 48 hours prior to the procedure. A longer course of clear liquids (3–5 days) was recommended for patients whose available preprocedural EGD revealed significant food retention in the esophagus. Patients were kept nil per os (NPO) after midnight on the day of the procedure. Prophylactic intravenous antibiotics (ampicillin/sulbactam or ciprofloxacin for those with penicillin allergy) and proton pump inhibitor (PPI) therapy (Protonix; 40 mg IV, twice daily) were initiated on the day of the procedure and continued during the postoperative hospitalization (usually 2–3 days). Periprocedural anticoagulation and/or antiplatelet therapy was managed according to the current American Society of Gastrointestinal Endoscopy (ASGE) guidelines [18].

Anesthesia management and intraprocedural monitoring for POEM

In our institution's endoscopy unit, we have a University-based anesthesia care team, consisting of an anesthesia attending MD in a supervisory role over anesthesia residents, a certified registered nurse anesthetist, or certified anesthesia assistants. All POEM procedures were performed by a dedicated team comprising the endoscopist, one endoscopic nurse and technician, and

the anesthesia care team (single anesthesia attending MD supervising one anesthesia resident, certified registered nurse anesthetist, or certified anesthesia assistant).

All procedures were performed under general anesthesia with endotracheal intubation and positive pressure ventilation to reduce the risk of capnomediastinum. Anesthesia was induced by rapid sequence technique, where cricoid pressure was applied from the instant of loss of eyelid reflexes until confirmation of correct endotracheal tube placement. The induction sequence was propofol (1–2 mg/kg) followed by a muscle relaxant, either succinylcholine (1–2 mg/kg) or rocuronium (1 mg/kg). Anesthesia was maintained primarily with propofol infusion (dosage range 50–300 $\mu\text{g}/\text{kg}/\text{min}$), with the addition of inhaled sevoflurane left to the individual preference of the anesthetist. When used, sevoflurane was in a dose of 0.5–2 minimum alveolar concentration as necessary to provide additional anesthetic depth and smooth hemodynamics. Constant neuromuscular relaxation was considered critical and was maintained by bolus doses of rocuronium. Mechanical ventilation was provided during the period of neuromuscular relaxation, with a strong preference for pressure control mode over volume control mode. Intraprocedural monitoring included noninvasive blood pressure measurement, electrocardiography, pulse oximetry, end-tidal CO_2 ($E_T\text{CO}_2$) measurement, and train-of-four twitch monitor. Arterial line was not placed in any of the patients. The capnogram was closely monitored for all patients and increases in $E_T\text{CO}_2$ were countered by appropriate increases in the minute ventilation to maintain $E_T\text{CO}_2$ under 45 mmHg. Peak airway pressures were monitored and elevations were regarded as a potential marker for increased intra-abdominal pressure, first managed by decompressing the stomach by suctioning excess CO_2 . Delivered tidal volume was monitored closely in conjunction with $E_T\text{CO}_2$, not only as an indicator of "light anesthesia" (insufficient depth or an undesired level of neuromuscular relaxation) but also as an early indicator of capnothorax. All patients were positioned supine allowing periodic assessment of the upper abdomen for increasing distension due to capnoperitoneum and to prevent abdominal compartment syndrome.

POEM procedure

All procedures were performed in our endoscopy unit in a room that is typically used for advanced endoscopy patients, such as endoscopic retrograde cholangiopancreatography and endoscopic ultrasound. A high definition endoscope with incorporated water jet function (GIFH190, Olympus, America, Center Valley, Pennsylvania, United States) fitted with a transparent distal cap attachment (D20110704; Olympus, America) was used for all patients. For the first three patients, we used the triangle-tip knife (KD640L; Olympus America) for mucosal entry incision, dissection in the submucosal plane, and myotomy. From successive patients 4 to 52, we opted for the Hybrid knife (ERBE USA, Marietta, Georgia, United States), because this knife permits saline injection without needing to exchange the device. Carbon dioxide (CO_2) insufflation was used for all patients. A Coagrasper (FD410-R; Olympus, America) was used for preemptive coagulation of large vessels or hemostasis when needed. The electrosurgical generator VIO 300D (ERBE USA) was used. Last, standard endoscopic clips (Resolution Clip, Boston Scientific, Natick, Massachusetts, United States and Instinct Clip, Cook Medical, Winston-Salem, North Carolina, United States) were used for mucosal closure. The POEM procedure was performed as previously described [4, 19] with the steps summarized below.

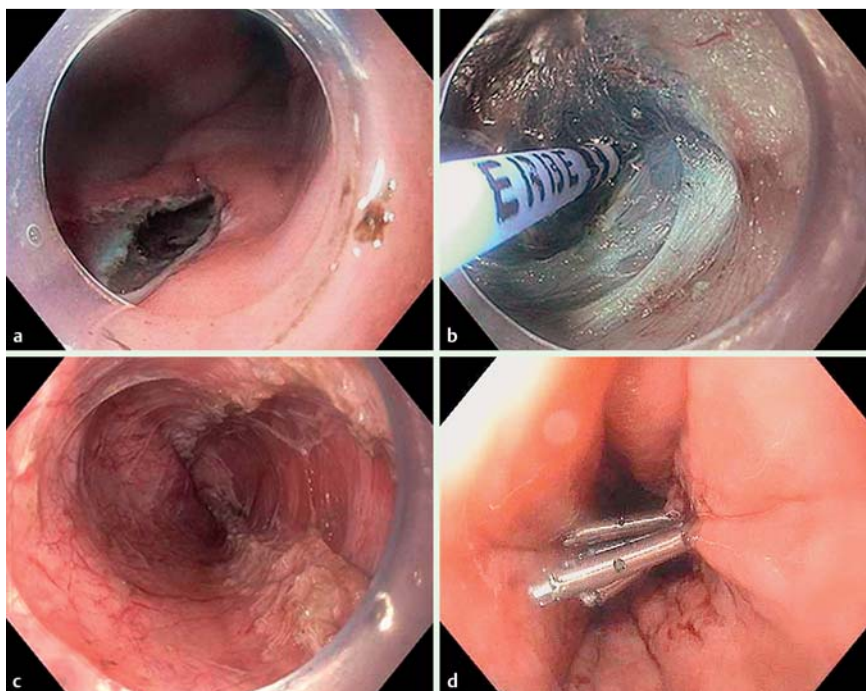


Fig. 1 Peroral endoscopic myotomy. **a** Mucosal incision in the mid-esophagus. **b** Repeated injections of dyed saline solution helps delineate the tissue in the submucosal tunnel. **c** Endoscopic view of the completed myotomy. **d** Mucosal incision closure with endoscopic clips.

1. **Mucosal Entry.** Any fluid or residual food was suctioned and removed from the esophageal/gastric lumen. The site for mucosal entry was chosen at the two o'clock position on the right anterolateral esophagus, approximately 14 cm to 15 cm above the LES. After injecting 8 mL of normal saline solution admixed with indigo carmine to create a submucosal lift, a 10 mm to 15 mm longitudinal mucosal incision was performed with the electrocautery knife until exposure of the submucosal space (● Fig. 1 a).
2. **Submucosal Tunneling.** The tip of the endoscope was maneuvered through the mucosal entry site and subsequently inserted into the newly created submucosal space. Submucosal dissection was achieved by using the electrocautery knife with repeated dyed saline injections (● Fig. 1 b). The submucosal tunnel was extended at least 3 cm caudal from the LES into the gastric cardia. This was established by the anatomical landmark changes consistent with the transition from the esophagus into the stomach [20] and confirmed by inspection of the proximal stomach after withdrawing the EGD from the tunnel and advancing it into the gastric lumen.
3. **Myotomy.** Selective myotomy of the circular muscle fibers with the electrocautery knife was initiated 2–3 cm distal to the mucosal entry site, proceeding proximal to distal while maintaining the underlying longitudinal fibers intact when possible (● Fig. 1 c). The myotomy was continued 2–3 cm past the LES into the gastric cardia.
4. **Closure of Mucosal Entry.** Closure of the mucosal entry incision was generally achieved with the placement of standard endoscopic clips (● Fig. 1 d). Over-the-scope clips (Ovesco Endoscopy AG, Tubingen, Germany) and/or fully covered esophageal stents were used where the mucosa incision edges could not be apposed adequately with standard clips.

Post-POEM management

All patients were hospitalized and kept NPO the night after the procedure and continued on intravenous antibiotics and PPI therapy. Postprocedure chest radiograph, Gastrografin esopha-

gram or chest computed tomography with water-soluble oral contrast were routinely obtained on postoperative day one (POD#1) to ensure the absence of leakage. In the absence of contraindications, a soft pureed diet was initiated and maintained for 14 days prior to gradual advancement as tolerated. Postoperative instructions included supervised incentive spirometry every 2 hours while awake to prevent atelectasis. Antibiotics were discontinued by discharge and PPI converted to oral therapy and continued for two weeks. Patients were seen in clinic 4 weeks following their procedure.

Outcome measures

The aim of this study was to evaluate the safety, feasibility, and efficacy of POEM for the treatment of achalasia when performed by a dedicated anesthesia and endoscopy team in the endoscopy unit. Safety was determined by endoscopic adverse events based on previously established criteria by the ASGE [21]. Feasibility was determined by the rate of completion of the POEM procedure as described above. Perioperative measures, including total procedure time, postoperative esophagram, time to resume oral diet, and duration of hospital stay were all recorded. Efficacy was evaluated by the short-term clinical success (defined as an Eckardt score ≤ 3 following the procedure) and by comparing the Eckardt [16] and dysphagia [17] scores before and after POEM at one-month follow-up visit.

Statistical analysis

Summary data was expressed as mean, standard deviation, median, and range. The continuous data between preprocedural and post-POEM at 1 month follow up were compared using Student's *t*-test for paired samples. Nominal *P* values were reported; *P* values less than 0.05 were considered statistically significant (GraphPad Prism version 6.00 for Windows, GraphPad Software, San Diego, California, United States).

Results

Patient characteristics

From February 2013 to October 2014, 52 patients with achalasia (men, 48.1%; median age, 55 years) underwent POEM in our institution. All procedures were performed by a single advanced endoscopist (P. V. D.) in our endoscopy unit with the assistance of a nurse, technician, and a dedicated anesthesia team. These represented the first POEM procedures performed in our institution. Patient characteristics are summarized in **Table 1**. Most patients endorsed longstanding symptoms (median, 36 months), with median preoperative Eckardt and dysphagia scores of 8 and 3, respectively. Most patients (34/52; 65.4%) had achalasia subtype II based on HRM; the other patients had achalasia subtype I (9/52; 17.3%) and subtype III (9/32; 17.3%). Four patients (5.8%) had previously undergone surgical myotomy, whereas some patients had received botulinum toxin injection (10/52; 19.2%) or pneumatic balloon dilation (6/52; 11.5%) prior to POEM. Other previous surgical procedures are summarized in **Table 1**.

Periprocedural outcomes

All procedures were done under general anesthesia with endotracheal intubation and positive pressure ventilation. No regurgitation or aspiration into the trachea was observed during anesthesia induction. Peak airway pressures were monitored and maintained under 38 cm H₂O. In most instances, rising peak airway pressures were managed by promptly withdrawing the endoscope from the tunnel and advancing it into the gastric lumen to decompress the stomach by suctioning excess CO₂. In most patients (46/52; 88.5%), E_tCO₂ was maintained within a normal physiologic range (30–40 mmHg), corresponding to a PaCO₂ range of 35–45 mmHg. In five patients, rising E_tCO₂ (range, 50–64 mmHg) was associated with elevations of peak airway pressures (range, 36–55 cm H₂O). In one patient, peak airway pressure did not increase above intraoperative baseline of 25 cm H₂O when the E_tCO₂ peaked at 64 mmHg. In all of these six patients (6/52; 11.5%), increases in intra-abdominal pressure was treated by placement of a Veress needle for intraoperative abdominal decompression. Vital signs remained stable in all of the patients who underwent intraoperative abdominal decompression. All patients were successfully extubated in the operating room except one patient with oxygen-dependent chronic obstructive pulmonary disease. This patient was monitored postoperatively and subsequently extubated 6 hours later on that same day. No postprocedure bleeding occurred in any of the patients, and any intraprocedural bleeding was promptly controlled with the electrocautery knife and/or Coagrasper. No blood transfusions were given.

POEM was successfully completed in 50 of 52 patients (96.2%) with achalasia (**Table 2**). POEM could not be completed in two patients due to severe fibrotic changes in the submucosa, impeding adequate separation of tissue planes for safe submucosal tunneling. The procedure was aborted and these patients were scheduled for pneumatic dilation. Overall, the mean procedural time was 90.6 min (range, 32–215 min). The mean length of the esophageal and stomach myotomies were 10.3 cm (range, 6–14 cm) and 3.1 cm (range, 2–4 cm) respectively, with mean total myotomy length of 13.4 cm (range, 6–17 cm).

Perforation occurred in four patients (7.7%). In two patients, small mucosal perforations occurred during submucosal tunneling and endoscopic closure was achieved with one endoclip and one over-the-scope clip, respectively. In one patient, the mucosal

Table 1 Patient baseline characteristics (n = 52).

Characteristics	Values
Age, median (range); years	55 (20–83)
Sex, women : men	27 : 25
BMI, median (range); kg/m ²	27.8 (11.5–42.5)
Duration of symptoms, median (range); months	36 (4–360)
Previous intervention; n (%)	
<i>Botulinum toxin injection</i>	10 (19.2)
<i>Pneumatic balloon dilation</i>	6 (11.5)
<i>Surgical myotomy</i>	4 (5.8)
<i>Sleeve gastrectomy</i>	1 (1.9)
<i>Roux-en-Y gastric bypass</i>	1 (1.9)
<i>Pyloroplasty</i>	1 (1.9)
Basal LES, median (range); mmHg	39.8 (7.3–167.6)
Residual LES, median (range); mmHg	24.5 (6.8–54.9)
Preoperative Eckardt Score, median (range)	8 (3–12)
Preoperative Dysphagia Score, median (range)	3 (0–4)
Achalasia subtype; n (%)	
<i>Type I</i>	9 (17.3)
<i>Type II</i>	34 (65.4)
<i>Type III</i>	9 (17.3)

Abbreviations: BMI, body mass index; LES, lower esophageal sphincter.

Table 2 POEM procedural and immediate post-operative parameters (n = 52).

Parameters	Values
Total procedure time, mean (range); min	90.6 (32–214)
Myotomy length, mean (range); cm	
<i>Esophagus</i>	10.3 (6–14)
<i>Stomach</i>	3.1 (2–4)
<i>Total</i>	13.4 (6–17)
POEM Completion; n (%)	50 (96.2)
Adverse Events; n (%)	
<i>Pneumonia on post-operative day #3</i>	2 (3.8)
<i>Full-thickness mucosal injury</i>	3 (5.8)
<i>Full thickness mucosal injury secondary to overtube</i>	1 (1.9)
Leak on postoperative day #1 esophagram, n (%)	1 (1.9)
Time to oral diet resumption post-POEM, mean (range); days	1 (2–6)
Hospital stay, mean (range); days	3.5 (2–10)

Abbreviations: POEM, peroral endoscopic myotomy; n, number.

perforation was not seen on index POEM but was later identified on POD#1 esophagram. This was managed with laparoscopic repair with intraoperative endoluminal stent placement. Repeat EGD with stent removal four weeks later showed mucosal healing without leakage on esophagram. In one patient, esophageal perforation occurred secondary to trauma from overtube placement and this was closed successfully with a combination of endoscopic clipping, suturing, and placement of a fully covered esophageal stent. There was no evidence of leakage on esophagram following stent removal at 6 weeks. In the remaining patients (48/52; 92.3%), there was no evidence of leakage on POD#1 esophagram. None of the patients with findings of capnomediastinum, capnoperitoneum, cervical emphysema, or combination on chest imaging on POD#1 required any specific intervention. Two patients were diagnosed with pneumonia based on cough, fever, and new infiltrate on chest radiograph on POD#3. They were discharged on a seven day course of antibiotics and did well. Most patients (50/52; 96.1%) resumed diet on POD#2 after the procedure (median, 2; range, 2–6 days) and mean hospital stay was 3.5 days (range, 2–10 days).

Post-POEM clinical outcomes at 1-month follow up

Forty-four of 52 patients who underwent POEM in our institution had 1-month follow up. Clinical success (Eckardt score, ≤ 3) was achieved in most of the patients at 1-month follow up (40/44, 90.9%). Clinical success rate was 100% (9/9) for patients with achalasia type I, and 92.6% (25/27) and 75% (6/8) for patients with achalasia type II and III; respectively. POEM was successful in most patients (13/15; 86.7%) who had undergone previous interventions for their achalasia. Forty-two patients (42/44; 95.5%) reported improvement of dysphagia with reduction in their dysphagia scores, including the four patients with an Eckardt score > 3 . In all, there was much improvement in the mean Eckardt score (7.6 to 1.1; $P < 0.0001$) and dysphagia scores (2.2 to 0.3; $P < 0.0001$) at 1-month follow up after POEM (● Fig. 2).

Discussion

Experience with POEM for the management of achalasia performed exclusively in the endoscopy suite is limited, particularly in the United States [22–24]. In this prospective single-center study, we demonstrated that endoscopic clearance of esophageal contents prior to anesthesia induction was not necessary to prevent aspiration, anesthesia management of POEM in the endoscopic unit is safe, and that POEM was both feasible and effective for the management of symptomatic achalasia.

The literature on anesthesia management of POEM is limited. Recently, Tanaka and colleagues reported their experience with anesthesia management of POEM for esophageal achalasia [14]. In their retrospective case series, all patients underwent EGD within a few hours prior to anesthesia induction to ensure complete evacuation of esophageal contents and thus prevent aspiration pneumonia during anesthesia induction. There are some potential limitations with this approach, particularly in the West. First, patients in this study were not pre-medicated for this index EGD (performed within hours of the POEM) for esophageal clearance. This appears to be counterintuitive because POEM has been commonly performed with patients under general anesthesia to minimize movement and potentially prevent aspiration of residual esophageal contents. Thus, while an initial endoscopic procedure to clear the esophagus from contents would reduce the risk of subsequent anesthesia management, this index procedure itself may be placing the patients at risk of aspiration even before the POEM. Second, over one-half of the patients in their series had residual contents in the esophagus on their preanesthetic EGD evaluation (37% consisted of solid material). Although not reported, esophageal clearance prior to POEM must have added to the overall operational time and increased the utilization of resources. In our prospective study, all patients were maintained on a clear liquid diet for at least 48 hours and NPO after midnight on the day of the procedure. No regurgitation or aspiration into the trachea was observed during anesthesia induction in any of the patients who underwent POEM in our endoscopy unit. Based on these results, endoscopic clearance of esophageal contents prior to anesthesia induction was not necessary to prevent aspiration, and an adequate and safe “single step” POEM procedure can be performed by maintaining patients on a clear liquid diet days prior to the intervention.

In this study, anesthesia was successfully managed in all patients undergoing POEM in the endoscopy unit. All patients were extubated without any cardiopulmonary adverse events. Peak airway pressures were monitored and maintained under 38 cm H₂O to

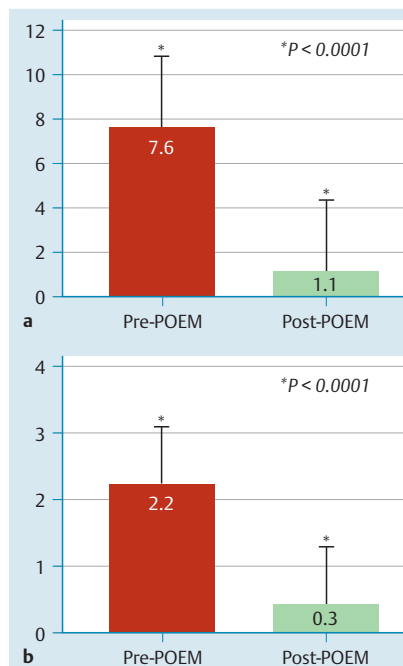


Fig. 2 Symptom scores. **a** Eckardt symptom scores before and after peroral endoscopic myotomy at the 1-month follow up. **b** Dysphagia symptom scores before and after peroral endoscopic myotomy at the 1-month follow up.

reduce the risk of capnoperitoneum. Elevations of peak airway pressures accompanied by abdominal distension were all successfully managed with intra-abdominal decompression with venting, resulting in prompt decrease of the peak airway pressure in all patients. There were no adverse events associated with this intervention. The frequency of intra-abdominal venting in this study was comparable to that previously reported in the literature (8%–9%) [20], and highlights the importance of serial evaluations of the upper abdomen during the procedure.

POEM was successfully completed in 96.2% of the patients. The high completion rate was congruent with those previously reported in the literature (90%–100%) [4–8]. Other performance parameters such as operative time and extent of the myotomy were also comparable to those reported from POEM performed in the operating room [5, 12]. In addition, POEM was successfully completed in all patients with previous endoscopic intervention and in most patients with prior surgical myotomy, which are well recognized as challenging situations [25–27]. Overall, the findings suggest that POEM performed in the endoscopy unit is feasible with a high technical completion rate.

Perforations of the mucosa during POEM have been reported in the range of 0%–7% [20]. Most perforations can be closed endoscopically with a combination of different techniques and rarely require surgical intervention. Nonetheless, it is important to highlight that the successful integration of a POEM program in the endoscopy unit requires the establishment of a knowledgeable multidisciplinary team comprising gastroenterologists, surgeons, anesthesiologists, and trained endoscopy ancillary staff capable of managing all potential serious adverse events associated with this complex procedure.

POEM performed in the endoscopy unit appears to be a highly effective treatment for achalasia, resulting in 88% short-term response rate (Eckardt score, ≤ 3), which is congruent with treatment success (89%–100%) reported in the literature [4–8, 10, 11, 13]. Furthermore, all patients had improvement of their dysphagia symptoms and there was a significant decrease in both the mean Eckardt (8.1 to 1.4) and dysphagia (2.4 to 0.4) scores at the 1-month follow-up period. While these findings are preli-

minary given the brief follow-up period, these outcome measures align with the positive short-term results reported by centers worldwide [20].

Our study has several strengths. First, it is one of largest prospective POEM series performed exclusively by a gastroenterologist in an endoscopy unit reported from the United States. Second, we demonstrated that our anesthesia management of POEM in the endoscopy unit is safe and does not require a prior EGD for esophageal content clearance prior to anesthesia induction. Third, we collected and analyzed important established performance parameters (e.g., completion rate, procedure time, perioperative) and clinical outcome measures (e.g., standardized, validated symptom scores) of POEM in the endoscopy unit that may serve as benchmarks for other endoscopic centers. Furthermore, in contrast to other institutions in which POEM was initially performed in the operating room and honed prior to its transition into the endoscopy suite [20], our experience with POEM originated in the endoscopy unit and the results of all procedures performed were included in this study. Last, unlike many studies on the safety and efficacy of POEM [5–9], our series encompassed a diverse achalasia patient population (age range, 20–83 years; BMI range, 18–41), some patients with severe medical comorbidities (median ASA score, 3; range, 2–4), some with previous surgeries (e.g., Roux-en-Y gastric bypass, sleeve gastrectomy), and some with prior failed endoscopic/surgical treatment for achalasia. Hence, our initial performance and outcomes data on POEM in the endoscopy unit reflect a broad spectrum rather than a subset of achalasia patients.

We also acknowledge that our study has a few limitations. We reported the outcomes of a relatively small number of patients. Nonetheless, the patients in this study underwent the first 52 procedures performed in our institution and included the steepest part of the learning curve for the POEM operator, nurse, technician, and anesthesia team. Therefore, our experience included the most important and vulnerable time where poor outcomes and high incidence of adverse events would be most likely. However, we observed favorable clinical outcomes with an excellent safety profile when POEM was performed in our endoscopy unit. We acknowledge that our results are from a single POEM endoscopist supported by an experienced team of nurses and anesthesiologists in an environment that is accustomed to treating complex patients with multiple comorbidities. Thus, while our findings may provide a framework for other endoscopy units planning on initiating their own POEM program, there may be few tertiary referral centers with the appropriate multidisciplinary support.

In conclusion, we demonstrated that a POEM program can be successfully implemented in the endoscopy unit of a tertiary referral center. Anesthesia management of POEM was safe in the endoscopy unit and aspiration was prevented without requiring a prior EGD for esophageal content clearance. Overall, POEM performed by a gastroenterologist in the endoscopy unit was feasible and effective for the treatment of achalasia. Prior to initiating a POEM program in the endoscopy unit, the development of a comprehensive multidisciplinary POEM team and infrastructure are important. Future prospective multi-center trials are needed to corroborate our findings and establish long-term performance parameters for anesthesia management and outcomes of POEM in the endoscopy suite environment.

Competing interests: None

Acknowledgments



Yang D and Draganov PV performed the literature search, conception and design, and drafting of the article. All authors were involved in the analysis and interpretation of the data, critical revision, and final approval of the article.

References

- 1 Campos GM, Vittinghoff E, Rabl C et al. Endoscopic and surgical treatments for achalasia: a systematic review and meta-analysis. *Ann Surg* 2009; 249: 45–57
- 2 Boeckxstaens GE, Annese V, des Varannes SB et al. Pneumatic dilation versus laparoscopic Heller's myotomy for idiopathic achalasia. *N Engl J Med* 2011; 364: 1807–1816
- 3 Pasricha PJ, Hawari R, Ahmed I et al. Submucosal endoscopic esophageal myotomy: a novel experimental approach for the treatment of achalasia. *Endoscopy* 2007; 39: 761–764
- 4 Inoue H, Minami H, Kobayashi Y et al. Peroral endoscopic myotomy (POEM) for esophageal achalasia. *Endoscopy* 2010; 42: 265–271
- 5 Swanström LL, Rider E, Dunst CM. A stepwise approach and early clinical experience in peroral endoscopic myotomy for the treatment of achalasia and esophageal motility disorders. *J Am Coll Surg* 2011; 213: 751–756
- 6 Von Renteln D, Inoue H, Minami H et al. Peroral endoscopic myotomy for the treatment of achalasia: a prospective single center study. *Am J Gastroenterol* 2012; 107: 411–417
- 7 Costamagna G, Marchese M, Familiari P et al. Peroral endoscopic myotomy (POEM) for oesophageal achalasia: preliminary results in humans. *Dig Disease Liv* 2012; 44: 827–832
- 8 Chiu PW, Wu JC, Teoh AY et al. Peroral endoscopic myotomy for treatment of achalasia: from bench to bedside (with video). *Gastrointest Endosc* 2013; 77: 29–38
- 9 Verlaan T, Rohof WO, Bredenoord AJ et al. Effect of peroral endoscopic myotomy on esophagogastric junction physiology in patients with achalasia. *Gastrointest Endosc* 2013; 78: 39–44
- 10 Lee BH, Shim KY, Hong SJ et al. Peroral endoscopic myotomy for treatment of achalasia: initial results of a Korean study. *Clin Endosc* 2013; 46: 161–167
- 11 Minami H, Isomoto H, Yamaguchi N et al. Peroral endoscopic myotomy for esophageal achalasia: clinical impact of 28 cases. *Dig Endosc* 2014; 26: 43–51
- 12 Hungness ES, Teitelbaum EN, Santos BF et al. Comparison of perioperative outcomes between peroral esophageal myotomy (POEM) and laparoscopic Heller myotomy. *J Gastrointest Surg* 2013; 17: 228–235
- 13 Von Renteln D, Fuchs KH, Fockens P. Peroral endoscopic myotomy for the treatment of achalasia: an international prospective multicenter study. *Gastroenterology* 2013; 145: 309–311
- 14 Tanaka E, Murata H, Minami H et al. Anesthetic management of peroral endoscopic myotomy for esophageal achalasia: a retrospective case series. *J Anesth* 2014; 28: 456–459
- 15 Eckardt VF, Aigherr C, Bernhard G. Predictors of outcome in patients with achalasia treated by pneumatic dilation. *Gastroenterology* 1992; 103: 1732–1738
- 16 Pandolfino JE, Kwiatek MA, Nealis T et al. Achalasia: a new clinically relevant classification by high-resolution manometry. *Gastroenterology* 2008; 135: 1525–1533
- 17 Mellow MH, Pinkas H. Endoscopic laser therapy for malignancies affecting the esophagus and gastroesophageal junction: analysis of technical and functional efficacy. *Arch Intern Med* 1985; 145: 1443–1446
- 18 Eisen GM, Baron TH, Dominitz JA et al. Guideline on the management of anticoagulation and antiplatelet therapy for endoscopic procedures. *Gastrointest Endosc* 2002; 55: 775–779
- 19 Yang D, Wagh MS. Peroral endoscopic myotomy for the treatment of achalasia: an analysis. *Diagn Ther Endosc* 2013; 2013: 389596
- 20 Stavropoulos SN, Modavil RJ, Friedel D et al. The International Per Oral Endoscopic Myotomy Survey (IPOEMS): a snapshot of the global POEM experience. *Surg Endosc* 2013; 27: 3322–3338
- 21 Cotton PB, Eisen GM, Aabakken L et al. A lexicon for endoscopic adverse events: report of an ASGE workshop. *Gastrointest Endosc* 2010; 71: 446–454
- 22 Friedel D, Modavil R, Iqbal S et al. Per-oral endoscopic myotomy for achalasia: an American perspective. *World J Gastrointest Endosc* 2013; 5: 420–427

- 23 *Khashab MA*. Thoughts on starting a peroral endoscopic myotomy program. *Gastrointest Endosc* 2013; 77: 109–110
- 24 *Khashab MA, Azola A, Saxena PA* et al. Can gastroenterologists perform POEM safely and effectively in the endoscopy suite without a surgeon? *Gastrointest Endosc* 2014; 79: AB166–AB167
- 25 *Zhou PH, Li QL, Yao LQ* et al. Peroral endoscopic remyotomy for failed Heller myotomy: a prospective single-center study. *Endoscopy* 2013; 45: 161–166
- 26 *Onimaru M, Inoue H, Ikeda H* et al. Peroral endoscopic myotomy is a viable option for failed surgical esophagocardiomyotomy instead of redo surgical Heller myotomy: a single center prospective study. *J Am Coll Surg* 2013; 217: 598–605
- 27 *Vigneswaran Y, Yetasook AK, Zhao JC* et al. Peroral endoscopic myotomy (POEM): feasible as reoperation following Heller myotomy. *J Gastrointest Surg* 2014; 18: 1071–1076
- 28 *Bredenoord AJ, Rösch T, Fockens P*. Peroral endoscopic myotomy for achalasia. *Neurogastroenterol Motil* 2014; 26: 3–12