



REVIEW

# Exploring the Role of the Cerebellum in Pain Perception: A Narrative Review

Orita Manda · Marios Hadjivassiliou · Giustino Varrassi · Periklis Zavridis ·

Panagiotis Zis 

Received: January 21, 2025 / Accepted: March 5, 2025 / Published online: March 17, 2025  
© The Author(s) 2025

## ABSTRACT

This systematic review aims to reassess the expanding role of the cerebellum in pain perception, challenging its traditional and simplistic association with the motor domain. Pain perception is a complex experience shaped by sensory, emotional, and cognitive factors, with recent findings underlining the cerebellum's influence over these systems. This paper

evaluates findings from 24 relevant studies to elucidate key findings with regard to pain and their potential clinical applications. The cerebellum's role in pain processing is assessed through its interaction with nociceptive pathways, pain anticipation, and the intonation of pain-related emotional responses. Key cerebellar regions such as Crus I, lobules VI and VIII, and the vermis, are persistently activated during pain perception and anticipation. These regions are linked to sensory-discriminative and affective-motivational elements of pain. Studies on patients with migraines, chronic low back pain, and irritable bowel syndrome (IBS) demonstrated increased cerebellar activation, suggesting its role in chronic pain conditions. Non-invasive neurostimulation techniques, such as transcranial direct current stimulation (tDCS) and repetitive transcranial magnetic stimulation (rTMS), administered onto these cerebellar regions, show potential in modulation of pain and clinical application. Future research should aim to standardise methodologies, explore the cerebellum's role in acute pain, and investigate long-term effects of cerebellar-targeted treatments. Understanding the cerebellum's multifaceted role in pain perception can advance diagnostic and therapeutic strategies, offering a more comprehensive approach to pain management. This review underscores the need for further investigation into cerebellar mechanisms and their

---

O. Manda · M. Hadjivassiliou · P. Zis (✉)  
Sheffield Institute for Translational Neuroscience,  
University of Sheffield, Sheffield, UK  
e-mail: takiszis@gmail.com

O. Manda  
e-mail: oritamanda@gmail.com

M. Hadjivassiliou  
e-mail: m.hadjivassiliou@sheffield.ac.uk

G. Varrassi  
Fondazione Paolo Procacci, Rome, Italy  
e-mail: giuvarr@gmail.com

P. Zavridis  
Medical School, European University of Cyprus,  
Nicosia, Cyprus  
e-mail: pzavridis@painclinic.com.cy

P. Zavridis  
Cyprus Pain Clinic, Egkomi, 2415 Nicosia, Cyprus

P. Zis  
Medical School, University of Cyprus, Nicosia,  
Cyprus

clinical applications, potentially transforming pain treatment paradigms.

**Keywords:** Nociception; Cerebellum; Pain perception

### Key Points

The cerebellum plays a significant role in pain processing, particularly in inhibiting pain sensation, with regions like Crus I, Crus II, and lobule VI involved in pain anticipation, perception, and emotional aspects.

Activation in lobules I–VI, VIII, and the vermis has been linked to nociceptive signalling, fear conditioning, and sensory integration.

Studies also highlight cerebellar involvement in conditions such as chronic pain, IBS, and migraines, with specific regions showing altered activation patterns.

The cerebellum has multimodal role in integrating pain, motor responses, and emotional processing.

## INTRODUCTION

Pain is classified as an uncomfortable sensory and emotional phenomenon. Despite being classically described as a sensory experience, it has been increasingly recognised that psychological and social factors also play a role in influencing the overall experience of pain for each individual [22]. Over the past 100 years, there has been increasing discussion of an emotional involvement in pain perception [35]. Additionally, the past decade, especially, has provided significant advancements in investigating the link between pain and emotion, through the use of animal studies and brain imaging techniques [32]. Recent studies are still trying to uncover all neural areas involved in pain perception. While there are symptom-managing treatment plans in place for these conditions, there are still gaps in the literature in

understanding all modulating areas within the brain which contribute to pain perception.

The cerebellum is conventionally known as the area for motor control responsible for coordinating voluntary movements. However, the cerebellum is now additionally recognised as a core aspect in an integrated network that relays motor, cognitive, sensory, affective and social functions [49]. This shift in perspective did not occur until the late twentieth century, where nonmotor functions of the cerebellum had started to be investigated, speculating that the structure played a part in higher order functions [52]. Various studies using hypothesis-driven experiments and novel concepts further questioned the traditional theory [37, 52], which inevitably led to the reassessment of the role of the cerebellum [11]. Since then, the cerebellum's role has further expanded from motor control to functions such as emotional learning and fear conditioning, via its interconnections with the prefrontal cortex, amygdala and other brain areas [49].

The current review aims to investigate the role of the cerebellum in pain perception, what are the future implications of these findings, and, furthermore, how these findings can translate into clinical use.

## METHODS

A single-database search was conducted. All literature was retrieved from PubMed by one reviewer. PubMed database searching was conducted in May 2024. During the literature search, three main terms were used to identify relevant papers: (1) cerebellum/cerebellar, (2) pain/painful, and (3) nociception/nociceptive. Synonyms of each phrase were included in order to produce the most efficient yield when identifying relevant papers for screening. No publication date restrictions were put on the search criteria.

### Inclusion and Exclusion Criteria

Articles were included based on the following criteria:

- The study discussed the potential role of the cerebellum in pain perception.

- The study subjects were a human population.
- The study was in English.
- The study had a sample size larger than 10 participants.

Articles were excluded based on the following criteria:

- Unoriginal studies (i.e. review studies, case reports).
- The study used pediatric populations.

### Data Collection Process

Two authors were responsible for screening of search results. Data extraction was then performed. Relevant data were collected and assembled into data extraction tables. These summarised the included main details of the study, i.e. generalised study design, participant details, geographical location, key results and conclusions.

### Critical Appraisal

All randomised controlled trials (RCTs) included in this review were critically appraised using the Jadad Score, which is used to assess the risk of bias present within pain research studies. The scale allows for a score from 0 (very poor) to the maximum 5 (excellent). This enables parallel comparisons to be drawn between the quality of differing RCTs available [33].

### Compliance with Ethical Guidelines

This article is based on previously conducted studies and does not contain any new studies with human participants or animals performed by any of the authors.

## RESULTS

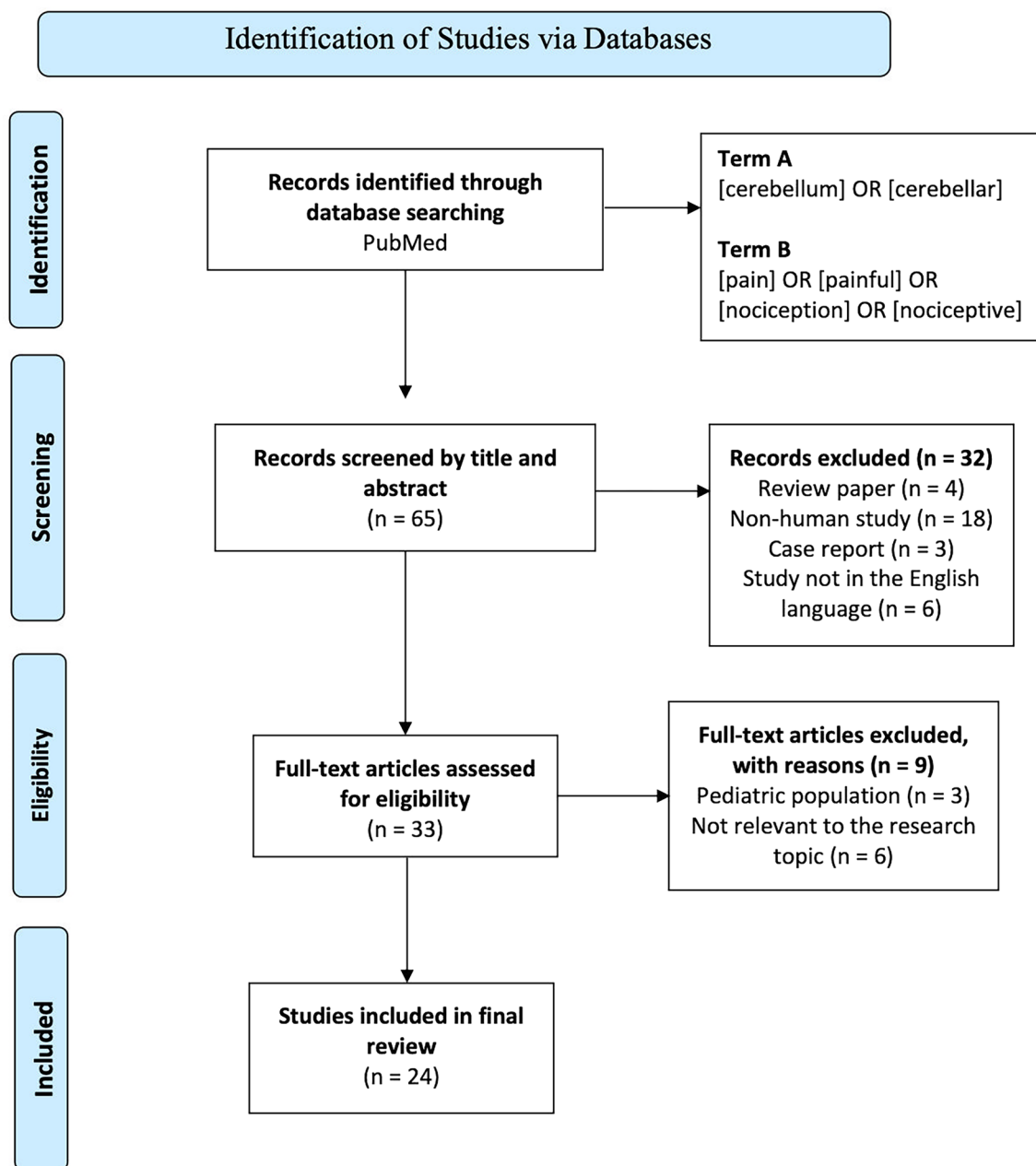
The research question yielded a total of 65 results on PubMed. A total of 24 studies were included in the final review. Details of the screening process have been summarised in the

flow diagram (Fig. 1). Table 1 highlights the various cerebellar regions and their associated functions in the processing and modulation of pain.

### Cerebellar Networks

The cerebellum is predominantly known for its involvement in motor control, functioning to regulate balance and coordination of movement. However, the role of the cerebellum was not always widely understood. Prior to the eighteenth century, theories of cerebellar function were predominantly made through the observation of gross anatomy, as well as conceptual speculations [23]. Today, it is widely understood that the cerebellum constitutes one of the most significant circuits present within the human brain. This circuit accounts for motor control, but increasing research shows this to be vastly more complex than originally thought [47]. Ataxia (loss of co-ordination) is largely associated with cerebellar dysfunction, with visible atrophy of the cerebellum often observed in these neurological conditions [17]. However, the cerebellum is increasingly proven to have functions other than motor control through recent findings from imaging, behavioural and anatomical research.

Functional connectivity during pain processing was analysed using a mechanical punctuate stimulus on 12 healthy subjects [19]. Following a pinprick stimulus to the back of the hand, MRI identified three clusters: (1) vermis IV–V and hemispheres IV–VI, (2) hemisphere VI and Crus 1 and Crus 2, and (3) lobule VIIb and Crus 1 and Crus 2. Additional to these findings, previous literature has also highlighted activation of these cerebellar regions during the use of heat stimuli in a study with neuropathic patients and healthy subjects. The application of heat triggered activation in Crus II and VIIb in healthy patients, regions which are thought to be associated with socializing and cognitive processing [59]. However, in neuropathic patients, heat produced activation regions in lobules III–V, lobule VI and VIIIa [10]. Painful electrical stimuli delivered to the dermatomes of the three trigeminal branches (V1, V2, V3) and the greater occipital nerve triggered high



**Fig. 1** PRISMA diagram detailing the screening processes

activation areas in Crus I, lobule I–IV, V and VI in the hemispheres and also the vermis [4]. The findings of this study suggest that there is a high level of cerebellar activation during trigemino-cervical pain processing, thus largely highlighting the significant influence of V1 on the somatotopy present within the cerebellum, which could be underlining the significant role

of this specific branch in headache pathologies. The trigeminal nerve has long been recognised as the ‘common denominator’ in headache disorders [21], indicative that this dominant connectivity between the V1 trigeminal branch and cerebellar somatotopy could be an underlying factor of this pathology. It should be noted that electrical stimulation is susceptible

**Table 1** Summary of cerebellar regions and their key functions in pain processing

Cerebellar region	Associated role in pain processing	References
Crus I	Pain anticipation, pain perception, emotional aspects of pain, painful stimuli processing, sensory disturbances in migraine	[4, 15, 19, 26, 36, 47, 51]
Crus II	Pain anticipation, pain perception, emotional aspects of pain, painful stimuli processing, sensory disturbances in migraine	[4, 15, 19, 26, 36, 47, 51]
Lobule I	Painful stimuli processing	[16]
Lobule II	Painful stimuli processing	[16]
Lobule III	Painful stimuli processing	[16]
Lobule IV	Painful stimuli processing	[16]
Lobule V	Increased activation during the sudden exclusion of a previously experienced negative stimulus	[47]
Lobule VI	Pain anticipation, pain perception, emotional aspects of pain, fear conditioning, painful stimuli processing (trigeminal)	[4, 10, 19, 20, 34, 36, 41]
Lobule VIIb	Painful stimuli processing	[16]
Lobule VIIa	Painful stimuli processing (trigeminal)	[4, 34]
Lobule VIIb	Pain-related fear conditioning, pain and motor processing	[15, 16]
Lobule IX	Increased activation during the sudden exclusion of a previously experienced negative stimulus	[47]
Anterior Vermis (Lobule VI and VIII)	Painful stimuli processing	[4, 20]
Posterior Vermis (Lobules VIIb–IX)	Increased activation during sudden exclusion of a previously experienced negative stimulus	[47]
Vermis	Fear conditioning, nociceptive reflex signalling, sensory signal integration	[4, 15, 19, 20]

to non-nociceptive somatosensory influence as well as nociceptive influence alone.

In those who had spinal manipulation before having their cerebellar inhibition (CBI) remeasured, findings revealed there to be a significantly lower CBI level in the spinal manipulation groups compared to healthy control (HC) group. It was observed that the more extreme the neck pain in the patient, spinal manipulation subjects had a larger change in CBI, measured using motor evoked potentials

[3]. CBI levels were also found to decrease following hand stimulation in a healthy population, as well as an increased vibration perception threshold. These findings are indicative that the cerebellum exerts modulatory effects in processing vibrotactile stimuli via motor–sensory interactions [14]. Similar to the previous paper, this study aimed to evaluate whether spinal manipulation prior to motor sequence learning would help restore the baseline functional relationship between the cerebellum and the motor cortex in

individuals with subclinical neck pain (SCNP). Following transcranial magnetic stimulation (TMS) before and after a combination of spinal manipulation and motor sequence learning, a significant decrease in mean reaction time was observed, as well as a lowered CBI [18]. Similar to the findings of Baarbé et al. [3], the results indicate that individuals with SCNP have modified CBI compared to healthy individuals. Non-invasive brain stimulation techniques such as transcranial direct current stimulation (tDCS) and repetitive transcranial magnetic stimulation (rTMS) have successfully modulated CBI in previous literature; however, the results have shown inconsistencies when considering the magnitude and direction of effects for these techniques [55].

Differences in sensorimotor white matter microstructure between those with non-specific low back pain (NSLBP) and healthy subjects were investigated by [44]. Patients with NSLBP showed a reduced fractional anisotropy in the left superior cerebellar peduncle compared to HC, suggestive of impaired microstructural integrity. Interestingly, decreased integrity of the white matter fibres of the superior cerebellar peduncle showed a correlation with an increased dependency of proprioception within the ankle muscles. As the cerebellar peduncles carry all the fibres which transport information out of the cerebellum, decreased integrity of these structures are likely the cause of impaired processing of sensory signals [44].

### Activity of the Cerebellum During Painful Stimuli

Domains such as vestibular, cognitive, emotional and autonomic function are areas where research has uncovered evidence of cerebellar influence. Cerebellar activation has been demonstrated in the presence of unpleasant or painful stimuli in varying areas. Lobules Crus I and VI of both hemispheres as well as lobules I–V of the anterior vermis, and lobules VIIb–IX of the posterior vermis have all shown increased activation during the sudden exclusion of a previously experienced negative stimulus [47].

Using magnetic resonance imaging (MRI) during nociceptive and trigeminal stimulation, it was found that an increased activation was present in Crus I, VIIIa, VI and Vermis VIIIa. An ‘intense’ gaseous ammonia stimulus revealed four clusters in the cerebellum and the periaqueductal gray (PAG).

These findings show increased levels of cerebellar-cortical communication, as well as between brainstem nuclei and left lobules I–VI during trigeminal nociception. The circuitry between the cerebellum and the brainstem include structures such as the thalamus and PAG. The latter is largely associated with being a core centre of the descending pain processing pathway, correlated with the propagation and suppression of pain perception through inhibition of ascending nociceptive pathways [39].

During thumb and toe stimulation, functional magnetic resonance imaging (fMRI) found a significant contralateral activation present in Crus II and an ipsilateral activation in lobule VI. More specifically, lobule VIII was found to be ipsilaterally activated during thumb stimulation. Toe stimulation triggered activation in lobules IV, V, VIII and IX bilaterally, as well as lobule VI contralaterally [36].

These highlight that the conjunction regions (Crus I and lobule VI), which are triggered by both painful stimuli and the anticipation of painful stimuli, are located bilaterally in the posterior cerebellum. These findings support that activated areas during thumb and toe stimulation are somatotopically organised. Additionally, it may be indicative that Crus I and lobule VI could have a role in the general processing of the emotional aspects of pain, due to the heightened activation present during both the anticipation of and the actual pain stimulus.

When trigeminal heat stimulation was applied to patients with migraine with aura (MwA) and migraine without aura (MwoA), it was found that cerebellar activation was significantly higher in patients with MwA compared to MwoA. Interestingly, the degree of cerebellar activation was found to directly correlate with disease duration in patients with MwA [51], demonstrating a heightened activation in patients with MwA as opposed to MwoA, with aura often being sensory disturbances, so the



connectivity of the cerebellum to these trigeminal sensory inputs could be underpinning the role of sensory processing during migraine pathology.

Electrical stimulation of the left tibial nerve was used to trigger the nociceptive leg reflex, using fMRI to record the corresponding cerebellar areas of this pathway. Highest activation was found in the anterior vermis in lobules VI and VIII, as well as lobules VI and VIII in the posterior vermis. Furthermore, activation was triggered in lobules III and IV of the anterior lobe and lobule VIII in the posterior lobe [20]. These findings are in good accordance with the associated regions with leg movement, and this also supports the previous findings of the activation of posterior cerebellar hemispheres during painful stimuli [20].

In another study, when thermal stimulation of the right hand was applied, activation areas were detected in lobules I–IV and VIIIb in the right cerebellar lobules, as well as lobules VI and VIIb in the left lobules. Activity was also found in vermis IX and the PAG [16]. The findings presented in this study suggest the presence of multimodal areas in motor control and pain perception within the posterior cerebellum, highlighting the connections between these areas and sensorimotor areas within the cortex. Lobules VI and VIIb have previously been shown to govern the integration of information across various modalities [13]. Previous clinical studies have revealed specific functions for differing cerebellar regions, reporting that motor control is largely associated with lobules V and VIII, whereas more intricate tasks are correlated with lobules VI and VII [16]. Although functional regions of the cerebellum have not yet been established for pain perception, meta-analyses suggest that pain-related activities are mainly localised to lobules IV, V and bilateral lobule VI [41].

### Neurostimulation of the Cerebellum and its Effects on Pain

Non-invasive brain stimulation (NIBS) is a blanket term for a number of techniques. NIBS provides a safer and better-tolerated means to

regulate neuronal activity without the risks and recovery time that comes with invasive procedures, such as deep brain stimulation [31]. This scope of this review mainly focuses on tDCS and rTMS; however, other techniques such as transcranial electrical stimulation and transcranial alternating current stimulation have also been utilised [46]. tDCS consists of the application of a weak direct current. Typically, positive anodal stimulation will influence cortical excitability, whereas negative cathodal stimulation generally has an opposite effect [24]. TMS refers to the non-invasive magnetic stimulation of the brain, performed in order to alter excitability of the cortex. rTMS, more specifically, is the repetitive stimulation of a particular brain region. This is achieved through application of a high- or low-intensity magnetic field. Dependant on the desired effect, variables such as frequency, intensity, target regions and length of treatment plan are adjusted accordingly. Generally, a low frequency (< 1 Hz) will exhibit inhibitory effect whereas higher frequencies (> 1 Hz) will exhibit excitatory effects [60].

In a study using heat stimulation, tDCS was administered to assess regulatory properties of the cerebellum during nociception and endogenous pain modulation. Following a 5-s heat stimulus to the right and left arms, the results of this study revealed a significant decrease in CPM [56]. It should be noted that tDCS was administered over the occipital bone, which could minimise tDCS effects due to its thickness. The findings of the study are supportive that cathodal tDCS increased pain perception and decreased endogenous pain inhibition, whereas anodal tDCS appeared to increase endogenous pain inhibition. This falls in line with many previous studies, with the general consensus being that anodal tDCS increases the excitability of the cerebellum, whereas cathodal is thought to have the opposite effect. However, due to the unique disposition of the cerebellar functional units, analysing effects of cerebellar tDCS and localising them to specific lobules remains challenging, and should be kept in mind when interpreting results [58].

A similar study investigated lower extremity sensory and pain thresholds, using cerebellar transcranial direct current stimulation (ctDCS)

on healthy volunteers. Pain thresholds (PT) were obtained before and after the administration of ctDCS, revealing that ctDCS modulated lower extremity PT. More specifically, anodal stimulation caused a significant increase in pain perception compared to cathodal and sham [43]. In another study using ctDCS on upper limb amputees who experience both painful and non-painful phantom limb sensations, laser-evoked potentials were recorded from their site of amputation. Following anodal ctDCS, the results showed that phantom limb symptoms significantly improved [7], providing evidence that anodal ctDCS improves painful and non-painful phantom limb symptoms in patients with upper limb amputations. While these findings mimic similar results from previous literature [1, 48], other studies have displayed no correlation between painful and non-painful phantom limb sensations after the application of tDCS over the primary motor cortex [9].

tDCS was used to assess the cerebellum in pain perception and nociceptive processing through application of laser stimulation to the back of the hand. A direct current was administered transcranially revealing that cathodal tDCS increases pain perception, as well as increases laser-evoked potentials amplitudes and decreases their latencies [8]. Similar to Stacheneder et al. [56] and Pereira et al. [43], the findings of this study supported that cathodal tDCS increases pain perception. These findings fall in line with the hypothesis that cerebellum exerts an inhibitory influence on other brain regions, and, thus, a reduction in this will increase pain perception.

Hypnotisability-related differences were investigated through the use of ctDCS in pain modulation. This revealed only a small change in ctDCS in highly hypnotisable individuals following a nociceptive stimulus [6]. The paper highlighted that ‘hypnotisability’ is an influential factor which can cause variation of cerebellar function within the general population. As the study contained only 16 subjects, a low study sample should be factored in when considering these results. Nonetheless, this novel experiment provides an interesting standpoint on cerebellar function, highlighting that implementing hypnotic assessments before pain-focused ctDCS could be beneficial.

Another study used rTMS to investigate cerebellar modulation on peripheral stimulation effects. This was assessed through the application of low frequency rTMS stimulation on Crus II in the lateral cerebellum, and also in the lateral neck. Findings revealed that 1-Hz rTMS over Crus II resulted in a significantly increased HPT and decreased CT. Furthermore, changes in CT and HPT were present following rMS over the lateral neck, suggesting that modulatory changes to thermal perceptions are likely from periphery or afferents and not from cerebellar alterations itself [62]. However, as this study only had a sample size of 12, it is possible that there was a surplus effect of the cerebellar rTMS over rMS of the neck. While general observational trends of rTMS and rMS effects have been extracted from previous literature, the exact mechanisms of how these modulate pain remain ambiguous.

### Role of Cerebellum on Pain Perception and Pain Anticipation

Pain anticipation is a multifactorial state which holds the power to influence the immediate severity of pain, as well as shape pain perception as a whole [42]. Pain anticipation can evoke feelings of anxiety and fear. This phenomenon in turn can trigger cortical excitability and thus influence descending pathways to regulate pain perception and behaviour [61]. The anticipation of pain can cause individuals to become increasingly sensitive to somatosensory stimuli, eliciting different responses in various individuals, even if they receive the same stimulus [30]. The correlation of pain anticipation to the cerebellum was first demonstrated in 1999, revealing that a painful heat stimulus triggered activation in the bilateral midline of the anterior cerebellum, whereas the pain anticipation of a heat stimulus elicited activation ipsilaterally in the posterior cerebellum [45].

Changes in cerebellar activation were analysed during visceral pain-related fear conditioning and extinction in individuals with irritable bowel syndrome (IBS). Following fMRI, participants with IBS showed significantly more activation in CS+ and CS-. Three significant clusters were identified; (1) lobule VI in the upper



vermis, (2) lobule VIIIb with partial extension into the right lobule VIIa and X, and (3) right lobule VI with partial extension into Crus I [15]. These findings further support the hypothesis that the cerebellum plays a role in the neuronal pathway which correlate to maladaptive pain-related conditioning present in patients with IBS. Collectively, IBS patients showed heightened activation in regions within the vermis and intermediate cerebellum, as well as the lateral hemispheres. These regions are likely to have a role in fear conditioning.

In another study, fMRI was carried out on 15 patients with mild craniomandibular disorder during occlusal movements. Following occlusal Michigan splint therapy for 2 weeks and fMRI measurements, changes in BOLD magnitude were observed in the right anterior insula, left posterior insula and the left cerebellar hemisphere, namely Crus I and Crus II [29]. Furthermore, this was correlated to a significant decrease in angle from  $3.58^\circ$  to  $3.15^\circ$ . The higher degree of cerebellar activation in the right posterior lobe before therapy is suggestive of a heightened sensorimotor control processes prior to any intervention. These findings have been mimicked in previous studies [29], highlighting the association between decreased pain scores and low activation rates in the left cerebellar hemisphere. As previously mentioned, the therapy duration is relatively short, with other studies typically using treatment periods of 4–12 weeks [28].

MVPA was used to explore the central processing system of pain perception in individuals with cLBP. Interestingly, the study demonstrated a negative correlation between the right Crus II and SMA.R to the severity of pain-related symptoms [12]. However, the number of participants were relatively low, which restricts the generalisability of the results. Crus II has previously been reported to have a link to various cognitive disorders such as schizophrenia [40] and Parkinson's disease [54]. Similarly to these findings, the present study also highlighted the significance of Crus II in the central processing of pain perception in cLBP. The work of Labrenz et al. [26], who also highlighted Crus II in their findings, conducted a study to investigate any sex-related differences in neuronal and behavioural

responses for pain-related safety cues, with respect to cerebellar mechanisms. The study used 48 participants using rectal distension as an unconditioned stimulus combined with a visual warning cue (CS). Significant activation clusters in females were detected in bilateral lobules I–IV, left lobules V, VIIa, IX, X, left Crus II and the right dentate nucleus, subsequent to the safety cues. Conversely, male activation clusters following the safety cues were reported in lobules I–IV, VI, VIIIb, right lobules VIIb, and the right Crus I and left Crus II. The activation clusters which were present in males are connected to the frontoparietal, ventral attention, limbic and default networks [26]. Crus II showed to be the largest activation cluster in males, which is involved with structures such as the prefrontal cortex, as well as the parietal cortex. This is linked to functions such as regulating complex cognitive behaviour [2], with the frontoparietal being a hub for processing both pain anticipation and application [25].

Another study used pain testing as a means to compare acute pain perception in cerebellar infarction patients. All the patients were 1–11 years after cerebellar infarction. Results found skin temperature was significantly lower in patients when compared to HC. Furthermore, it was found that patients experienced the heat stimulus to be more painful when compared to HC [50]. When examining for any correlations to cerebellar infarction location, it was found that heat stimuli ipsilaterally were perceived as more painful than those contralaterally ( $P < 0.05$ ).

The above findings largely demonstrated heat hyperalgesia to be present ipsilaterally to the side of cerebellar lesion. However, not all cases followed this trend, interestingly contrasting to the strict ipsilateral nature of motor symptoms present following cerebellar lesions [57]. The cerebellum has reciprocated connectivity with the dorsolateral prefrontal cortex [27], which is largely associated with cognitive control and also specific pain sensitivity [53]. Furthermore, the cerebellum has connections with varying brainstem structures [5], which are core to descending pain-modulatory circuits [38]. Thus, although this puts the cerebellum in a good position to influence the placebo effect

in pain studies, the results of this study do not exhibit placebo analgesia as one might expect. Collectively, these findings are suggestive that the cerebellum is a supraspinal centre which may exert modulatory effects on descending pain-modulatory circuits.

## LIMITATIONS

Relying on a single database, PubMed, may introduce publication bias. However, PubMed is the largest and most reputable medical database, where high-quality studies are typically indexed. While some relevant papers may not be included, studies not indexed in PubMed are often of lower quality.

Moreover, this review did not include studies on pediatric populations. Pain is a highly subjective symptom, and studies in children may have additional limitations regarding accuracy and reliability. Additionally, this review is addressed to clinicians specializing in adult patients. Including pediatric studies could have diluted our findings and made interpretation more complex. However, we acknowledge this as an important area for future research.

## FURTHER DIRECTIONS FOR FUTURE RESEARCH

On the basis of the literature reviewed in the present study, longitudinal research could be vastly beneficial when translating these findings into a clinical standpoint. A common limitation among the papers in this review is the small sample sizes. Long-term studies should be encouraged, evaluating the prolonged effects of cerebellar-targeted therapies, such as tDCS and rTMS, when treating pain disorders. Additional mechanistic studies could be used to investigate how differing cerebellar lobules influence pain pathways and other brain regions when modulating pain perception.

It has become more apparent that many factors affect pain perception. For example, ‘hypnotisability’ in the general population was

shown to cause variation in cerebellar function [6]. More research is needed to identify these underlying factors, so that individual response to treatment can be better understood and thus provide better clinical outcomes when treating pain-related symptoms. Identifying which cerebellar regions interact with differing pain pathways would allow for a more ‘personalised medicine’ approach, thus minimising trial-and-error in treating pain-related symptoms. The findings of the present study fall in line with the potential of neuromodulation in treating chronic pain. Further research in refining these techniques should be encouraged to improve patient outcomes. Furthermore, investigating synergistic effects of neurostimulation of the cerebellum with other treatments such as pharmaceuticals should be researched further, in order to identify potential combination therapies for pain management.

The potential of these findings in clinical use is substantial; however, much more research is needed in pinpointing specific cerebellar regions to function in pain perception before this can be utilised clinically. Currently, while there is much recorded overlap of cerebellar activation in experiments concerning pain perception, there is still a vast variety of results which need to be addressed before reliable and safe treatments can be designed.

## CONCLUSION

The cerebellum plays a significant role in pain processing, particularly in inhibiting pain sensation, with regions like Crus I, Crus II, and lobule VI involved in pain anticipation, perception, and emotional aspects. Activation in lobules I–VI, VIII, and the vermis has been linked to nociceptive signalling, fear conditioning, and sensory integration. Studies have also highlighted cerebellar involvement in conditions such as chronic pain, IBS, and migraines, with specific regions showing altered activation patterns. These findings underscore the cerebellum’s multimodal role in integrating pain, motor responses, and emotional processing.

**Author Contributions.** Orita Manda screened the papers, collected the data and drafted the manuscript. Marios Hadjivassiliou, Giustino Varrassi and Periklis Zavridis critically revised the manuscript. Panagiotis Zis designed the study, screened the papers, analysed the data and drafted the manuscript.

**Funding.** No funding or sponsorship was received for this study or publication of this article.

**Data Availability.** The datasets generated during and/or analysed during the current study are available from the corresponding author on reasonable request.

### Declarations

**Conflict of Interest.** Giustino Varrassi is an Editor-in-Chief and Panagiotis Zis is an Editorial Board member of Pain and Therapy. Neither were involved in the selection of peer reviewers for the manuscript nor any of the subsequent editorial decisions. Orita Manda, Marios Hadjivassiliou and Periklis Zavridis declare no conflicts of interest.

**Ethical Approval.** This article is based on previously conducted studies and does not contain any new studies with human participants or animals performed by any of the authors. Thus, there are no ethical concerns in respect to this study, nor was approval of the research protocol from an ethics committee required.

**Open Access.** This article is licensed under a Creative Commons Attribution-NonCommercial 4.0 International License, which permits any non-commercial use, sharing, adaptation, distribution and reproduction in any medium or format, as long as you give appropriate credit to the original author(s) and the source, provide a link to the Creative Commons licence, and indicate if changes were made. The images or other third party material in this article are included in the article's Creative Commons licence, unless indicated otherwise in a credit line to the material. If material is not included in the article's Creative

Commons licence and your intended use is not permitted by statutory regulation or exceeds the permitted use, you will need to obtain permission directly from the copyright holder. To view a copy of this licence, visit <http://creativecommons.org/licenses/by-nc/4.0/>.

## REFERENCES

1. Anderson WS, Lenz FA. Review of motor and phantom-related imagery. *NeuroReport*. 2011;22(17):939–42.
2. Arnsten AF. Stress signalling pathways that impair prefrontal cortex structure and function. *Nat Rev Neurosci*. 2009;10(6):410–22.
3. Baarbé JK, Yelder P, Haavik H, Holmes MWR, Murphy BA. Subclinical recurrent neck pain and its treatment impacts motor training-induced plasticity of the cerebellum and motor cortex. *PLoS ONE*. 2018;13(2): e0193413.
4. Basedau H, May A, Mehnert J. Cerebellar somatotopy of the trigemino- cervical complex during nociception. *Eur J Pain*. 2024;28(5):719–28.
5. Basinger H, Hogg JP. 'Neuroanatomy, Brainstem', *StatPearls*. Treasure Island (FL): StatPearls Publishing Copyright © 2024, StatPearls Publishing LLC.
6. Bocci T, Barloscio D, Parenti L, Sartucci F, Carli G, Santarcangelo EL. High hypnotizability impairs the cerebellar control of pain. *Cerebellum*. 2017;16(1):55–61.
7. Bocci T, De Carolis G, Ferrucci R, Paroli M, Mansani F, Priori A, Valeriani M, Sartucci F. Cerebellar transcranial direct current stimulation (ctDCS) ameliorates phantom limb pain and non-painful phantom limb sensations. *Cerebellum*. 2019;18(3):527–35.
8. Bocci T, Santarcangelo E, Vannini B, Torzini A, Carli G, Ferrucci R, Priori A, Valeriani M, Sartucci F. Cerebellar direct current stimulation modulates pain perception in humans. *Restor Neurol Neurosci*. 2015;33(5):597–609.
9. Bolognini N, Olgiati E, Maravita A, Ferraro F, Fregni F. Motor and parietal cortex stimulation for phantom limb pain and sensations. *Pain*. 2013;154(8):1274–80.
10. Borsook D, Moulton EA, Tully S, Schmähmann JD, Becerra L. Human cerebellar responses to brush and heat stimuli in healthy and neuropathic pain subjects. *Cerebellum*. 2008;7(3):252–72.

11. Buckner RL. The cerebellum and cognitive function: 25 years of insight from anatomy and neuroimaging. *Neuron*. 2013;80(3):807–15.
12. Chen Y, Yang Y, Gong Z, Kang Y, Zhang Y, Chen H, Zeng K, Men X, Wang J, Huang Y, Wang H, Zhan S, Tan W, Wang W. Altered effective connectivity from cerebellum to motor cortex in chronic low back pain: a multivariate pattern analysis and spectral dynamic causal modeling study. *Brain Res Bull*. 2023;204: 110794.
13. Christensen A, Giese MA, Sultan F, Mueller OM, Goericke SL, Ilg W, Timmann D. An intact action-perception coupling depends on the integrity of the cerebellum. *J Neurosci*. 2014;34(19):6707–16.
14. Christova M, Sylwester V, Gallasch E, Fresnoza S. Reduced cerebellar brain inhibition and vibrotactile perception in response to mechanical hand stimulation at flutter frequency. *The Cerebellum*. 2022. <https://doi.org/10.1007/s12311-022-01502-4>.
15. Claassen J, Labrenz F, Ernst TM, Icenhour A, Langhorst J, Forsting M, Timmann D, Elsenbruch S. Altered cerebellar activity in visceral pain-related fear conditioning in irritable bowel syndrome. *Cerebellum*. 2017;16(2):508–17.
16. Coombes SA, Misra G. Pain and motor processing in the human cerebellum. *Pain*. 2016;157(1):117–27.
17. D'Angelo E. The cerebellar network: revisiting the critical issues. *J Physiology*. 2011;589(Pt 14):3421–2.
18. Daligadu J, Haavik H, Yelder PC, Baarbe J, Murphy B. Alterations in cortical and cerebellar motor processing in subclinical neck pain patients following spinal manipulation. *J Manipulative Physiol Ther*. 2013;36(8):527–37.
19. Diano M, D'Agata F, Cauda F, Costa T, Geda E, Sacco K, Duca S, Torta DM, Geminiani GC. Cerebellar clustering and functional connectivity during pain processing. *Cerebellum*. 2016;15(3):343–56.
20. Dimitrova A, Kolb FP, Elles HG, Maschke M, Forsting M, Diener HC, Timmann D. Cerebellar responses evoked by nociceptive leg withdrawal reflex as revealed by event-related fMRI. *J Neurophysiol*. 2003;90(3):1877–86.
21. Edvinsson JCA, Viganò A, Alekseeva A, Alieva E, Arruda R, De Luca C, D'Ettore N, Frattale I, Kurnukhina M, Macerola N, Malenkova E, Maiorova M, Novikova A, Řehulka P, Rapaccini V, Roshchina O, Vanderschueren G, Zvaune L, Andreou AP, Haanes KA, On behalf of the European Headache Federation School of Advanced. The fifth cranial nerve in headaches. *J Headache Pain*. 2020;21(1):65.
22. Gilam G, Gross JJ, Wager TD, Keefe FJ, Mackey SC. What is the relationship between pain and emotion? Bridging constructs and communities. *Neuron*. 2020;107(1):17–21.
23. Glickstein M, Strata P, Voogd J. Cerebellum: history. *Neuroscience*. 2009;162(3):549–59.
24. Jonker ZD, Gaiser C, Tulen JHM, Ribbers GM, Frens MA, Selles RW. No effect of anodal tDCS on motor cortical excitability and no evidence for responders in a large double-blind placebo-controlled trial. *Brain Stimul*. 2021;14(1):100–9.
25. Kong J, Jensen K, Loiotile R, Cheetham A, Wey HY, Tan Y, Rosen B, Smoller JW, Kaptchuk TJ, Gollub RL. Functional connectivity of the frontoparietal network predicts cognitive modulation of pain. *Pain*. 2013;154(3):459–67.
26. Labrenz F, Icenhour A, Thürling M, Schlamann M, Forsting M, Timmann D, Elsenbruch S. Sex differences in cerebellar mechanisms involved in pain-related safety learning. *Neurobiol Learn Mem*. 2015;123:92–9.
27. Lam CLM, Wong CHY, Junghöfer M, Roesmann K. Implicit threat learning involves the dorsolateral prefrontal cortex and the cerebellum. *Int J Clin Health Psychol*. 2023;23(2): 100357.
28. Lickteig R, Lotze M, Kordass B. Successful therapy for temporomandibular pain alters anterior insula and cerebellar representations of occlusion. *Cephalalgia*. 2013;33(15):1248–57.
29. Lickteig R, Lotze M, Lucas C, Domin M, Kordaß B. Changes in cortical activation in craniomandibular disorders during splint therapy – a single subject fMRI study. *Ann Anat - Anatomischer Anzeiger*. 2012;194(2):212–5.
30. Lindheimer JB, Stegner AJ, Ellingson-Sayen LD, Van Riper SM, Dougherty RJ, Falvo MJ, Cook DB. Influence of pain anticipation on brain activity and pain perception in Gulf War Veterans with chronic musculoskeletal pain. *Psychophysiology*. 2019;56(12): e13452.
31. Liu X, Qiu F, Hou L, Wang X. Review of noninvasive or minimally invasive deep brain stimulation. *Front Behav Neurosci*. 2022. <https://doi.org/10.3389/fnbeh.2021.820017>.
32. Lumley MA, Cohen JL, Borszcz GS, Cano A, Radcliffe AM, Porter LS, Schubiner H, Keefe FJ. Pain and emotion: a biopsychosocial review of recent research. *J Clin Psychol*. 2011;67(9):942–68.

33. Lundh A, Gøtzsche PC. Recommendations by cochrane review groups for assessment of the risk of bias in studies. *BMC Med Res Methodol*. 2008;8(1):22.
34. Mehnert J, Schulte L, Timmann D, May A. Activity and connectivity of the cerebellum in trigeminal nociception. *Neuroimage*. 2017;150:112–8.
35. Merskey H. History and definition of pain, *Chronic Pain*, 2008; 19–28
36. Michelle Welman FHS, Smit AE, Jongen JLM, Tibboel D, van der Geest JN, Holstege JC. Pain experience is somatotopically organized and overlaps with pain anticipation in the human cerebellum. *Cerebellum*. 2018;17(4):447–60.
37. Middleton FA, Strick PL. Anatomical evidence for cerebellar and basal ganglia involvement in higher cognitive function. *Science*. 1994;266(5184):458–61.
38. Mills EP, Keay KA, Henderson LA. Brainstem pain-modulation circuitry and its plasticity in neuropathic pain: insights from human brain imaging investigations. *Front Pain Res (Lausanne)*. 2021;2:705345.
39. Mokhtar M, Singh P. *Neuroanatomy, Periaqueductal Gray*, *StatPearls*. Treasure Island (FL): StatPearls Publishing Copyright © 2024, StatPearls Publishing LLC.
40. Morimoto C, Uematsu A, Nakatani H, Takano Y, Iwashiro N, Abe O, Yamasue H, Kasai K, Koike S. Volumetric differences in gray and white matter of cerebellar Crus I/II across the different clinical stages of schizophrenia. *Psychiatry Clin Neurosci*. 2021;75(8):256–64.
41. Moulton EA, Elman I, Pendse G, Schmahmann J, Becerra L, Borsook D. Aversion-related circuitry in the cerebellum: responses to noxious heat and unpleasant images. *J Neurosci*. 2011;31(10):3795–804.
42. Palermo S, Benedetti F, Costa T, Amanzio M. Pain anticipation: an activation likelihood estimation meta-analysis of brain imaging studies. *Hum Brain Mapp*. 2015;36(5):1648–61.
43. Pereira M, Rafiq B, Chowdhury E, Babayev J, Boo H, Metwaly R, Sandilya P, Chusid E, Battaglia F. Anodal cerebellar tDCS modulates lower extremity pain perception. *NeuroRehabilitation*. 2017;40(2):195–200.
44. Pijnenburg M, Caeyenberghs K, Janssens L, Goossens N, Swinnen SP, Sunaert S, Brumagne S. Microstructural integrity of the superior cerebellar peduncle is associated with an impaired proprioceptive weighting capacity in individuals with non-specific low back pain. *PLoS ONE*. 2014;9(6):e100666.
45. Ploghaus A, Tracey I, Gati JS, Clare S, Menon RS, Matthews PM, Rawlins JN. Dissociating pain from its anticipation in the human brain. *Science*. 1999;284(5422):1979–81.
46. Potok W, van der Groen O, Bächinger M, Edwards D, Wenderoth N. Transcranial random noise stimulation modulates neural processing of sensory and motor circuits, from potential cellular mechanisms to behavior: a scoping review. *Neuro*. 2022. <https://doi.org/10.1523/ENEURO.0248-21.2021>.
47. Prati JM, Pontes-Silva A, Gianlorenço ACL. The cerebellum and its connections to other brain structures involved in motor and non-motor functions: a comprehensive review. *Behav Brain Res*. 2024;465: 114933.
48. Raffin E, Mattout J, Reilly KT, Giraux P. Disentangling motor execution from motor imagery with the phantom limb. *Brain*. 2012;135(Pt 2):582–95.
49. Rudolph S, Badura A, Lutz S, Pathak SS, Thieme A, Verpeut JL, Wagner MJ, Yang Y-M, Fioravante D. Cognitive-affective functions of the cerebellum. *J Neurosci*. 2023;43(45):7554.
50. Ruscheweyh R, Kühnel M, Filippopoulos F, Blum B, Eggert T, Straube A. Altered experimental pain perception after cerebellar infarction. *Pain*. 2014;155(7):1303–12.
51. Russo A, Tessitore A, Silvestro M, Di Nardo F, Trojsi F, Del Santo T, De Micco R, Esposito F, Tedeschi G. Advanced visual network and cerebellar hyperresponsiveness to trigeminal nociception in migraine with aura. *J Headache Pain*. 2019;20(1):46.
52. Schmahmann JD. An emerging concept: the cerebellar contribution to higher function. *Arch Neurol*. 1991;48(11):1178–87.
53. Seminowicz DA, Moayedi M. The dorsolateral prefrontal cortex in acute and chronic pain. *J Pain*. 2017;18(9):1027–35.
54. Solstrand Dahlberg L, Lungu O, Doyon J. Cerebellar contribution to motor and non-motor functions in Parkinson's disease: a meta-analysis of fMRI findings. *Front Neurol*. 2020. <https://doi.org/10.3389/fneur.2020.00127>.
55. Spampinato D, Avci E, Rothwell J, Rocchi L. Frequency-dependent modulation of cerebellar excitability during the application of non-invasive alternating current stimulation. *Brain Stimul*. 2021;14(2):277–83.

- 
56. Stacheneder R, Alt L, Straube A, Ruscheweyh R. Effects of transcranial direct current stimulation (t-DCS) of the cerebellum on pain perception and endogenous pain modulation: a randomized, monocentric, double-blind, sham- controlled crossover study. *Cerebellum*. 2023;22(6):1234–42.
  57. Unverdi M, Alsayouri K. 'Neuroanatomy, Cerebellar Dysfunction', *StatPearls*. Treasure Island (FL): StatPearls Publishing Copyright © 2024, StatPearls Publishing LLC.
  58. van Dun K, Bodranghien FC, Mariën P, Manto MU. 'tDCS of the cerebellum: where do we stand in 2016? Technical issues and critical review of the literature. *Front Hum Neurosci*. 2016;10:199.
  59. Van Overwalle F, Ma Q, Heleven E. The posterior crus II cerebellum is specialized for social mentalizing and emotional self-experiences: a meta-analysis. *Social Cognitive Affect Neurosci*. 2020;15(9):905–28.
  60. Wang J, Deng XP, Wu YY, Li XL, Feng ZJ, Wang HX, Jing Y, Zhao N, Zang YF, Zhang J. High-frequency rTMS of the motor cortex modulates cerebellar and widespread activity as revealed by SVM. *Front Neurosci*. 2020;14:186.
  61. Xu Z, Soh Z, Kurota Y, Kimura Y, Hirano H, Sasaoka T, Yoshino A, Tsuji T. Neuroimaging-based evidence for sympathetic correlation between brain activity and peripheral vasomotion during pain anticipation. *Sci Rep*. 2024;14(1):3383.
  62. Zunhammer M, Busch V, Griesbach F, Landgrebe M, Hajak G, Langguth B. rTMS over the cerebellum modulates temperature detection and pain thresholds through peripheral mechanisms. *Brain Stimul*. 2011;4(4):210-7.e1.