

Successful treatment of phantom limb pain and phantom limb sensation in the traumatic amputee using scalp acupuncture

Up to 80% of amputees report phantom limb pain (PLP), the management of which remains a considerable challenge. Here I describe the successful treatment with scalp acupuncture (SA) of a woman with PLP.

A 71-year-old woman with no significant medical history was injured in a road-traffic accident in January 2010, leaving her with a fracture of the right elbow and right scapula, and multiple lacerations in her left foot and right inguinal area. The fracture caused displacement of the middle third of her right radius from the distal end of her right ulna. This, combined with other fractures in the fifth metacarpal bone and the proximal phalanx, resulted in almost total traumatic amputation. Her right arm was amputated surgically below the elbow.

Recurrent wound infections occurred in her right forearm stump. As a result she underwent three debridement operations and split-thickness skin graft surgery. A skin rash, diagnosed as erythema multiforme, developed over the upper trunk after the operation. Steroid treatment stabilised the condition. After a hospital stay of about 1.5 months, she was discharged with outpatient follow-up.

The woman had PLP and phantom limb sensation (PLS) after the surgical amputation. She described this as “severe numbness and pain from the phantom fingers and through her right forearm stump”, and could feel the missing limb’s position in space and even attempted to use it to reach for objects. She took pharmacological agents such as barbiturates, muscle relaxants, antidepressants, analgesics, etc, for almost 2 years. However, the drugs did not relieve her PLP. The

pain persisted throughout the night, affecting her sleep and overall quality of life. As the drugs were ineffective and various side effects occurred she decided to stop taking them.

ACUPUNCTURE

In November 2011 she visited our Chinese medicine clinic for treatment of heartburn, constipation and PLP. We suggested acupuncture treatment. She had not previously received any form of acupuncture and was sceptical about its effectiveness in treating PLP. However, after an explanation of the procedure, she agreed to the treatment.

Initial examination showed that the patient’s stump had fully healed; the scar was uneven; the intact portion of her limb had normal muscle power and full range of movement. Changes in PLP and PLS intensity were measured using an 11-point numeric rating Visual Analogue Scale (VAS)¹ at each session. In the first session her VAS score for PLP was 10 and for PLS 8.

Four scalp points and one scalp line were selected for treatment. The four points were the *Sishencong* (EX-HN1) on the vertex of the head, anterior, posterior and lateral to the *Baihui* (GV20) (see figure 1). The acupuncture line was the MS7 (posterior oblique line of the vertex-temporal from GV20) oblique to *Qubin* (GB7) on the contralateral side of the phantom limb (see figure 2). The needles used (0.30×25 mm) were inserted 1 cun

at an oblique angle of around 15° into the subaponeurotic space. After insertion, the needles were stimulated by rapid small-amplitude lifting and thrusting (in and out) movements for 1 min, resulting in a marked *de qi* effect. The needles were left in the scalp for 20 min. The patient underwent six sessions of treatment, twice a week for 3 weeks.

Immediately after the first session, the patient noted significant relief of both PLP and PLS. In the second session just 2 days later she had a VAS score for PLP of 4, and for PLS of 3. She reported no adverse effects and continued with the same SA treatment. At final review 6 months after her final treatment in December 2011, she was completely free of PLP and PLS.

COMMENTS

In about half of amputees, PLP occurs immediately after the amputation. The mechanisms of PLP are unknown, but cortical and peripheral mechanisms may be responsible.²

Treatment of PLP includes drugs, invasive motor cortex stimulation techniques and conservative treatment. Although pharmacological treatments such as barbiturates, muscle relaxants, antidepressants, neuroleptic agents and anticonvulsants have been recommended, their wide range of side effects is a cause for concern. Since most treatments for PLP have limited effectiveness,³ its management remains a considerable challenge. To our knowledge, few studies have explored the clinical

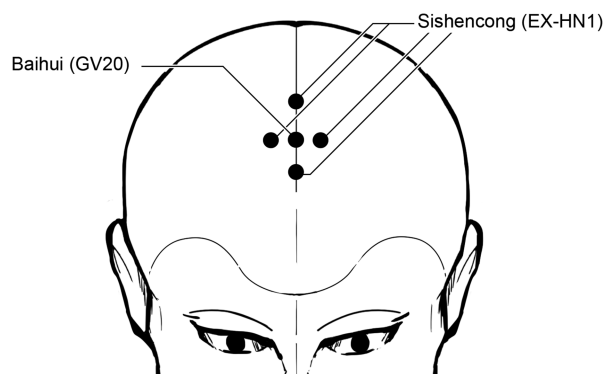


Figure 1 *Sishencong* (EX-HN1) is a group of four points around GV20 (*Baihui*), each 1 cun away from Baihui in four directions (anterior, bilateral and posterior).

effect of acupuncture in PLP.^{4,5} We believe that this is the first report of a patient who had complete relief from PLP after SA.

Experimental studies show that neuroplastic changes of the sensorimotor cortex are often associated with PLP.^{6,7} This highlights the use of motor and parietal cortex stimulation in the treatment of PLP.⁸ Increased knowledge of the proposed mechanisms of cortical reorganisation has added to our understanding of SA treatment protocols for PLP and PLS. The SA line MS7 is located on the lateral side of the head, 1.5 cun parallel and posterior to MS6, extending from GV20 to GB7, and related to the underlying sensory area of the brain.⁹ The main therapeutic claim for the SA line MS7 is relief of pain, numbness and sensory disorders.¹⁰

The extra point *Sishencong* is located on the vertex of the head and forms a group of four points

around the GV20.¹¹ The main therapeutic effect claimed for *Sishencong* is the relief of insomnia, and it has been shown that acupuncture at *Sishencong* enhances cardiac vagal function and suppresses sympathetic activity.¹² Although there are numerous theories about the underlying mechanism of PLP, association with cardiovascular hyperactivity and greater sympathetic response has been proposed.¹³

In our case, an elderly woman had had PLP and PLS for almost 2 years, which was relieved after a short course of SA treatment, avoiding further use of drugs. We suggest that SA should be tried as an alternative approach to the treatment of PLP and PLS in patients who do not respond well to conventional treatment. Long-term, randomised, controlled and double-blind studies of a larger group of patients are warranted to explore the efficacy of SA in the patient population.

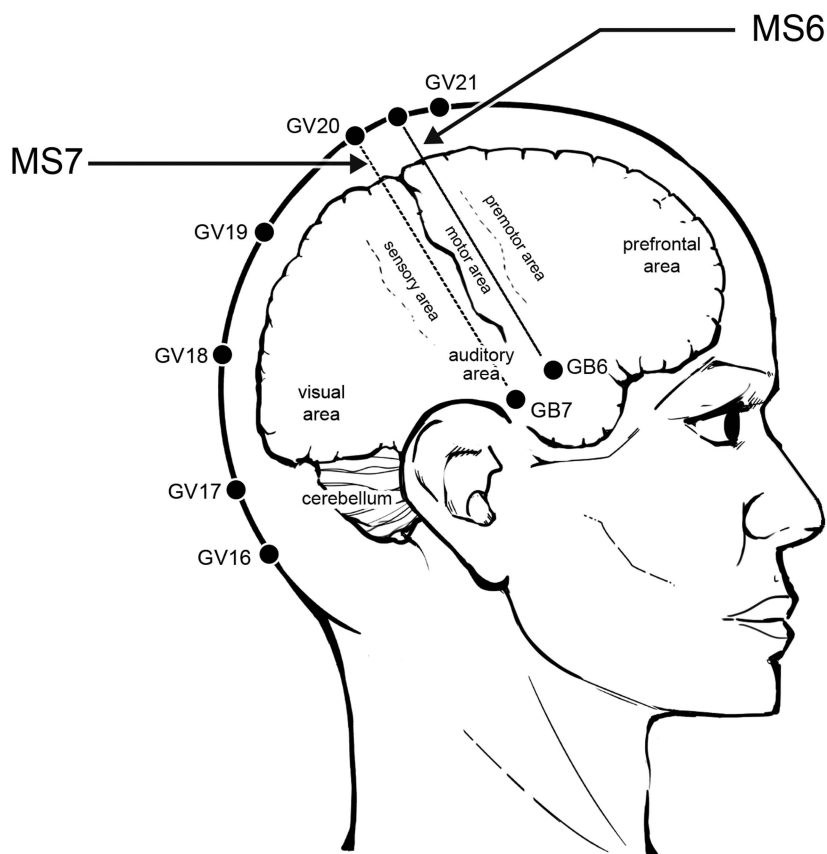


Figure 2 Scalp acupuncture line MS7 (posterior oblique line of vertex-temporal from GV20 obliquely to GB7).

Chi-Chuan Tseng,^{1,2,3} Pin-Yeh Chen,³ Yi-Ching Lee³

¹Division of Chinese Medicine, Chang Gung Memorial Hospital, Chiayi, Taiwan

²Graduate Institute of Clinical Medical Sciences, College of Medicine, Chang Gung University, Taoyuan, Taiwan

³School of Traditional Chinese Medicine, Chang Gung University, Taoyuan, Taiwan

Correspondence to Dr Chi-Chuan Tseng, Division of Chinese Medicine, Chiayi Chang Gung Memorial Hospital, No 6, West Section, Chiapu Road, Putzu City, Chiayi Hsien 613, Taiwan; acupmox@gmail.com

Acknowledgements The authors are grateful to Jason Tseng for his assistance as scientific advisor in this research and his medical illustration.

Contributors C-CT was involved in the development of research protocols, design of the study, carrying out literature review and writing of the article. P-YC and Y-CL contributed to acquisition of data and carrying out the article review. All authors read and approved the final manuscript.

Competing interests None.


Patient consent Obtained.

Ethics approval Chang Gung Memorial Hospital (No 102-4324B).

Provenance and peer review Not commissioned; externally peer reviewed.



OPEN ACCESS



Open Access
Scan to access more
free content

Open Access This is an Open Access article distributed in accordance with the Creative Commons Attribution Non Commercial (CC BY-NC 3.0) license, which permits others to distribute, remix, adapt, build upon this work non-commercially, and license their derivative works on different terms, provided the original work is properly cited and the use is non-commercial. See: <http://creativecommons.org/licenses/by-nc/3.0/>



CrossMark

To cite Tseng C-C, Chen P-Y, Lee Y-C. *Acupunct Med* 2014;**32**:356–358.

Received 8 March 2014

Accepted 28 April 2014

Published Online First 22 May 2014

Acupunct Med 2014;**32**:356–358.

doi:10.1136/acupmed-2014-010556

REFERENCES

- 1 White A. Measuring pain. *Acupunct Med* 1998;16:83–7.
- 2 Weeks SR, Anderson-Barnes VC, Tsao JW. Phantom limb pain theories and therapies. *Neurologist* 2010;16:277–86.
- 3 Flor H. Phantom-limb pain: characteristics, causes, and treatment. *Lancet Neurol* 2002;1:182–9.
- 4 Bradbrook D. Acupuncture treatment of phantom limb pain and phantom limb sensation in amputees. *Acupunct Med* 2004;22:93–7.
- 5 Davies A. Acupuncture treatment of phantom limb pain and phantom limb sensation in a primary care setting. *Acupunct Med* 2013;31:101–4.
- 6 Flor H, Nikolajsen L, Staehelin Jensen T. Phantom limb pain: a case of maladaptive CNS plasticity? *Nat Rev Neurosci* 2006;7:873–81.
- 7 Lotze M, Flor H, Grodd W, *et al.* Phantom movements and pain. An fMRI study in upper limb amputees. *Brain* 2001;124:2268–77.
- 8 Bolognini N, Olgjati E, Maravita A, *et al.* Motor and parietal cortex stimulation for phantom limb pain and sensations. *Pain* 2013;154:1274–80.
- 9 WHO Scientific Group on International Acupuncture Nomenclature. A Proposed Standard International Acupuncture Nomenclature. Report of a WHO Scientific Group. Geneva, Switzerland: World Health Organization, 1991:17.
- 10 Wang Y. *Micro-acupuncture in practice*. 1st edn. St Louise, MO: Churchill Livingstone Elsevier, 2009:55.
- 11 Focks C. *Atlas of acupuncture*. 1st edn. Edinburgh: Churchill Livingstone Elsevier, 2008:539.
- 12 Wang JD, Kuo TBJ, Yang CCH. An alternative method to enhance vagal activities and suppress sympathetic activities in humans. *Auton Neurosci* 2002;100:90–5.
- 13 Angrilli A, Köster U. Psychophysiological stress responses in amputees with and without phantom limb pain. *Physiol Behav* 2000;68:699–706.