

Surgical treatment of severe laryngomalacia: a retrospective study of 11 cases

José Antonio Pinto¹, Henrique Wambier², Elcio Izumi Mizoguchi², Leonardo Marques Gomes², Rodrigo Kohler², Renata Coutinho Ribeiro²

Keywords:

airway handling;
laryngomalacia;
respiratory sounds.

Abstract

Laryngomalacia is the most frequent congenital abnormality of the larynx, accounting for approximately 60-75% of congenital stridor cases. Despite its benign and self-limited aspects, 10% of cases require intervention. Currently, supraglottoplasty is considered the standard treatment of severe laryngomalacia.

Objective: To describe the experience of the authors in the surgical treatment of patients with severe laryngomalacia. Methodology: A retrospective study.

Method: The medical records of 11 consecutive cases of severe laryngomalacia who underwent surgical treatment between 2003 and 2012 were analyzed for age, gender, symptoms, associated diseases, surgical technique employed, extubation time, surgical complications, length of hospital stay and clinical outcome.

Results: Of the 11 cases of severe laryngomalacia, six patients (54.5%) were operated with the use of CO₂ laser and five patients (45.5%) were submitted to the cold technique. Only 1 patient (9.1%) required surgical reintervention. There were no cases of surgical complications. All patients had clinical improvement.

Conclusion: Supraglottoplasty proved to be effective and safe in the treatment of severe laryngomalacia.

¹ Otorhinolaryngologist (Director/Chief).

² ENT Resident - Nucleus of Otorhinolaryngology and Head and Neck Surgery of São Paulo.
Nucleus of Otorhinolaryngology and Head and Neck Surgery of São Paulo.

Send correspondence to: José Antonio Pinto. Al. dos Nhambiquaras, nº 159. Moema. São Paulo - SP. Brazil. CEP: 04090-010.
Paper submitted to the BJORL-SGP (Publishing Management System – Brazilian Journal of Otorhinolaryngology) on February 20, 2013;
and accepted on June 14, 2013. cod. 10784.

INTRODUCTION

Laryngomalacia is the most common congenital abnormality of the larynx, accounting for about 60% to 75% of congenital stridor cases¹⁻³. Although its pathogenesis is not fully understood, there is a collapse of supraglottic tissues during inspiration^{4,5}, generating a high-frequency inspiratory stridor, exacerbated in the supine position during feeding, agitation and crying⁶⁻⁸. This stridor usually appears in the first two weeks of life, with an incidence peak around 6 months and spontaneous resolution in 90% of the cases by the second year of life^{9,10}. Despite its benign and self-limited nature, 10% of laryngomalacia cases require intervention to relieve the respiratory obstruction^{10,11}.

Tracheotomy was considered the safest option for airway maintenance; however, it has become an obsolete method, especially in the last 20 years with the advent of minimally invasive endoscopic techniques. Although some authors advocate hyomandibulopexy as a treatment for severe laryngomalacia, most operations currently involve endoscopic procedures in the supraglottic region, the so-called supraglottoplasties¹¹⁻¹⁵.

These techniques can be subdivided according to the anatomical region addressed. When the aryepiglottic fold mucosa is excised, we call it: aryepiglottoplasty; likewise, we call it arytenoidoplasty and epiglottoplasty when the supra-arytenoid and epiglottis mucosae are resected, respectively. Other variants described are: epiglottopexy - which corresponds to the lingual-face attachment of the epiglottis to the base of the tongue, and epiglottectomy, which corresponds to the epiglottis cartilage resection¹⁴.

The definition of severe laryngomalacia is based on the following clinical criteria: apnea, cyanosis, respiratory failure, cor pulmonale, feeding difficulties, low weight and height development, and uncontrollable gastroesophageal reflux - which are severity indicators, being criteria for surgical intervention^{10,13,15,16}.

The aim of this study is to describe the experience of the authors in the surgical treatment of patients with severe laryngomalacia evaluated in the pediatric ICU of a tertiary hospital.

METHOD

Longitudinal historical cohort study, with patient chart review and video recording of 11 surgical patients with severe laryngomalacia, submitted to supraglottoplasty from January 2003 to April 2012.

The charts and video documentation of procedures were obtained from the hospital medical files. We collected data regarding age, gender, symptoms,

associated diseases, surgical technique used, extubation time, surgical complications, length of hospital stay and clinical outcome. This study was approved by the Research Ethics Committee, under protocol number 151.689.

RESULTS

Among the 11 cases evaluated for severe laryngomalacia, nine (81.8%) were males and two were (18.2%) females. All children in the study had stridor and respiratory distress - the main reason for hospitalization; and they were initially evaluated in the intensive care unit.

The time of surgery ranged from 1 to 12 months of age. All patients underwent suspension microlaryngoscopy, and supraglottoplasty was performed under general anesthesia and tracheal intubation (Figures 1 and 2 of case number 3).

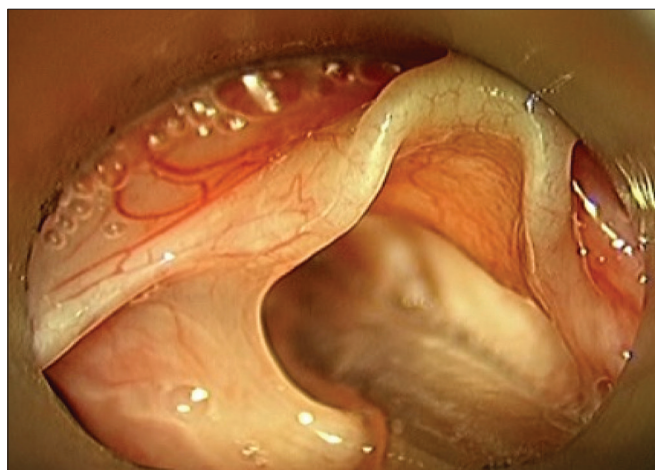

Figure 1. Intraoperative aspect of a 3 - month old child with laryngomalacia, detail of the aryepiglottic fold shortening.

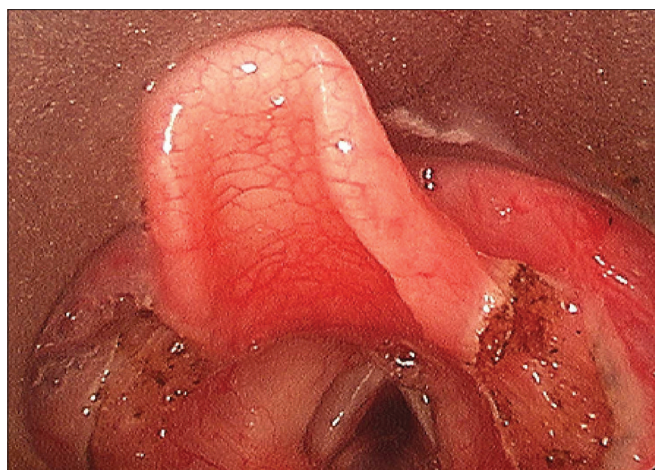


Figure 2. Post - aryepiglottoplasty with CO₂ laser.

Postoperatively, all patients were monitored in the intensive care unit. Five patients were extubated after a 48-hour period, four in the immediate post-op and two cases had extubation after 3 and 9 days, respectively.

Only one patient (9.1%) submitted to cold aryepiglottoplasty and extubated in the immediate postoperative period, there was airway obstruction recurrence, which required a new surgical approach, this time using the CO₂ laser.

There were no cases of surgical complications. All patients had significant stridor and respiratory distress.

Data such as age, gender, signs/symptoms, associated disorders, surgery, extubation time, length of hospital stay and clinical outcomes are described on Table 1.

DISCUSSION

Consistent with the medical literature, there was a predominance of laryngomalacia cases among male patients^{2,17}. The inspiratory stridor was considered the most important symptom of the disease, being present in all patients.^{1,6}

Table 1. Results.

Cases	Age	Gender	Signs/Symptoms	Associated diseases	Surgical treatment	Extubation	Hospital stay	Clinical Outcome
1	3 months	M	Stridor, dyspnea, cyanosis	Hypoxic ischemic encephalopathy, renal failure, bronchopulmonary dysplasia	Bilateral aryepiglottoplasty with CO ₂ laser and vaporization of the lingual face of the epiglottis	48h	34 days	Progressive symptom improvement
2	2 months	M	Stridor, dyspnea, cyanosis	No	Bilateral aryepiglottoplasty with the CO ₂ laser	Immediate post-op	1 day	Progressive symptom improvement
3	3 months	F	Stridor, furcula retraction, dyspnea, cyanosis	Hypoxic encephalopathy, ischemic hypoxia	Bilateral aryepiglottoplasty with the CO ₂ laser	48h	7 days	Progressive symptom improvement
4	1 Month	M	Cyanosis, apnea, insufficient weight gain	Gastroesophageal reflux disease (GERD)	Cold bilateral aryepiglottoplasty + epiglottoplasty and removal of the redundant arytenoid mucosa with the CO ₂ laser	48h	35 days	Progressive symptom improvement
5	2 months	M	Dyspnea, bronchospasm	No	1 - Cold bilateral aryepiglottoplasty. 2 - Bilateral aryepiglottoplasty with the CO ₂ laser	Immediate postop. Re-intubation after 3 days for respiratory distress	100 days	Need for reintervention and Progressive symptom improvement
6	2 months	M	Stridor, furcula retraction, intercostal retraction	Down syndrome, GERD	Cold bilateral aryepiglottoplasty	Immediate post-op	20 days	Progressive symptom improvement
7	4 months	M	Dysphagia, Stridor, furcula retraction, intercostal retraction	Interatrial communication	Cold bilateral aryepiglottoplasty	48h	31 days	Progressive symptom improvement
8	10 months	M	Stridor, bronchospasm	None	Cold bilateral aryepiglottoplasty	Immediate postop	12 days	Progressive symptom improvement
9	12 months	F	Respiratory distress	None	Cold bilateral aryepiglottoplasty	72h	20 days	Progressive symptom improvement
10	8 months	M	Dysphagia	GERD	Bilateral Aryepiglottoplasty and CO ₂ laser epiglottoplasty	9 days	35 days	Microaspiration
11	3 months	M	Stridor, Respiratory failure	None	Bilateral Aryepiglottoplasty and CO ₂ laser epiglottoplasty	48h	23 days	Progressive symptom improvement

In the preoperative classification of laryngomalacia, we rely on clinical signs, i.e., the severity of the disease and not the anatomical classification presented by Holinger & Konior¹⁸. Most authors indicate the procedure in cases of severe laryngomalacia.^{1,2} Likewise, we indicated the surgical procedure based on a number of factors, including the development delays, feeding issues, severe gastroesophageal reflux, and especially the manifestations resulting from airway obstruction.

Although the results presented in the literature are statistically similar with respect to the use of CO₂ laser and the cold approach¹⁹, in our experience the CO₂ laser offers lower risk of intraoperative bleeding and postoperative edema in cases of greater mucosal resection, as in epiglottoplasty and arytenoidoplasty. Clinical outcome was favorable in all our patients, regardless of the technique and instruments employed. We also emphasize that we have no experience in the treatment of laryngomalacia by the potassium-titanium-phosphate (KTP) laser²⁰ or microdebrider¹⁹, as per suggested by some authors.

The first study to systematically examine the unilateral supraglottoplasty was published in 1995 by Kelly & Gray²¹. The authors had a successful surgery in 94% of cases without major complications in a study involving 18 patients. Only three patients required a bilateral aryepiglottic fold approach. Loke et al.¹⁹ performed the technique bilaterally in 33 patients, with complete resolution of stridor in 22 cases (68.7%), partial resolution in seven (21.8%), re-operation surgery in two patients; and one patient with multiple malformations underwent tracheostomy. Considering the 19% to 45% rate of surgical revisions described in the literature⁴ - with an even higher percentage of unilateral supraglottoplasty cases⁸, we adopt the bilateral aryepiglottoplasty as the procedure of choice at our institution. Thus, the epiglottoplasty and arytenoidoplasty are kept as a complementary method to aryepiglottoplasty, when this alone is not sufficient to improve the supraglottic obstruction.

Complications of supraglottoplasty include bleeding, infection, edema, aspiration, dysphagia, supraglottic stenosis, synechia, respiratory failure and death^{2,4,14,22}. Denoyelle et al.⁵ reported a 7.4% complication rate in 136 patients undergoing bilateral supraglottoplasty, and five patients developed supraglottic stenosis. Although this risk has been hypothesized, current studies indicate excessive removal of laryngeal tissues rather than bilateral aryepiglottoplasty²³ as the main risk factor for the occurrence of complications. No major complication was described in our study.

Schroeder et al.²⁴ warned that the risk of liquid aspiration during the pharyngeal phase of swallowing is

more common in patients undergoing supraglottoplasty by CO₂ laser, the main risk factor for the presence of preoperative aspiration. In our study, only one patient underwent aryepiglottoplasty with epiglottoplasty presented with transient aspiration with improvements after the conservative approach.

In a review of 84 cases O'Donnell et al.²⁵ concluded that the majority of patients submitted to aryepiglottoplasty to treat laryngomalacia are able to return home after an overnight stay at the hospital. We have not adopted this recommendation, believing it to be prudent monitoring patients in intensive care unit for a minimum of 24 hours, even in cases of extubation immediately after surgery. This provides further support for possible cases of airway obstruction and lower anxiety by relatives.

Toynton et al.¹¹ reported an incidence of 47%, and Friedman et al.²⁶ reported an incidence of 65% of synchronous airway lesions, especially in patients with severe laryngomalacia undergoing supraglottoplasty, this being one of the possible causes of treatment failure. Although this index is quite considerable, we do not generalize the use of bronchoscopy as a means of diagnosis, being a test of exception. Our diagnosis is based on clinical and nasal-laryngoscopy findings. There were no cases of synchronous lesions in our patients.

Finally, the diagnosis of laryngomalacia is not commonly observed in the general population, being restricted mostly to the tertiary level of care¹¹, with spontaneous resolution in most cases²⁷⁻³⁰. The success rate of supraglottoplasty described in the literature varies from 38% to 100%⁴. In our series, the clinical improvement of all patients submitted to surgical treatment ensured a success rate of 100% of cases.

CONCLUSION

Supraglottoplasty proved to be an effective procedure in the treatment of respiratory obstruction, enlarging the laryngeal lumen. Due to its high resolution and low complication rate, it is a safe procedure in the treatment of children with severe laryngomalacia, ensuring clinical improvement for the patients.

REFERENCES

1. Valera FC, Tamashiro E, de Araújo MM, Sander HH, Küpper DS. Evaluation of the efficacy of supraglottoplasty in obstructive sleep apnea syndrome associated with severe laryngomalacia. *Arch Otolaryngol Head Neck Surg.* 2006;132(5):489-93. PMID: 16702563 DOI: <http://dx.doi.org/10.1001/archotol.132.5.489>
2. Lee KS, Chen BN, Yang CC, Chen YC. CO₂ laser supraglottoplasty for severe laryngomalacia: a study of symptomatic improvement. *Int J Pediatr Otorhinolaryngol.* 2007;71(6):889-95. PMID: 17416423 DOI: <http://dx.doi.org/10.1016/j.ijporl.2007.02.010>

3. Bluestone CD, Healy GB, Cotton RT. Diagnosis of laryngomalacia is not enough! *Arch Otolaryngol Head Neck Surg.* 1996;122(12):1417-8.
4. Day KE, Discolo CM, Meier JD, Wolf BJ, Halstead LA, White DR. Risk Factors for Supraglottoplasty Failure. *Otolaryngol Head Neck Surg.* 2011; [Epub ahead of print].
5. Denoyelle F, Mondain M, Gresillon N, Roger G, Chaudre F, Garabedian EN. Failures and complications of supraglottoplasty in children. *Arch Otolaryngol Head Neck Surg.* 2003;129(10):1077-80. DOI: <http://dx.doi.org/10.1001/archotol.129.10.1077>
6. Werner JA, Lippert BM, Dünne AA, Ankermann T, Folz BJ, Seyberth H. Epiglottopexy for the treatment of severe laryngomalacia. *Eur Arch Otorhinolaryngol.* 2002;259(9):459-64. PMID: 12386747
7. Richter GT, Thompson DM. The surgical management of laryngomalacia. *Otolaryngol Clin North Am.* 2008;41(5):837-64. DOI: <http://dx.doi.org/10.1016/j.otc.2008.04.011>
8. Gandhi S, Oswal V, Thekedar P, Mishra P. Role of transoral CO(2) laser surgery for severe pediatric laryngomalacia. *Eur Arch Otorhinolaryngol.* 2011;268(10):1479-83. PMID: 21604072 DOI: <http://dx.doi.org/10.1007/s00405-011-1631-x>
9. Senders CW, Navarete EG. Laser supraglottoplasty for laryngomalacia: are specific anatomical defects more influential than associated anomalies on outcome? *Int J Pediatr Otorhinolaryngol.* 2001;57(3):235-44. PMID: 11223456 DOI: [http://dx.doi.org/10.1016/S0165-5876\(00\)00461-4](http://dx.doi.org/10.1016/S0165-5876(00)00461-4)
10. Zafereo ME, Taylor RJ, Pereira KD. Supraglottoplasty for laryngomalacia with obstructive sleep apnea. *Laryngoscope.* 2008;118(10):1873-7. PMID: 18641529 DOI: <http://dx.doi.org/10.1097/MLG.0b013e31817e7441>
11. Toynton SC, Saunders MW, Bailey CM. Aryepiglottoplasty for laryngomalacia: 100 consecutive cases. *J Laryngol Otol.* 2001;115(1):35-8. DOI: <http://dx.doi.org/10.1258/0022215011906966>
12. Dafico SR, Costa HO. Surgical treatment of laryngomalacia. *ACTA ORL/Técnicas em Otorrinolaringologia.* 2008;26(2):75-9.
13. Fraga JC, Schopf L, Volker V, Canani S. Endoscopic supraglottoplasty in children with severe laryngomalacia with and without neurological impairment. *J Pediatr (Rio J).* 2001;77(5):420-4. DOI: <http://dx.doi.org/10.2223/JPED.285>
14. Bourolias C, Hajjioannou J, Sobol E, Velegrakis G, Helidonis E. Epiglottis reshaping using CO₂ laser: a minimally invasive technique and its potent applications. *Head Face Med.* 2008;4:15. DOI: <http://dx.doi.org/10.1186/1746-160X-4-15>
15. Schroeder JW Jr, Bhandarkar ND, Holinger LD. S Synchronous airway lesions and outcomes in infants with severe laryngomalacia requiring supraglottoplasty. *Arch Otolaryngol Head Neck Surg.* 2009;135(7):647-51. DOI: <http://dx.doi.org/10.1001/archoto.2009.73>
16. Chan DK, Truong MT, Koltai PJ. Supraglottoplasty for occult laryngomalacia to improve obstructive sleep apnea syndrome. *Arch Otolaryngol Head Neck Surg.* 2012;138(1):50-4. DOI: <http://dx.doi.org/10.1001/archoto.2011.233>
17. Avelino MA, Liriano RY, Fujita R, Pignatari S, Weckx LL. Treatment laryngomalacia: experience with 22 cases. *Braz J Otorhinolaryngol.* 2005;71(3):330-4. PMID: 16446937
18. Holinger LD, Konior RJ. Surgical management of severe laryngomalacia. *Laryngoscope.* 1989;99(2):136-42.
19. Loke D, Ghosh S, Panarese A, Bull PD. Endoscopic division of the ary-epiglottic folds in severe laryngomalacia. *Int J Pediatr Otorhinolaryngol.* 2001;60(1):59-63. PMID: 11434955 DOI: [http://dx.doi.org/10.1016/S0165-5876\(01\)00515-8](http://dx.doi.org/10.1016/S0165-5876(01)00515-8)
20. Soong WJ, Shiao AS, Jeng MJ, Lee YS, Tsao PC, Yang CF, et al. Comparison between rigid and flexible laser supraglottoplasty in the treatment of severe laryngomalacia in infants. *Int J Pediatr Otorhinolaryngol.* 2011;75(6):824-9. PMID: 21513991 DOI: <http://dx.doi.org/10.1016/j.ijporl.2011.03.016>
21. Reddy DK, Matt BH. Unilateral vs. bilateral supraglottoplasty for severe laryngomalacia in children. *Arch Otolaryngol Head Neck Surg.* 2001;127(6):694-9. PMID: 11405871 DOI: <http://dx.doi.org/10.1001/archotol.127.6.694>
22. Fattah HA, Gaafar AH, Mandour ZM. Laryngomalacia: Diagnosis and management. *Egypt J Ear Nose Throat Allied Sci.* 2011;12(3):149-53. DOI: <http://dx.doi.org/10.1016/j.ejenta.2011.12.001>
23. Thompson DM. Abnormal sensorimotor integrative function of the larynx in congenital laryngomalacia: a new theory of etiology. *Laryngoscope.* 2007;117(6 Pt Suppl 114):1-33.
24. Schroeder JW Jr, Thakkar KH, Poznanovic SA, Holinger LD. Aspiration following CO(2) laser-assisted supraglottoplasty. *Int J Pediatr Otorhinolaryngol.* 2008;72(7):985-90. DOI: <http://dx.doi.org/10.1016/j.ijporl.2008.03.007>
25. O'Donnell S, Murphy J, Bew S, Knight LC. Aryepiglottoplasty for laryngomalacia: results and recommendations following a case series of 84. *Int J Pediatr Otorhinolaryngol.* 2007;71(8):1271-5. PMID: 17597233 DOI: <http://dx.doi.org/10.1016/j.ijporl.2007.05.001>
26. Sakakura K, Chikamatsu K, Toyoda M, Kaai M, Yasuoka Y, Furuya N. Congenital laryngeal anomalies presenting as chronic stridor: a retrospective study of 55 patients. *Auris Nasus Larynx.* 2008;35(4):527-33. PMID: 18262373 DOI: <http://dx.doi.org/10.1016/j.anl.2007.12.001>
27. Martin JE, Howarth KE, Khodaei I, Karkanevatos A, Clarke RW. Aryepiglottoplasty for laryngomalacia: the Alder Hey experience. *J Laryngol Otol.* 2005;119(12):958-60. PMID: 16354358 DOI: <http://dx.doi.org/10.1258/002221505775010904>
28. Ahmad SM, Soliman AM. Congenital anomalies of the larynx. *Otolaryngol Clin North Am.* 2007;40(1):177-91. DOI: <http://dx.doi.org/10.1016/j.otc.2006.10.004>
29. Siou GS, Jeannon JP, Stafford FW. Acquired idiopathic laryngomalacia treated by laser aryepiglottoplasty. *J Laryngol Otol.* 2002;116(9):733-5. PMID: 12437813 DOI: <http://dx.doi.org/10.1258/002221502760238073>
30. Manning SC, Inglis AF, Mouzakes J, Carron J, Perkins JA. Laryngeal anatomic differences in pediatric patients with severe laryngomalacia. *Arch Otolaryngol Head Neck Surg.* 2005;131(4):340-3. PMID: 15837904 DOI: <http://dx.doi.org/10.1001/archotol.131.4.340>