

Neurostructural brain imaging study of trait dissociation in healthy children

Amy S. Badura Brack, Marika Marklin, Christine M. Embury, Giorgia Picci, Michaela Frenzel, Alicia Klanecky Earl, Julia Stephen, Yu-Ping Wang, Vince Calhoun and Tony W. Wilson

Background

Trait dissociation has not been examined from a structural human brain mapping perspective in healthy adults or children. Non-pathological dissociation shares some features with day-dreaming and mind-wandering, but also involves subtle disruptions in affect and autobiographical memory.

Aims

To identify neurostructural biomarkers of trait dissociation in healthy children.

Method

Typically developing 9- to 15-year-olds ($n = 180$) without psychological or behavioural disorders were enrolled in the Developmental Chronnecto-Genomics (DevCoG) study of healthy brain development and completed psychological assessments of trauma exposure and dissociation, along with a structural T_1 -weighted magnetic resonance imaging. We conducted univariate ANCOVA generalised linear models for each region of the default mode network examining the effects of trait dissociation, including scanner site, age, gender and trauma as covariates and correcting for multiple comparison.

Results

We found that the precuneus was significantly larger in children with higher levels of trait dissociation but this was not related to trauma exposure. The inferior parietal volume was smaller in

children with higher levels of trauma but was not related to dissociation. No other regions of interest, including frontal and limbic structures, were significantly related to trait dissociation even before multiple comparison correction.

Conclusions

Trait dissociation reflects subtle cognitive disruptions worthy of study in healthy people and warrants study as a potential risk factor for psychopathology. This neurostructural study of trait dissociation in healthy children identified the precuneus as an essential brain region to consider in future dissociation research.

Keywords

Default mode network; mind-wandering; precuneus; magnetic resonance imaging; volumetrics.

Copyright and usage

© The Author(s), 2022. Published by Cambridge University Press on behalf of the Royal College of Psychiatrists. This is an Open Access article, distributed under the terms of the Creative Commons Attribution-NonCommercial licence (<http://creativecommons.org/licenses/by-nc/4.0>), which permits non-commercial re-use, distribution, and reproduction in any medium, provided the original article is properly cited. The written permission of Cambridge University Press must be obtained prior to any commercial use.

Dissociation is conceptualised both as a cognitive trait in the general population and as a psychological state which is linked to certain psychopathologies.¹ Non-pathological dissociation has been described as a cognitive trait involving suggestibility, fantasy proneness and daydreaming,² rather than as a psychological symptom.³ Trait dissociation has been linked to increased emotionally elaborated memories,⁴ as well as poor memory for associative material and diminished executive control.⁵ Theorists vary on their conceptualisations of dissociative experiences, some believing that these fall on a continuum from mild to pathological^{6,7} and others arguing for a taxonomic distinction between trait and pathological dissociation⁸ which may be differentially related to past trauma,⁹ however, all dissociations share some cognitive disruptions in level of awareness.¹⁰ Therefore, identifying neurostructural correlates of non-pathological dissociation may inform aspects of cognitive neuroscience in general and suggest key brain regions potentially involved in the understanding, identification and treatment of pathological dissociation. We are not aware of any brain imaging research directly assessing trait dissociation in healthy adults or children, so this exploratory study of normative dissociation in healthy children is truly novel.

Neuroimaging in pathological dissociation

This is the first neuroimaging study of trait dissociation in a healthy population and brain regions involved in normative dissociation are

unknown; however, previous studies have identified brain regions involved in people with pathological dissociation. For a comprehensive review of neurobiological findings in pathological dissociation, we direct readers to a 2021 review by Roydeva & Reinders.¹¹ This review identified 44 structural neuroimaging studies and reported that decreased volumes in limbic structures – specifically the hippocampus, basal ganglia and thalamus – are common in pathological dissociation. Very few volumetric studies have examined pathological dissociation in children or adolescents. Such studies found that dissociation correlated negatively with total corpus callosum volume in youth with post-traumatic stress disorder (PTSD);^{12,13} dissociation was not associated with superior temporal gyrus volumes in youth with PTSD;¹³ and dissociative symptoms were negatively correlated with right amygdala and positively correlated with left prefrontal volumes in adolescents with PTSD.¹⁴ The one functional study of pathological dissociation in traumatised children found that dissociation was negatively correlated with bilateral putamen activation in children with reactive attachment disorder.¹⁵ These limited findings in children again point to decreased volume or function in limbic structures and add a potential increase in prefrontal volumes in the presence of dissociation.

Roydeva & Reinders' review¹¹ also included 71 functional neuroimaging studies of pathological dissociation. Most of the reviewed studies were conducted in patient groups with PTSD or dissociative identity disorder (DID) and measured brain activity in response to emotional stimuli. Pathological dissociation is a transdiagnostic

symptom which is the defining feature of DID, dissociative amnesia and depersonalisation disorder, and is associated with PTSD and borderline personality disorder.¹⁶ Underlying the generally well-accepted aetiological role of trauma in pathological dissociation,¹⁷ pathological dissociation may function as a coping strategy allowing psychological escape from traumatic events.^{3,18} Frontolimbic alterations are the most common neuroimaging findings in trauma-related disorders¹⁹ and are consistent with theories of PTSD and DID in which midline frontal regions attempt to downregulate emotional arousal by overmodulating limbic structures.^{20,21} Roydeva & Reinders' review¹¹ supported the involvement of frontal and limbic regions in pathological dissociation – specifically the dorsomedial and dorsolateral prefrontal cortex, superior frontal regions, anterior cingulate and basal ganglia – as functional biomarkers of pathological dissociation. Notably, they also highlighted the role of posterior association areas – specifically the precuneus – in pathological dissociation.

Studying clinical populations has been the standard approach to parsing out brain regions responsible for dissociation; however, this approach is inherently and inextricably confounded by the presence of other psychopathological symptoms and trauma exposure. As a result, researchers and clinicians should consider the possibility that brain regions identified in previous neuroimaging studies of pathological dissociation in traumatised samples have likely overrepresented the importance of frontal and limbic regions, at least in non-trauma-related, non-pathological dissociation. The trauma confound in previous imaging studies is particularly concerning, as some theorists suggest that trauma exposure is of limited importance even in pathological dissociation and call for a paradigm shift away from trauma-centric views in developing a full understanding of dissociation.^{2,22} Because trauma exposure is not aetiologically required¹⁰ – nor even suspected in trait dissociation – we did not want to base the regions of interest in our current study on regions identified by previous trauma-related dissociation work. Consequently, we looked for neuroimaging research on non-pathological cognitive functions that overlap well with trait dissociation.

Daydreaming, mind-wandering and the default mode network

To that aim, Giesbrecht and colleagues² reviewed cognitive processes in dissociation and found that fantasy proneness (including daydreaming), suggestibility and subtle cognitive failures such as a lapsed attention account for a significant proportion of the variance in dissociation. Butler described normative dissociation as a 'forum for mental processing',²³ that is a passive, spontaneous absorptive experience, typically termed daydreaming, that occurs in the absence of environmentally cued cognitive demands. In her foundational article on normative dissociation, Butler¹⁰ noted that much of our stream of consciousness is filled with dissociative experiences such as daydreaming and fantasy involving a temporary separation from other mental processes. Therefore, considering constructs that have been operationally defined in previous neuroimaging research, we determined that trait dissociation shares notable commonalities with daydreaming, mind-wandering and undirected thought, all of which have been associated with default mode network (DMN) activation.^{24,25} The DMN is a network of brain regions with highly correlated mental activity when a person is awake but not engaged in task-focused work.^{26,27} Past research reports enhanced dynamic DMN functional connectivity and activity during daydreaming and mind-wandering,²⁸ and DMN connectivity was recently implicated as a potential predictor of trauma-related dissociation after controlling for psychological symptoms and trauma,²⁹ which reinforced our selection of the DMN.

Study aims

To date, brain regions structurally related to the specific concept of trait dissociation in healthy people are unknown – and very little is known about brain regions involved in any type of dissociation in child and adolescent samples. Our study goal was to identify potential neurostructural correlates of non-pathological trait dissociation in healthy children. To this aim, we designed an exploratory volumetric study of all regions in the DMN, including the hippocampus. We controlled for age, gender, scanner site and, most importantly, trauma exposure. Trauma exposure was evaluated as a covariate of interest to examine its potential interaction with dissociation in this sample.

Method

Participants

Typically developing children aged 9 to 15 years were enrolled in our Developmental Chronnecto-Genomics (DevCoG)³⁰ study of healthy brain development after obtaining parental permission and consent and participant assent. Children completed psychological assessments and underwent structural magnetic resonance imaging (MRI) ($n = 183$). Three children were excluded because of unusable data, giving a final sample of $n = 180$. The sample was evenly distributed by gender, with 94 males and 86 females, by study site, with 89 at the University of Nebraska Medical Center (UNMC) and 91 at the Mind Research Network (MRN), and by age, with an average age of 11.97 years ($s.d. = 1.73$). Children were excluded from the study if parents reported that their child ever had a diagnosis of any psychiatric or behavioural disorder, a history of traumatic brain injury or other neurological condition, or the presence of metallic implants (e.g. orthodontia). The study was approved by both study sites' institutional review boards (IRBs) and all research was conducted according to ethical principles including obtaining fully informed written parental consent and child assent. The authors assert that all procedures contributing to this work comply with the ethical standards of the relevant national and institutional committees on human experimentation and with the Helsinki Declaration of 1975, as revised in 2008. All procedures involving human participants/patients were approved by the IRBs at the University of Nebraska Medical Center in Omaha, Nebraska, USA (UNMC IRB #503-15-EP) and at the Mind Research Network in Albuquerque, New Mexico, USA.

Psychological measures

The Trauma Symptom Checklist for Children (TSCC)³¹ is a self-report measure for children aged 8–16, with scores for five clinical scales, of which we used the TSCC dissociation scale. This 10-item self-report scale includes statements such as 'Trying not to have any feelings', 'Pretending I'm somewhere else', 'My mind going empty or blank' rated on a Likert scale from 0 (never) to 3 (almost all of the time). The Cronbach's alpha for the dissociation scale in this sample was very good, at 0.80. Providing evidence of convergent validity, the TSCC dissociation scale correlates highly in adolescent samples with the Adolescent Dissociative Experiences Scale (e.g. $r = 0.79$).³²

We used a modified version of the UCLA Trauma History Profile³³ to assess the number of traumatic life events encountered by children in the study. Children answered 'yes' or 'no' to whether they had experienced each of 12 potentially traumatic events. We shortened the original 15 event measures to exclude items about sexual abuse or physical abuse that occurred specifically in the home, so that participation would be considered low risk by the IRBs. Both personally experiencing violence and witnessing violence

to family members were still assessed. The items used in the current study were: having someone close to them die; being hit, punched or kicked very hard; seeing a family member hit, punched or kicked very hard; seeing or hearing about violence to a loved one; being a victim of community violence; being in a war; being in a disaster; being in a bad accident; having a painful or scary medical procedure; seeing a dead body not at a funeral; and having anything else very scary or upsetting happen.

Structural T₁-weighted MRI

Structural T₁-weighted MRI images were acquired using a Siemens 3-Tesla Skyra (at UNMC) or a Siemens 3-Tesla TRIO (at MRN), both with 32-channel head coils and closely calibrated sequences. A three-dimensional magnetisation-prepared rapid gradient-echo (3D MP-RAGE) sequence was used with the following parameters: repetition time TR = 2400 ms; echo time TE = 1.94 ms; flip angle 8°; field of view FOV = 256 mm; slice thickness 1 mm; base resolution 256; 192 slices; voxel size 1.0 × 1.0 × 1.0 mm. The T₁-weighted structural brain images of all participants were processed using the Freesurfer software version 5.3 on a Linux Ubuntu platform (<http://surfer.nmr.mgh.harvard.edu>). Regional volumes were computed for the automatic cortical parcellation (aparc)³⁴ and automatic subcortical segmentation (aseg)³⁵ atlases in Freesurfer. We followed the ENIGMA protocol for quality assurance, which included performing visual checks of all cortical segmentations (<http://enigma.usc.edu/protocols/imaging-protocols>) and checking for motion, among other artifacts. Participants whose MRI images had large motion artifacts were excluded ($n = 3$). In addition, histograms of all regional values were computed for visual inspection. All volumes were normalised by dividing each regional volume by the total intracranial volume (TIV) per participant, to avoid the bias of head size in the volumetric measurements.³⁶

Statistical analysis

The DMN regions of interest were: the caudal middle frontal, hippocampal, inferior parietal, isthmus cingulate, medial orbital frontal, parahippocampal, posterior cingulate, precuneus, and rostral anterior cingulate regions. For each of the nine DMN

regions of interest, we conducted a univariate ANCOVA generalised linear model (GLM). Each of the models utilised the TIV-corrected volume averaged across the brain hemispheres for each structure of the DMN, which was entered as a dependent variable per model. TSCC dissociation score was the independent variable, and scanner site (UNMC or MRN), age, gender (male or female) and number of traumatic events experienced were entered as covariates. Full models were corrected using the Benjamini–Hochberg false discovery rate multiple comparison correction (denoted as BH in corrected p -values) as implemented in the $p.adjust$ function in R version 1.2.5019 on a Windows 10 platform.

Results

TSCC dissociation scale scores in the full sample ($n = 180$) ranged from 0 to 19 and averaged 5.33 (s.d. = 4.02). Both the median and modal dissociation scores were 4.00, and the sample dissociation scores had acceptable skewness and kurtosis. The pathological cut-off scores for the TSCC dissociation scale varied slightly by age and gender but centred around a score of 15.³¹ Importantly, less than 4% of our sample scored above the pathological cut-off score, supporting the non-pathological nature of dissociation in our sample. The most strongly endorsed dissociation items were daydreaming, forgetfulness, my mind going empty or blank, and going away in my mind/trying not to think. Trauma exposure scores ranged from 0 to 7 (mean 2.17, s.d. = 1.81), with the most commonly endorsed traumas including the death of a loved one, the violent or serious injury of a loved one, and being a victim of physical violence. As expected, dissociation and trauma exposure scores were significantly correlated ($r = 0.36$, $p < 0.001$).

We conducted univariate ANCOVAs for each cortical structure of the DMN using the aparc atlas³⁴ (Fig. 1) and added the subcortical hippocampus defined by the aseg atlas³⁵ for completeness. Levene's test of equality showed no significant differences in error variance in any model ($p = 0.200$ – 0.798). Significant effects were found in the precuneus ($F_{5,174} = 4.83$, $p_{BH} = 0.003$, $R^2 = 0.12$) and inferior parietal lobes ($F_{5,174} = 3.98$, $p_{BH} = 0.008$, $R^2 = 0.10$), and these results survived multiple comparison correction.

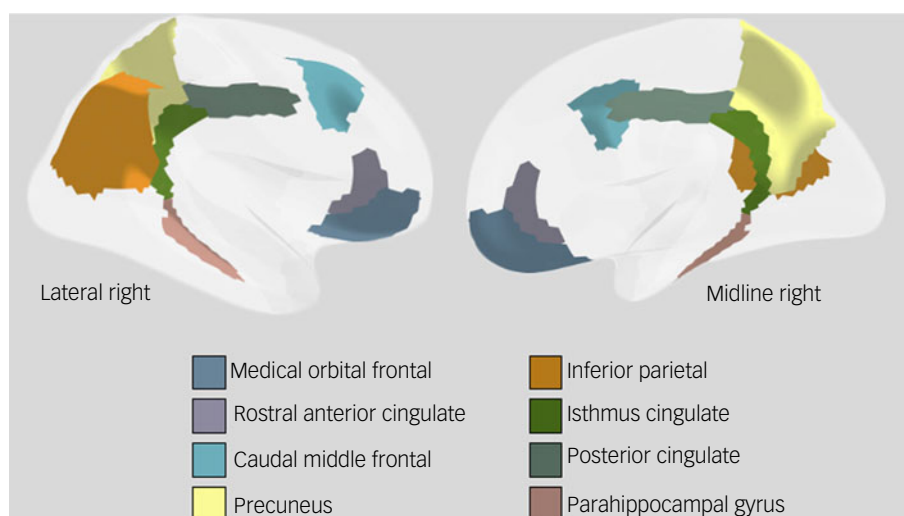


Fig. 1 Cortical default mode network regions included in this study and labelled by the (aparc) atlas. Note that we also included the hippocampus, not shown in this figure.

Table 1 ANCOVA results for precuneus and inferior parietal regions of the DMN

Predictors	Estimates	95% CI	t	p	Partial η^2
Precuneus					
Intercept	0.00934	0.00845 to 0.01023	20.78626	<0.001	0.725
Site	0.00007	-0.00017 to 0.00032	0.60292	0.547	0.002
Age	-0.00012	-0.00019 to -0.00005	-3.49982	0.001	0.066
Gender	-0.00006	-0.00029 to 0.00018	-0.46998	0.639	0.001
Trauma history	-0.00005	-0.00012 to 0.00002	-1.27660	0.203	0.009
Dissociation	0.00005	0.00002 to 0.00008	3.05445	0.003	0.051
Inferior parietal lobes					
Intercept	0.01411	0.01273 to 0.01549	20.18396	<0.001	0.713
Site	0.00016	-0.00022 to 0.00054	0.82065	0.413	0.004
Age	-0.00019	-0.00029 to -0.00008	-3.44657	0.001	0.064
Gender	-0.00011	-0.00048 to 0.00026	-0.57094	0.569	0.002
Trauma history	-0.00015	-0.00026 to -0.00004	-2.66851	0.008	0.039
Dissociation	0.00003	-0.00002 to 0.00008	1.08488	0.279	0.007

Bold denotes significant results at $p < 0.01$.

In the precuneus, dissociation significantly predicted TIV-corrected volumes ($F_{1,174} = 3.05$, $p_{BH} = 0.002$) above and beyond the covariates in the model, such that greater volumes were found in those with higher dissociation values (Table 1). Age was a significant predictor in this model, such that older age was associated with smaller TIV-corrected volumes, but no other covariate significantly predicted precuneus volumes. In the inferior parietal region, trauma but not dissociation significantly predicted TIV-corrected volumes ($F_{1,174} = 5.96$, $p_{BH} = 0.008$), such that greater numbers of traumatic events were associated with decreased volumes (Table 1). Age was also a significant predictor in this model, such that as age increased, volume decreased. The models examining the effects in caudal middle frontal ($F_{5,174} = 1.07$, $p_{BH} = 0.380$), hippocampus ($F_{5,174} = 2.81$, $p_{BH} = 0.055$), isthmus cingulate ($F_{5,174} = 1.09$, $p_{BH} = 0.380$), medial orbital frontal ($F_{5,174} = 1.89$, $p_{BH} = 0.177$), parahippocampal gyrus ($F_{5,174} = 2.18$, $p_{BH} = 0.131$), posterior cingulate ($F_{5,174} = 1.41$, $p_{BH} = 0.335$) and rostral anterior cingulate regions ($F_{5,174} = 1.25$, $p_{BH} = 0.373$) were not significant even before multiple comparison correction.

Discussion

To the best of our knowledge, this is the first structural MRI study of brain regions associated with non-pathological dissociation in healthy children. Our most important finding is that the precuneus was larger in children with higher levels of trait dissociation and that volumes in this region were not significantly related to trauma. We also found that the inferior parietal region was smaller in healthy children who had experienced more traumatic events, but this region was not associated with trait dissociation. Research on trait dissociation in healthy people is lacking; however, a meta-analysis of 24 functional neuroimaging studies of the relatively similar concept of mind-wandering²⁸ identified the importance of the precuneus/posterior cingulate cortex during this mental state. Similarly, our results are bolstered by two reviews of neuroimaging studies of pathological dissociation. Roydeva & Reinders¹¹ concluded that posterior association areas were functionally relevant in pathological dissociation, and specifically called for more research on the precuneus. In a review of pathological dissociation in borderline personality disorder, Krause-Utz et al³⁷ explicitly suggested the importance of the precuneus owing to its role in self-referential processing. Known functions of the precuneus³⁸ are consistent with the phenomenological experience of trait

dissociation, including absorption in one's internal world and alterations in one's experience of self or others,²³ so finding larger precuneus in the current study is intriguing.

Functionally, the precuneus is known to be involved in episodic memory retrieval, mental imagery, self-referential processing tasks, perspective taking and consciousness.³⁹ Interestingly, a study comparing individuals with DID with actors simulating DID found higher resting-state metabolism in regions of the DMN, including the precuneus, in those with DID, suggesting that they were more involved in self-referential thought than the actors during rest.⁴⁰ The inferior parietal region is an important association area typically involved in internal sensory processing⁴¹ and it is also active during rest, especially during self-referential thought, along with the precuneus.⁴² Nardo and colleagues⁴³ studied dissociation in a traumatised sample and controlled for the effects of psychological symptoms and trauma exposure. Contrary to our results, which found no non-pathological dissociation effect and decreased volumes with trauma exposure in the inferior parietal region, they found that both pathological and trait dissociation were associated with volumetric increases in this region.

Although negative results should be discussed with great caution, we believe it is important to note that the current study did not find any significant volumetric differences in the examined frontal,⁴³⁻⁴⁵ hippocampal^{46,47} or parahippocampal^{44,47} regions noted in previous trauma research. Interestingly, a study found that reduced hippocampal volume was related to both severity of dissociative symptoms and trauma exposure in people with PTSD and DID (who also met criteria for PTSD);⁴⁶ however, a rare study of individuals with dissociative disorders who did not meet criteria for PTSD did not find reduced hippocampal volume.⁴⁸ Perhaps structural findings related to diminished medial temporal and increased frontal volumes become apparent over the course of disorder development, or perhaps these regions are not implicated in non-pathological trait dissociation. These questions are clearly a matter for future research. For now, our absence of frontal and medial temporal findings – an absence noted even before multiple comparison correction – clearly separates our findings on trait dissociation from most work on pathological dissociation related to trauma. Although we are careful in drawing conclusions from negative findings, our results clearly call for future imaging research of dissociation in psychologically healthy individuals to avoid the trauma confound and isolate structural and functional origins of the process of normative dissociation.

In identifying some – but not unmitigated – overlap between brain areas implicated in pathological and non-pathological dissociation, and given the subtle cognitive errors noted in trait dissociation, our findings align with Loewenstein's⁴⁹ suggestion that studying dissociation may address puzzling gaps in psychology and neuroscience. These gaps are relevant for understanding not only cognitive function in general, but also pathological disorders because research suggests that mild cognitive impairments may pose a potential risk for PTSD or dissociative disorder in healthy people with high dissociation.⁵ Such risks are consistent with previous research associating alterations in the DMN with psychopathology in general,⁵⁰ and specifically structural variations in the precuneus with subclinical symptoms of clinical disorders.⁵¹

Limitations and future research

Despite the novel contribution of the current study, it has limitations. The exploratory research utilised structural MRIs in healthy children. By design, our study did not include a sample of children diagnosed with dissociative disorders. Although such a sample would certainly be smaller, replicating this study in children with dissociative disorders would improve understanding of potential structural alterations related to pathological versus non-pathological dissociation. Future neurofunctional research should include blood oxygen level-dependent (BOLD) or arterial spin labelling (ASL) perfusion or magnetencephalography resting-state studies and functional assessments specifically targeting the precuneus in healthy child and adult samples and pathological samples. Finally, our analyses are cross-sectional, so future work should examine how longitudinal changes in dissociation correspond with changes in brain structure and function. Longitudinal follow-up should also assess whether trait dissociation relates to risk for psychopathology in the current sample. Such future work would allow us to evaluate the extent to which normative dissociation is a risk or protective factor during development.

Implications

We hope our findings on non-pathological trait dissociation in children may inform brain mapping research and also inform research on transdiagnostic symptoms of pathological dissociation, independent of psychiatric diagnoses and trauma exposure. We believe the key implications of this study are the identification of a previously unknown psychological function of the precuneus and the suggestion of this structure as a promising target for future neuropsychological and psychopathological research in healthy and psychopathological groups.

Amy S. Badura Brack , Department of Psychological Science, Creighton University, Omaha, Nebraska, USA; **Marika Marklin**, Department of Psychological Science, Creighton University, Omaha, Nebraska, USA; **Christine M. Embury**, Institute for Human Neuroscience, Boys Town National Research Hospital, Omaha, Nebraska, USA; and Department of Psychology, University of Nebraska – Omaha, Nebraska, USA; **Giorgia Picci**, Institute for Human Neuroscience, Boys Town National Research Hospital, Omaha, Nebraska, USA; **Michaela Frenzel**, Institute for Human Neuroscience, Boys Town National Research Hospital, Omaha, Nebraska, USA; and Department of Psychology, University of Nebraska – Omaha, Nebraska, USA; **Alicia Klanecky Earl**, Department of Psychological Science, Creighton University, Omaha, Nebraska, USA; **Julia Stephen**, The Mind Research Network, Albuquerque, New Mexico, USA; **Yu-Ping Wang**, Department of Biomedical Engineering, Tulane University, New Orleans, Louisiana, USA; **Vince Calhoun**, Tri-institutional Center for Translational Research in Neuroimaging and Data Science, Georgia State University, Georgia Institute of Technology, and Emory University, Atlanta, Georgia, USA; **Tony W. Wilson**, Institute for Human Neuroscience, Boys Town National Research Hospital, Omaha, Nebraska, USA; and Department of Psychology, University of Nebraska – Omaha, Nebraska, USA

Correspondence: Amy S. Badura Brack. Email: amybadurabrack@creighton.edu

First received 22 Dec 2021, final revision 19 Jul 2022, accepted 17 Aug 2022

Data availability

The data used in this article are openly available through the COINS framework (<https://coins.trendscenter.org/>): see data-set COINS:Dev-CoG.

Author contributions

A.S.B.B., J.S., Y.-P.W., V.C. and T.W.W. designed the study. C.M.E., G.P., M.F., J.S. and T.W.W. were involved in data acquisition. A.S.B.B., M.M., C.M.E., G.P. and T.W.W. were involved in data analysis. A.S.B.B., M.M., C.M.E. and A.K.E. were involved in data interpretation. A.S.B.B. and M.M. wrote the main draft of the paper. C.M.E., G.P., M.F., A.K.E., J.S., Y.-P.W., V.C. and T.W.W. revised the paper for important intellectual content. All authors approved the final version and agree to be accountable for the work.

Funding

This work was supported by the National Science Foundation of the USA (#1539067 and 2112455), the National Institutes of Health (R01-MH121101, R01-MH116782, P20-GM144641, R01-EB020407, R01-MH118695 and R56-MH124925) and At Ease, USA. The funders had no role in study design, data collection and analysis, decision to publish, or preparation of the manuscript.

Declaration of interest

None.

References

- Holmes EA, Brown RJ, Mansell W, Fearon RP, Hunter EC, Frasquilho F, et al. Are there two qualitatively distinct forms of dissociation? A review and some clinical implications. *Clin Psychol Rev* 2005; **25**: 1–23.
- Giesbrecht T, Lynn ST, Lilienfeld SO, Merckelbach H. Cognitive processes in dissociation: an analysis of core theoretical assumptions. *Psychol Bull* 2008; **134**: 617–47.
- de Ruiter MB, Elzinga BM, Phaf RH. Dissociation: cognitive capacity or dysfunction? *J Trauma Dissociation* 2006; **17**: 115–34.
- Oathes DJ, Ray WJ. Dissociative tendencies and facilitated emotional processing. *Emotion* 2008; **8**: 653–61.
- Amrhein C, Hengmith S, Maragkos M, Hennig-Fast K. Neuropsychological characteristics of highly dissociative healthy individuals. *J Trauma Dissociation* 2008; **9**: 525–42.
- Hilgard ER. *Divided Consciousness: Multiple Controls in Human Thought and Action*. John Wiley & Sons, 1977.
- Bernstein EM, Putnam FW. Development, reliability, and validity of a dissociation scale. *J Nerv Ment Dis* 1986; **174**: 727–35.
- Waller NG, Putnam FW, Carlson EB. Types of dissociation and dissociative types: a taxometric analysis of dissociative experiences. *Psychol Methods* 1996; **1**: 300–21.
- Irwin HJ. Pathological and nonpathological dissociation: the relevance of childhood trauma. *J Psychol* 1999; **133**: 157–64.
- Butler LD. Normative dissociation. *Psychiatr Clin North Am* 2006; **29**: 45–62.
- Roydeva MI, Reinders A. Biomarkers of pathological dissociation: a systematic review. *Neurosci Biobehav Rev* 2021; **123**: 120–202.
- De Bellis MD, Baum AS, Birmaher B, Keshavan MS, Eccard CH, Boring AM, et al. A.E. Developmental traumatology. Part I: biological stress systems. *Biol Psychiatry* 1999; **45**: 1259–70.
- De Bellis MD, Keshavan MS, Frustaci K, Shifflett H, Iyengar S, Beers SR, et al. Superior temporal gyrus volumes in maltreated children and adolescents with PTSD. *Biol Psychiatry* 2002; **51**: 544–52.
- Mutluer T, Şar V, Kose-Demiray Ç, Arslan H, Tamer S, Inal S, et al. Lateralization of neurobiological response in adolescents with post-traumatic stress disorder related to severe childhood sexual abuse: the Tri-Modal Reaction (T-MR) model of protection. *J Trauma Dissociation* 2018; **19**: 108–25.
- Mizuno K, Takiguchi S, Yamazaki M, Asano M, Kato S, Kuriyama K, et al. Impaired neural reward processing in children and adolescents with reactive attachment disorder: a pilot study. *Asian J Psychiatr* 2015; **17**: 89–93.
- Lyssenko L, Schmahl C, Bockhacker L, Vonderlin R, Bohus M, Kleindienst N. Dissociation in psychiatric disorders: a meta-analysis of studies using the dissociative experiences scale. *Am J Psychiatry* 2018; **175**: 37–46.
- Bremner JD. Cognitive processes in dissociation: comment on Giesbrecht et al. (2008). *Psychol Bull* 2010; **136**: 1–11.
- Dalenberg CJ, Brand BL, Gleaves DH, Dorahy MG, Loewenstein RG, Cardeña E, et al. Evaluation of the evidence for the trauma and fantasy models of dissociation. *Psychol Bull* 2012; **138**: 550–88.

- 19 Pitman RK, Rasmusson AM, Koenen KC, Shin LM, Orr SP, Gilbertson MW, et al. Biological studies of post-traumatic stress disorder. *Nat Rev Neurosci* 2012; **13**: 769–87.
- 20 Lanius RA, Vermetten E, Loewenstein RJ, Brand B, Schmahl C, Bremner JD, et al. Emotion modulation in PTSD: clinical and neurobiological evidence for a dissociative subtype. *Am J Psychiatry* 2010; **167**: 640–7.
- 21 Reinders AA, Willemsen AT, den Boer JA, Vos HP, Veltman DJ, Loewenstein RJ. Opposite brain emotion-regulation patterns in identity states of dissociative identity disorder: a PET study and neurobiological model. *Psychiatry Res* 2014; **223**: 236–43.
- 22 Giesbrecht T, Lynn ST, Lilienfeld SO, Merckelbach H. Cognitive processes, trauma, and dissociation—misconceptions and misrepresentations: reply to Bremner (2010). *Psychol Bull* 2010; **136**: 7–11.
- 23 Butler LD. The dissociations of everyday life. *J Trauma Dissociation* 2004; **5**(2): 1–11.
- 24 Christoff K. Undirected thought: neural determinants and correlates. *Brain Res* 2012; **1428**: 51–9.
- 25 Smallwood J, Schooler JW. The science of mind wandering: empirically navigating the stream of consciousness. *Annu Rev Psychol* 2015; **66**: 487–518.
- 26 Fox MD, Snyder AZ, Vincent JL, Corbetta M, Van Essen DC, Raichle ME. The human brain is intrinsically organized into dynamic, anticorrelated functional networks. *Proc Natl Acad Sci USA* 2005; **102**: 9673–8.
- 27 Raichle ME, Snyder AZ. A default mode of brain function: a brief history of an evolving idea. *Neuroimage* 2007; **37**: 1083–99.
- 28 Fox KC, Spreng RN, Ellamil M, Andrews-Hanna JR, Christoff K. The wandering brain: meta-analysis of functional neuroimaging studies of mind-wandering and related spontaneous thought processes. *Neuroimage* 2015; **111**: 611–21.
- 29 Lebois LAM, Li M, Baker JT, Wolff JD, Wang D, Lambros AM, et al. Large-scale functional brain network architecture changes associated with trauma-related dissociation. *Am J Psychiatry* 2021; **178**: 165–73.
- 30 Stephen JM, Solis I, Janowich J, Stern M, Frenzel MR, Eastman JA, et al. The Developmental Chronnecto-Genomics (Dev-CoG) study: a multimodal study on the developing brain. *Neuroimage* 2021; **225**: 117438.
- 31 Briere J. *Trauma Symptom Checklist for Children (TSCC): Professional Manual*. Psychological Assessment Resources, 1996.
- 32 Sadowski CM, Friedrich WN. Psychometric properties of the Trauma Symptom Checklist for Children (TSCC) with psychiatrically hospitalized adolescents. *Child Maltreat* 2000; **5**: 364–72.
- 33 Steinberg AM, Brymer MJ, Decker KB, Pynoos RS. The University of California at Los Angeles post-traumatic stress disorder reaction index. *Curr Psychiatry Rep* 2004; **6**: 96–100.
- 34 Desikan RS, Ségonne F, Fischl B, Quinn BT, Dickerson BC, Blacker D, et al. An automated labeling system for subdividing the human cerebral cortex on MRI scans into gyral based regions of interest. *Neuroimage* 2006; **31**: 968–80.
- 35 Fischl B, Salat DH, Busa E, Albert M, Dieterich M, Haselgrove C, et al. Whole brain segmentation: automated labeling of neuroanatomical structures in the human brain. *Neuron* 2002; **33**: 341–55.
- 36 Whitwell JL, Crum WR, Watt HC, Fox NC. Normalization of cerebral volumes by use of intracranial volume: implications for longitudinal quantitative MR imaging. *AJNR Am J Neuroradiol* 2001; **22**: 1483–9.
- 37 Krause-Utz A, Frost R, Winter D, Elzinga BM. Dissociation and alterations in brain function and structure: Implications for borderline personality disorder. *Curr Psychiatry Rep* 2017; **19**: 6.
- 38 Fransson P, Marrelec G. The precuneus/posterior cingulate cortex plays a pivotal role in the default mode network: evidence from a partial correlation network analysis. *Neuroimage* 2008; **42**: 1178–84.
- 39 Cavanna AE, Trimble MR. The precuneus: a review of its functional anatomy and behavioural correlates. *Brain* 2006; **129**: 564–83.
- 40 Schlumpf YR, Reinders AA, Nijenhuis ER, Luechinger R, van Osch MJ, Jäncke L. Dissociative part-dependent resting-state activity in dissociative identity disorder: a controlled fMRI perfusion study. *PLoS One* 2014; **9**(6): e98795.
- 41 Igelström KM, Graziano MSA. The inferior parietal lobule and temporoparietal junction: a network perspective. *Neuropsychologia* 2017; **105**: 70–83.
- 42 Davey CG, Pujol J, Harrison BJ. Mapping the self in the brain's default mode network. *Neuroimage* 2016; **132**: 390–7.
- 43 Nardo D, Högberg G, Lanius RA, Jacobsson H, Jonsson C, Hällström T, et al. Gray matter volume alterations related to trait dissociation in PTSD and traumatized controls. *Acta Psychiatr Scand* 2013; **128**: 222–33.
- 44 Meng Y, Qiu C, Zhu H, Lama S, Lui S, Gong Q, et al. Anatomical deficits in adult posttraumatic stress disorder: a meta-analysis of voxel-based morphometry studies. *Behav Brain Res* 2014; **270**: 307–15.
- 45 Ehling T, Nijenhuis ER, Krikke AP. Volume of discrete brain structures in complex dissociative disorders: preliminary findings. *Prog Brain Res* 2007; **167**: 307–10.
- 46 Chalavi S, Vissia EM, Giesen ME, Nijenhuis ER, Draijer N, Cole JH, et al. Abnormal hippocampal morphology in dissociative identity disorder and post-traumatic stress disorder correlates with childhood trauma and dissociative symptoms. *Hum Brain Mapp* 2015; **36**: 1692–704.
- 47 Badura-Brack AS, Mills MS, Embury CM, Khanna MM, Klanecky Earl A, Stephen JM, et al. Hippocampal and parahippocampal volumes vary by sex and traumatic life events in children. *J Psychiatry Neurosci* 2020; **45**: 288–97.
- 48 Weniger G, Lange C, Sachsse U, Irle E. Amygdala and hippocampal volumes and cognition in adult survivors of childhood abuse with dissociative disorders. *Acta Psychiatr Scand* 2008; **118**: 281–90.
- 49 Loewenstein RJ. Dissociation debates: everything you know is wrong. *Dialogues Clin Neurosci* 2018; **20**: 229–42.
- 50 Andrews-Hanna JR, Smallwood J, Spreng RN. The default network and self-generated thought: component processes, dynamic control, and clinical relevance. *Ann N Y Acad Sci* 2014; **1316**: 29–52.
- 51 Besteher B, Gaser C, Nenadić I. Brain structure and subclinical symptoms: A dimensional perspective of psychopathology in the depression and anxiety spectrum. *Neuropsychobiology* 2016; **79**: 270–83.

