

## Two cases of paralytic ileus in onco-hematologic patients

Francesca Carraro, Elisa Rivetti,  
Erica Romano, Franca Fagioli

Pediatric Onco-Hematology, Stem Cell Transplantation and Cellular Therapy Division, Regina Margherita Children's Hospital, Turin, Italy

### Abstract

Paralytic ileus is a severe complication resulting from a variety of disorders. It occurs most commonly in patients with serious underlying medical or surgical conditions. Prompt diagnosis and appropriate management may improve the outcome. We describe 2 cases of onco-hematologic patients who presented this complication after intensive chemotherapy.

### Introduction

Paralytic ileus is a gastrointestinal motility disorder. It is rare in childhood, but severe complications result from a variety of disorders.<sup>1,2</sup> This condition results in colonic atony deriving from an imbalance in autonomic bowel innervation. Patients with trauma, electrolyte disturbances, medications affecting gastrointestinal motility and sepsis, are predisposed to its development. The principal ileus symptoms are abdominal pain and distention, constipation, failure to pass gas or stool, and vomiting. Diagnosis is based on clinical presentation with X-ray evidence of marked colonic dilatation in the absence of a mechanical obstruction. Without treatment, the patient's general conditions rapidly worsen until dehydration and shock.

We describe 2 cases of onco-hematologic patients who presented this acute complication after intensive chemotherapy.

### Case #1

VG is a 5-year old girl with a non-Hodgkin's abdominal lymphoma which was diagnosed in March 2011 by abdominal surgery for intestinal invagination. She was enrolled on the AIEOP (Italian Association of Pediatric Hematology Oncology) LNH 97 protocol. At the end of a chemotherapy cycle, in disease remission, she developed severe abdominal pain and distension with constipation, vomiting, and fever. Blood tests showed an increase in absolute

leukocyte number and C-reactive protein. Intestinal pseudo-obstruction was confirmed both clinically and by X-ray (Figure 1). Broad-spectrum antibiotic therapy (meropenem, metronidazole, vancomycin, fluconazol), a nasogastric decompression and parenteral nutrition were performed. However, two days later, her general condition worsened with aplasia (PMN 130/mmc), severe abdominal pain, distension, hyponatremia and fever. Therapy with G-CSF was started. An abdominal computed tomography scan (CT) revealed significant cecal dilatation without mechanical obstruction with residual fecal loading.

Therefore, four days after the end of chemotherapy, she underwent surgery with an intestinal resection for ileitis with a pseudovolvulus. Ileostomy was not performed because important mucosal damage made surgery impossible. The histological examination was negative for the baseline disease. Cultural specimens were negative. Only urine culture was positive for *E. coli* ESBL positive. Her general condition gradually improved over the following days. Supportive therapy was, therefore, continued.

Six days after surgery, her condition worsened again with fever, desaturation and gastric pain. Chest X-ray showed a bilateral pleural effusion. The girl was transferred to the intensive care unit with invasive ventilation support. Antibiotic therapy was changed with colimicina, cefepime and linezolid. Her general condition was still poor. Maternal leukocyte infusion was carried out. Over the following days, her clinical condition improved. Six days later, she was extubated with no recurrent abdominal pain or fever and normal leukocyte count. Enteral nutrition was gradually restarted without any complications. She presented regular bowel function. Five days later, 32 days after onset, she was discharged from hospital in good general condition.

She continued the chemotherapy protocol until July 2011. She is now in good general condition in complete disease remission.

### Case #2

GM was diagnosed at the age of 18 with a B-cell acute lymphoblastic leukemia (ALL), central nervous system (CNS) negative, one month after traumatic abdominal injuries due to a car accident. He started treatment according to the AIEOP LLA R 2006 protocol with good disease response (blasts < 1000/UL) after eight days.

Induction therapy was immediately complicated by asthenia, nausea, and constipation treated with antiemetic, oral laxatives and rectal enemas with transient relief. After 3 doses of VCR (vincristine), he developed severe

Correspondence: Carraro Francesca, Onco-Hematology, Stem Cell Transplantation and Cellular Therapy Division, Regina Margherita Children's Hospital, Turin, Italy.  
E-mail: francesca.carraro80@libero.it

Key words: paralytic ileus, onco-hematologic patients, pediatric.

Received for publication: 3 November 2011.

Revision received: 15 November 2011.

Accepted for publication: 18 November 2011.

This work is licensed under a Creative Commons Attribution NonCommercial 3.0 License (CC BY-NC 3.0).

©Copyright F. Carraro et al., 2012

License PAGEPress, Italy

Pediatric Reports 2012; 4:e3

doi:10.4081/pr.2012.e3

abdominal pain with marked constipation associated with weight loss. X-ray of the abdomen showed gas/fluid-levels scattered throughout the abdomen. Blood count showed pancytopenia (PMN 90/mmc). Parenteral therapy was started with hydration, antibiotics (piperacilline/tazobactam, amikacine) and antifungal (fluconazol). Rectal enemas still had transient relief. Stool cultural examinations were negative, C-reactive protein was slightly raised.

Five days later he presented severe abdominal and left scapular pain with nausea, vomiting and fever. Physical examination showed abdominal distention. The X-ray of the abdomen showed free gas in the abdominal cavity (left hypochondrium). According the suspicious of intestinal perforation due to paralytic ileus and mucositis, the patient underwent emergency surgery. Perforations in the ileo cecal valve and cecum end were found and repaired, associated with an important dilatation in the proximal ileus and a temporary ileostomy was needed. The peritoneal culture was positive for *Enterococcus faecalis* and *Prevotella oralis*.

After surgery, the leukocyte count increased and the patient's condition improved. Broad-spectrum antibiotics (meropenem, vancomycin, metronidazole), antifungal therapy (fluconazol), and continuous hydration with close monitoring of electrolytes were continued. He was transferred to the Pediatric Onco-Hematology Division 12 days after surgery. At Day 46 a bone marrow showed the remission of disease. On Day 58, after an improvement in his general clinical condition, chemotherapy was restarted.

Enteral nutrition was gradually restarted and bowel function reestablished. He was discharged from hospital two weeks later with ileostomy. He is now in good clinical condition

in complete disease remission and is continuing chemotherapy.

## Discussion

Paralytic ileus is associated with infections or disorders of autonomic neuropathy caused by chemotherapy drugs, such as vincristine and vinblastine or opioid, which depress bowel peristalsis.

VCR gastrointestinal toxicity seems to be dose-related and cumulative.<sup>3</sup> Co-administration of several drugs which interfere with VCR metabolism and elimination can increase drug-related toxicity.<sup>2,4,5</sup> VCR is metabolized by the hepatic CYP3A subfamily of enzymes and then mainly eliminated by biliary excretion. Several polymorphisms of CYP3A5 with variable phenotypic expression have been described and might be of importance when considering the potential implication of drug interactions. According to this genetic variability, in some patients, several drugs, such as azole antifungals or nifedipine might increase VCR exposure. Macrolides and steroids have also been mentioned as interfering with VCR metabolism, as either inhibitors, inducers, or both.<sup>2,5</sup>

However, in pediatric patients, VCR-related pseudo-obstruction seems to be reversible and even allows chemotherapy to be continued. The implications of genetic polymorphisms in the CYP3A and MDR1 genes are not clear or feasible in all patients.<sup>6</sup>

There is little awareness of this condition and a lack of guidance for both diagnosis and management. Prompt diagnosis and appropriate management of these patients may reduce the significant morbidity and mortality seen in this uncommon condition. The outcome of ileus varies depending on its cause.<sup>1</sup> Initial management is conservative with bowel rest and nasogastric decompression, intravenous fluids and correction of electrolyte imbalance, cessation of medications affecting colonic motility.<sup>1,7</sup> Especially in onco-hematologic patients the prompt treatment with broad spectrum antibiotics and antifungals is recommended to improve the outcome.

Surgical intervention to remove the cause of ileus is necessary when the obstruction is complete or the bowel is likely to become gangrenous. The type of surgical procedure depends on the condition of the bowel and the cause of the obstruction. In some cases, ileostomy or colostomy, either temporary or permanent, may be necessary.<sup>1,7</sup>

Here we describe 2 oncologic pediatric cases

who developed acute colonic pseudo-obstruction during intensive chemotherapy. Both patients underwent intensive chemotherapy cycles with damage to gut mucosae, and alterations in bowel function during a prolonged bone marrow depression. While in the first case the previous surgery was a relevant risk factor, in the second case the high-dose steroid therapy caused concomitant gastric mucosa damage and abdominal distension associated with a bowel atony due to VCR. Genetic polymorphisms were not assessed in our patients. In both cases, the prompt therapy with intravenous fluid, nasogastric decompression and antibiotic therapy improved the outcome, although both patients needed a multidisciplinary approach with surgery, carefully controlled electrolytic imbalance and sepsis status.

## References

1. M Jessop, K Choo, M Little. Acute colonic pseudo-obstruction in paediatric oncology patients. *J Paed Child Health* 2010;46:696-701.
2. M Diezi, A Nydegger, E R. Di Paolo, et al. Vincristine and Intestinal Pseudo-obstruction in Children Report of 5 Cases, Literature Review, and Suggested Management. *J Pediatr Hematol Oncol* 2010;32:e126-e130.
3. Stones DK. Vincristine overdosage in paediatric patients. *Med Pediatr Oncol.* 1998; 30:193.
4. Bermudez M, Fuster JL, Llinares E, et al. Itraconazole-related increased vincristine neurotoxicity: case report and review of literature. *J Pediatr Hematol Oncol* 2005;27:389-92.
5. Zhou SF, Xue CC, Yu XQ, et al. Clinically important drug interactions potentially involving mechanism-based inhibition of cytochrome P450 3A4 and the role of therapeutic drug monitoring. *Ther Drug Monit* 2007;29:687-710.
6. Eliasson E. Ethnicity and adverse drug reactions. *BMJ* 2006;332:1163-4.
7. Saunders M, Kimmey M. Systematic review: acute colonic pseudo-obstruction. *Aliment Pharmacol Ther* 2005;22:917-25.

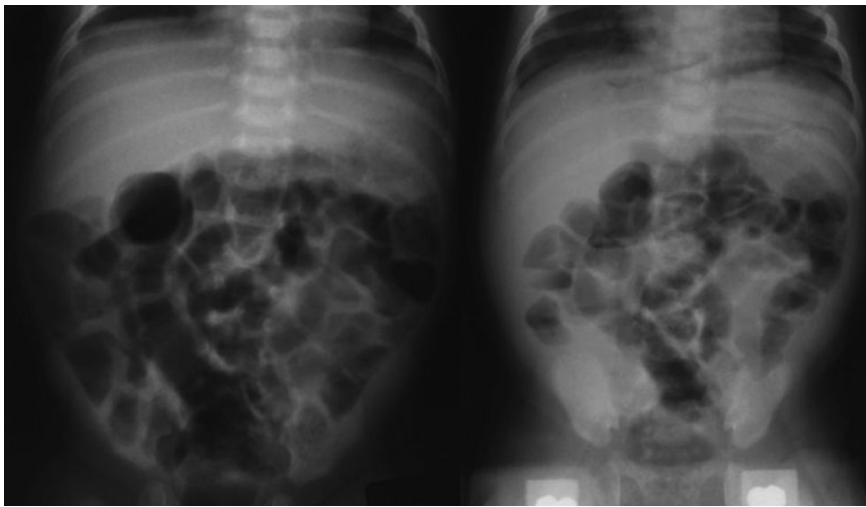


Figure 1. Intestinal pseudo-obstruction confirmed by X-ray.