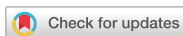









Original Article
Internal Medicine



Astrocyte lesions in cerebral cortex and cerebellum of dogs with congenital portosystemic shunting

Alun Williams ¹, Adam Gow ², Scott Kilpatrick ², Mickey Tivers ^{3,†}, Vicky Lipscomb ⁴, Ken Smith ⁵, Michael Oliver Day ³, Nick Jeffery ⁶, Richard John Mellanby ^{2,*}

¹Department of Veterinary Medicine, University of Cambridge, Cambridge, CB3 0ES, United Kingdom

²Royal (Dick) School of Veterinary Studies and The Roslin Institute, The University of Edinburgh, Edinburgh, EH25 9RG, United Kingdom

³Bristol Veterinary School, University of Bristol, Bristol, BS40 5DU, United Kingdom

⁴Department of Clinical Sciences and Services, Royal Veterinary College, London, AL97TA, United Kingdom

⁵Department of Pathobiology and Population Sciences, Royal Veterinary College, London, AL97TA, United Kingdom

⁶Department of Small Animal Clinical Studies, Texas A&M University, College Station, TX 77843-4474, USA

 OPEN ACCESS

Received: Nov 5, 2019

Revised: Mar 18, 2020

Accepted: Mar 23, 2020

*Corresponding author:

Richard John Mellanby

Royal (Dick) School of Veterinary Studies and The Roslin Institute, The University of Edinburgh, Roslin, Midlothian, Edinburgh, EH25 9RG, United Kingdom.

E-mail: Richard.Mellanby@ed.ac.uk

†Current address: Paragon Veterinary Referrals, Wakefield, WF1 2DF, United Kingdom

© 2020 The Korean Society of Veterinary Science

This is an Open Access article distributed under the terms of the Creative Commons Attribution Non-Commercial License (<https://creativecommons.org/licenses/by-nc/4.0>) which permits unrestricted non-commercial use, distribution, and reproduction in any medium, provided the original work is properly cited.

ORCID iDs

Alun Williams 


<https://orcid.org/0000-0002-8158-7194>

Adam Gow 


<https://orcid.org/0000-0002-4297-8870>

Scott Kilpatrick 

<https://orcid.org/0000-0002-6830-3142>

Mickey Tivers 

<https://orcid.org/0000-0001-7047-9334>

Vicky Lipscomb 

<https://orcid.org/0000-0001-8427-5885>

<https://vetsci.org>

ABSTRACT

Background: Congenital portosystemic shunt (cPSS) is one of the most common congenital disorders diagnosed in dogs. Hepatic encephalopathy (HE) is a frequent complication in dogs with a cPSS and is a major cause of morbidity and mortality. Despite HE been a major cause of morbidity in dogs with a cPSS, little is known about the cellular changes that occur in the central nervous system of dogs with a cPSS.

Objectives: The objective of this study was to characterise the histological changes in the cerebral cortex and cerebellum of dogs with cPSS with particular emphasis on astrocyte morphology.

Methods: Eight dogs with a confirmed cPSS were included in the study.

Results: Six dogs had substantial numbers of Alzheimer type II astrocytes and all cases had increased immunoreactivity for glial fibrillary acidic protein in the cerebral cortex, even if there were minimal other morphological changes.

Conclusions: This study demonstrates that dogs with a cPSS have marked cellular changes in the cerebral cortex and cerebellum. The cellular changes that occur in the cerebral cortex and cerebellum of dogs with spontaneously arising HE are similar to changes which occur in humans with HE, further validating dogs with a cPSS as a good model for human HE.

Keywords: Astrocytes; hepatic encephalopathy; dogs; portosystemic

INTRODUCTION

Congenital portosystemic shunt (cPSS) is one of the most common congenital abnormalities diagnosed in dogs [1]. Dogs with a cPSS usually have a single, extra-hepatic vessel that links the portal vein and the caudal vena cava, although a range of intrahepatic and extrahepatic vascular abnormalities have been described [2,3]. Dogs with a cPSS can present with a wide range of clinical signs such as poor growth and stunted development, gastrointestinal or urinary tract abnormalities or a range of neurological disturbances that are termed 'hepatic encephalopathy' (HE) [3-5]. Dogs can be screened with good sensitivity and specificity for

Ken Smith 

<https://orcid.org/0000-0002-4861-7048>

Michael Oliver Day 

<https://orcid.org/0000-0002-7947-8204>

Nick Jeffery 

<https://orcid.org/0000-0002-9812-1788>

Richard John Mellanby 

<https://orcid.org/0000-0002-3467-7007>

Conflict of Interest

The authors have no conflicts of interest to declare.

Author Contributions

Conceptualization: Williams A, Gow A.

cPSS by measurement of serum bile acids and ammonia [6] and the abnormal vessel can be definitively identified in almost all cases by either abdominal ultrasonography, computed tomography or magnetic resonance imaging [7-9].

HE is one of the most significant complications observed in dogs with a cPSS. The clinical signs range from mild lethargy to ataxia, disorientation through to stupor and coma. Medical management with therapies such as lactulose and antibiotics or surgical attenuation of the aberrant vessel can improve HE in most dogs with a cPSS [10-12]. However, persistence or recurrence of HE following either medical or surgical treatment is one of the most common reasons why dogs with a cPSS are euthanased [3,10-12]. Furthermore, in a small proportion of dogs with a cPSS treated by surgery, the neurological signs can dramatically worsen post attenuation [13-17].

As HE is such a significant cause of morbidity and mortality in dogs with a cPSS, there is clear interest in understanding more about the underlying pathophysiology of HE. Ammonia has long been implicated in the development of HE and it has been shown that dogs with cPSS and HE have significantly higher ammonia concentrations than dogs with cPSS and no HE [18]. Further evidence that increased concentrations of ammonia is an important aspect of the pathophysiology of HE is the concept that ammonia crossing the blood-brain barrier is absorbed and metabolised by astrocytes as they synthesise glutamine from glutamate. The increased levels of cerebral glutamine leads to an increased osmotic pressure in the astrocytes that then become swollen. Histologically, this can be detected as single, paired, or larger groups of astrocytes with pale nuclei, termed 'Alzheimer type II astrocytes' [19,20]. However, the raised blood ammonia levels do not always correlate with the severity of clinical signs and other putative toxic factors such as glutamine [21], excitatory amino acids and/or mercaptans have been proposed as key molecules responsible for the neuronal dysfunction that leads to clinical signs of HE [22].

Recent studies have demonstrated that dogs with a cPSS and HE have a greater systemic inflammatory response than dogs with a cPSS and no HE [18,23,24]. In addition, systemic inflammation declines following successful treatment of HE [25]. Whole blood manganese, which is a potent neurotoxin, concentrations have also been found to be higher in dogs with cPSS than healthy controls. However, whole blood manganese concentrations do not differ between dogs with HE and dogs without HE and concentrations do not decline even when HE has been successfully treated [26,27]. Consequently, increased blood manganese is not considered to be a key driver of HE in dogs with cPSS.

Despite recent advances in understanding the pathophysiology of canine HE, little is known about the cellular changes that occur in the brains of dogs with HE. A small number of imaging studies have reported structural brain abnormalities in dogs with a cPSS [28-30] but no case series has been published which solely focuses on describing the histological changes in the brain of dogs with confirmed cPSS. There are only a small number of cases reported in the peer reviewed literature where these histological changes are described [14,15,31-34]. These reports typically provide short descriptions of brain pathology and describe contrasting findings with histological changes in the brain varying from extensive necrosis of neurons to generalised polioencephalomalacia [14,31]. Consequently, the aim of this study was to undertake a more detailed histological evaluation of the changes that occur in the cerebral cortex and cerebellum of a cohort of dogs with a cPSS.

MATERIALS AND METHODS

The veterinary pathology post mortem databases at the University of Edinburgh, University of Bristol, University of Cambridge and Royal Veterinary College were reviewed for cases of dogs with a confirmed cPSS. The age, breed, gender and type of cPSS were recorded. The clinical records prior to death or euthanasia were reviewed.

The paraffin wax-embedded tissue blocks used for the original pathological investigations were recut and sections (6 µm) were mounted on glass slides and stained with haematoxylin and eosin (H&E). Semi-serial sections were also immunolabelled for expression of glial fibrillary acidic protein (GFAP) (rabbit anti-cow GFAP, Z0334, Dako) and rabbit anti-cow S-100 (1:2,000, Dako Z0311) as described for HE in cases of PSS in man [35] using an indirect peroxidase method, following antigen retrieval (97°C, 20 min, citrate buffer) on a Dako Autostainer. Control brain tissue was obtained from three dogs that had been euthanized for a non-neurological disorder. The brain sections were independently evaluated by two pathologists without reference to the original pathological descriptions or diagnosis.

The presence of type II astrocytes in the cerebral cortex was assessed using a semi-quantitative scale where:

- no type II astrocytes observed
- + occasional type II astrocytes present but in < 25% of ×20 objective fields
- ++ frequent type II astrocytes present; seen in 25%–50% of ×20 objective fields
- +++ many type II astrocytes present; seen in 50%–75% of ×20 objective fields
- ++++ abundant type II astrocytes present in > 75% of ×20 objective fields examined

Astrocytes were considered to be of the Alzheimer type II type when enlarged, pale glial nuclei showing a vesicular nucleus with at least one basophilic nucleolus were visible. Often, they were present as paired nuclei (**Fig. 1**). Other pathological features present in the sections were also noted. The two pathologists then compared their results. Discordant results were discussed using a multi-headed microscope.

RESULTS

The age, gender and breed of the eight dogs included in the study are shown in **Table 1**. Three dogs had an intrahepatic cPSS and five dogs had an extrahepatic cPSS. Two dogs were euthanized due to poor response to medical management of HE. The remaining six dogs had surgical attenuation of the cPSS. One dog was euthanized four years after placement of ameroid constrictor due to persistent HE. One dog was euthanized 11 months following complete suture ligation of their cPSS due to persistent HE. The remaining four dogs died or were euthanized within 10 days of surgical attenuation of their cPSS due to persistent HE or immediate post-operative complications (**Table 1**).

All cases had evidence of Alzheimer type II astrocytes with six of the eight cases having substantial numbers of type II astrocytes (**Table 2**). Both pathologists scored the brain sections similarly. Where more than one section of cerebral cortex had been examined in the original investigations, all those sections were re-examined and a mean score for the level of type II astrocytes determined (**Table 2**).

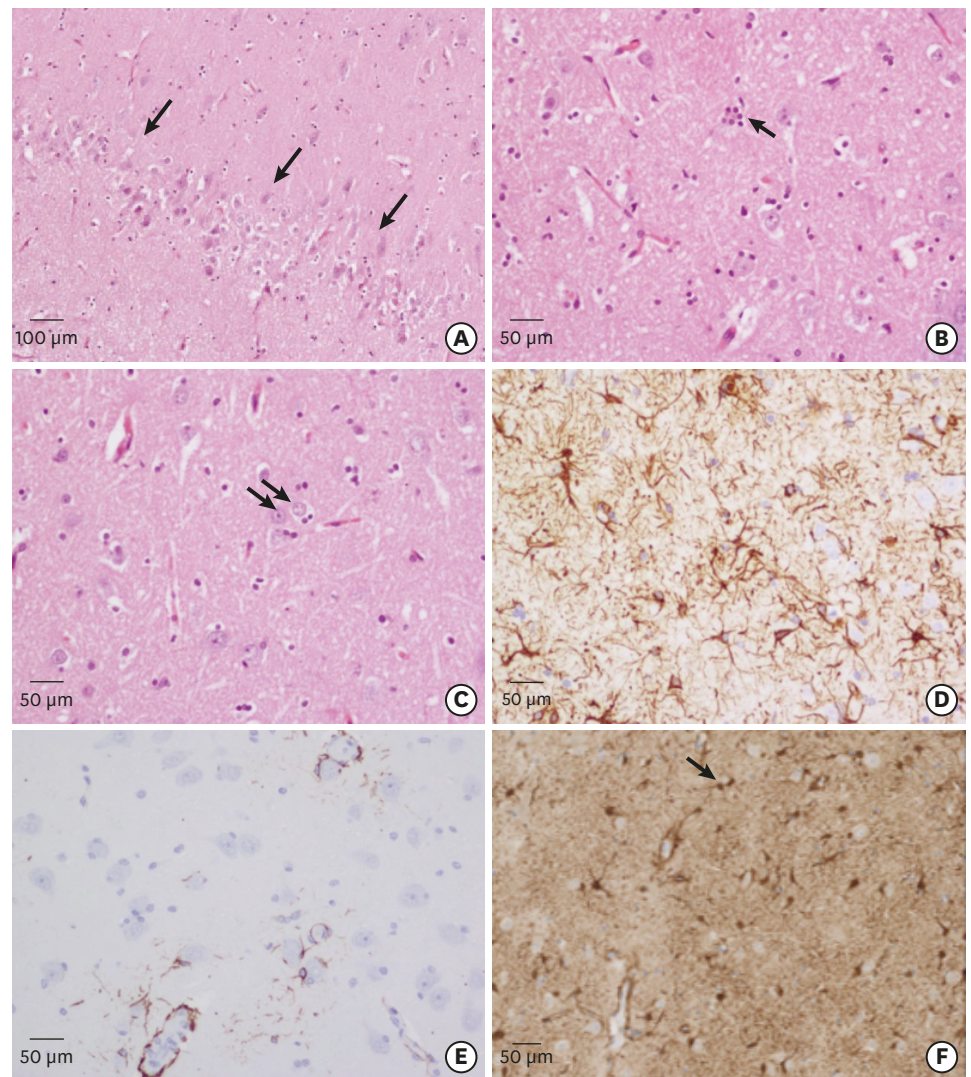


Fig. 1. Histological images from dogs included in the study. All histology images were from dogs which had HE apart from E which is included as non-neurological disease control to enable GFAP staining to be compared between brain tissue from a dog with a non-neurological disorder and a dog with HE. (A) Cerebral cortex showing laminar distribution of pathology (arrows) (H & E). (B) Cerebral cortex showing occasional neuronal satellitosis with presumed microglia (arrow) (H & E). (C) Cerebral cortex showing Alzheimer type 2 astrocytes (arrows) (H & E). (D) GFAP immunolabelling of affected area of cerebral cortex. (E) GFAP immunolabelling of similar area to D, taken from a normal adult dog. (F) S-100 immunolabelling of affected area of cerebral cortex showing paired astrocyte nuclei (arrow).

HE, hepatic encephalopathy; GFAP, glial fibrillary acidic protein; H & E, hematoxylin and eosin.

The type II astrocytes were found mainly in the cerebral cortex and tended to follow a laminar pattern, associated with mild laminar oedema in most cases (**Fig. 1**, **Table 2**). Neuronal ischaemic necrosis (i.e. small, angular, eosinophilic neurones) reported in other studies was not evident although occasional satellitosis was observed (**Fig. 1**). On review of the clinical history alongside the histological assessment of the brain samples, there was no clear correlation between the number of type II astrocytes detected and the duration or severity of clinical disease. For the cases where more than one wax block of brain tissue was available, there was little variation in the number of type II astrocytes between sections (and therefore areas) of cerebral cortex, except for case 6. All eight cases showed increased immunoreactivity for GFAP and S-100 (**Fig. 1**) within the cerebral cortex. While there is a

Table 1. Clinical summary of cases

Signalment	Types of cPSS	Treatment
3-month-old FE Labrador	Central divisional intrahepatic	Poor response to medical management, euthanized 1 month post-diagnosis.
7-month-old ME Crossbreed	Portocaval extrahepatic	Poor response to medical management, euthanized 4 days post-diagnosis.
6-year-old MN Miniature Schnauzer	Extrahepatic	Ameroid constrictor placed around cPSS. Euthanized 4 years post surgery following development of HE.
FN Dandie Dinmont Terrier	Extrahepatic	Cellophane band placed around cPSS, euthanized 4 days post surgery due to gastrointestinal haemorrhage.
8-year-old FN Cairn Terrier	Portocaval extrahepatic	Partial suture ligation performed. Develop seizures 2 days post-surgery. Euthanized 4 days post-surgery due to persistent seizures, which were refractory to medical management.
4-month-old ME Flat Coated Retriever	Left divisional intrahepatic	Partial suture ligation performed. Died 2 days post-surgery due to gastrointestinal haemorrhage.
14-month-old ME Labrador	Central divisional intrahepatic	Partial suture ligation performed. Euthanized 10 days post-surgery due to gastrointestinal haemorrhage.
12-year-old ME Crossbreed	Splenoazygous extrahepatic	Complete ligation performed, euthanized 11 months post-surgery due to persistent HE.

cPSS, congenital portosystemic shunt; FE, female entire; ME, male entire; MN, male neutered; FN, female neutered.

Table 2. Histological summary of cases

Dog number	Number of slides examined	Comment/description	Type 2 astrocytes
1	5 (cerebral cortex × 4; cerebellum × 1)	Scant type II astrocytes. No cortical laminar vacuolation. Mild vacuolation of internal capsule and major rami.	+
2	1 (cerebral cortex with basal nuclei × 1)	Abundant Type II astrocytes in cerebral cortex (laminar pattern) but not in basal nuclei; occasional neuronal satellitosis. No WM vacuolation.	+++
3	1 (cerebral cortex × 1)	Laminar cortical vacuolation with type II astrocytes.	++
4	1 (cerebral cortex × 1)	Mild hydrocephalus with reduced corpus callosum. Laminar cortical gliosis with moderate numbers of type II astrocytes.	++
5	5 (cerebral cortex × 4; cerebellum × 1)	Mild hydrocephalus with thinning of cerebral cortex. Mild, laminar cortical vacuolation and perineuronal spaces. Variable number of type II astrocytes depending on area of cortex examined. Mild perivascular lymphocytic cuffing.	+ → ++
6	4 (thalamus and cerebral cortex × 2; cerebellum × 1; spinal cord × 1)	Mild to moderate numbers of type II astrocytes in the little cortical tissue present. Type II astrocytes present in spinal cord.	+ → ++
7	2 (cerebral cortex × 1; cerebellum × 1)	Laminar cortical oedema/vacuolation. Mild numbers of type II astrocytes in cortical section only.	+
8	4 (cerebral cortex × 3; cerebellum × 1)	Cortical laminar oedema with vacuolation. Abundant type II astrocytes.	+++ → ++++

The number of type 2 astrocytes were assessed using a semi-quantitative approach as outlined in the Materials and Methods. Severity scores in parentheses indicates that some brain areas showed this severity whereas most brain areas showed the other severity indicated (i.e. some variation between tissue sections was observed).

WM, white matter.

general increase in GFAP immunoreactivity in HE, the Alzheimer Type II astrocytes do not show increased GFAP immunoreactivity whereas they do for S-100 (**Fig. 1**).

There was little evidence of white matter vacuolation, either within the core of cerebral white matter tracts or at the border between these tracts and deep grey matter in any of the 8 cases. Examination of the cerebellum from the 5 cases where material was available to this study revealed focal areas of Purkinje cell loss in 2 cases.

DISCUSSION

The main finding of this study was the high prevalence of Alzheimer type II astrocytes in a laminar pattern within the cerebral cortex of dogs with a cPSS and HE, together with an increase in GFAP immunoreactivity in the same areas of the brain. Although type II astrocytes are usually weakly GFAP positive [19,20,36] this study suggests that there is a more general activation of astrocytes in the affected areas of the brain, not all of which proceed to the type II astrocyte phenotype. To date, there have been limited descriptions of brain pathology in dogs with a cPSS. In two dogs which died following surgical attenuation of their cPSS,

post-mortem examination revealed severe neuronal necrosis in one dog and multifocal, suppurative, necrotising bacterial encephalitis in the second case [15]. The presence of type II astrocytes was not reported. In another case report of two dogs which died following ligation of cPSS, the main post-mortem finding was ischemic change affecting neurons [32]. In two dogs which died following gauged attenuation of cPSS, extensive necrosis of neurons in the cerebral cortex with dilation of blood vessels, perivascular infiltration of leukocytes and histiocytes, and activation of endothelium in arterioles was reported [31]. In a review of three dogs that had died after surgical ligation of cPSS, generalised polioencephalomalacia with spongiform leukoencephalopathy was found in two dogs and multifocal, mild spongiform degeneration of the cerebral cortex in another [14]. One of the few reports to describe Alzheimer type II astrocytes was a single case report of a dog with a cPSS [34].

Our study is the first detailed report of the pathological changes of the cerebral cortex from a series of dogs that had a spontaneously arising portosystemic shunt and a history of HE, uncomplicated by secondary encephalitis. Ischaemic neuronal necrosis was not a feature in the current study and white matter vacuolation was either mild or absent. Many of the classical accounts of HE in ruminants or other herbivores indicate that vacuolation of cerebral white matter tracts, or vacuolation at the white matter-grey matter interface is a diagnostic feature [20,36]; this pattern of vacuolation was not observed in the present study, supporting previous suggestions that such vacuolation is less common in dogs than larger animals and that there may be species differences in nature of HE pathology [36].

We have clearly demonstrated that Alzheimer type II astrocytes are a common feature in dogs with HE. In addition, and not previously reported, an astrocyte activation, reflected in increased GFAP immunoreactivity, was detected; this could be considered as a non-specific response to disturbances of cerebral homeostasis. Alzheimer type II astrocytes are thought to represent proliferating astrocytes—supported by thymidine incorporation studies following, for example, administration of radiolabelled methionine sulphoxide (inhibits glutamine synthetase and promotes local ammonia production in the brain)—and are found most frequently in the cerebral cortex. In this study, Alzheimer type II astrocytes were observed in the cerebral cortex, cerebellum and in one case also the spinal cord, which was available for review. In most cases, these cells were associated with a laminar pattern of pathology in the cerebral cortex with oedema (microvacuolation) of grey matter. Although ischaemic neurones were sparse, this laminar pattern is reminiscent of laminar cortical degeneration that occurs in some other toxic and metabolic neuropathologies secondary to cortical glucose deprivation in certain animal species [20,36].

There was no clear evidence of a difference in cerebral cortex pathology in dogs that were euthanized due to intractable HE or dogs that died shortly after surgical attenuation of their cPSS. The development of post-operative gastrointestinal haemorrhage and/or seizures following surgical reduction of porto-systemic shunting is a well-established complication of cPSS attenuation [3,14,15,31,32,37]. For example, case 5, which was euthanized following development of post attenuation seizures, had similar pathological changes to case 2 which had HE and did not undergo surgery. The lack of observed differences may relate to the relatively small numbers in each subgroup or due to histological changes in other areas of the brain not reviewed in this study.

The histological changes in the brains of humans with HE have been widely reported and typically involve characteristic changes in astrocyte morphology [38-42]. Classical changes

which occur in astrocytes in human patients with HE include swelling of the nucleus, margination of chromatin and glycogen deposits which are collectively defined as ‘Alzheimer type II’ astrocytes [38-42]. Although rare compared to dogs, over three hundred cases of cPSS have been reported in humans [43]. Neuropathological findings in humans mirror our results, with Alzheimer type II astrocytes in the cerebral cortex being a key pathological finding in humans with a cPSS [38].

This study further demonstrates the merit of investigating dogs with spontaneously arising cPSS as a model for human HE. The type and distribution of lesions observed in this study is more consistent with that of portosystemic shunt pathology in man than it is of HE in other domestic species such as cattle and horses [19]. A recent review of experimental models of HE highlighted the need for better validated models of human HE [44]. In terms of HE resulting from portocaval shunting in the absence of parenchymal liver disease, the International Society for HE and Nitrogen Metabolism Commission (ISHEN) highlighted the need for models to have evidence of portal-systemic shunting, a range of encephalopathic signs, hyperammonaemia, a precipitating factor and clinical response to established treatments [44]. There is now a growing body of evidence that has demonstrated that these requirements are met in dogs with a spontaneous cPSS. For example, inflammation and hyperammonaemia have been shown to be key drivers of both human and canine HE [18,45]. Importantly, the ISHEN guidelines highlighted the need for these models to have evidence of Alzheimer type II astrocytes. This study indicates that this requirement has now been satisfied which further demonstrates that dogs with a cPSS are a good model for human HE. Furthermore, our study provides additional evidence that the biology of HE can be studied without the need to induce disease in otherwise healthy animals.

In summary, this study has described the histological changes observed in the cerebral cortex and cerebellum of dogs with a cPSS. Numerous Alzheimer type II astrocytes were observed in the majority of cases. Our study demonstrates that the histological changes that occur in dogs with a cPSS are very similar to the changes observed in humans with HE underlying the merit of a ‘One Health’ approach to investigation of this disorder which could lead to therapeutic advances for both species.

REFERENCES

1. Tobias KM, Rohrbach BW. Association of breed with the diagnosis of congenital portosystemic shunts in dogs: 2,400 cases (1980–2002). *J Am Vet Med Assoc.* 2003;223(11):1636-1639.
[PUBMED](#) | [CROSSREF](#)
2. White RN, Macdonald NJ, Burton CA. Use of intraoperative mesenteric portovenography in congenital portosystemic shunt surgery. *Vet Radiol Ultrasound.* 2003;44(5):514-521.
[PUBMED](#) | [CROSSREF](#)
3. Berent AC, Tobias KM. Portosystemic vascular anomalies. *Vet Clin North Am Small Anim Pract.* 2009;39(3):513-541.
[PUBMED](#) | [CROSSREF](#)
4. Maddison JE. Hepatic encephalopathy. Current concepts of the pathogenesis. *J Vet Intern Med.* 1992;6(6):341-353.
[PUBMED](#) | [CROSSREF](#)
5. Winkler JT, Bohling MW, Tillson DM, Wright JC, Ballagas AJ. Portosystemic shunts: diagnosis, prognosis, and treatment of 64 cases (1993–2001). *J Am Anim Hosp Assoc.* 2003;39(2):169-185.
[PUBMED](#) | [CROSSREF](#)

6. Gerritzen-Bruning MJ, van den Ingh TS, Rothuizen J. Diagnostic value of fasting plasma ammonia and bile acid concentrations in the identification of portosystemic shunting in dogs. *J Vet Intern Med.* 2006;20(1):13-19.
[PUBMED](#) | [CROSSREF](#)
7. d'Anjou MA, Penninck D, Cornejo L, Pibarot P. Ultrasonographic diagnosis of portosystemic shunting in dogs and cats. *Vet Radiol Ultrasound.* 2004;45(5):424-437.
[PUBMED](#) | [CROSSREF](#)
8. Nelson NC, Nelson LL. Anatomy of extrahepatic portosystemic shunts in dogs as determined by computed tomography angiography. *Vet Radiol Ultrasound.* 2011;52(5):498-506.
[PUBMED](#) | [CROSSREF](#)
9. Seguin B, Tobias KM, Gavin PR, Tucker RL. Use of magnetic resonance angiography for diagnosis of portosystemic shunts in dogs. *Vet Radiol Ultrasound.* 1999;40(3):251-258.
[PUBMED](#) | [CROSSREF](#)
10. Watson PJ, Herrtage ME. Medical management of congenital portosystemic shunts in 27 dogs--a retrospective study. *J Small Anim Pract.* 1998;39(2):62-68.
[PUBMED](#) | [CROSSREF](#)
11. Greenhalgh SN, Dunning MD, McKinley TJ, Goodfellow MR, Kelman KR, Freitag T, O'Neill EJ, Hall EJ, Watson PJ, Jeffery ND. Comparison of survival after surgical or medical treatment in dogs with a congenital portosystemic shunt. *J Am Vet Med Assoc.* 2010;236(11):1215-1220.
[PUBMED](#) | [CROSSREF](#)
12. Greenhalgh SN, Reeve JA, Johnstone T, Goodfellow MR, Dunning MD, O'Neill EJ, Hall EJ, Watson PJ, Jeffery ND. Long-term survival and quality of life in dogs with clinical signs associated with a congenital portosystemic shunt after surgical or medical treatment. *J Am Vet Med Assoc.* 2014;245(5):527-533.
[PUBMED](#) | [CROSSREF](#)
13. Fryer KJ, Levine JM, Peycke LE, Thompson JA, Cohen ND. Incidence of postoperative seizures with and without levetiracetam pretreatment in dogs undergoing portosystemic shunt attenuation. *J Vet Intern Med.* 2011;25(6):1379-1384.
[PUBMED](#) | [CROSSREF](#)
14. Matushek KJ, Bjorling D, Mathews K. Generalized motor seizures after portosystemic shunt ligation in dogs: five cases (1981-1988). *J Am Vet Med Assoc.* 1990;196(12):2014-2017.
[PUBMED](#)
15. Mehl ML, Kyles AE, Hardie EM, Kass PH, Adin CA, Flynn AK, De Cock HE, Gregory CR. Evaluation of ameroid ring constrictors for treatment for single extrahepatic portosystemic shunts in dogs: 168 cases (1995-2001). *J Am Vet Med Assoc.* 2005;226(12):2020-2030.
[PUBMED](#) | [CROSSREF](#)
16. Tisdall PL, Hunt GB, Youmans KR, Malik R. Neurological dysfunction in dogs following attenuation of congenital extrahepatic portosystemic shunts. *J Small Anim Pract.* 2000;41(12):539-546.
[PUBMED](#) | [CROSSREF](#)
17. Yool DA, Kirby BM. Neurological dysfunction in three dogs and one cat following attenuation of intrahepatic portosystemic shunts. *J Small Anim Pract.* 2002;43(4):171-176.
[PUBMED](#) | [CROSSREF](#)
18. Tivers MS, Handel I, Gow AG, Lipscomb VJ, Jalan R, Mellanby RJ. Hyperammonemia and systemic inflammatory response syndrome predicts presence of hepatic encephalopathy in dogs with congenital portosystemic shunts. *PLoS One.* 2014;9(1):e82303.
[PUBMED](#) | [CROSSREF](#)
19. Harper CB. Toxic and metabolic diseases. In: Graham DI, Lantos PL, editors. *Grenfield's Neuropathology.* Volume 1 (6th edition). Arnold; London; 1997, 627-634.
20. Summers BA, Cummings JF, De Lahunta A. *Veterinary Neuropathology.* St Louis: Mosby; 1995, 208-211.
21. Albrecht J, Zielińska M, Norenberg MD. Glutamine as a mediator of ammonia neurotoxicity: A critical appraisal. *Biochem Pharmacol.* 2010;80(9):1303-1308.
[PUBMED](#) | [CROSSREF](#)
22. Chung RT. Cirrhosis and its complications. In: Kasper DL, Braunwald E, Fauci AS, editors. *Harrison's Principles of Internal Medicine,* 16th ed. New York: McGraw-Hill; 2005, 1858-1869.
23. Kilpatrick S, Gow AG, Foale RD, Tappin SW, Carruthers H, Reed N, Yool DA, Woods S, Marques AI, Jalan R, Mellanby RJ. Plasma cytokine concentrations in dogs with a congenital portosystemic shunt. *Vet J.* 2014;200(1):197-199.
[PUBMED](#) | [CROSSREF](#)

24. Gow AG, Marques AI, Yool DA, Crawford K, Warman SM, Eckersall PD, Jalan R, Mellanby RJ. Dogs with congenital porto-systemic shunting (cPSS) and hepatic encephalopathy have higher serum concentrations of C-reactive protein than asymptomatic dogs with cPSS. *Metab Brain Dis.* 2012;27(2):227-229.
[PUBMED](#) | [CROSSREF](#)
25. Tivers MS, Handel I, Gow AG, Lipscomb VJ, Jalan R, Mellanby RJ. Attenuation of congenital portosystemic shunt reduces inflammation in dogs. *PLoS One.* 2015;10(2):e0117557.
[PUBMED](#) | [CROSSREF](#)
26. Gow AG, Marques AI, Yool DA, Duncan A, Mellanby RJ. Whole blood manganese concentrations in dogs with congenital portosystemic shunts. *J Vet Intern Med.* 2010;24(1):90-96.
[PUBMED](#) | [CROSSREF](#)
27. Gow AG, Frowde PE, Elwood CM, Burton CA, Powell RM, Tappin SW, Foale RD, Duncan A, Mellanby RJ. Surgical attenuation of spontaneous congenital portosystemic shunts in dogs resolves hepatic encephalopathy but not hypermanganesemia. *Metab Brain Dis.* 2015;30(5):1285-1289.
[PUBMED](#) | [CROSSREF](#)
28. Moon SJ, Kim JW, Kang BT, Lim CY, Park HM. Magnetic resonance imaging findings of hepatic encephalopathy in a dog with a portosystemic shunt. *J Vet Med Sci.* 2012;74(3):361-366.
[PUBMED](#) | [CROSSREF](#)
29. Torisu S, Washizu M, Hasegawa D, Orima H. Brain magnetic resonance imaging characteristics in dogs and cats with congenital portosystemic shunts. *Vet Radiol Ultrasound.* 2005;46(6):447-451.
[PUBMED](#) | [CROSSREF](#)
30. Carrera I, Kircher PR, Meier D, Richter H, Beckman K, Dennler M. In vivo proton magnetic resonance spectroscopy for the evaluation of hepatic encephalopathy in dogs. *Am J Vet Res.* 2014;75(9):818-827.
[PUBMED](#) | [CROSSREF](#)
31. Wolschrijn CF, Mahapokai W, Rothuizen J, Meyer HP, van Sluijs FJ. Gauged attenuation of congenital portosystemic shunts: results in 160 dogs and 15 cats. *Vet Q.* 2000;22(2):94-98.
[PUBMED](#) | [CROSSREF](#)
32. Hardie EM, Kornegay JN, Cullen JM. Status epilepticus after ligation of portosystemic shunts. *Vet Surg.* 1990;19(6):412-417.
[PUBMED](#) | [CROSSREF](#)
33. Windsor RC, Olby NJ. Congenital portosystemic shunts in five mature dogs with neurological signs. *J Am Anim Hosp Assoc.* 2007;43(6):322-331.
[PUBMED](#) | [CROSSREF](#)
34. Morita T, Mizutani Y, Michimae Y, Sawada M, Sato K, Hikasa Y, Shimada A. Severe involvement of cerebral neopallidum in a dog with hepatic encephalopathy. *Vet Pathol.* 2004;41(4):442-445.
[PUBMED](#) | [CROSSREF](#)
35. Kimura T, Budka H. Glial fibrillary acidic protein and S-100 protein in human hepatic encephalopathy: immunocytochemical demonstration of dissociation of two glia-associated proteins. *Acta Neuropathol.* 1986;70(1):17-21.
[PUBMED](#) | [CROSSREF](#)
36. Vandervelde M, Higgins RJ, Oevermann A. *Veterinary Neuroanatomy: Essentials of Theory and Practice.* Hoboken: Wiley-Blackwell; 2012.
37. Weisse C, Berent AC, Todd K, Solomon JA, Cope C. Endovascular evaluation and treatment of intrahepatic portosystemic shunts in dogs: 100 cases (2001–2011). *J Am Vet Med Assoc.* 2014;244(1):78-94.
[PUBMED](#) | [CROSSREF](#)
38. Kimura N, Kumamoto T, Hanaoka T, Nakamura K, Hazama Y, Arakawa R. Portal-systemic shunt encephalopathy presenting with diffuse cerebral white matter lesion: an autopsy case. *Neuropathology.* 2008;28(6):627-632.
[PUBMED](#) | [CROSSREF](#)
39. Finlayson MH, Superville B. Distribution of cerebral lesions in acquired hepatocerebral degeneration. *Brain.* 1981;104(Pt 1):79-95.
[PUBMED](#) | [CROSSREF](#)
40. Matsusue E, Kinoshita T, Ohama E, Ogawa T. Cerebral cortical and white matter lesions in chronic hepatic encephalopathy: MR-pathologic correlations. *AJNR Am J Neuroradiol* 2005;26(2):347-351.
[PUBMED](#)
41. Butterworth R. Neuronal cell death in hepatic encephalopathy. *Metab Brain Dis.* 2007;22(3-4):309-320.
[PUBMED](#) | [CROSSREF](#)
42. Butterworth RF. Complications of cirrhosis III. Hepatic encephalopathy. *J Hepatol.* 2000;32(1 Suppl):171-180.
[PUBMED](#) | [CROSSREF](#)

43. Sokollik C, Bandsma RH, Gana JC, van den Heuvel M, Ling SC. Congenital portosystemic shunt: characterization of a multisystem disease. *J Pediatr Gastroenterol Nutr.* 2013;56(6):675-681.
[PUBMED](#) | [CROSSREF](#)
44. Butterworth RF, Norenberg MD, Felipo V, Ferenci P, Albrecht J, Blei AT; Members of the ISHEN Commission on Experimental Models of HE. Experimental models of hepatic encephalopathy: ISHEN guidelines. *Liver Int.* 2009;29(6):783-788.
[PUBMED](#) | [CROSSREF](#)
45. Shawcross D, Jalan R. The pathophysiologic basis of hepatic encephalopathy: central role for ammonia and inflammation. *Cell Mol Life Sci.* 2005;62(19-20):2295-2304.
[PUBMED](#) | [CROSSREF](#)