

# Evaluation of HER2/neu expression in different types of salivary gland tumors: a systematic review and meta-analysis

Aylar Javaheripour<sup>1</sup>, Maedeh Vakili Saatloo<sup>2</sup>, Nafiseh Vahed<sup>3</sup>, Leili Faraji Gavgani<sup>3</sup>, Maryam Kouhsoltani<sup>1\*</sup>

## Author Affiliations

1. Department of Oral and Maxillofacial Pathology, Faculty of Dentistry, Tabriz University of Medical Sciences, Tabriz, Iran
2. Department of Microbiology and Immunology, Medical University of South Carolina, Charleston, South Carolina, United States of America
3. Research Center for Evidence Based Medicine, Tabriz University of Medical Sciences, Tabriz, Iran

## \*Corresponding Author:

Maryam Kouhsoltani,  
Department of Oral and Maxillofacial Pathology,  
Faculty of Dentistry, Tabriz University of Medical sciences,  
Tabriz, Iran.  
E-mail: mkoohsoltani@yahoo.com

## DOI

10.25122/jml-2021-0394

## Dates

Received: 8 December 2021

Accepted: 24 January 2022

## ABSTRACT

This study is a systematic review and meta-analysis to assess the overexpression rate of HER2 in patients with salivary gland tumors. We included peer-reviewed publications from 1995 to 2020, indexed in medical databases, using search terms such as "human epidermal growth factor receptor 2 (HER2)" and "salivary gland tumors", and extracted relevant data. The extracted data were analyzed with RevMan 5.3 software. Intra- and intergroup post hoc analyses of outcome variables were performed using t-tests, and the rates of HER2 positivity among studies were evaluated. 80 studies were included in the analysis. The positive rates of HER2 ranged from 3.3% to 84.0% and 1% to 9% in malignant and benign subtypes, respectively. The highest HER2 overexpression rate among malignant tumors was in salivary ductal carcinomas (SDC), with a 45% positive rate (CI 95%: 21.9–70.3%). Mucoepidermoid carcinoma (MEC) had the highest positive rate of 84% (CI 95%: 74.1–90.0%). Among benign salivary gland tumors, the highest rate was found in myoepithelioma, with a positive rate of 9% (CI 95%: 1.7–33.6%). The highest rate of HER2 overexpression is present in malignant subtypes of salivary gland tumors, more specifically in salivary ductal carcinoma, mucoepidermoid carcinomas, salivary duct carcinoma in situ, and carcinoma ex pleomorphic adenoma.

**KEYWORDS:** salivary gland, cancer, HER2, oral pathology, carcinoma.

**ABBREVIATIONS:** ACC – Adenoid Cystic Carcinomas; HER2 – Human epidermal growth factor receptor 2; MEC – Mucoepidermoid Carcinoma; PRISMA – Preferred Reporting Items for Systematic Review and Meta-analyses.

## INTRODUCTION

Benign neoplasms comprise the major part of salivary gland tumors. However, salivary gland malignancies make up about 11% of all head and neck cancers, with more than 20 pathological subtypes [1–3]. This heterogeneity challenges the treatment of these carcinomas [4], and although adjuvant therapy following surgery is the treatment of choice in most cases, the results are usually not favorable [5, 6]. Nevertheless, since the emergence of modern, effective molecular targeted therapies for various types of cancers [7], such as breast cancer, non-small cell lung cancer, acute myeloid leukemia, renal cell carcinoma, and hepatocellular carcinoma [8–12] and successful application of trastuzumab and pertuzumab, which target human epidermal growth factor Receptor 2 (HER2 also known as HER2/neu), in management of the patients with HER2-positive metastatic

breast cancer [8], numerous studies tried to demonstrate the efficacy of these group of medications in the treatment of other HER2/neu positive cancers. HER2/neu is a proto-oncogene that encodes a transmembrane glycoprotein – with a tyrosine kinase activity and similarities to epidermal growth factor receptor [13–15]. In addition to breast cancer, its overexpression/amplification has been detected in various malignant neoplasms such as ovarian, gastrointestinal, and salivary gland cancers [16–19]. Several studies have immunohistochemically assessed salivary gland tumors for overexpression of HER2/neu; however, the results are somewhat controversial [20–24]. For instance, the HER2 overexpression rate was reported to vary between 38% to 67% in mucoepidermoid carcinomas (MEC) and 30% to 77% in adenoid cystic carcinomas (ACC) in different studies. Also, there is a lack of data reporting the pooled results of HER2 overexpression rates in salivary gland tumors, leading to a new

paradigm for future studies to evaluate possible therapeutic options for this family of neoplasms. The present study is a systematic review and meta-analysis of the expression of HER2/neu in different types of salivary gland tumors.

## MATERIAL AND METHODS

This systematic review was performed based on the PRISMA guidelines for writing systematic reviews.

### Search strategy and study selection criteria

We performed an electronic search on Pubmed (Medline), Scopus, Proquest, The Cochrane Library, Psycinfo, and CINAHL databases, including studies from 1995 to 2020. The search strategy was based on Medical Subject Headings (MeSH) and a combination of free words in the title/abstract as follows: (human epidermal growth factor receptor (HER/EGFR/ERBB) "ErbB2", "c-erb2", "EGFR2", "erbB-2 proto-oncogene protein", "tyrosine-protein kinase erbB2 receptor", and "human epidermal receptor 2". A manual search of articles presented in related conferences was performed. The search was restricted to English-language articles. Studies were eligible for inclusion if HER2 expression was detected by immunohistochemistry (IHC) with or without fluorescence in situ hybridization. The following articles were excluded: (1) not peer-reviewed; (2) not published in full (3) review articles, letters to editor, commentaries, case reports; (4) non-English language articles; (5) articles from which the relevant data could not be extracted; (6) non-human research (7) articles of poor quality; (8) studies without qualitative staining and immunohistochemistry analysis; and (9) duplicated articles (risk of bias). Articles reporting less than three cases were not included.

### Data Extraction

One of the authors selected the potentially eligible studies, and then two specialists in oral and maxillofacial pathology independently reviewed the quality of the articles using the Critical Appraisal Skills Program (CASP) quality checklist, and low-quality studies were excluded. Data were extracted by the first author (AJ). If there were duplicates, the most informative cohort was included. To ensure the review was comprehensive and reduce the risk of introducing selection bias, we aimed to include studies irrespective of the immunohistochemistry (IHC) methods used to measure overexpression of HER2/neu. The extracted data for each study included the first author's name, publication year, type of the study, number of patients, detection methods, rate of HER2 positivity, tumors' malignancy or benignity, and types of tumors.

Endnote X5 Resource Management Software was used to organize titles and abstracts of the articles and to recognize duplicates.

### Analysis

The comprehensive meta-analysis (CMA; Englewood, NJ, USA), software version 2.0, was used to analyze the data. Q statistics and  $I^2$  were used to purpose heterogeneity. A possibility value of  $P$ -value $<0.10$  and  $I^2$  value  $>50\%$  for Cochran's Q showed the existence of noteworthy heterogeneity. According to the analysis, fixed or random-effects models were used. We used a fixed-effect model with a 95% confidence interval and signifi-

cance level of 0.05 to perform the meta-analysis and forest plots to report the results. To check for publication bias, funnel plots and Egger's test with a significance level of 0.01 were used.

## RESULTS

### Study selection and characteristics

The online database search identified 3641 publications, and 3 more were identified from article lists. 855 publications were duplicates. All abstracts were reviewed, and 245 papers were read in full. The list of articles is available on request from the authors. 80 papers fulfilled the criteria for the study and were included in the analysis. The flow diagram shows the article selection process (Figure 1).

Studies were from South Korea (7), Germany (8), Japan (13), the United States (15), Canada (3), Brazil (5), Iran (1), the United Kingdom (2), Italy (5), Israel (2), Poland (2), Taiwan (1), Czech Republic (2), France (2), the Netherlands (2), China (2), Australia (1), Greece (2), Finland (3), and Portugal(2).

37 of the included studies were retrospective cohort studies, 33 were cross-sectional studies, 4 were clinical trials, 3 were case series, and 3 were case-control studies. Based on the quality criteria, all the studies were of high quality.

### Study results and meta-analysis

Of 80 studies, 8 reported the expression of HER2/neu in benign tumors, 78 studies reported the expression of HER2/neu in malignant tumors, 65 used evaluation methods for IHC used to assess HER2 in malignant salivary gland tumors (Group 1), and the remaining 13 used a variety of methods with different cut off points and scoring scales (Group 2).

### Malignant salivary gland tumors (Group 1)

Of 65 studies, overexpression of HER2/neu in salivary ductal carcinomas (SDC) was assessed in 40 studies, making it the most studied salivary gland tumor in this meta-analysis. The least studied salivary gland tumors were cystadenocarcinoma and poorly differentiated adenocarcinoma, with 1 study pertaining to each of them. After pooling the data for each salivary gland tumor subtype, the highest heterogeneity was seen in studies related to adenoid cystic carcinomas (ACC) ( $I^2=86.126$ ,  $P=0.002$ ) and then in the studies related to SDC ( $I^2=77.950$ ,  $P=0.000$ ). More details are available in Table 1.

The meta-analysis showed that salivary duct carcinoma in situ had the highest pooled overexpression rate of HER2/neu among salivary gland tumors, 45% (CI 95%: 21.9–70.3%). Also, the lowest expression rate was for cystadenocarcinoma, with an expression rate of 3.3% (CI 95%: 0.2–36.6%).

### Malignant Salivary gland tumors (Group 2)

In the studies evaluating IHC with a cut-off point of  $>30\%$  for +3 positive,  $>10\%$  for +2, +1 for faint and barely, and 0 for negative results, tumors with  $\geq 10\%$  nuclear-stained cells were considered positive. The positive rate in salivary duct carcinoma in situ was 23% (CI 95%: 11.9–39.5%), the expression rate of HER2/neu in carcinoma ex pleomorphic adenoma (CXPA) was 55% (CI 95%: 37.4–71.1%), and the pooled positive rate of for SDC was 41% (CI 95%: 34.8–47.7%).

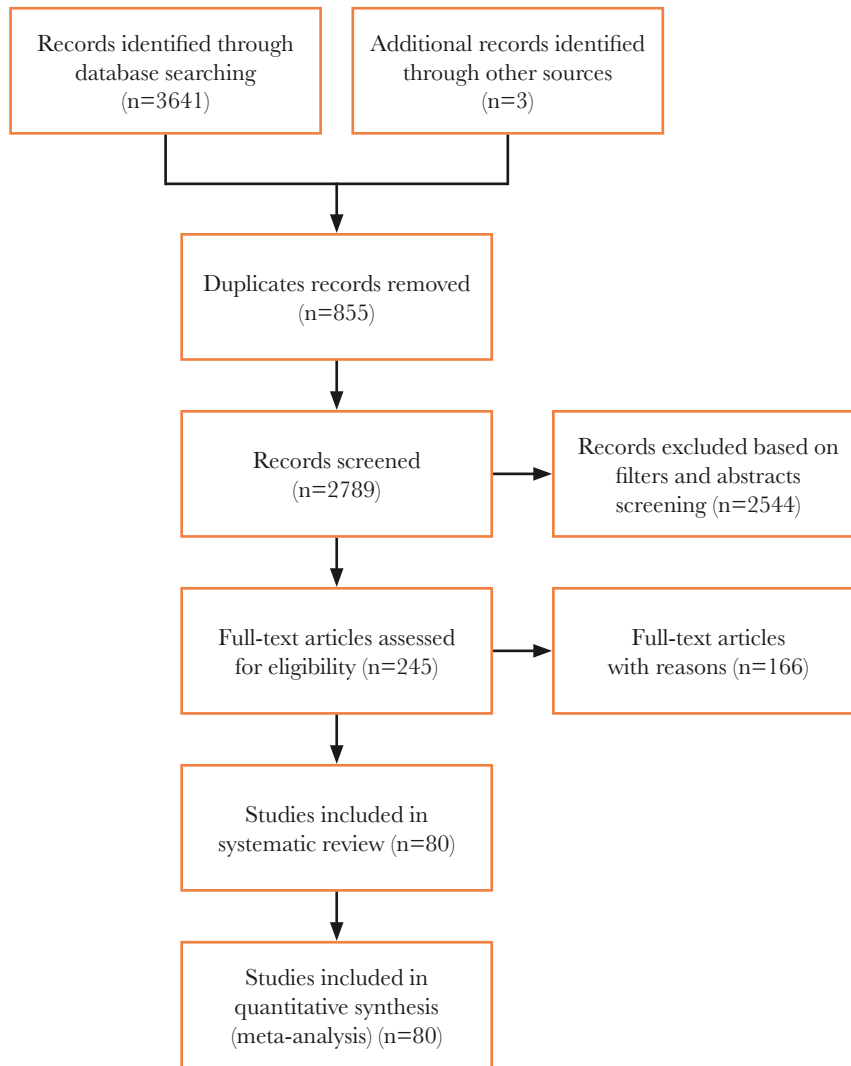


Figure 1. PRISMA flow diagram.

Table 1. Number of studies assessing the expression of HER2/neu protein in salivary gland tumors, the rate (%) and 95% confidence interval of expression, and the level of heterogeneity in the studies related to each subtype.

Tumor subtype	Number of studies	Expression of HER2/neu protein (%)	95% CI		I-squared	P-value
			Lower limit (%)	Upper limit (%)		
Acinic cell carcinoma	12	16.2	10.6	24.0	62.957	0.002
Adenocarcinomas, not otherwise specified (NOS)	9	22.3	15.5	31.0	0.000	0.667
Adenoid cystic carcinoma (ACC)	14	17.2	12.1	24.0	86.126	0.000
Basal cell adenocarcinoma (BCAC)	4	4.7	1.2	17.3	0.000	0.602
Salivary duct carcinoma in situ	2	44.9	21.9	70.3	53.673	0.142
Cystadenocarcinoma	1	3.3	0.2	36.6	0.000	1.000
Epithelial-myoepithelial carcinoma (EMC)	4	5.2	1.5	16.5	0.000	0.596
Carcinoma ex pleomorphic adenoma (CXPA)	14	33.7	28.8	38.9	46.857	0.027
Polymorphous low-grade adenocarcinoma (PLGA)	3	4.0	0.8	17.9	0.000	0.529

Table 2. Continued.

Tumor subtype	Number of studies	Expression of HER2/neu protein (%)	95% CI		I-squared	P-value
			Lower limit (%)	Upper limit (%)		
Mucoepidermoid carcinoma (MEC)	15	12.9	10.2	16.1	54.712	0.006
Myoepithelial carcinoma	4	5.1	1.5	16.2	0.000	0.908
Oncocytic carcinoma	2	4.6	0.6	26.5	0.000	0.851
Poorly differentiated adenocarcinoma	1	25.0	3.4	76.2	0.000	1.000
Salivary ductal carcinoma (SDC)	40	38.1	35.3	41.1	77.950	0.000
Squamous cell carcinoma	4	21.4	8.2	45.4	48.320	0.121

In the studies where the cut-off point was >50% for strongly positive, 5–50% weak positivity, and <5% for negative results, the expression rate of HER2/neu in SDC was 30% (CI 95%: 15.6–49.0%). Also, the summary expression rate of HER2/neu in MEC was 84% (CI 95%: 74.1–90.0%).

Finally, in the studies with a cut-off point of 50% for positive and 10% for negative results, the overexpression rate of HER2/neu in SDC was 33% (CI 95%: 13.1–62.4%), and the expression rate of HER2/neu in ACC was 2% (CI 95%: 0.2–31.0%).

### Benign salivary gland tumors

In benign tumors of the salivary gland, basal cell adenoma had an overexpression rate of HER2/neu of 2% (CI 95%: 0.1–27.7%), warthin tumor had an expression rate of 1% (CI 95%: 0.1–13.1). For myoepithelioma the summary expression rate of HER2/neu was 9% (CI 95%: 1.7–33.6%). Ultimately, the summary expression rate of HER2/neu for pleomorphic adenoma was 5% (CI 95%: 1.9–10.7%).

### Publication Bias

For publication bias analysis, a funnel plot and Egger's test with a P-value<0.1 were used. In malignant salivary gland tumors, studies involving SDC (p=0.001), squamous cell carcinoma (p=0.059), an acinic cell carcinoma (p=0.015), basal cell adenocarcinoma (BCAC) (p<0.001) and ACC (p=0.005) had significant publication biases.

There was no statistically significant publication bias for SDC in studies assessing the overexpression rate of HER2/neu using a cut-off point of 30% and 10% (p=0.98).

Among the studies assessing the expression rate of HER2/neu using a cut-off point of 10% and 50%, studies related to MEC had no statistically significant publication bias (p=0.90).

For benign salivary gland tumors, results reporting the rate of HER2/neu overexpression in myoepithelioma had no statistically significant publication bias (p=0.060), and studies assessing the expression rate of HER2/neu in pleomorphic adenomas had a statistically significant publication bias (p=0.06).

## DISCUSSION

HER2 overexpression has been studied as a prognostic factor as well as a target for therapy in some malignancies such as breast cancer [23]. Several studies found that despite the worse

prognosis of HER2 overexpressing tumors, targeted treatment with monoclonal antibodies such as Lapatinib and Trastuzumab resulted in prolonged event-free periods and overall survival rates. Nevertheless, several studies tried to evaluate the impact of HER2/neu overexpression on the prognosis of salivary gland tumors and showed that overexpression of HRE2/neu is a marker of poor prognosis independent of histopathological grade and tumor size [24–26].

In the present systematic review and meta-analysis, we found that 6 subtypes of malignant salivary gland tumors had positive HER2 rates higher than 20%, including salivary duct carcinoma in situ, SDC, CXPA, poorly differentiated adenocarcinoma, adenocarcinomas not otherwise specified (NOS), squamous cell carcinomas and mucoepidermoid carcinomas. Furthermore, HER2/neu overexpression was more prevalent in malignant salivary gland tumors than benign tumors. The rates varied among different subtypes of malignant tumors with different histopathological characteristics and levels of invasiveness, with SGCs having a high expression of HER2, specifically subtypes other than SDC and CXPA.

Similarly, Giannoni *et al.* [27], in a study of minor salivary gland tumors of the palate, reported that gender, tumor stage, and HER2/neu overexpression together are predictors of survival in patients with malignant tumors. The highest rate of overexpression of HER2/neu in benign tumors in this study was 9% for myoepithelioma, in contrast to malignant tumors, which had rates as high as 84% in MECs. Pooled positive rates of HER2/neu overexpression in CXPA tested by different IHC methods were 55% and 33.7%. For SDCs, the positive overexpression rate ranged from 30% to 41% based on the IHC method used.

Similar to the findings of our analysis, studies showed a significant difference in overexpression of HER2/neu between benign and malignant tumors [27]. Even though not all malignant salivary gland tumors showed high HER2/neu overexpression, the difference between overexpression in benign and malignant tumors can suggest an association between overexpression of HER2/neu and malignancy of the tumor.

There is an association between overexpression of HER2/neu and aggressive behavior in tumors [27]. This may explain the higher rate of overexpression in SDCs than other less aggressive subtypes of salivary gland tumors such as ACCs. Also, Shintani *et al.* [21], in a study of patients with ACCs using IHC, observed strong staining mostly in cells of the invasive area. That being said, metastatic potential and tumor recurrence were also associated with HER2/neu overexpression [28]. Differences in

the overexpression rates of HER2/neu were also observed in tumors of the same subtype but in different areas of origin [29–32].

Similar to breast cancer, studies have shown promising results in treating salivary gland cancers with a high HER2/neu overexpression, such as SDC and CXPA, with targeted therapy having HER2/neu as a molecular target [33–36]. For example, a recent phase II clinical trial assessing the efficacy and toxicity of trastuzumab plus docetaxel in 57 patients with locally advanced and/or recurrent or metastatic HER2+ SDC yielded a 70.2% overall response rate with a clinical benefit rate of 84.2%. This led Takahashi *et al.* [37] to conclude that this regimen is effective in treating HER2+ SDCs. Although there are studies with contrasting results, multiple factors, such as a small number of included patients in the studies, make it difficult to draw a conclusion [38–42].

These results suggest the possibility of promising outcomes for patients with HER2+ salivary gland tumors being treated with targeted therapy. In addition to this, we can conclude that anti-HER2 therapy may be effective for treating patients with other subtypes of salivary gland tumors with a high overexpression of HER2/neu. However, a series of carefully designed studies are required to reach a consensus.

Notably, HER2/neu positivity ranges vary between studies, which can be due to several factors. Besides the tumor heterogeneity, the impreciseness of techniques used to detect HER2/neu overexpression can be a cause for this variability. This inconsistency in HER2 testing results is due to various reasons, including limitations in IHC techniques and a lack of uniform cut-off values and protocols. While there is a HER2 testing guideline for breast cancers [43], there are no definitive algorithms for defining positive, negative, and equivocal values for HER2/neu expression in salivary gland tumors. There are multiple cut-off points for IHC overexpression which vary from 10% [44] and 30% [45] to 50% [46]. A universal guideline suggesting a uniform approach to IHC in salivary ductal tumors can resolve this issue.

There are a number of limitations in this meta-analysis. The first limitation is publication bias. We used funnel plot determination to evaluate publication bias and performed Egger's test to confirm the results. However, each study included in this meta-analysis is susceptible to bias. For instance, we only included the published English articles. Positive studies are accepted more commonly in English language journals, yet studies yielding negative results, more often than not, are submitted to native journals. Also, including only full published studies and excluding journals with incomplete data may cause bias.

Heterogeneity is the second limitation, as high heterogeneity was observed among the studies in regards to the rate of HER2/neu overexpression. Several factors can result in heterogeneity among studies. For example, different baseline characteristics in patients (such as age, ethnicity, tumor stages), differences in methods of sampling, and their effects on IHC detection, such as fragmentation during the biopsy process, can increase the edge effect, thus causing stronger staining at the circumference, differences in materials used in the process.

Also, because only a limited number of studies are eligible, some of the studies had relatively small sample sizes and a weaker level of evidence.

Finally, the complexities in the mechanisms involved in tumorigenesis and the relationship between various factors determining the expression of certain proteins and tumor invasiveness should be considered. Consequently, the effectiveness of HER2-targeted therapy must be further examined. The results of this study showed that HER2/neu overexpression was asso-

ciated with a high level of invasiveness and malignancy of the tumor. Therefore, functions of HER2 in the aggressive behavior of certain types of salivary duct carcinomas must be further investigated.

## CONCLUSION

To our knowledge, this study is the first systematic review and meta-analysis that evaluated the overexpression rates of HER2/neu in patients with various subtypes of salivary gland tumors. The results showed that HER2/neu overexpression was more prevalent in malignant salivary gland tumors than benign tumors. Also, the rates varied among different subtypes of malignant tumors with different histopathological characteristics and levels of invasiveness. Also, the results suggest the possibility of using novel targeted therapy regimens for treating patients with SGCs having a high expression of HER2, specifically subtypes other than SDC and CXPA. Having said that, the results of this systematic review should be carefully interpreted regarding the discussed limitations. Therefore, large-high-quality prospective studies must be performed to confirm the results.

## ACKNOWLEDGMENTS

### Conflicts of interest

The authors declare no conflict of interest.

### Data availability

Further data is available from the corresponding author on reasonable request.

### Authorship

AJ, MK, MVS contributed to conceptualizing the study. MVS, NV, LFG contributed to the methodology. AJ, MK contributed to writing the original draft and editing the manuscript. AJ contributed to data collection. AJ, NV, LFG contributed to the data analysis.

## REFERENCES

- Speight PM, Barrett AW. Salivary gland tumours. *Oral diseases*. 2002; 8(5):229-40. doi: 10.1034/j.1601-0825.2002.02870.x.
- Hosni A, Huang SH, Goldstein D, Xu W, *et al.* Outcomes and prognostic factors for major salivary gland carcinoma following postoperative radiotherapy. *Oral oncology*. 2016;54:75-80. doi: 10.1016/j.oraloncology.2015.11.023.
- Boukheris H, Curtis RE, Land CE, Dores GM. Incidence of carcinoma of the major salivary glands according to the WHO classification, 1992 to 2006: a population-based study in the United States. *Cancer Epidemiology and Prevention Biomarkers*. 2009;18:2899-906. doi: 10.1158/1055-9965.EPI-09-0638.
- Laurie SA, Licitra L. Systemic therapy in the palliative management of advanced salivary gland cancers. *J Clin Oncol*. 2006;24(17):2673-8. doi: 10.1200/JCO.2005.05.3025.
- Etl T, Schwarz-Furlan S, Gosau M, Reichert TE. Salivary gland carcinomas. Oral and maxillofacial surgery. 2012;16(3):267-83. doi: 10.1007/s10006-012-0350-9.
- Sood S, McGurk M, Vaz F. Management of salivary gland tumours: United Kingdom national multidisciplinary guidelines. *The Journal of Laryngology & Otology*. 2016;130(S2):S142-9. doi: 10.1017/S0022215116000566.
- A Baudino T. Targeted cancer therapy: the next generation of cancer treatment. *Current drug discovery technologies*. 2015;12(1):3-20. doi: 10.2174/1570163812666150602144310.
- Perez EA, Barrios C, Eiermann W, Toi M, *et al.* trastuzumab emtansine with or without pertuzumab *versus* trastuzumab plus taxane for human epidermal growth factor receptor 2-positive, advanced breast cancer: primary results from the phase III MARIANNE study. *Journal of Clinical Oncology*. 2017;35(2):141. doi: 10.1200/JCO.2016.67.4887.

9. Zhao D, Chen X, Qin N, Su D, *et al.* The prognostic role of EGFR-TKIs for patients with advanced non-small cell lung cancer. *Scientific reports.* 2017;7:40374. doi: 10.1038/srep40374.
10. Li X, Yin X, Wang H, Huang J, *et al.* The combination effect of homoharringtonine and ibrutinib on FLT3-ITD mutant acute myeloid leukemia. *Oncotarget.* 2017;8(8):12764. doi: 10.18632/oncotarget.14463.
11. Négrier S, Gravis G, Pérol D, Chevreau C, *et al.* Temsirolimus and bevacizumab, or sunitinib, or interferon alfa and bevacizumab for patients with advanced renal cell carcinoma (TORAVA): a randomised phase 2 trial. *The lancet oncology.* 2011;12:673-80. doi: 10.1016/S1470-2045(11)70124-3.
12. Antoniou EA, Koutsounas I, Damaskos C, Koutsounas S. Remission of psoriasis in a patient with hepatocellular carcinoma treated with sorafenib. *In Vivo.* 2016;30(5):677-80.
13. Popescu NC, King CR, Kraus MH. Localization of the human erbB-2 gene on normal and rearranged chromosomes 17 to bands q12-21.32. *Genomics.* 1989;4(3):362-6. DOI: 10.1016/0888-7543(89)90343-1
14. Akiyama T, Sudo C, Ogawara H, Toyoshima K, Yamamoto T. The product of the human c-erbB-2 gene: a 185-kilodalton glycoprotein with tyrosine kinase activity. *Science.* 1986;232(4758):1644-6. doi: 10.1126/science.3012781.
15. Yamamoto T, Ikawa S, Akiyama T, Semba K, *et al.* Similarity of protein encoded by the human c-erbB-2 gene to epidermal growth factor receptor. *Nature.* 1986;319(6050):230-4. doi: 10.1038/319230a0.
16. Press MF, Cordon-Cardo C, Slamon DJ. Expression of the HER-2/neu proto-oncogene in normal human adult and fetal tissues. *Oncogene.* 1990;5:953-62.
17. Venter D, Kumar S, Tuzi N, Gullick W. Overexpression of the c-erbB-2 oncoprotein in human breast carcinomas: immunohistological assessment correlates with gene amplification. *The Lancet.* 1987;330(8550):69-72. doi: 10.1016/s0140-6736(87)92736x.
18. Semba K, Kamata N, Toyoshima K, Yamamoto T. A v-erbB-related proto-oncogene, c-erbB-2, is distinct from the c-erbB-1/epidermal growth factor-receptor gene and is amplified in a human salivary gland adenocarcinoma. *Proceedings of the National Academy of Sciences.* 1985;82(19):6497-501. doi: 10.1073/pnas.82.19.6497.
19. Hall PA, Hughes CM, Staddon SL, Richman PI, *et al.* The c-erbB-2 proto-oncogene in human pancreatic cancer. *The Journal of pathology.* 1990;161(3):195-200. doi: 10.1002/path.1711610305.
20. Sugano S, Mukai K, Tsuda H, Hirohashi S, *et al.* Immunohistochemical study of c-erbB-2 oncoprotein overexpression in human major salivary gland carcinoma: an indicator of aggressiveness. *The Laryngoscope.* 1992;102:923-7. doi: 10.1288/00005537-199208000-00013.
21. Shintani S, Funayama T, Yoshihama Y, Alcalde RE, *et al.* expression of c-erbB family gene products in adenoid cystic carcinoma of salivary glands: an immunohistochemical study. *Anticancer Res.* 1995 Nov-Dec;15(6B):2623-6.
22. Gibbons MD, Manne U, Carroll WR, Peters GE, *et al.* Molecular differences in mucoepidermoid carcinoma and adenoid cystic carcinoma of the major salivary glands. *The Laryngoscope.* 2001;111:1373-8. doi: 10.1097/00005537-200108000-00011.
23. Joensuu H, Kellokumpu-Lehtinen PL, Bono P, Alanko T, *et al.* Trastuzumab in Combination with Vinorelbine or Docetaxel as Adjuvant Treatment of Breast Cancer with HER-2 Gene Amplification. *New England Journal of Medicine.* 2006(354):809-20. doi: 10.1056/NEJMoa053028.
24. Press MF, Pike MC, Hung G, Zhou JY, *et al.* Amplification and overexpression of HER-2/neu in carcinomas of the salivary gland: correlation with poor prognosis. *Cancer research.* 1994;54(21):5675-82.
25. Nguyen LH, Black MJ, Hier M, Chauvin P, Rochon L. HER2/neu and Ki-67 as prognostic indicators in mucoepidermoid carcinoma of salivary glands. *Journal of otolaryngology.* 2003;32(5). doi: 10.2310/7070.2003.11438.
26. Agulnik M, Siu LL. An update on the systemic therapy of malignant salivary gland cancers: role of chemotherapy and molecular targeted agents. *Current Medicinal Chemistry-Anti-Cancer Agents.* 2004;4(6):543-51. doi: 10.2174/1568011043352641.
27. Giannoni C, El-Naggar AK, Ordóñez NG, Nora Tu Z, *et al.* c-erbB-2/neu oncogene and Ki-67 analysis in the assessment of palatal salivary gland neoplasms. *Otolaryngology-Head and Neck Surgery.* 1995;112:391-8. doi: 10.1016/s0194-5998(95)70272-5.
28. Etges A, Pinto DS, Kowalski LP, Soares FA, Araujo VC. Salivary duct carcinoma: immunohistochemical profile of an aggressive salivary gland tumour. *Journal of clinical pathology.* 2003;56:914-8. doi: 10.1136/jcp.56.12.914.
29. Glisson B, Colevas AD, Haddad R, Krane J, *et al.* HER2 expression in salivary gland carcinomas: dependence on histological subtype. *Clinical Cancer Research.* 2004;10(3):944-6. doi: 10.1158/1078-0432.ccr-03-0253.
30. Hashimoto K, Yamamoto H, Shiratsuchi H, Nakashima T, *et al.* HER-2/neu gene amplification in carcinoma ex pleomorphic adenoma in relation to progression and prognosis: a chromogenic in-situ hybridization study. *Histopathology.* 2012;60(6B):E131-42. doi: 10.1111/j.1365-2559.2012.04201.x.
31. Bang YJ, Van Cutsem E, Feyereislova A, Chung HC, *et al.* ToGA Trial Investigators. Trastuzumab in combination with chemotherapy versus chemotherapy alone for treatment of HER2-positive advanced gastric or gastro-oesophageal junction cancer (ToGA): a phase 3, open-label, randomised controlled trial. *The Lancet.* 2010;376(9742):687-97. doi: 10.1016/S0140-6736(10)61121-X.
32. Wolff AC, Hammond ME, Schwartz JN, Hagerty KL, *et al.* American Society of Clinical Oncology/College of American Pathologists guideline recommendations for human epidermal growth factor receptor 2 testing in breast cancer. *Archives of pathology & laboratory medicine.* 2007;131:18-43. doi: 10.5858/2007-131-18-ASOCCO.
33. Johnson CJ, Barry MB, Vasef MA, DeYoung BR. Her-2/neu expression in salivary duct carcinoma: an immunohistochemical and chromogenic in situ hybridization study. *Applied Immunohistochemistry & Molecular Morphology.* 2008;16:54-8. doi: 10.1097/PAL.0b013e31802e91b2.
34. Nashed M, Casasola RJ. Biological therapy of salivary duct carcinoma. *The Journal of laryngology and otology.* 2009;123:250. doi: 10.1017/S0022215108002314.
35. Sharon E, Kelly RJ, Szabo E. Sustained response of carcinoma ex pleomorphic adenoma treated with trastuzumab and capecitabine. *Head & Neck Oncology.* 2010;2(1):1-3. doi: 10.1186/1758-3284-2-12.
36. Kadowaki S, Yatabe Y, Hirakawa H, Komori A, *et al.* Complete response to trastuzumab-based chemotherapy in a patient with human epidermal growth factor receptor-2-positive metastatic salivary duct carcinoma ex pleomorphic adenoma. *Case reports in oncology.* 2013;6(3):450-5. doi: 10.1159/000355219.
37. Takahashi H, Tada Y, Saotome T, Akazawa K, *et al.* Phase II trial of trastuzumab and docetaxel in patients with human epidermal growth factor receptor 2-positive salivary duct carcinoma. *J Clin Oncol.* 2019;37(2):125-34. doi: 10.1200/JCO.18.00545.
38. Haddad R, Colevas AD, Krane JF, Cooper D, *et al.* Herceptin in patients with advanced or metastatic salivary gland carcinomas. A phase II study. *Oral oncology.* 2003;39(7):724-7. doi: 10.1016/s1368-8375(03)00097-6.
39. Perissinotti AJ, Pierce ML, Pace MB, El-Naggar A, *et al.* The role of trastuzumab in the management of salivary ductal carcinomas. *Anticancer research.* 2013;33(6):2587-91.
40. Eitl T, Schwarz S, Kleinsasser N, Hartmann A, *et al.* Overexpression of EGFR and absence of C-KIT expression correlate with poor prognosis in salivary gland carcinomas. *Histopathology.* 2008;53(5):567-77. doi: 10.1111/j.1365-2559.2008.03159.x.
41. Cornolti G, Ungari M, Morassi ML, Facchetti F, *et al.* Amplification and overexpression of HER2/neu gene and HER2/neu protein in salivary duct carcinoma of the parotid gland. *Archives of otolaryngology-head & neck surgery.* 2007;133:1031-6. doi: 10.1001/archotol.133.10.1031.
42. Williams MD, Roberts DB, Kies MS, Mao L, *et al.* Genetic and expression analysis of HER-2 and EGFR genes in salivary duct carcinoma: empirical and therapeutic significance. *Clinical cancer research.* 2010;16(8):2266-74. doi: 10.1158/1078-0432.CCR-09-0238.
43. Wolff AC, Hammond ME, Hicks DG, Dowsett M, *et al.* American Society of Clinical Oncology; College of American Pathologists Recommendations for human epidermal growth factor receptor 2 testing in breast cancer: American Society of Clinical Oncology/College of American Pathologists clinical practice guideline update. *Archives of Pathology and Laboratory Medicine.* 2014;138:241-56. doi: 10.5858/arpa.2013-0953-SA.
44. Szweczyk M, Marszałek A, Sygut J, Goluśiński P, Goluśiński W. Prognostic markers in salivary gland cancer and their impact on survival. *Head & neck.* 2019;41:3338-47. doi: 10.1002/hed.25857.
45. Limaye SA, Posner MR, Krane JF, Fonfria M, *et al.* Trastuzumab for the treatment of salivary duct carcinoma. *The oncologist.* 2013;18:294. doi: 10.1634/theoncologist.2012-0369.
46. Nardi V, Sadow PM, Juric D, Zhao D, *et al.* Detection of novel actionable genetic changes in salivary duct carcinoma helps direct patient treatment. *Clinical cancer research.* 2013;19(2):480-90. doi: 10.1158/1078-0432.CCR-12-1842.