



Transcatheter Closure of Atrial Septal Defect with Amplatzer Septal Occluder in Adults: Immediate, Short, and Intermediate-Term Results

Mostafa Behjati, MD*, Mansour Rafiei, MD, Mohammad Hossein Soltani, MD, Mahmoud Emami, MD, Majid Dehghani, MD

Afshar Hospital, Shahid Sadoughi University of Medical Sciences, Yazd, Iran.

Received 31 March 2010; Accepted 05 February 2011

Abstract

Background: The transcatheter closure of the atrial septal defect (ASD) has become an alternative technique to surgical procedures. The aim of this study was to assess the immediate, short, and intermediate-term results of the transcatheter closure of the secundum ASD with the Amplatzer Septal Occluder (ASO) in adult Iranian patients.

Methods: Between December 2004 and July 2008, the transcatheter closure of the ASD using the ASO was attempted in 58 consecutive, adult patients. The mean age of the patients was 37.1 ± 12.7 years (range = 19 - 75 years).

All the procedures were performed under local anesthesia with transthoracic or transesophageal echocardiography and fluoroscopic guidance. The stretched diameter of the ASD was determined with a balloon sizing catheter, and device selection was based on and matched to the stretched diameter of the septal defect.

Transthoracic echocardiography was performed immediately after the release of the device and before discharge. Further follow-up at one month, six months, and yearly thereafter included physical examination, electrocardiography, and transthoracic echocardiography.

Results: The mean ASD diameter, as measured by esophageal echocardiography, was 24.8 ± 5.4 mm (range = 13 - 34 mm). The mean stretched diameter, as measured by the balloon catheter, was 27.1 ± 6.4 mm (range = 12.5 - 39 mm). Deployment of the ASO was successful in 52 (89.6%) patients and failed in 6 (10.4%). Four patients experienced severe complications, 1 had tamponade requiring drainage, 2 had device embolization to the left atrium and right ventricular outflow tract, and 1 had late wire fracture (surgical removal and repair of the ASD). The position of two large devices (34 mm and 36 mm) was considered unsuitable and unstable after implantation and resulted in the removal of these devices.

Minor complications included transient complete atrioventricular block in 1 patient, paroxysmal supra tachycardia in 3 patients, atrial flutter in 1 patient, and angina pectoris with transient ST elevation in 2 patients. The mean follow-up period was 32.5 ± 18.5 months. Echocardiography at 24 hours, 1 month, 6 months, and 12 months after the procedure showed residual shunts in 11 (21%), 3 (5.8%), 2 (3.8%), and 2 (3.8%) patients, respectively. At follow-up (12.8 months to 48.5 months, mean \pm SD = 32.5 ± 18.5 months), complete closure was documented in 50 (96.2%) of the 52 cases. At the end of the follow-up, 2 (3.8%) patients had residual shunts: The shunt was moderate in 1 (1.9%) patient and small in the other (1.9%). The overall success rate of the transcatheter closure of the ASD was 86% (50 of 58 cases).

Conclusion: The transcatheter closure of the secundum ASD in our adult patient population using the ASO was associated with high degrees of success, minimal procedural complication rates, and excellent short and midterm results. The use of this device, however, requires thorough attention in that the procedure may be ineffective or the device may embolize. Further experience and long-term follow-up are required before a widespread clinical use can be recommended.

J Teh Univ Heart Ctr 2011;6(2):79-84

*Corresponding Author: Mostafa Behjati, Associate Professor of Pediatric Cardiology, Division of Pediatric Cardiology, Shahid Sadoughi University of Medical Science, Afshar Hospital, Jomhoury Boulevard, Yazd, Iran. 8917945556. Tel: +98 351 5231421. Fax: +98 351 5253335. E-mail: dr_behjati@yahoo.com.

This paper should be cited as: Behjati M, Rafiei M, Soltani M. H, Emami M, Dehghani M. Transcatheter Closure of Atrial Septal Defect with Amplatzer Septal Occluder in Adults: Immediate, Short, and Intermediate-Term Results. *J Teh Univ Heart Ctr* 2011;6(2):79-84.

Keywords: *Septal occluder device • Heart septal defects, atrial • Adult • Treatment outcome*

Introduction

The atrial septal defect (ASD) is the third most common form of congenital heart anomalies.¹ For several decades, surgical closure has been considered the standard method of repairing a secundum ASD.² Surgical repair, albeit enjoying a high success rate, negligible mortality, and good long-term outcome, is associated with morbidity, discomfort, and thoracotomy scars.³ That is why the transcatheter closure of the ASD has more recently become an alternative to the surgical procedure.⁴ The transcatheter closure of the ASD was first described by King et al. in 1976.⁵ Currently, there are multiple devices clinically available with variable degrees of success; none of them, however, is fully satisfactory inasmuch as they cannot be utilized to completely close defects > 20 mm and they frequently allow residual shunting.⁶

During the last decade, the Amplatzer septal occluder (ASO), with its unique design and easy handling, has finally replaced surgical ASD repair in most adult patients as the standard method of repair for the secundum ASD.^{7, 8} We herein report our immediate, short, and intermediate-term results of the ASO use for the non-surgical transcatheter closure of the ASD in adults.

Methods

Between December 2004 and July 2008, 58 out of 68 consecutive patients with a significant ASD, as demonstrated by initial transthoracic echocardiography (TTE), were considered for transcatheter closure with the ASO. The inclusion criteria for the patients with the ASD were: (1) the presence of a secundum ASD with a significant left-to-right shunt (pulmonary to systemic flow ratio [QP/QS] $\geq 1.5/1$); (2) an ASD with a balloon stretched diameter ≤ 39 mm with a suitable septal rim of at least 5 mm from the mitral and tricuspid valves; and (3) right ventricular overload. Ten patients were excluded from the analysis for the following reasons: (1) The defect was too large for occlusion (1 patient); (2) there was severe pulmonary artery hypertension (pulmonary artery systolic pressure > 80 mmHg and pulmonary artery resistance > 8 woods) (2 patients); and (3) there were small superior, inferior, or posterior rims of the ASD during the TEE examination or balloon stretch sizing (6 patients). One patient showed drainage of the right pulmonary vein into the superior vena cava. Finally, 58 patients underwent the transcatheter closure of the ASD

with the ASO. Informed consent was obtained from all the patients or their guardians.

The principle of the device is based on the conjoint waist "stenting" the ASD, providing both fixation and occlusion. The ASO is a self-centering and self-extracting occlusion device made from a nitinol wire mesh forming a left atrial retention disc, a self-centering stent, and a right atrial disc. The ASO is available in sizes with one-mm increments from four mm to twenty mm and then in two-mm increments up to the current largest device of forty mm. The device is attached to a delivery cable by a central screw at the proximal end of the device, and it is compressed into a loader by pulling on the delivery wire. A 6F to 12F delivery sheath is used depending on the required size of the device.

Before catheterization, all the patients were evaluated via transthoracic (TTE) and transesophageal echocardiography (TEE) was conducted under local anesthesia and moderate conscious sedation with midazolam (3-5 mg) using a Hewlett-Packard Sonos 4000 or Vivid 4 (QE- Vingmed Ultrasound AS) echocardiography device and a nine-MHZ probe to evaluate the size, location, and margin of the defect.

All the procedures were performed under local anesthesia and moderate sedation, with transthoracic and fluoroscopy guidance throughout. First, a standard right-heart catheterization was carried out through the right femoral vein with recording of the blood pressure and blood sampling to calculate the QP/QS ratio. The right upper pulmonary vein angiography in the hepatoclavicular view was performed to visualize the atrial septum.

For endocarditis prophylaxis, the patients received cefazolin (1g IV) thirty minutes before the procedure, followed by 1g IV every eight hours for an additional two doses. After sheath placement, all the patients received intravenous heparin (100 IU/kg) and maximum 5000 IU was administered intravenously.

A sizing balloon catheter (AGA Medical Golden Valley, MN) was inflated at the level of the defect until the waist in the middle of the balloon was seen (Figure 1). The waist was measured and calibrated on the cine-angiographic frame together with a calibrated template. A device with a waist diameter similar to the stretched ASD diameter; or in the large defects, up to two mm larger than the stretched ASD diameter, was chosen. The selected ASO was attached to the delivery cable via the screw mechanism and was loaded by being withdrawn into the loader through traction on the delivery cable.

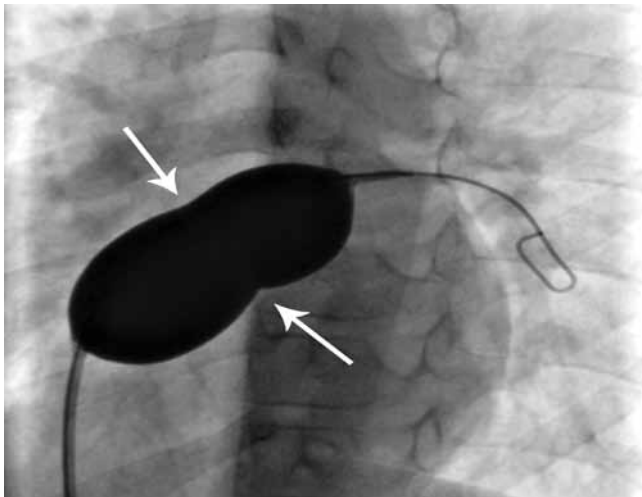
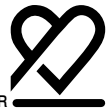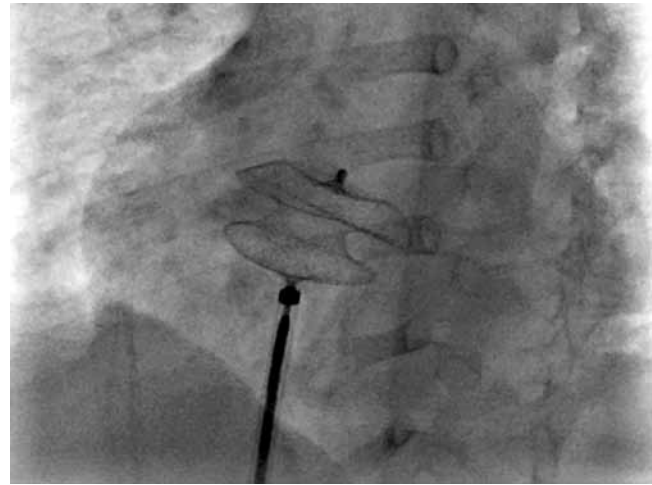


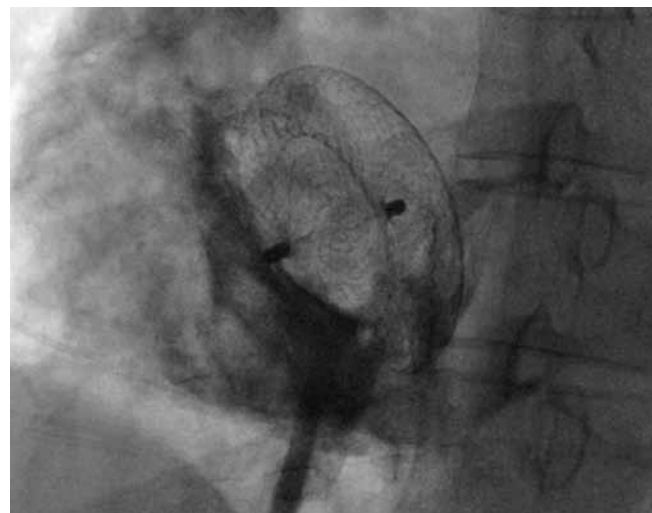Figure 1. Sizing procedure using sizing balloon catheter; waist of the balloon clearly indicates the stretch diameter of the atrial septal defect (arrows)

The compressed ASO was then advanced through the long sheath that had previously been positioned in the left atrium. Under fluoroscopic control, the left atrial disc was extruded by advancing the delivery cable. After the distal disc was deployed in the middle left atrium, the delivery system was gently pulled back against the atrial septum. The ASO was thereafter fully deployed by withdrawing the sheath over the delivery cable to expand the right atrial disc. The position and stability of the ASO was assessed by fluoroscopy and TTE. Care was taken to ensure that the device did not obstruct the right pulmonary veins, caval veins, coronary sinus, or the mitral valve. Any residual shunt was evaluated by two-dimensional color-flow Doppler. The residual shunt was defined as a leak traversing or passing between the two discs of the ASO or around the device edges to the right atrium and was detected by two-dimensional color-flow Doppler. The residual shunt was classified according to the color-jet width describe by Boutin and her colleagues¹⁰ as trace < 1 mm, 2 mm > small > 1mm, 4 mm > moderate > 2 mm, and large > 4 mm. If the width of the color Doppler flow was < 2mm, 2-4mm, and > 4mm; the residual shunts were classified as mild, moderate, and severe, respectively. The device was subsequently released from the delivery system, and final assessment of the position of the device was made via TTE. After the release of the device, right atrium angiography with follow-through was carried out in the hepatoclavicular projection (Figure 2).

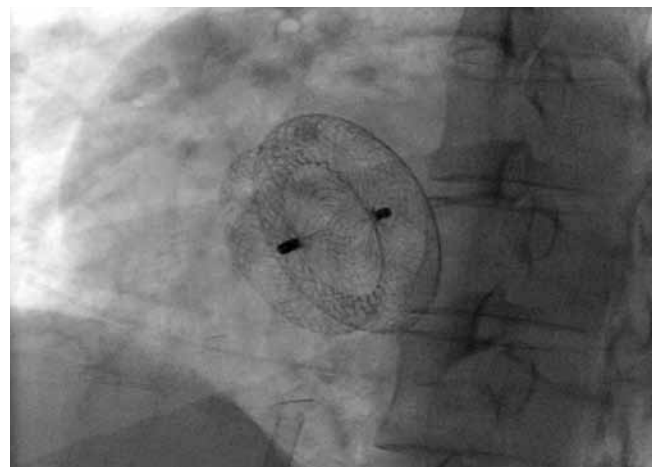
As a matter of routine, after ASD closure, the patients remained in the general ward of the hospital for one night and received heparin 100 IU/kg/daily (partial thromboplastin time [PTT] 50-60 seconds) for twenty-four hours. TTE was performed twenty-four hours after the procedure and before hospital discharge to ensure the suitable deployment of the device and to look for any residual shunt.



A



B



C

Figure 2. Transcatheter closure steps by fluoroscopy. Deployment of the left and right discs of an Amplatzer device with the central waist stenting the atrial septal defect (A); contrast injection in right atrium showing suitable device position and no residual shunt through the device (B); and complete deployment of the Amplatzer septal occluder after release of device from delivery cable (C)

The patients were discharged on ticlopidine (250 mg/day) for one month and aspirin (80 mg/day) for six months in order to prevent excessive thrombus formation on the device. Standard bacterial endocarditis prophylaxis was recommended for six months or until complete closure had been achieved. Repeat TTE was performed one, six, and twelve months after the procedure and yearly thereafter.

Efficacy was defined as the successful closure of the defect without residual shunts or only trivial shunts after six months, and safety was defined as the avoidance of death or major complications such as cerebral embolism, cardiac tamponade, device embolization or dislodgement requiring open cardiac surgery, and infectious endocarditis. TTE is a reliable technique for the evaluation of residual shunts;⁹ therefore, residual shunting in the wake of device closure was evaluated via two-dimensional color-flow Doppler echocardiography.¹⁰

All the data were collected on a set data sheet, collated by a single coordinator, and entered into a common database for analysis. The data were expressed as mean \pm standard deviation, median, range, and percentage. The data were analyzed using the SPSS software version 13.0.

Results

Between December 2004 and July 2008, the transcatheter closure of the ASD was conducted in 58 of 68 consecutive patients who presented at our institution. On account of the fact that the position of two large devices (34 mm, 36 mm) was considered unstable or unsuitable after implantation, these two devices were not released and were withdrawn. There were four major procedure-related complications. The ASD was successfully implanted in 52 patients (female/male: 3.3/1).

The patients' demographics and procedure characteristics are depicted in Table 1.

The mean age of the study population was 37.1 ± 12.7 years (median = 36 years, range = 19 - 75 years). The mean body weight was 59.9 ± 11.5 kg (median = 58 kg, range = 42 - 88 kg). On TEE, the mean defect diameter was 24.8 ± 5.4 mm (median = 26 mm, range = 13 - 34 mm).

The balloon stretch diameter of the ASD varied between 12.5 and 39 mm (mean = 27.1 ± 6.4 mm). The pulmonary to systemic shunt ratio (QP/QS) ranged from 1.6 to 5.8 (mean 2.7 ± 0.85). The average pulmonary artery pressure was 23.4 ± 7 mmHg (range = 12 - 48 mmHg). The average procedure time and fluoroscopy time were 46.1 ± 12.9 minutes (range = 25 - 80 minutes) and 8.9 ± 4.1 minutes (range = 3.8 - 20 minutes) respectively, with a tendency to shorter procedural and screening time after the learning curve. The mean follow-up period was 32.5 ± 18.5 months (range = 12.8 - 48.5 months).

At the end of the procedure, on color flow Doppler, residual

shunting (including foaming through the wire mesh of the device.) was seen in 30 (58%) of the 52 patients. By the time of discharge, the rate of the residual shunt had decreased to 21% (11 patients). The residual shunt remained persistent, however, 6 months after the procedure in 3 patients. At the end of the follow-up, the residual shunt was detected in 2 patients. One patient with a mild residual shunt at the time of discharge worsened; the shunt was adjudged moderate one month after the procedure and this moderate shunt persisted at one year's follow-up.

Repeat TTE at twelve months' follow-up showed device wire fracture and malposition to the right atrium. The device was removed at surgery, during which the ASD was closed as well. Finally, follow-up echocardiography at twenty-four hours, one month, six months, and one year after the procedure showed complete closure rates of 79%, 94.2%, 94.2%, and 96.2%, respectively (excluding 4 patients with major complications and 2 patients with unstable-unsuitable device position).

There were 4 major procedure-related complications: one device embolization to the right ventricle, one device embolization to the left atrium, one left atrium perforation, and one device wire fracture. The left atrium perforation case and cardiac tamponade necessitated emergency surgery. The embolized devices were retrieved at surgery, during which the ASD was closed without further complications. There was no cardiac death during the study.

There were 7 other documented complications. Two patients developed transient ST-elevation, which cleared within a short period of time; these were attributed to small air emboli. Another patient developed transient complete atrioventricular block during the manipulation of the delivery system and the ASD in the left atrium; it cleared spontaneously and was not associated with any hemodynamic compromise. Three patients presented with supraventricular tachycardia, which was spontaneously resolved in 2 patients and was reverted in the other case with verapamil. A 45-year-old woman developed persistent atrial flutter one month after uncomplicated ASD closure with a 36-mm ASD. In this patient, long-term maintenance of sinus rhythm was achieved with propranolol and amiodarone. One patient had a new onset of migraine-type headaches during the first month after the procedure, which was spontaneously resolved six months subsequently.

At a mean follow-up period of 32.5 ± 18.5 months (range = 12.8 - 48.5 months, median = 30 months), all the defects, with the exception of two cases with moderate and small shunts, were completely closed and remained closed afterwards. Also, the integrity of the ASD was evaluated using echocardiography in all the cases. One late device wire fracture was observed; the device was retrieved at surgery and the ASD was closed at the same time.



Discussion

The percutaneous closure of the ASD first and foremost obviates thoracotomy, open heart surgery, and admission to an intensive care unit and thus avoids subsequent surgical scars and postoperative pain. The other advantages of this treatment modality include fewer psychological impacts, shorter hospital stays, and lesser need for blood transfusion.^{11, 12} Furthermore, the absence of atrial myocardial scar may reduce the incidence of incisional dysrhythmias.¹¹

The transcatheter closure of the ASD is an established technique with a low incidence of morbidity and mortality, and an important advantage of the ASO is that it can be easily retrieved into the delivery sheath and re-deployed several times before final release. This greatly diminishes the risk of the malposition and embolization of the device. We believe that a thorough device size selection is of paramount importance; this depends on an accurate assessment of the stretched diameter of the ASD because the device is matched to the size of the stretched ASD diameter. An oversized device can cause the distortion of the retention discs and impinge on sensitive structures, while an undersized device may result in residual shunting and the early or even late embolization of the device. TEE monitoring of the procedure to ensure the correct positioning of the device before and after its release is also essential. In our study, the devices were deployed without TEE monitoring, as a result of which the chance of embolization of the device increased significantly (2 cases [3.5%])

After the deployment, the residual shunt is a major concern when a septal occluder is employed for the transcatheter closure of the ASD. In our patients, there was 1 small and 1 clinically important residual shunt at one year's follow-up. A small residual shunt after device closure does not seem to lead to long-term problems. The low incidence of residual

shunts could be an important advantage for the ASO over other devices designed for the closure of the secundum ASD.¹³

Cardiac perforation is a rare procedure-related complication.¹⁴ In our study, cardiac perforation occurred in the antero-superior atrial wall; the patient underwent the surgical repair of the perforation and closure of the ASD. The ASO-associated cardiac perforation has been recorded predominantly in the antero-superior atrial wall and/or the adjacent aorta.¹⁴

In our study, embolization occurred in 2 (3.5%) patients. The device was deployed without TEE monitoring, resulting in a significant occurrence rate of device embolization. Residual shunts and serious complications have low incidence post-ASO implantation.^{9, 15, 16} In our experience, the incidence of the residual shunt was low and only 1 (1.9%) patient had a moderate residual shunt at mid-term follow-up. Chiming in with other studies, device embolization /malposition was the most common major complication in our study.¹⁷⁻²⁰ Overall, the literature supports the notion that the treatment of the secundum ASD via transcatheter occlusion is associated with complications, but the trend is towards lower complications using the newer transcatheter with the ASO. Avoidance of complications is dependent on careful case selection, sizing of the defect, selection of the suitable size of the device, prevention of air embolism, and TEE monitoring during the transcatheter procedure.

The results of our study of the transcatheter ASD closure with the ASO in 52 patients, with a complete occlusion rate of 79% (41 cases) at twenty-four hours, 94.2% (49 cases) at one month, 94.2% (49 cases) at six months, and 96.2% (52 cases) at twelve months and the overall success rate of 86% (50 of 58) (including complications and residual shunts), concur with the results reported in previous studies.¹⁹⁻²³ Our results demonstrate that the ASO device is particularly useful in most adults with the secundum ASD.

Table 1. Patients' demographic and procedural details, n=52

| | Mean | SD | Median | Range |
|---------------------------|------|------|--------|-----------|
| Age (y) | 37 | 12.7 | 36 | 19-75 |
| Gender (F/M) | - | - | - | 3.3/1 |
| Weight (kg) | 59.9 | 11.5 | 58.2 | 42-88 |
| QP/QS | 2.7 | 0.85 | 2.5 | 1.6-5.8 |
| Average PAP (mmHg) | 23.4 | 6.98 | 23 | 12-48 |
| Size of ASD with TEE | 24.8 | 5.4 | 26 | 13-34 |
| Size of ASD with SBC (mm) | 27.1 | 6.4 | 27.5 | 12.5-39 |
| ASO size (mm) | 27.9 | 6.2 | 28 | 14-40 |
| FT (min) | 8.9 | 4.1 | 7.30 | 3.8-20 |
| PT (min) | 46.1 | 12.9 | 44 | 25-80 |
| F/U (mo) | 32.5 | 18.5 | 30 | 12.8-48.5 |

SD, Standard deviation; F, Female; M, Male; QP/QS, Pulmonary to systemic flow ratio; PAP, Pulmonary artery pressure; ASD, Atrial septal defect; TEE, Transesophageal echocardiography; SBC, Sizing balloon catheter; ASO, Amplatzer septal occluder; FT, Fluoroscopy time; PT, Procedure time; F/U, Follow-up

Conclusion

In summary, the ASO can be used successfully to close selected secundum ASDs in most adult patients with low complication rates and good short and intermediate-term outcomes. Be that as it may, the utilization of this device requires careful attention in that the procedure may be unsuccessful or the device may embolize. Strict case selection criteria, expertise, and meticulous device selection may help reduce, although not completely eliminate, the incidence of complications such as device embolization. The device may show short and intermediate-term good results but further experience and long-term observation of patients treated with the transcatheter procedure is needed in order to draw definite conclusions.

Acknowledgements

Mostafa Behjati, MD, was supported in part by a grant from the Yazd Cardiovascular Research Center and Shahid Sadoughi University of Medical Sciences. We thank MH Ahmadi, PhD, for statistical analysis.

We gratefully acknowledge Majid Dehghani, MD, who helped to establish this procedure in Afshar Hospital.

References

1. Dickinson DF, Arnold R, Wilkinson JL. Congenital heart disease among 160 480 liveborn children in Liverpool 1960 to 1969. Implications for surgical treatment. *Br Heart J* 1981;46:55-62.
2. Kouchoukos NT, Blackstone EH, Doty DB. Congenital heart disease, atrial septal defect and partial anomalous pulmonary venous connection. In: Honley FL, Karp RB, Kirklin JW, Barratt-Boyes BG. *Cardiac Surgery*; 2nd Ed, New York: Churchill Livingstone; 1993. p. 609-644.
3. Du ZD, Hijazi ZM, Kleinman CS, Silverman NH, Larntz K; Amplatzer Investigators. Comparison between transcatheter and surgical closure of secundum atrial septal defect in children and adults: results of a multicenter nonrandomized trial. *J Am Coll Cardiol* 2002;39:1836-1844.
4. Celiker A, Ozkutlu S, Karagöz T, Ayabakan C, Bilgiç A. Transcatheter closure of interatrial communications with Amplatzer device: results, unfulfilled attempts and special considerations in children and adolescents. *Anadolu Kardiyol Derg* 2005;5:159-164.
5. King TD, Thompson SL, Steiner C, Mills NL. Secundum atrial septal defect. Nonoperative closure during cardiac catheterization. *JAMA* 1976;235:2506-2509.
6. Kong X, Cao K, Xu D, Chen M, Yang R, Huang J. Transcatheter closure of secundum atrial septal defect with a new self-expanding nitinol double disk device (Amplatzer device): experience in Nanjing. *J Interv Cardiol* 2001;14:193-196.
7. Masura J, Gavora P, Podnar T. Long-term outcome of transcatheter secundum-type atrial septal defect closure using Amplatzer septal occluders. *J Am Coll Cardiol* 2005;45:505-507.
8. Peters B, Ewert P, Schubert S, Abdul-Khalik H, Schmitt B, Nagdyman N, Berger F. Self-fabricated fenestrated Amplatzer occluders for transcatheter closure of atrial septal defect in patients with left ventricular restriction: midterm results. *Clin Res Cardiol* 2006;95:88-92.
9. Li GS, Kong GM, Wang YL, Jin YP, Ji QS, Li JF, You BA, Zhang Y. Safety and efficacy of transcatheter closure of atrial septal defects guided by transthoracic echocardiography: a prospective study from two Chinese medical centers. *Ultrasound Med Biol* 2009;35:58-64.
10. Boutin C, Musewe NN, Smallhorn JF, Dyck JD, Kobayashi T, Benson LN. Echocardiographic follow-up of atrial septal defect after catheter closure by double-umbrella device. *Circulation* 1993;88:621-627.
11. Butera G, De Rosa G, Chessa M, Rosti L, Negura DG, Luciane P, Giamberti A, Bossone E, Carminati M. Transcatheter closure of atrial septal defect in young children: results and follow-up. *J Am Coll Cardiol* 2003;42:241-245.
12. Lee CH, Kwok OH, Fan K, Chau E, Yip A, Chow WH. Transcatheter closure of atrial septal defect using Amplatzer septal occluder in Chinese adults. *Catheter Cardiovasc Interv* 2001;53:373-377.
13. Kong X, Cao K, Yang R, Xu D, Sheng Y, Huang J, Ma W. Transcatheter closure of secundum atrial septal defect using an Amplatzer septal occluder. *Chin Med J (Engl)* 2002;115:126-128.
14. Divekar A, Gaamangwe T, Shaikh N, Raabe M, Ducas J. Cardiac perforation after device closure of atrial septal defects with the Amplatzer septal occluder. *J Am Coll Cardiol* 2005;45:1213-1218.
15. Majunke N, Bialkowski J, Wilson N, Szkutnik M, Kusa J, Baranowski A, Heinisch C, Ostermayer S, Wunderlich N, Sievert H. Closure of atrial septal defect with the Amplatzer septal occluder in adults. *Am J Cardiol* 2009;103:550-554.
16. Knepp MD, Rocchini AP, Lloyd TR, Aiyagari RM. Long-term follow up of secundum atrial septal defect closure with the amplatzer septal occluder. *Congenit Heart Dis* 2010;5:32-37.
17. Spence MS, Qureshi SA. Complications of transcatheter closure of atrial septal defects. *Heart* 2005;91:1512-1514.
18. Lopez K, Dalvi BV, Balzer D, Bass JL, Momenah T, Cao QL, Hijazi ZM. Transcatheter closure of large secundum atrial septal defects using the 40 mm Amplatzer septal occluder: results of an international registry. *Catheter Cardiovasc Interv* 2005;66:580-584.
19. Patel A, Lopez K, Banerjee A, Joseph A, Cao QL, Hijazi ZM. Transcatheter closure of atrial septal defects in adults > or = 40 years of age: immediate and follow-up results. *J Interv Cardiol* 2007;20:82-88.
20. Wilson NJ, Smith J, Prommete B, O'Donnell C, Gentles TL, Ruygrok PN. Transcatheter closure of secundum atrial septal defects with the Amplatzer septal occluder in adults and children: follow-up closure rates, degree of mitral regurgitation and evolution of arrhythmias. *Heart Lung Circ* 2008;17:318-324.
21. Vida VL, Barnoya J, O'Connell M, Leon-Wyss J, Larrazabal LA, Castañeda AR. Surgical versus percutaneous occlusion of ostium secundum atrial septal defects: results and cost-effective considerations in a low-income country. *J Am Coll Cardiol* 2006;47:326-331.
22. Spies C, Timmermanns I, Schröder R. Transcatheter closure of secundum atrial septal defects in adults with the Amplatzer septal occluder: intermediate and long-term results. *Clin Res Cardiol* 2007;96:340-346.
23. Elshershari H, Cao QL, Hijazi ZM. Transcatheter device closure of atrial septal defects in patients older than 60 years of age: immediate and follow-up results. *J Invasive Cardiol* 2008;20:173-176.