

“Culture-positive exogenous endophthalmitis related to XEN45 gel stent implantation”

Aaron W. Ng^{a,b,*}, Vivien C. Yip^{a,b}, Bryan C. Ang^{a,b}, Leonard W. Yip^{a,b}, Boon Ang Lim^{a,b}

^a Department of Ophthalmology, Tan Tock Seng Hospital, Singapore

^b NHG Eye Institute, National Healthcare Group, Singapore

ARTICLE INFO

Keywords:

Glaucoma
Endophthalmitis
Blebitis
Minimally-invasive
Infection

ABSTRACT

Purpose: The XEN45 gel stent implant (Allergan, CA, USA) is one of many micro-invasive surgical options available to glaucomatologists. Our case series describes the presentation, treatment, and possible risk factors of XEN45 gel stent related endophthalmitis.

Observations: A 71 year old Chinese man and a 88 year old Caucasian woman underwent XEN45 gel stent implantation for primary open angle glaucoma. They presented with endophthalmitis at 7 and 4 months post-surgery respectively. The first patient had stent exposure with blebitis while the second patient did not show any signs of conjunctival defect, stent exposure, bleb leak nor blebitis. Both patients were treated immediately with intravitreal, topical and systemic antibiotics, followed by early vitrectomy. The implant was removed in the first, but not in the second patient. Vitreous cultures grew *Streptococcus Viridans* in the first patient and *Haemophilus influenzae* in the other. Unfortunately, the first patient eventually sustained a total retinal detachment requiring surgery and did not recover his vision. The second patient however, recovered with a good Snellen's visual acuity of 6/9 and maintenance of good intraocular pressure and bleb formation.

Conclusions: Exogenous endophthalmitis related to XEN45 gel stent implantation is a rare but devastating complication. The risks factors identified were multiple post-operative procedures, bleb exposure, conjunctival defect, use of antifibrotics, blepharitis and prolonged post-operative antibiotics. XEN45 gel stent implant provides a different challenge to ophthalmologists compared to trabeculectomy as more post-operative procedures are required to prevent subconjunctival scarring. Great care should be taken to individualize the use of antifibrotics in each patient to balance the risk of subconjunctival fibrosis with the risk of infection. In patients with stent exposure we propose early closure of the conjunctiva to close off the portal of entry for pathogens and reduce the need for prophylactic topical antibiotics.

1. Introduction

The XEN45 gel stent Implant (Allergan, CA, USA) is one of many new surgical options available to glaucomatologists, with the emergence of micro-invasive glaucoma surgery.¹ Unlike traditional trabeculectomy surgery, it allows the ab-interno creation of a fistula into the subtenon or subconjunctival space for bleb formation. While this minimally-invasive approach results in a theoretically better safety profile and a shorter surgical time,² bleb-related complications such as bleb-related endophthalmitis (BRE), similar to that observed in traditional trabeculectomy surgery,³ may be observed after XEN45 implantation as well. To date however, post-XEN BRE has been rarely reported in the literature.

We report a case series of 2 patients with primary open angle

glaucoma (POAG) who had undergone insertion of a XEN45 gel stent in one eye and subsequently re-presented with delayed onset exogenous endophthalmitis. We aim to describe and compare their presentations, management, and possible underlying risk factors.

2. Findings

2.1. Case 1

2.1.1. Background

Our first case involves a 71 year old Chinese man with bilateral POAG. His right eye was blind with no perception of light vision. He had undergone previous trabeculectomy which was complicated by

* Corresponding author. Tan Tock Seng Hospital, Level 1, TTSH Medical Centre 11 Jalan Tan Tock Seng, 308433, Singapore.

E-mail address: aaron.ng@mohh.com.sg (A.W. Ng).

<https://doi.org/10.1016/j.ajoc.2022.101291>

Received 21 January 2021; Received in revised form 20 July 2021; Accepted 17 January 2022

Available online 29 January 2022

2451-9936/© 2022 The Authors.

Published by Elsevier Inc.

This is an open access article under the CC BY-NC-ND license

(<http://creativecommons.org/licenses/by-nc-nd/4.0/>).

hypotony and choroidal detachments. Subsequent vitrectomy had unfortunately led to visual wipeout. His left eye was pseudophakic and had a previous selective laser trabeculoplasty performed a year prior. Snellen's visual acuity was 6/15 and automated static perimetry showed a superior altitudinal and inferior arcuate defect involving fixation, with a mean deviation of -26.92dB (Fig. 1). As a result of uncontrolled intraocular pressure (IOP) despite maximal medical treatment (Topical dorzolamide 2% (Trusopt, Merck & Co), brimonidine tartrate 0.2% and timolol malaete 0.5% combination (Combigan, Allergan), travoprost 0.004% (Travatan, Alcon)), the patient was offered surgical therapy. The patient declined our initial recommendation of trabeculectomy or XEN45 stent insertion at the outset and instead chose insertion of the iStent inject (Glaukos Corp. San Clemente, CA, USA) due to its better safety profile despite its weaker IOP lowering efficacy. However, his IOP remained uncontrolled (28 mmHg) and he subsequently underwent XEN45 implantation with mitomycin C (MMC) 0.2mg/ml (0.1ml).

While the operative procedure was uneventful, his early post-

operative recovery was complicated by hypotony with choroidal detachments, grade 2 shallow anterior chamber, and hypotony maculopathy necessitating anterior chamber reformation with balanced sterile saline and air on post-operative day 6. During this time, he was also prescribed oral prednisolone 15mg daily. Gradually, his IOP increased, and the choroidal detachments improved. In the 3rd post-operative week, encapsulation of conjunctiva over the implant tip was noted and bleb needling (without antifibrotics) was performed. At the 5th post-operative month, the XEN45 implant was noted to be curled in the subconjunctival space. 2 weeks later, the stent tip had eroded through the conjunctiva. In the outpatient clinic, the XEN45 stent was successfully pushed back into the conjunctiva. At the 6th post-operative month, XEN45 stent tip noted to have eroded through the conjunctiva again (Fig. 2), and was repositioned in the clinic in a similar fashion. At the 7th post-operative month, while the conjunctival erosion was smaller, Seidel's test remained positive. All procedures were performed in the outpatient clinic under strict aseptic technique with sterile instruments

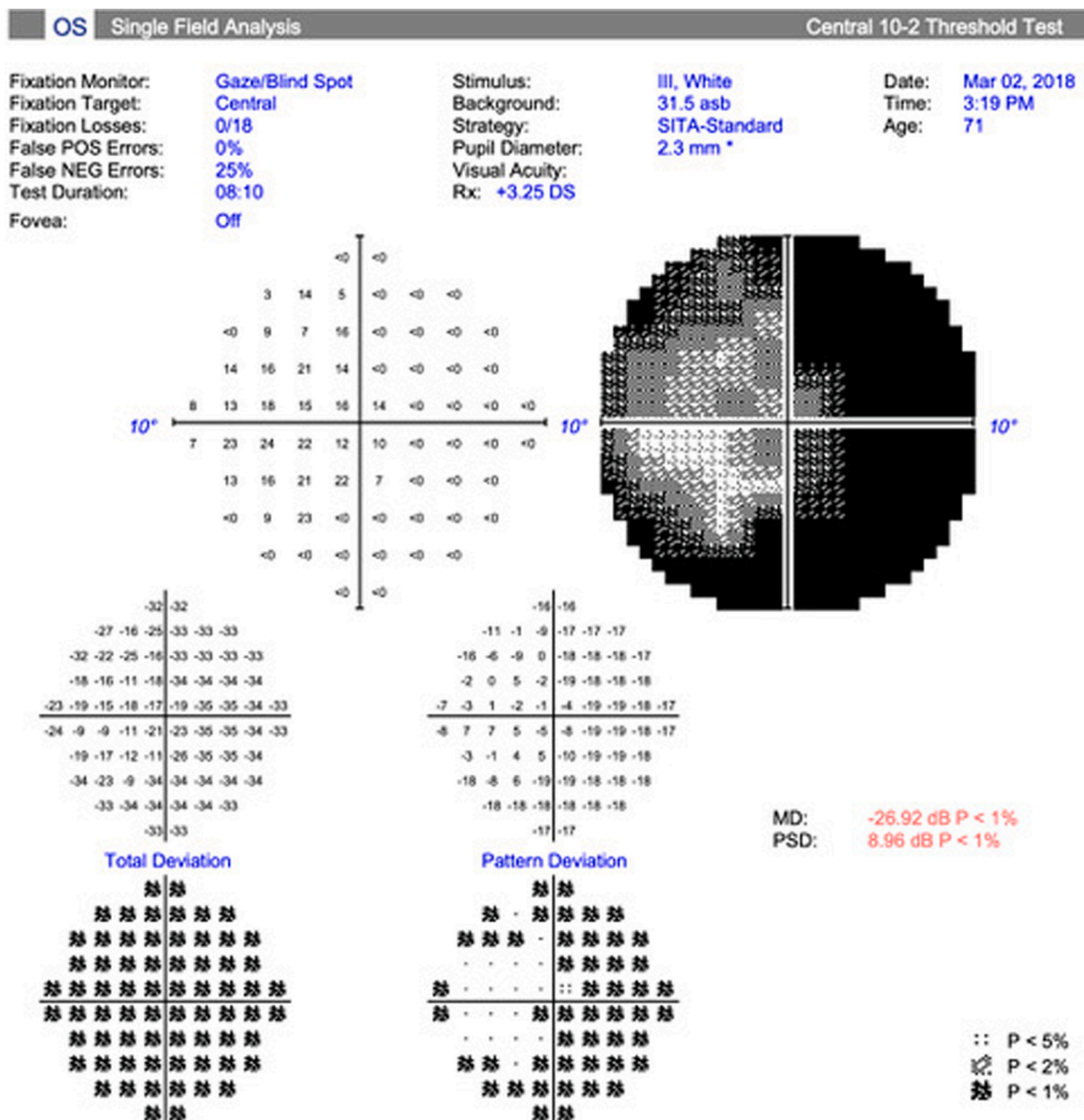


Fig. 1. Patient 1: 10-2 automated perimetry showing initial visual field loss before XEN45 implantation.

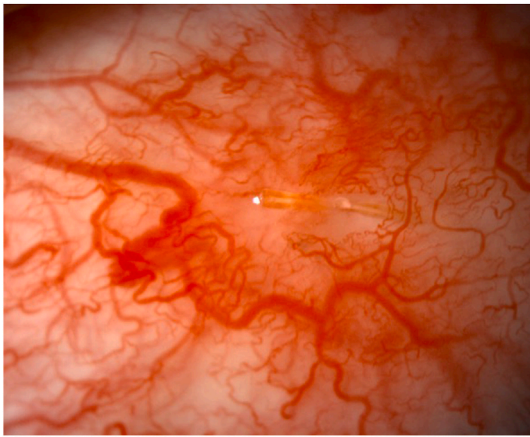


Fig. 2. Patient 1: XEN stent exposure taken before the infection. Unfortunately we were unable to document photos of stent erosion during the presentation of endophthalmitis.

and 5% povidone iodine cover. Topical levofloxacin 0.5% (Cravit, Santen) was prescribed from the time of the first stent exposure and continued throughout the patient's follow up.

2.1.2. Presentation

3 weeks later, the patient presented to our clinic for 1 day of pain and redness in the left eye. His visual acuity had worsened to light perception and the IOP was 40 mmHg. There were anterior chamber cells, fibrin, and a hypopyon (Fig. 3). There was also exposure of the XEN45 stent, measuring 1.3mm, with a visible conjunctival defect. Seidel's test, however, was negative. B- Scan ultrasound of the eye showed moderate to dense intra-gel opacities and dense subhyaloid opacities (Fig. 4). There was also a dome-shaped membrane/elevation at the inferotemporal region posterior to the equator. There were no other risk factors for bleb infection identified such as upper respiratory tract infection, blepharitis or diabetes mellitus.

2.1.3. Management and investigations

A diagnosis of exogenous endophthalmitis was made and the patient underwent a diagnostic vitreous tap and injection of intravitreal vancomycin 1mg/0.1mL and ceftazidime 2.25mg/0.1mL. He was administered oral ciprofloxacin (Ciprobay, Bayer) 500mg, topical fortified cefazolin 50mg/ml and gentamicin 14mg/ml at hourly intervals, as well as chloramphenicol 1% ointment. He was treated IOP-lowering medications, with intravenous acetazolamide (Diamox, MercuryPharma) 500mg and topical brinzolamide 1.0% (Azopt, Alcon), travoprost 0.004%, and a brimonidine 0.2% and timolol 0.5% combination. On the

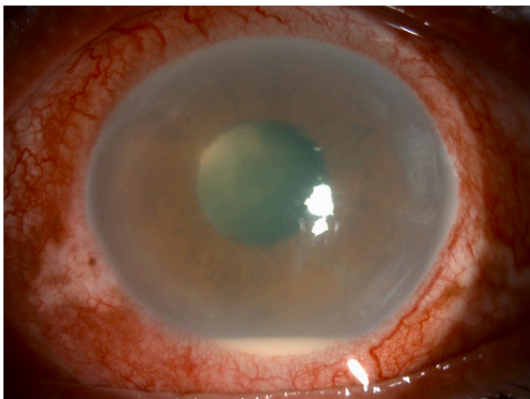


Fig. 3. Patient 1: The patient presented with typical features of endophthalmitis: Severe conjunctival injection, corneal oedema and a hypopyon.

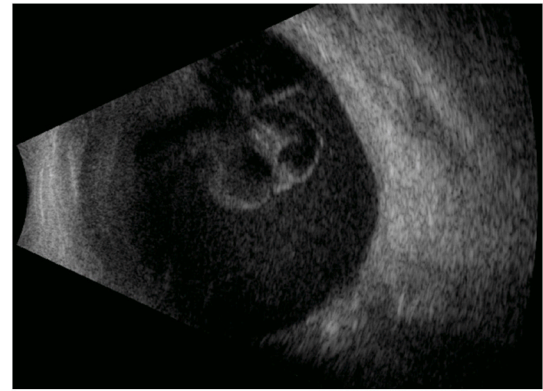


Fig. 4. Patient 1: B scan ultrasound scan showing dense vitreous opacities.

same day of presentation, the patient underwent anterior chamber washout, pars plana vitrectomy, endolaser, intravitreal antibiotics and antifungal treatment, as well as removal of the XEN45 implant. Intraoperatively, the eye was observed to have fibrin in the anterior chamber, purulent vitreous, a fibrinous membrane with thick infiltrate overlying the entire macula, peripheral infiltrates, retinal hemorrhages and sclerosed vessels in all 4 quadrants.

The patient subsequently required another intravitreal injection of vancomycin, ceftazidime, amphotericin, and dexamethasone. Vitreous cultures grew *Streptococcus viridians* which was sensitive to tetracycline, erythromycin, clindamycin and vancomycin. Topical gentamicin was switched to topical vancomycin.

2.1.4. Outcome and follow up

Despite the complete resolution of the inflammation, and clearing of retinal hemorrhages, the patient's visual acuity only improved to 6/120. Unfortunately, he then developed a total retinal detachment, for which he underwent a second vitrectomy with endolaser and heavy silicone oil fill.

2.2. Case 2

2.2.1. Background

A 88 year old Caucasian lady with multiple antibiotic allergies including penicillin and fluoroquinolones, had right eye POAG with a baseline IOP of 46 mmHg. She had a visual acuity of 6/12, and a superior arcuate visual field defect with a mean deviation of -7.97 dB on automatic static perimetry (Fig. 5). Prior to her operation she had a previous cataract surgery 12 years ago, followed by selective laser trabeculoplasty and was on topical timolol 0.5% (Timolol Maleate, Alcon), and latanoprost 0.005% (Xalatan, Pfizer). However, her IOP remained suboptimal (21 mmHg with a target of 16 mmHg) and she was keen to reduce her eye drop burden, thus she underwent XEN45 implantation with MMC 0.3mg/ml (0.1ml).

Her early post-operative recovery was complicated by hypotony with grade 2 shallowing of the anterior chamber, 360° choroidal detachments as well as a drop in visual acuity. She was started on oral prednisolone 10mg daily and topical atropine 1% (Isopto- Atropine, Alcon) thrice daily and underwent anterior chamber reformation with Viscoat (Viscoat, Alcon) on the 5th post-operative day. However, the recurrent anterior chamber shallowing and persistent kissing choroidal detachments necessitated 2 more successive anterior chamber reformations, with plain Healon (Abbott Medical Optics, Inc., Santa Ana, CA, USA) and subsequently with Healon GV (Abbott Medical Optics, Inc., Santa Ana, CA, USA). Thereafter, her anterior chamber maintained its depth and the choroidal detachments resolved. After each procedure, the patient was covered with topical antibiotics.

However, at her 1st post-operative month review, her IOP was raised (24 mmHg) and a low bleb was observed. Bleb needling with 5-

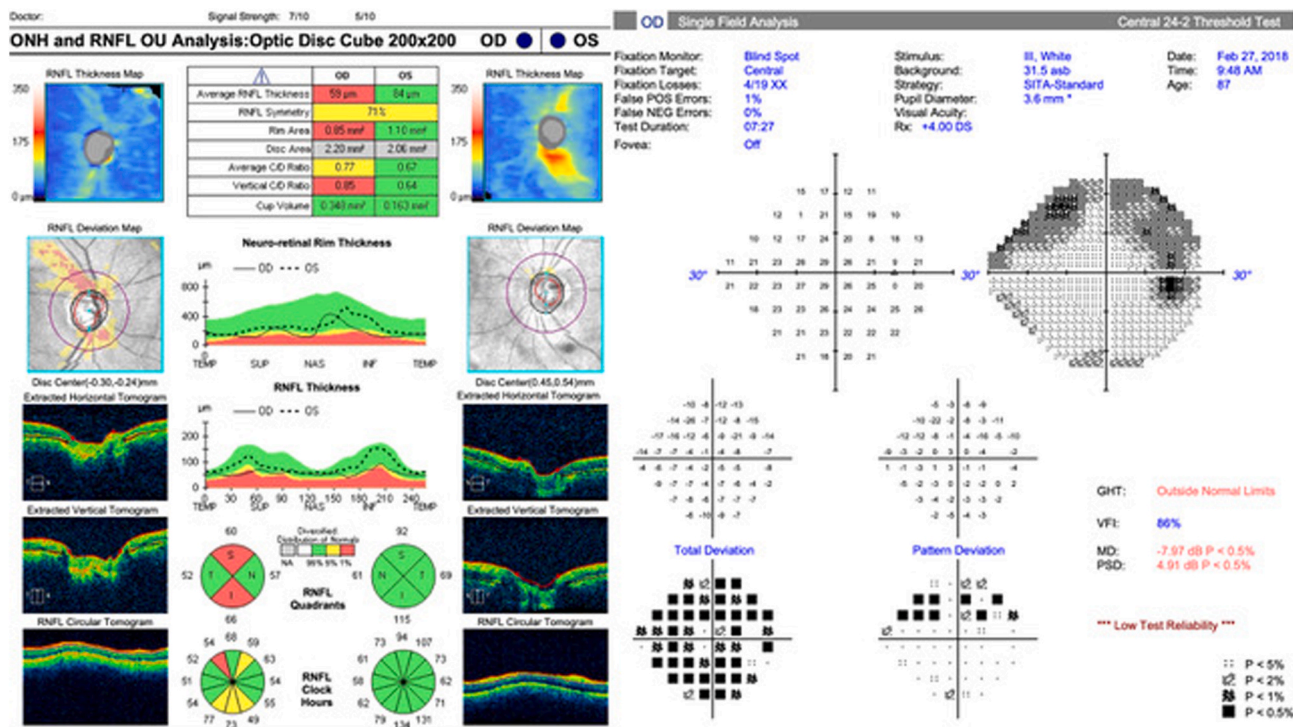


Fig. 5. Patient 2: Optical coherence tomography and 24-2 perimetry showing initial field loss before XEN45 implantation.

fluorouracil (5-FU) 50mg/mL (0.1ml) was performed and the IOP decreased. Chloramphenicol 1% ointment was prescribed post needling. A second injection of 5-FU 50mg/mL (0.1ml) was performed at the 3rd post-operative month.

2.2.2. Presentation

At the 4th post-operative month, the patient returned to clinic with complaints of 2 days of redness, and 1 day of blurring of vision. Her visual acuity was counting fingers and her IOP had increased to 40 mmHg. Her conjunctiva was injected, however, there was no sign of blebitis and the XEN45 stent was well covered (Fig. 6). The anterior chamber was deep and there were cells (Fig. 7), flare, fibrin, and a sliver of hypopyon. There was no view of the fundus. B-scan ultrasound showed moderate to dense opacities (Fig. 8). Hence, a diagnosis of exogenous endophthalmitis was made. Mild crusting of the lids suggestive of blepharitis was noted at this time, while other possible risk factors of bleb infection such as upper respiratory tract infection or history of diabetes mellitus were not present.

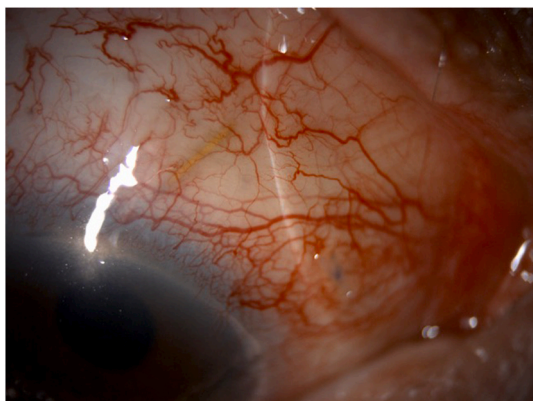


Fig. 6. Patient 2: No blebitis, leak, or stent exposure was noted during presentation of endophthalmitis.

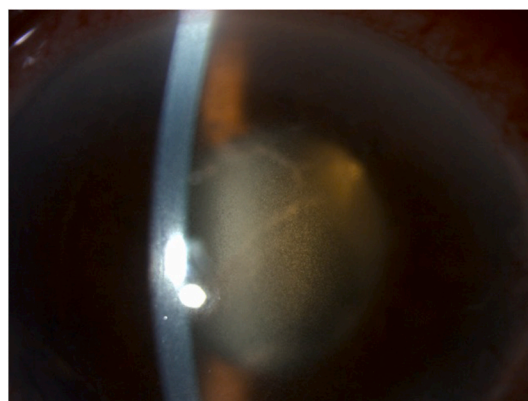


Fig. 7. Patient 2: Similar to the 1st patient, the second patient presented with typical features of endophthalmitis including severe anterior chamber cells and flare.

2.2.3. Management and investigations

The patient was immediately given topical IOP lowering drops and intravenous acetazolamide, whilst also undergoing aspiration of aqueous and vitreous fluid, and intravitreal vancomycin and amikacin injections. She was started on oral clindamycin 600mg every 6 hours, and topical fortified vancomycin 5% and gentamicin 14mg/ml at hourly intervals. She was also given topical atropine 1%, travoprost 0.004%, brimonidine tartrate 0.1% (Alphagan P, Allergan) and oral acetazolamide 250mg for IOP control. The patient was given a trial of topical prednisolone acetate 1% (Pred Forte, Allergan) – initially two doses were administered in 4 hours and then continued 4 times a day after it was noted that clinical signs remained stable. Anterior chamber and vitreous cultures grew *Haemophilus influenzae* sensitive to augmentin, ceftriaxone, levofloxacin, trimethoprim and sulfamethoxazole. On the 3rd day of presentation the patient subsequently underwent anterior chamber washout with pars plana vitrectomy, partial fluid air exchange and intravitreal injection of vancomycin, ceftazidime and

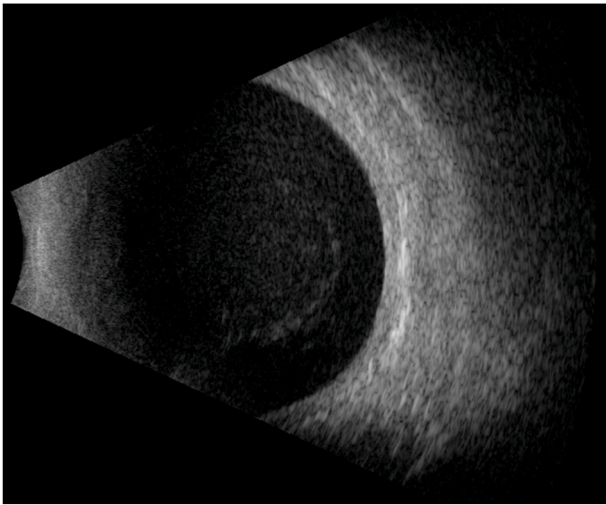


Fig. 8. Patient 2: B scan ultrasound scan showing moderate - dense vitreous opacities.

dexamethasone. The XEN45 stent was not removed as no exposure was noted intra-operatively nor was there any evidence of blebitis. Other intra-operative findings included moderately dense vitritis, inferior retinitis with perivascular infiltrates and generalized dot and blot retinal hemorrhages. On top of these, her lids were also regularly and thoroughly cleaned with eyelid wipes. Her IOPs remained below her target pressure of 16 mmHg and glaucoma medications were tapered accordingly.

2.2.4. Outcome and follow up

The inflammation gradually resolved by two and a half months after her initial presentation. Although the patient's visual field mean deviation had deteriorated to -12.11 dB (Fig. 9), the patient's Snellen's visual acuity improved significantly to 6/9 and intraocular pressures were optimally controlled with brimonidine and latanoprost.

3. Discussion

The XEN45 implant is an FDA approved device that is implanted into the eye ab-interno without the need for scleral or conjunctival incisions. It is a hydrophilic tube made up of porcine collagen-derived gelatin cross-linked with glutaraldehyde.⁴ In clinical practice it presents a potentially safer surgical alternative to traditional trabeculectomy, given its minimally invasive approach.⁵

This case series describes two cases of culture-positive exogenous endophthalmitis related to XEN45 gel stent implantation. BRE is a recognized entity traditionally involving delayed-onset endophthalmitis in an eye with a trabeculectomy. Recent studies of BRE in augmented trabeculectomy surgery have reported a 2.2% 5 year cumulative risk.⁶ Compared to standard glaucoma filtering surgery, implantation of the XEN45 gel stent is a relatively new procedure, hence there is insufficient data regarding post-XEN45 implantation related endophthalmitis.

To our knowledge, there have been thus far, only a handful of reports of XEN implant related endophthalmitis. Olgun et al. reported two cases of culture negative endophthalmitis related to XEN gel stent implantation in patients with POAG. Similar to our cases, one of the two patients did not appear to have blebitis and thus the implant was not removed – both patients however, did not recover vision after treatment.⁷ Another case series of XEN-associated bleb related infection by Kerr et al. described one case of isolated blebitis and two cases of bleb-related endophthalmitis. Of the 3 patients described, one had POAG and two had uveitic glaucoma.⁸ A retrospective study of 199 XEN45 implantations by Heidinger et al. noted one case of culture positive BRE 4 months after surgery.⁹ A second retrospective case analysis by Karimi et al. of

259 XEN implantations noted a case of endophthalmitis likely related to post-implant bleb resuturing.¹⁰

Both our patients presented with classical symptoms of endophthalmitis – rapid onset of a unilateral painful red eye, with severe blurring of vision. Visual acuity was markedly decreased in both patients (Light perception in the first patient and counting fingers in the second) and both had high IOPs at the time of presentation. Both patients had intense conjunctival injection, anterior chamber inflammation with a hypopyon, and significant vitreous opacities on B-scan ultrasonography. The main difference in presentation between both patients was that in the first patient, there was XEN45 stent erosion through the conjunctiva, whereas in the second patient there was no exposure of the XEN45 or evidence of blebitis.

After initiation of topical and systemic antibiotics, both patients underwent aspiration of vitreous for microbiological sampling, followed by immediate broad-spectrum intravitreal antibiotics, and early anterior chamber washout with pars plana vitrectomy. In the first case, the XEN45 implant was removed during the operation. In the second case, leaving the implant in-situ did not appear to have significant impact on the clinical sequelae as the infection resolved and the patient achieved remarkable improvement of her vision from counting fingers to 6/9. Kerr et al. described three cases of XEN implant bleb related infection whose implants were not removed during treatment. Upon resolution of the infection there were no episodes of recurrent infection reported. It is noteworthy that one of the cases described had endophthalmitis with blebitis but nonetheless achieved good improvement of the visual acuity to 6/18, even without pars plana vitrectomy or stent removal.⁸ It seems that in the absence of blebitis, leaving the XEN implant in-situ may not adversely affect the outcomes of the infection.

Risk factors for XEN related endophthalmitis may share similarities to late-onset BRE in trabeculectomy surgery, and some were present in our cases. These include the use of adjunctive antifibrotics, stent exposure, blepharitis, and a complicated post-surgical course requiring multiple post-surgical interventions (such as anterior chamber reformations, stent repositioning and bleb needling).

Antifibrotics used throughout the course of management in our patients included MMC during stent insertion for both cases, and 5-FU during bleb needling in the second case. MMC is an antibiotic with antimetabolic properties that is derived from the bacteria *Streptomyces caespitosus*. It is commonly used as an adjunct in glaucoma filtration surgery and prevents DNA synthesis via alkylation, thus inhibiting proliferation of fibroblasts in the Tenon's. This in turn reduces scar formation and greater IOP control.¹¹ On the other hand, 5-FU is a pyrimidine analogue that suppresses cellular proliferation by inhibiting thymidylate synthase crucial to DNA synthesis. The use of antifibrotics is commonplace in trabeculectomy, however its increased use has also coincided with a greater incidence of BRE.¹² Avascular, cystic and thin walled blebs are often a result of antifibrotic use and increases the risk of bleb leak and the introduction of bacteria via the conjunctival defect.¹³ A superiorly placed bleb, although still the most ideal position, is vulnerable as a result of its contact to the upper lid which can cause or prevent closure of an open defect in a thin conjunctiva from recurrent chaffing, while also acting as a source of bacteria. Similar to BRE, we feel that amongst the predisposing factors for endophthalmitis related to XEN45 implantation, use of antifibrotic agents are likely to be one of the most important.

In patients with significant XEN related infections, the reported concentration of MMC injected into the subconjunctival space was 0.1–0.2mg/ml.^{7,8} In our patients, we used a concentration of 0.2mg/ml in the first case and 0.3mg/ml in the second case. It is unclear if a higher MMC concentration directly resulted in an increased risk of endophthalmitis.

Despite a larger concentration of MMC used in our second patient, further needling with 5-FU was still required to achieve adequate IOP control post-operatively. XEN45 blebs, however, have been shown to require more post-operative bleb manipulation than trabeculectomy.

of endophthalmitis in this second case. The onset of endophthalmitis was late – 1 month after the bleb needling procedure, which would have been unusual if bacterial inoculation had occurred at the time of needling. Given the relatively high incidence of bleb-augmentation procedures after XEN implantation,¹⁴ with the attendant risks of post-needling infection, patients should be carefully counselled of the risks and their expectations managed prior to embarking on XEN implantation.

The use of prolonged prophylactic topical antibiotics post-surgery is controversial. Both our patients were prescribed prolonged prophylactic antibiotic eye drops after surgery to prevent infection. A study by Jampel et al. reported intermittent and prolonged use of antibiotics after surgery as a risk factor for bleb related endophthalmitis.¹⁵ Supporting this, it has also been reported that patients undergoing intravitreal injections who were given topical antibiotics had higher rates of endophthalmitis compared to those who did not.¹⁶ Furthermore, studies have also reported up to 20% increase in fluoroquinolone resistance in eyes routinely treated with antibiotics after their monthly injections.¹⁷ It is possible that prolonged post-operative antibiotic use could select for more pathogenic and resistant bacteria and should be used with care.

The organisms cultured in our cases were *S. viridans* and *H. influenzae*. Both *Streptococcal* and *Haemophilus* endophthalmitis have also been observed to present as a delayed infection in the setting of trabeculectomy bleb.^{18,19}

To date, these are the first reported cases of XEN-related exogenous endophthalmitis related to these organisms. One article reported an *Enterococcus faecalis* endophthalmitis while having had previous XEN stent insertion with MMC 0.1mg/ml (0.1ml).²⁰ Similar to our first case, there was exposure of the stent. It is noted that in this case, the patient was suffering from gastroenteritis, which may have been a significant inciting factor. Other organisms reported include *Moraxella nonliquefaciens* and *Staphylococcus aureus*.⁵

Our first case had a *S. viridans* endophthalmitis with blebitis in the setting of an exposed bleb with active bleb leak. *S. viridians* is an alpha hemolytic streptococcus with low pathogenicity, classically known to colonize the mouth. Recent studies have reported *S. viridans* colonizing normal conjunctiva in as much as 2.5–4% of individuals.^{21–23} We postulate that the conjunctival defect could have acted as a convenient portal of entry for conjunctival *S. viridans* to gain entry intraocularly and subsequently cause the endophthalmitis.

Our case of *H. influenzae* endophthalmitis had delayed-onset endophthalmitis without stent exposure, bleb leak nor blebitis. Her lids had crusting suggestive of blepharitis however, *H. influenzae* is not a usual cause of blepharitis, nor a common skin or eyelid commensal. Could the entry of bacteria have been via other means besides the bleb? A case series of *H. influenzae* endophthalmitis by Yoder et al. described a time interval between surgery and diagnosis of endophthalmitis of up to 21 years for trabeculectomy and even occurred 4 years after cataract surgery alone.¹⁹ In cases where there is no bleb leak, a probable explanation for delayed-onset BRE in patients post-trabeculectomy would be inoculation from a distant source and entry through the thin wall of the bleb. Alternatively, *H. influenzae* may have been sequestered intraocularly during the first cataract surgery 12 years before, and reactivated after the secondary XEN implantation.

Since XEN45 implantation is a relatively new procedure, there is currently a lack of consensus regarding the management of its post-operative complications, including exposed or failed XEN45 implants.^{24,25} While bleb related infections in XEN implantation and trabeculectomy patients may seem similar, the XEN45 implant may additionally induce mechanical damage to the conjunctiva. Furthermore, the incidence of XEN45 post-operative bleb manipulation with antifibrotics to prevent subconjunctival scarring is relatively high compared to trabeculectomy^{26,27} and this, in combination with thin walled avascular blebs from antifibrotic use may lead to an increased risk of exposure. The risk may be further compounded by the need for prolonged prophylactic antibiotic use. The accumulation of multiple risk

factors in this way may lead to a cumulatively increased risk of XEN45 infection. Further studies are required to assess if these issues affect the incidence of BRE related to XEN implants in the longer term.

4. Conclusions

In conclusion, we present two cases of culture proven delayed onset exogenous endophthalmitis related to XEN45 gel stent implantation. Both presented classically, and were treated immediately with topical, systemic, and intravitreal antibiotics, followed by anterior chamber washout and vitrectomy. While the first patient unfortunately had a poor visual outcome, the second patient achieved a remarkable visual recovery.

Despite XEN45 gel stent implantation being a minimally invasive procedure, bleb related infections do occur. Given its delayed presentation, its true incidence is still yet to be determined. This is an important point that the clinician needs to be aware of and to communicate to the patient.

Our second patient maintained good vision and even maintained her IOPs after treatment of her infection. We treated our patients in a fashion analogous to traditional BRE. Similar to other reported cases,⁸ we did not remove the implant during surgery as there was no blebitis. This suggests that it is possible to achieve good outcomes without the removal of the implant in the absence of blebitis.

Based on our patients and published cases, the risk factors are similar to traditional trabeculectomy. There seems to be a higher incidence of postoperative manipulation bleb manipulation with antifibrotics to deal with subconjunctival scarring in XEN 45 compared to trabeculectomy^{26,27} but no reported increase in endophthalmitis rate. Careful consideration needs to be taken when considering the type of subconjunctival filtration surgery and to individualize each patient's post-operative regimen based on their risk of scarring. More studies will be helpful in determining how best to optimize antifibrotic use to strike a balance between bleb survival, reduction of post-operative manipulation and endophthalmitis risk. Complications such as conjunctival erosion and stent exposure are challenges unique to subconjunctival minimally invasive glaucoma surgical devices of which trabeculectomy patients are spared from. Whilst some may close spontaneously, we suggest early surgical closure. The benefits are twofold - to close the portal of entry, and reduce the duration of prophylactic antibiotics given. Again, more research in this area can inform our decisions to optimize the management of such complications.

Patient consent

Consent to publish the case series was not obtained. This report does not contain any personal information that could lead to the identification of the patient. Institutional review board approval was sought but deemed to be unnecessary due to the nature of the article.

Funding

No funding or grant support

Authorship

All authors attest that they meet the current ICMJE criteria for Authorship.

Declaration of competing interest

Ang, Bryan C: Consultant and travel assistance (Allergan).
Yip, Leonard W: Consultant and travel assistance (Allergan).
The following authors have no financial disclosures:
Ng, Aaron W.
Yip, Vivien C.

Lim, Boon Ang.

Acknowledgements

None.

References

- Manasses DT, Au L. The new era of glaucoma micro-stent surgery. *Ophthalmol Ther.* 2016;5(2):135–146.
- Tan SZ, Walkden A, Au L. One-year result of XEN45 implant for glaucoma: efficacy, safety, and postoperative management. *Eye.* 2018;32(2):324–332.
- Kirwan JF, Lockwood AJ, Shah P, et al. Trabeculectomy in the 21st century: a multicenter analysis. *Ophthalmology.* 2013;120(12):2352–2539.
- Lewis RA. Ab interno approach to the subconjunctival space using a collagen glaucoma stent. *J Cataract Refract Surg.* 2014;40:1301–1306.
- Sheybani A, Lenzhofer M, Hohensinn M, et al. Phacoemulsification combined with a new ab interno gel stent to treat open-angle glaucoma: pilot study. *J Cataract Refract Surg.* 2015;41:1905–1909.
- Yamamoto T, Sawada A, Mayama C, et al. The 5-year incidence of bleb-related infection and its risk factors after filtering surgeries with adjunctive mitomycin C: collaborative bleb-related infection incidence and treatment study 2. *Ophthalmology.* 2014;121(5):1001–1006.
- Olgun A, Imamoğlu S, Karapapak M, et al. Endophthalmitis after Xen Gel stent implantation: 2 cases. *J Glaucoma.* 2018;27(12):e191–e194.
- Kerr NM, Wang J, Sandhu A, et al. Ab interno gel implant-associated bleb-related infection. *Am J Ophthalmol.* 2018;189:96–101.
- Heidinger A, Schwab C, Lindner E, et al. A retrospective study of 199 Xen45 stent implantations from 2014 to 2016. *J Glaucoma.* 2019;28(1):75–79.
- Karimi A, Lindfield D, Turnbull A, et al. A multi-centre interventional case series of 259 ab-interno Xen gel implants for glaucoma, with and without combined cataract surgery. *Eye.* 2019;33(3):469–477.
- Wilkins M, Indar A, Wormald R. Intra-operative mitomycin C for glaucoma surgery. *Cochrane Database Syst Rev.* 2005;19(4), CD002897.
- Yassin SA. Bleb-related infection revisited: a literature review. *Acta Ophthalmol.* 2016;94:122–134.
- Lehmann OJ, Bunce C, Matheson MM, et al. Risk factors for development of post-trabeculectomy endophthalmitis. *Br J Ophthalmol.* 2000;84(12):1349–1353.
- Smith M, Charles R, Abdel-Hay A, et al. 1-year outcomes of the Xen45 glaucoma implant. *Eye.* 2019;33(5):761–766.
- Jampel HD, Quigley HA, Kerrigan-Baumrind LA, et al. Glaucoma Surgical Outcomes Study Group. Risk factors for late-onset infection following glaucoma filtration surgery. *Arch Ophthalmol.* 2001;119(7):1001–1008.
- Cheung CS, Wong AW, Lui A, et al. Incidence of endophthalmitis and use of antibiotic prophylaxis after intravitreal injections. *Ophthalmology.* 2012;119(8):1609–1614.
- Yin VT, Weisbrod DJ, Eng KT, et al. Antibiotic resistance of ocular surface flora with repeated use of a topical antibiotic after intravitreal injection. *JAMA Ophthalmol.* 2013;131:456–461.
- Kuriyan AE, Weiss KD, Flynn Jr HW, et al. Endophthalmitis caused by streptococcal species: clinical settings, microbiology management, and outcomes. *Am J Ophthalmol.* 2014;157(4):774–780. e1.
- Yoder DM, Scott IU, Flynn Jr HW, Miller D. Endophthalmitis caused by Haemophilus influenzae. *Ophthalmology.* 2004;111(11):2023–2026.
- Karri B, Gupta C, Mathews D. Endophthalmitis following XEN stent exposure. *J Glaucoma.* 2018;27(10):931–933.
- Keshav BR, Basu S. Normal conjunctival flora and their antibiotic sensitivity in Omanis undergoing cataract surgery. *Oman J Ophthalmol.* 2012;5(1):16–18.
- Rubab S, Awan H, Khan WA. Comparison of indigenous microbial flora of the eye to that found in conjunctival and corneal infections in A hospital based study. *Pak J Ophthalmol.* 2006;22(2):97–107.
- Sharma PD, Sharma N, Gupta RK, Singh P. Aerobic bacterial flora of the normal conjunctiva at high altitude area of Shimla Hills in India: a hospital based study. *Int J Ophthalmol.* 2013;6(5):723–726.
- Kam KYR, Muhundhakumar D, Barton K, et al. Re: lim et al. XEN implant-related endophthalmitis. *Ophthalmology* 2018;125:209. *Ophthalmology.* 2018;125(10):e75.
- Lim R, Lim KS. XEN implant-related endophthalmitis. *Ophthalmology.* 2018;125(2):209.
- Schlenker MB, Gulamhusein H, Conrad-Hengerer I, et al. Efficacy, safety, and risk factors for failure of standalone ab interno gelatin microstent implantation versus standalone trabeculectomy. *Ophthalmology.* 2017;124(11):1579–1588.
- Teus MA, Paz Moreno-Arrones J, Castaño B, et al. Optical coherence tomography analysis of filtering blebs after long-term, functioning trabeculectomy and XEN® stent implant. *Graefes Arch Clin Exp Ophthalmol.* 2019;257(5):1005–1011.