



## Nail changes in female pemphigus vulgaris patients on immunosuppressive therapy<sup>☆</sup>

M.M. El-Komy, MD<sup>a</sup>, D.M. Abdel Halim, MD<sup>a</sup>, N. Samir, MD<sup>a</sup>, R.A. Hegazy, MD<sup>a</sup>,  
H.I. Gawdat, MD<sup>a,\*</sup>, S.A. Shoeb, MD<sup>b</sup>

<sup>a</sup> Dermatology Department, Faculty of Medicine, Cairo University

<sup>b</sup> Microbiology and Immunology Department, Faculty of Medicine, Cairo University

### ARTICLE INFO

#### Article history:

Received 10 December 2014

Received in revised form 28 January 2015

Accepted 28 January 2015

#### Keywords:

Bacterial growth

Fungal growth

Immunosuppressive therapy

Nail changes

Pemphigus vulgaris

### ABSTRACT

**Background:** Pemphigus vulgaris (PV) patients receiving immunosuppressive therapy may develop nail alterations resulting from infection, skin disorder, or drug regimen.

**Objective:** This study aims to describe nail changes in PV female patients receiving immunosuppressive therapy and to report the frequency of associated fungal and bacterial growth in the patients' nails.

**Methods:** Twenty-five female PV patients who had at least one acquired finger or toenail abnormality and had been administered at least one immunosuppressive drug were included in the study. Nail alterations were recorded. Nail scrapings were collected from abnormal nails for fungal and bacterial examination.

**Results:** Positive fungal and bacterial cultures were detected in 20 (80%) of patients' nail samples. Five patients reported nail alterations coinciding with disease onset, whereas 13 reported nail changes after administration of immunosuppressive therapy.

**Limitations:** Lack of a control group (patients on similar immunosuppressive medications for conditions other than PV) which would have further supported the findings demonstrated in this observational study.

**Conclusion:** Nail abnormalities in severe PV patients are frequently associated with fungal and bacterial growth. Immunosuppressive therapy potentially initiates such changes.

© 2015 The Authors. Published by Elsevier Inc. on behalf of Women's Dermatologic Society. This is an open access article under the CC BY-NC-ND license (<http://creativecommons.org/licenses/by-nc-nd/4.0/>).

### Introduction

Patients suffering from several dermatologic diseases may develop nail abnormalities that are either related to their dermatoses, an associated systemic disease, a concurrent infection in the nail apparatus, or drugs administered for their condition (de Berker and Baran, 2010; Singh et al., 2005).

Pemphigus vulgaris (PV) patients occasionally present with associated, yet slightly variable, nail manifestations (Serratos and Rashid, 2009). The nail unit involvement can be a part of the initial presentation of the disease or occur during a flare along with other lesions. It has been suggested that an increased frequency of onychomycosis in PV patients may result from immunosuppressive therapy (Schlesinger et al., 2002).

Immunosuppressive therapy for PV includes systemic steroids (conventional or pulse therapy), azathioprine, cyclophosphamide, mycophenolate mofetil, and cyclosporine (Tsuruta et al., 2012). Although many of these drugs have demonstrated potent efficacy in the treatment of nail manifestations in PV (Serratos and Rashid, 2009), several reports indicate that these drugs may induce a variety of nail alterations (Rault, 2000; Tosti et al., 2001).

The current study describes nail changes in female PV patients receiving immunosuppressive therapy and reports the frequency of associated fungal and bacterial growth in the patients' nails.

### Methods

The study was approved by the Dermatology Research Ethical Committee (REC), Faculty of Medicine, Cairo University and is in accordance with the Helsinki Declaration of 1975. It included 25 female PV patients from the dermatology inpatient ward of Kasr AL-Ainy Hospital, Faculty of Medicine, Cairo University. All recruited patients required admission to the inpatient ward, either because of the severity of the disease or for therapeutic intervention; had at least one acquired finger or toenail abnormality; and had been administered at least one immunosuppressive drug. Pemphigus vulgaris was diagnosed based on classic clinical and histopathological features. All patients were examined thoroughly, with special emphasis on nail abnormalities. All participants were asked to sign an informed consent before admission into the study.

Patients with a known history of nail disease for which they received treatment were not included. In addition, patients with associated nondermatologic conditions that are known to cause nail alterations, such as diabetes, renal failure, advanced liver disease, and peripheral vascular disease, were also excluded from the study. Patients who developed steroid-induced diabetes were not excluded.

<sup>☆</sup> Conflicts of interest: The authors state no conflicts of interest.

\* Corresponding author.

E-mail address: [heba.gawdat@yahoo.com](mailto:heba.gawdat@yahoo.com) (H.I. Gawdat).

Complete personal, medical, and drug histories were obtained for each patient, with a special emphasis on the history of the associated nail changes. General physical and dermatological examinations were performed and all nail abnormalities were recorded for each patient. Nail scrapings were collected from the deeper layers of the abnormal nails of all recruits with a No. 11 scalpel blade and sent to the lab for fungal and bacterial examination and culture.

#### Laboratory diagnosis

##### Microscopic examination

Thin nail pieces were placed on a slide under a cover slip in KOH, heated gently, and examined under low- and high-power on a microscope with a reduced light source. Young hyphae appear in the specimen as long, undulant, branching threads, and older hyphae break down into arthrospores.

##### Direct culture

Each sample was cultured in mycological media for dermatophytes and bacteriological media for bacteria as follows.

**Mycological media culture.** Screw capped bottles of Sabouraud's dextrose agar containing 0.05 mg/ml of chloramphenicol and 0.1 mg/ml of cyclohexamide were prepared, and the pH was adjusted to 6.5 to 7.0.

Nail scrapings were imbedded in the media and incubated at 22 to 30°C for 2 to 3 weeks. The cultures were examined soon after sporulation, as dermatophytes macroconidia are more easily observed in the first few days of sporulation compared with old cultures.

Fungal growth was identified according to:

1. Fungal growth pattern.
2. Surface color and growth reversal.
3. Microscopic examination of the macroconidia and conidiophore.

##### Bacteriological culture

Blood agar plates were prepared, inoculated with nail scrapings, and incubated at 37°C for 24 hours.

Bacterial growth was identified by routine methods (e.g., morphology, culture characteristics, biochemical reactions, and serological identification).

##### Statistical methods

The data are statistically described as the mean  $\pm$  standard deviation ( $\pm$  SD), range, frequency (number of cases), and percentage, where appropriate. Comparisons of the numerical variables between the study groups were performed with the Chi square ( $\chi^2$ ) test. Alternatively, the exact test was used when the expected frequency was less than five. *P* values less than 0.05 were considered statistically significant. All statistical calculations were performed with SPSS version 15.0 (SPSS Inc., Chicago, Illinois).

## Results

The study included 25 female PV patients, aged between 20 and 65 years (mean = 45.5, SD  $\pm$  13.7). The disease duration ranged between 1.92 and 120 months (mean = 34.8, SD  $\pm$  30) and the treatment duration ranged between 1 and 120 months (mean = 24.4, SD  $\pm$  28.2). The duration of nail affliction ranged between 0.96 and 60 months (mean = 18, SD  $\pm$  15.6).

All patients exclusively received high-dose systemic steroids in the form of intravenous (IV) pulse steroid therapy (500 mg IV methyl prednisolone for 3 consecutive days plus 500 mg IV cyclophosphamide for one day) every 2 to 4 weeks.

The number of nails affected with any type of abnormality differed among patients. The frequency of nail alteration ranged between 2

and 20 nails per patient (mean = 9, SD  $\pm$  6). Toenail abnormalities were observed in 21 (84%) patients. Specifically, 15 patients displayed bilateral toenail alterations. Fingernail abnormalities were observed in 20 (80%) patients, with 18 of these patients displaying bilateral fingernail alterations. Of the 25 PV patients, 16 (64%) patients displayed both fingernail and toenail alterations, 5 (20%) patients exclusively displayed toenail alterations, and 4 (16%) patients exclusively presented with fingernail changes.

The most common nail alterations were onycholysis, subungual hyperkeratosis, onychorrhexis, and discoloration. Brittleness and total dystrophy were observed to a lesser extent. No significant difference between the total number of nails affected in the fingers or toes was observed (*P* = 0.182). The frequency of nail abnormalities detected in patients is presented in Table 1.

Positive culture results were observed in 20 patients. Six (24%) patients displayed fungal culture growth, 6 (24%) patients demonstrated positive bacterial culture growth, and 8 (32%) patients demonstrated both positive fungal and bacterial growth. No bacterial or fungal growth was detected in 5 (20%) patients. *Staphylococcus aureus* and *Microsporum canis* were the most commonly isolated pathogens. The frequency of bacterial and fungal growth is shown in Table 2.

The onset of nail abnormalities was determined by patient observation in 18 cases. Five patients with nail samples that demonstrated no growth on culture reported that their nail changes coincided with or started shortly after the onset of PV, while 8 patients with nail samples that demonstrated both fungal and bacterial growth on culture reported that their nail abnormalities developed at least 1 year following the initiation of immunosuppressive therapy. The remaining five reported that their nail abnormalities occurred sometime following the start of systemic immunosuppressive therapy. Seven patients could not report the onset of their nail affection.

Pemphigus vulgaris disease and treatment durations did not significantly influence the results of fungal or bacterial cultures (*P* = 0.086 and 0.063, respectively). In addition, the total number of digits affected and the duration of nail disease displayed no significant difference between patients with positive cultures and those with negative cultures (*P* = 0.968 and 0.462, respectively). On the other hand, both PV disease and treatment duration significantly positively correlated to nail disease duration (*P* = 0.001, *r* = 0.795 and *P* = 0.001, *r* = 0.748, respectively) (Fig. 1).

## Discussion

Several dermatologic diseases are associated with nail apparatus abnormalities. The nail alterations described in PV patients include onychomadesis, onycholysis, cross-ridging, pitting, Beau's lines, subungual hemorrhage, paronychia, nail dystrophy, and nail plate discoloration (de Berker et al., 1993; Engineer et al., 2000; Kim et al., 1996).

In the current work, subungual hyperkeratosis, onycholysis, and onychorrhexis were the most common nail alterations observed in Egyptian PV female patients. Schlesinger et al. (2002) reported 30 PV patients presenting with nail alterations, such as paronychia, discoloration, onychomadesis, subungual hemorrhage, onycholysis, subungual hyperkeratosis, deformation and onychorrhexis. In the current study, we also noted brittleness in 8 (32%) patients and total nail dystrophy in 3 (12%) patients, which may correspond with previous authors' classifications of deformation. We did not observe paronychia or subungual hemorrhage in any of our PV patients undergoing treatment.

**Table 1**  
Frequency of Nail Changes in Pemphigus Vulgaris Patients.

Clinical Nail Finding	No. of Patients (Percentage of Total)
Subungual hyperkeratosis	16 (64%)
Onycholysis	16 (64%)
Onychorrhexis	13 (52%)
Brittleness	8 (32%)
Yellow discoloration	11 (44%)
Total dystrophy	3 (12%)

**Table 2**  
Type and Frequency of Bacterial and Fungal Growth Observed in Patients' Nails.

Fungus	Positive Culture	Bacteria	Positive Culture
<i>Microsporium canis</i>	5 (20%)	<i>Staphylococcus aureus</i>	5 (20%)
<i>Microsporium audouinii</i>	4 (16%)	<i>Streptococcus pyogenes</i>	3 (12%)
<i>Trichophyton rubrum</i>	2 (8%)	<i>Escherichia coli</i>	2 (8%)
<i>Trichophyton concentricum</i>	3 (12%)	<i>Klebsiella pneumoniae</i>	2 (8%)
Total positive growth	14 (56%)	<i>Streptococcus haemolyticus</i>	1 (4%)
		<i>Staphylococcus epidermidis</i>	1 (4%)
		Total positive growth	14 (56%)

Fourteen (56%) PV patients' fungal cultures displayed dermatophytic growth, the most frequent being *M. canis*. Similarly, 53% of the PV patients reported by Schlesinger et al. (2002) displayed a positive fungal culture but exclusively grew *Trichophyton rubrum* in culture. The difference in the frequency of dermatophytes involved in the current study could be attributed to the fact that dermatophytes species vary geographically (Aboueisha and El-Mahallawy, 2013).

Schlesinger et al. (2002) attributed the high frequency of onychomycosis to therapeutic immunosuppression in those patients.

Bacterial cultures from abnormal nails were positive in 14 (56%) out of 25 PV patients. Cahali et al. (2002) reported *S. aureus* positive cultures in 2 out of 5 PV patients and paronychia was the primary nail alteration. Although *S. aureus* was the most common bacteria in our PV patients, bacterial cultures also demonstrated the presence of other organisms. Similar to onychomycosis (Schlesinger et al., 2002), the increased bacterial growth on culture may also be related to immunosuppression.

Furthermore, in 13 (72%) out of 18 cases with reliable histories, the nail alterations occurred after receiving one or more immunosuppressive drugs. The cultures of all 13 patients were positive for bacteria, fungi, or both. Interestingly, an interval of at least 1 year between the initiation of immunosuppressive therapy and the onset of nail alterations was observed in 8 cases, despite PV stabilization or improvement. This observation may

point to the notion that immunosuppressive drugs administered to PV patients can indirectly cause increased nail fungal and bacterial contamination as a consequence of generalized immunosuppression.

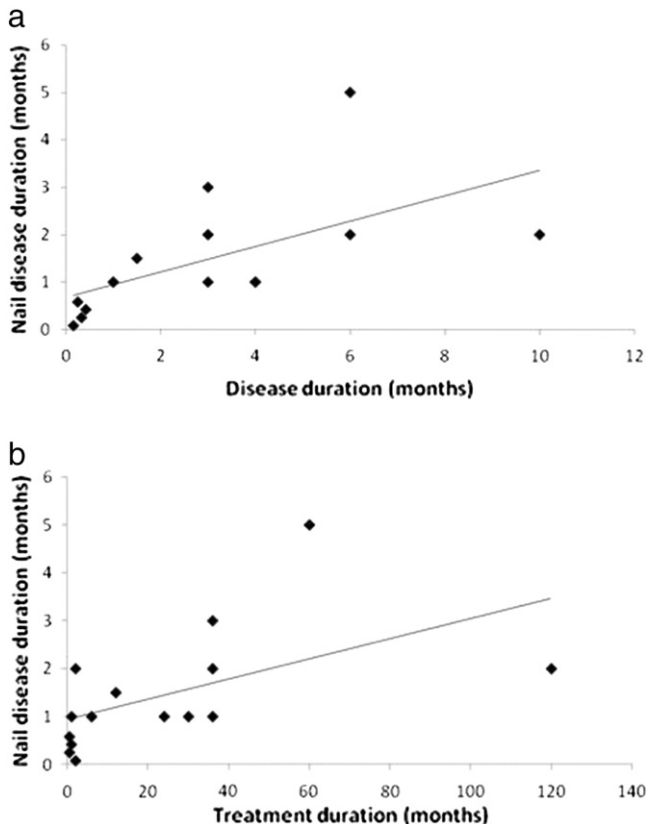
On the other hand, nail abnormalities appeared to coincide with or occur shortly after the onset of PV in 20% of our patients. Interestingly, these patients did not display any fungal or bacterial growth on culture, suggesting that early nail alterations in PV patients potentially result from their disease rather than immunosuppression or drug therapy. This finding is in agreement with the report by Schlesinger et al. (2002) that demonstrated that 14 (46%) of 30 patients with nail changes attributed to PV displayed negative fungal cultures. In contrast to the results of the previous authors, who reported that nail changes in PV exclusively affect fingernails, nail changes due to PV affected both fingernails and toenails almost equally.

Our results suggest that nail abnormalities in PV may be related to dermatologic disease in 20% of cases and immunosuppressive therapy in at least 52% of cases. However, whether bacterial and/or fungal infection of the nail is precipitated by drug therapy or the dermatological disease itself remains unclear and requires further study. Moreover, the degree of participation of these microbes in nail morphology distortion in PV patients remains to be elucidated.

In contrast to previous PV reports that imply that fingernails are more often involved than toenails (Engineer et al., 2000), toenail abnormalities were slightly more common than fingernail abnormalities in PV patients in this study. Moreover, Cahali et al. (2002) reported that no patient exclusively displayed toenail alterations in their series of five PV patients, whereas we observed 5 patients with toenail alterations exclusively and 4 patients with only fingernail affliction.

The significantly positive correlation between the duration of nail alterations and PV duration as well as treatment duration may provide further insight into the etiopathogenesis of nail dystrophy associated with PV. The former correlation suggests a potential clue for the intertwined relation between PV and clinical nail involvement. However, this finding contradicts what was reported by Schlesinger et al. (2002), who suggested that nail changes in PV patients do not correlate with the disease's duration.

The results of this study suggest that nail abnormalities in severe PV patients requiring hospitalization and immunosuppressive treatment are commonly associated with fungal and bacterial growth. The most common abnormalities are onycholysis and subungual hyperkeratosis. The duration of disease appears to dictate the longevity of nail changes in our patients, and immunosuppressive therapy may initiate these nail changes either alone or as a result of opportunistic bacterial and/or fungal growth affecting the nail unit. Accordingly, prompt treatment of PV utilizing a multidisciplinary approach (combined or sequential therapy) would presumably decrease the incidence of nail affection in PV patients on immunosuppressive therapy.



**Fig. 1.** Correlation between nail disease duration and pemphigus vulgaris disease (a) and treatment (b) durations.

## References

- Aboueisha AM, El-Mahallawy H. Public health significance of dermatophytes in Ismailia and Port Said Provinces, Egypt. *Med Mycol J* 2013;54:123–9.
- Cahali JB, Kakuda EY, Santi CG, Maruta CW. Nail manifestations in pemphigus vulgaris. *Rev Hosp Clin Fac Med Sao Paulo* 2002;57:229–34.
- de Berker DAR, Baran R. Disorders of nails. In: Burns T, Breathnach S, Cox N, Griffiths C, editors. *Rook's textbook of dermatology*. 8th ed. Oxford: Blackwell Science; 2010. p. 1–23.
- de Berker DD, Dalziel K, Dawber RP, Wojnarowska F. Pemphigus associated with nail dystrophy. *Br J Dermatol* 1993;129(4):461–4.
- Engineer L, Norton LA, Ahmed AR. Nail involvement in pemphigus vulgaris. *J Am Acad Dermatol* 2000;43:529–35.
- Kim BS, Song KY, Youn JI, Chung JH. Paronychia—a manifestation of pemphigus vulgaris. *Clin Exp Dermatol* 1996;21:315–7.
- Rault R. Mycophenolate-associated onycholysis. *Ann Intern Med* 2000;133:921–2.
- Schlesinger N, Katz M, Ingber A. Nail involvement in pemphigus vulgaris. *Br J Dermatol* 2002;146:836–9.
- Serratos BD, Rashid RM. Nail disease in pemphigus vulgaris. *Dermatol Online J* 2009;15(7):2.
- Singh G, Haneeff NS, Uday A. Nail changes and disorders among the elderly. *Indian J Dermatol Venereol Leprol* 2005;71:386–92.
- Tosti A, Baran R, Dawber RP. The nail in systemic diseases and drug-induced changes. In: Baran R, Dawber RP, editors. *Diseases of the nails and their management*. 8th ed. Oxford: Blackwell Science; 2001. p. 320–7.
- Tsuruta D, Ishii N, Hashimoto T. Diagnosis and treatment of pemphigus. *Immunotherapy* 2012;4:735–45.