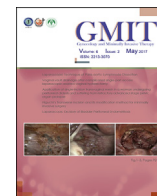



Contents lists available at ScienceDirect

Gynecology and Minimally Invasive Therapy

journal homepage: www.e-gmit.com

Short communication

Application of single-incision transvaginal mesh in a woman undergoing peritoneal dialysis and suffering from refractory advanced stage pelvic organ prolapse

Yi-Hung Sun ^a, Wei-Chih Kan ^b, Ming-Ping Wu ^{a, c, d, e, *}^a Division of Oncology Gynecology, Department of Obstetrics and Gynecology, Chi Mei Medical Center, Tainan, Taiwan^b Division of Nephrology, Department of Medicine, Chi Mei Medical Center, Tainan, Taiwan^c Division of Urogynecology and Pelvic Floor Reconstruction, Department of Obstetrics and Gynecology, Chi Mei Medical Center, Tainan, Taiwan^d Department of Obstetrics and Gynecology, College of Medicine, Taipei Medical University, Taipei, Taiwan^e Center of General Education, Chia Nan University of Pharmacy and Science, Tainan, Taiwan

ARTICLE INFO

Article history:

Received 24 February 2016

Received in revised form

23 September 2016

Accepted 9 November 2016

Available online 27 December 2016

Keywords:

pelvic organ prolapse

peritoneal dialysis

peritoneocele

transvaginal mesh

ABSTRACT

Objective: We would like to provide an option of minimal invasive surgical intervention for a patient with end-stage renal disease undergoing continuous ambulatory peritoneal dialysis, who was at the advanced-stage pelvic organ prolapse (POP) and who also failed to be treated conservatively.

Materials and method: We present a case of uterine prolapse stage IV in a woman who underwent continuous ambulatory peritoneal dialysis due to end-stage renal disease. Her severity of POP had only limited improvement after being switched to hemodialysis and vaginal cream use. After her informed consent, we performed a uterus-sparing transvaginal mesh procedure to adjust the anterior, apical, and posterior defects of pelvis.

Results: There has been no recurrence of any compartment of POP during the 16-month follow-up period, nor any mesh-related complications. The perineal swelling subsided after switching to nocturnal automated peritoneal dialysis only in the supine position.

Conclusion: Patients with POP at an advanced stage during peritoneal dialysis who failed to be treated conservatively may require a surgical intervention. Uterus-sparing transvaginal mesh was a feasible minimal invasive option.

Copyright © 2016, The Asia-Pacific Association for Gynecologic Endoscopy and Minimally Invasive Therapy. Published by Elsevier Taiwan LLC. This is an open access article under the CC BY-NC-ND license (<http://creativecommons.org/licenses/by-nc-nd/4.0/>).

Introduction

Established risk factors for pelvic organ prolapse (POP) include childbirth, parity, advanced age, and obesity.¹ Situations that cause repetitive increases in intra-abdominal pressure, such as chronic constipation, heavy lifting, etc., are also considered to increase the risk of POP.² In end-stage renal disease (ESRD) patients treated with continuous ambulatory peritoneal dialysis (CAPD), massive abdominal fluid during the upright position can result in additional

pressure that is exerted on the pelvic floor, thereby increasing the risks of symptomatic POP in these patients.^{3,4}

Women with symptomatic prolapse who have failed or declined conservative management may search for a surgical intervention. Different surgical procedures have been developed to treat POP, including anterior and posterior colporrhaphy, paravaginal repair, and sacrospinous suspension. The newly introduced technique of vaginal inlay mesh repair using a synthetic polypropylene mesh kit has shown promising outcomes in terms of correcting POP. Reported vaginal mesh-related complications has raised concerns regarding the safety of mesh repair, such as dyspareunia, mesh extrusion, and lower urinary tract symptoms.⁵ Therefore, whether to use mesh in surgery for women with POP remains debatable. The choice of primary surgical procedure, including either uterus-sparing or concomitant hysterectomy, with or without the use of mesh, in symptomatic POP surgeries depends upon a variety of conditions.

Conflicts of interest: The authors have no conflicts of interest relevant to this article.

* Corresponding author. Department of Obstetrics & Gynecology, Chi Mei Foundation Hospital, No. 901, Zhonghua Rd., Yongkang Dist., Tainan City 710, Taiwan 71004.

E-mail address: mpwu@mail.chimei.org.tw (M.-P. Wu).

<http://dx.doi.org/10.1016/j.gmit.2016.11.002>

2213-3070/Copyright © 2016, The Asia-Pacific Association for Gynecologic Endoscopy and Minimally Invasive Therapy. Published by Elsevier Taiwan LLC. This is an open access article under the CC BY-NC-ND license (<http://creativecommons.org/licenses/by-nc-nd/4.0/>).

Materials and methods

The case we present here is a 52-year-old woman, gravida 4, para 3 (all vaginal deliveries), and artificial abortus 1. She had been in menopause since the age of 48 years. Her body mass index was 18.66 kg/m² (body weight 46 kg and body height 157 cm). She had Type 2 diabetes mellitus for more than 10 years with chronic diabetic nephropathy. She also had chronic hypertension, congestive heart failure, and a history of intracranial hemorrhage. She developed ESRD at the age of 50 years, and received hemodialysis (HD) from then on, and then shifted to CAPD 1 year later. Thereafter, she suffered from vaginal protruding mass gradually, associated with easy rubbing sensation, recurrent vulvitis, and vaginitis, but not difficulty in defecation. She visited our urogynecology division, where pelvic examination revealed uterine prolapse stage IV. Perineal swelling, multiple vaginal erosion, and fungal infection were noted as well. She did not have stress urinary incontinence, frequency, urgency, or urgency incontinence.

After the initial outpatient visit, her CAPD was replaced temporarily by HD for 1 month and vaginal estrogen cream was also given, which showed no improvement of POP. She also declined the use of a vaginal pessary. After we discussed with the patient about her complicated medical condition, uterine-sparing single-incision transvaginal mesh (TVM) was suggested.

Prior to the formal surgery, two scheduled surgeries were postponed due to suspected peritonitis and electrolyte imbalance-induced convulsion. After her medical conditions stabilized, we treated the prolapse by single-incision mesh repair using the Anterior and Posterior Elevate system (American Medical Systems, Minnetonka, MN, USA). The mesh utilized was lighter and softer Type I polypropylene mesh (Intepro Lite; American Medical Systems). The lower two arms of the trocar-guided Elevate mesh kit were anchored to sacrospinous ligaments bilaterally via a single-incision vaginal wound.

Results

The POP quantification score before the operation is shown in Figure 1A, while the data of POP quantification score collected 5 months after the operation are shown in Figure 1B. Postoperatively, there was no vaginal wall or vault protruding after she resumed CAPD 1 month later. However, perineum swelling still persisted as a preoperative condition. As a result, CAPD was replaced by automated peritoneal dialysis (APD), which was used in the supine position and at nighttime only. After that, the perineum swelling subsided. The postoperative course went smoothly up to 16 months, before she died of her complicated medical causes including progressive cognitive decline, metabolic encephalopathy underlying cardiovascular problem, and electrolyte imbalance.

Discussion

The prevalence of chronic kidney disease and ESRD requiring dialysis therapy continues to increase worldwide. Life spans of patients who receive peritoneal dialysis (PD) or HD are similar, but with different economic burdens and compliance. From our case and the literature, women who desire PD need to be reminded about the potential POP issue because of the increased abdominal pressure. With regard to PD options, APD may be offered to the patient.³ APD was performed in the supine position, with minimal to no PD fluid remaining in the abdomen during the daytime when the patient was in the erect position, and so intra-abdominal pressure was decreased compared with CAPD.

The related literature about POP and PD is very limited. Conservative management is more demanding, and the necessity of

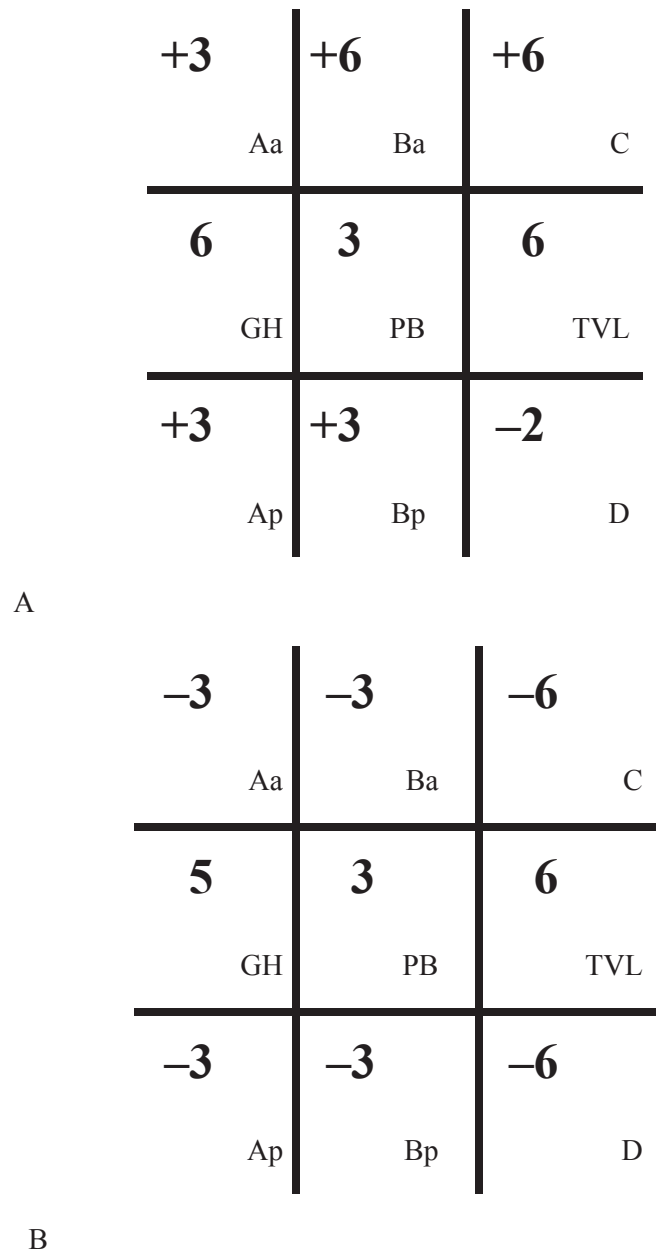


Figure 1. POP-Q (A) before operation and (B) 5 months after operation. POP-Q = pelvic organ prolapse quantification score. Points and landmarks for POP-Q system examination: Aa = point A anterior; Ap = point A posterior; Ba = point B anterior; Bp = point B posterior; C = cervix or vaginal cuff; D = posterior fornix (if cervix is present); gh = genital hiatus; pb = perineal body; tvl = total vaginal length.

surgical intervention remains a controversial issue.^{3,4} POP surgery in ESRD patients is often associated with many potential perioperative morbidity events⁶; thus, the complicated medical condition makes anesthesia management more challenging. Based on this, a conservative treatment, such as a vaginal pessary, could be considered for such patients. For this patient with poor compliance to vaginal pessary due to intolerant foreign body sensation, and bothersome daily removal and cleaning, a surgical intervention was subsequently considered by us.

There still exists complicated precipitating mechanisms inducing POP in CAPD patients. The defective rectovaginal fascia leaves the deep rectovaginal fluid dissection plane unprotected, which further predisposes these patients to a vulnerable condition.

Even concomitant posterior colporrhaphy does not obliterate the cul-de-sac space. By contrast, an intraperitoneal approach involving laparoscopy or abdominal sacrocolpopexy for repair may introduce the risk of PD fluid infection and open the retroperitoneal space, which could lead to significant retroperitoneal fluid dissection and inhibit postoperative reperitonealization. Therefore, a vaginal extraperitoneal approach is preferred when surgery is needed.³

The use of a mesh or native tissue for women with POP remains a subject of debate due to the reported higher rate of surgical complications, when compared with the traditional group. However, both intra- and postoperative complications in mesh repair could be reduced with more surgical experience.

The 2013 Cochran review for surgical management of POP in women reported that sacral colpopexy has superior outcomes to a variety of vaginal procedures including sacrospinous colpopexy, uterosacral colpopexy, and TVM.⁷ Even so, these benefits must be weighed against the increased operating time, blood loss, rate of apical or posterior compartment prolapse, *de novo* stress urinary incontinence, and reoperation rate for mesh exposures associated with the use of polypropylene mesh.⁷ Nevertheless, sacral colpopexy may not be indicated in women receiving PD, due to its intraperitoneal approaches.

TVM implantation with a decreased risk of disruption of natural uterine support structures and a relatively low recurrence rate provides a better anatomical support while avoiding intraperitoneal approaches. This was further shown to be an applicable minimal invasive option. Several single-arm studies have reported favorable outcomes with the use of TVM by the Elevate repair system after 1 year of follow-up, with an objective success rate of 88–92% in the anterior compartment, 89–96% in the apical compartment, and 93% in the posterior compartment.^{8–10}

In this case, there has been successful anatomical reduction after the surgery, without any mesh-related complications being noted. However, the patient still suffered from perineal swelling after the resumption of CAPD postoperatively. After being switched to APD, her perineal swelling subsided. It might indicate that TVM implantation by vaginal extraperitoneal approach with graft support

still did not obliterate the whole pelvic cavity, leaving some fluid dissection plane unprotected. However, such a problem could be resolved by decreasing abdominal pressure after changing dialysis modality.

In conclusion, gynecological examination is mandatory before the implementation of PD. For women with POP or at risk of it, CAPD should be avoided and alternated by APD or HD. Conservative management is important to limit the progression of prolapse. When surgical intervention becomes imperative for refractory prolapse, vaginal extraperitoneal approach without hysterectomy for repair is recommended in patients undergoing PD. Uterus-sparing TVM with a shorter operative duration, less blood loss, and a relatively low recurrence rate, without the need of entering into the pelvic cavity, was a feasible minimal invasive option.

References

1. Jelovsek JE, Maher C, Barber MD. Pelvic organ prolapse. *Lancet*. 2007;369:1027–1038.
2. Swift S, Woodman P, O'Boyle A. Pelvic Organ Support Study (POSST): the distribution, clinical definition, and epidemiologic condition of pelvic organ support defects. *Am J Obstet Gynecol*. 2005;192:795–806.
3. Lew SQ, Robinson JK. A conservative approach to peritoneal dialysis-associated rectocele. *Perit Dial Int*. 2014;34:655–657.
4. Liberek T, Lichodziejewska-Niemierko M, Kowalewska J, Swiatkowska-Freund M, Rutkowski B. Uterine prolapse—a rare or rarely reported complication of CAPD? *Perit Dial Int*. 2002;22:95–96.
5. Altman D, Väyrynen T, Engh ME, Axelsen S, Falconer C. Anterior colporrhaphy versus transvaginal mesh for pelvic-organ prolapse. *N Engl J Med*. 2011;364:1826–1836.
6. Rang ST, West NL, Howard J, Cousins J. Anaesthesia for chronic renal disease and renal transplantation. *EAU-EBU Update Ser*. 2006;4:246–256.
7. Maher C, Feiner B, Baessler K, Schmid C. Surgical management of pelvic organ prolapse in women. *Cochrane Database Syst Rev*. 2013;30:34.
8. Jiang G, Yan B, Wang Y, Ma Q. Transvaginal mesh repair for pelvic organ prolapse. *J Obstet Gynaecol Res*. 2014;40:1046–1050.
9. Su TH, Lau HH, Huang WC, Hsieh CH, Chang RC, Su CH. Single-incision mesh repair versus traditional native tissue repair for pelvic organ prolapse: results of a cohort study. *Int Urogynecol J*. 2014;25:901–908.
10. Moore RD, Mitchell GK, Miklos JR. Single-incision vaginal approach to treat cystocele and vault prolapse with an anterior wall mesh anchored apically to the sacrospinous ligaments. *Int Urogynecol J*. 2012;23:85–91.