

Persistent cutaneous abdominal ulcerations secondary to diffuse dermal angiomas: an underestimated sign for severe atherosclerosis

A case report

Lidia García-Colmenero, MD^{a,*}, Gemma Martín-Ezquerro, MD^a, Ignacio Gómez-Martín, MD^a, Meritxell Mellado Joan, MD^b, Carlos Barranco, MD^c, Raquel Albero-González, MD^c, Judith Villar-García, MD^d, Ramon M. Pujol, MD^a,

Abstract

Background: Diffuse dermal angiomas (DDA) is a rare, acquired, reactive vascular proliferation, clinically characterized by livedoid erythematous–violaceous plaques, which frequently evolve to ulceration and necrosis. Histopathologically, it is manifested by a diffuse proliferation of endothelial cells within the full thickness of the dermis. DDA has been mainly associated with severe peripheral atherosclerosis.

Methods: We report a 63-year-old woman who presented with multiple erythematous–violaceous plaques with central deep skin ulcers on thighs, lower abdomen, and perianal area, associated with intermittent claudication, low-grade fever, and weight loss. Initially, the clinical picture along with positive cultures for *Klebsiella pneumoniae* suggested a multifocal ecthyma gangrenosum; nevertheless, a skin biopsy showed a diffuse dermal proliferation of endothelial cells interstitially arranged between collagen bundles. A computed tomography scan revealed severe aortic atheromatosis with complete luminal occlusion of the infrarenal aorta and common iliac arteries.

Results: The diagnosis of DDA secondary to severe atherosclerosis was established. The patient underwent a left axillofemoral bypass surgery with a rapidly healing of the ulcers in the next weeks.

Conclusions: DDA should be considered in the differential diagnosis of livedoid ischemic lesions. Recognition of DDA as a cutaneous sign of severe peripheral vascular disease is important for both dermatologists and internists. Recognition of risk factors and their management with an early intervention to correct tissue ischemia can be curative.

Abbreviations: CRA = cutaneous reactive angiomas, CT = computed tomography, DDA = diffuse dermal angiomas, DSA = digital subtraction angiography, VEGF = vascular endothelial growth factor.

Keywords: atherosclerosis, diffuse dermal angiomas, revascularization, vascular proliferation, vaso-occlusive disease

1. Introduction

Diffuse dermal angiomas (DDA) is an unusual variant of cutaneous reactive angiomas (CRA), a group of benign

vascular disorders characterized clinically by multiple, skin ulcers, developing on livedoid erythematous–violaceous plaques, often arising in nonacral areas. Histologically DDA is usually characterized by a diffuse dermal proliferation of endothelial cells and pericytes. The pathogenic mechanisms are not fully understood but it is thought to correspond to a reactive process secondary to an underlying vascular occlusion. We report a case of DDA related to peripheral vascular atherosclerotic disease with successful evolution after revascularization.

Editor: Ahmet Aykan.

Informed Consent: The patient provided her informed consent for the publication of this case report.

The authors have no conflict of interest to disclose.

^a Department of Dermatology, ^b Department of Vascular Surgery, ^c Department of Pathology, ^d Department of Infectious Diseases, Hospital del Mar, Parc de Salut Mar, Universitat Autònoma de Barcelona, Barcelona, Spain.

* Correspondence: Lidia García-Colmenero, Department of Dermatology, Hospital del Mar, Parc de Salut Mar, Passeig Marítim 25–29, Barcelona, Spain (e-mail: lidia.garcia.colmenero@gmail.com).

Copyright © 2016 the Author(s). Published by Wolters Kluwer Health, Inc. All rights reserved.

This is an open access article distributed under the Creative Commons Attribution-NoDerivatives License 4.0, which allows for redistribution, commercial and non-commercial, as long as it is passed along unchanged and in whole, with credit to the author.

Medicine (2016) 95:29(e4212)

Received: 8 February 2016 / Received in final form: 10 May 2016 / Accepted: 20 June 2016

<http://dx.doi.org/10.1097/MD.0000000000004212>

2. Case report

In April 2015, a 63-year-old woman presented to our department for evaluation of persistent multiple painful deep skin ulcers on the inner aspects of both thighs, lower abdomen, and perianal area that had appeared 1 month before consultation. The development of these lesions was associated with intense pain, low-grade fever, and discrete weight loss (6 kg). Over the past 2 months the patient also referred progressive intermittent claudication of both legs. Her medical history was significant for heavy smoking, arterial hypertension, and dyslipidemia treated with enalapril and simvastatin.

Physical examination disclosed multiple irregularly shaped retiform erythematous–violaceous and purpuric plaques with

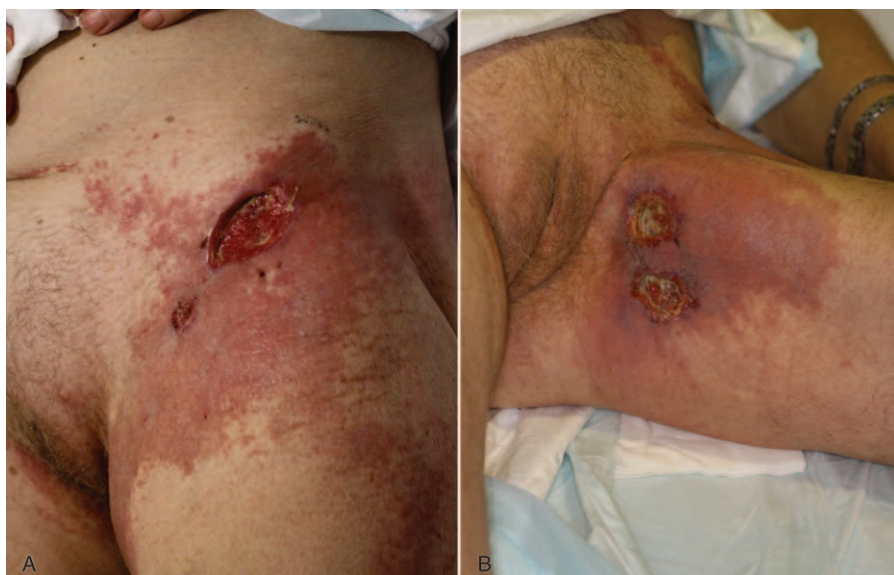

Figure 1. (A and B) Retiform erythematous-violaceous plaques with central deep skin ulcers.

central deep skin ulcers of undermined edges, ranging from 2 to 5 cm in diameter (Fig. 1). No peripheral pulses were noted in both lower extremities. No enlarged lymph nodes or signs of chronic venous insufficiency were detected. Laboratory test showed an increased leukocyte count ($13.5 \times 10^9/L$) with neutrophilia (60%) and raised C-reactive protein levels (11 mg/L). The rest of hematological, biochemical, and immunological surveys disclosed no abnormalities. A complete thrombophilic evaluation including lupus anticoagulant, anticardiolipin antibodies, Leiden factor V, proteins S and C, antithrombin III, antiphospholipid antibodies, cryoglobulin, fibrin degradation products, and D-dimer failed to detect any abnormality.

A bacteriological culture from a 4-mm biopsy specimen obtained from the cutaneous ulcers isolated *Klebsiella pneumoniae*, suggesting multifocal ecthyma gangrenosum as a possible diagnosis. Antibiotic therapy with clindamycin and ciprofloxacin was prescribed without significant improvement. After this treatment, bacteriological cultures yielded negative results. A biopsy specimen obtained from the abdominal erythematous plaque revealed a diffuse dermal proliferation of endothelial cells interstitially arranged between the collagen bundles involving the full dermal thickness. The proliferating cells stained positively

with vascular markers CD31 and CD34 and negatively for HHV-8 and D2.40 (Fig. 2). A CT scan revealed severe aortic atheromatosis with complete luminal occlusion of the infrarenal aorta and common iliac arteries (Fig. 3A). Digital subtraction angiography (DSA) confirmed a complete aortic occlusion immediately below the renal arteries and also a complete occlusion of both iliac arteries with bilateral patent common, deep femoral and proximal superficial femoral arteries. The diagnosis of DDA secondary to severe atherosclerosis was established.

Patient's ulcers continued to rapidly grow despite strict control of cardiovascular risk factors, daily treatment with 100 mg of acetyl salicylic acid and intensive local care. Despite the surgical risk, the patient underwent a left axillofemoral bypass surgery with a rapidly healing of the ulcers within 3 weeks after surgical intervention. The erythematous plaques took longer to be solved (Fig. 3B).

3. Discussion

CRA are a group of benign vascular disorders characterized histologically by different patterns of intravascular or extravas-

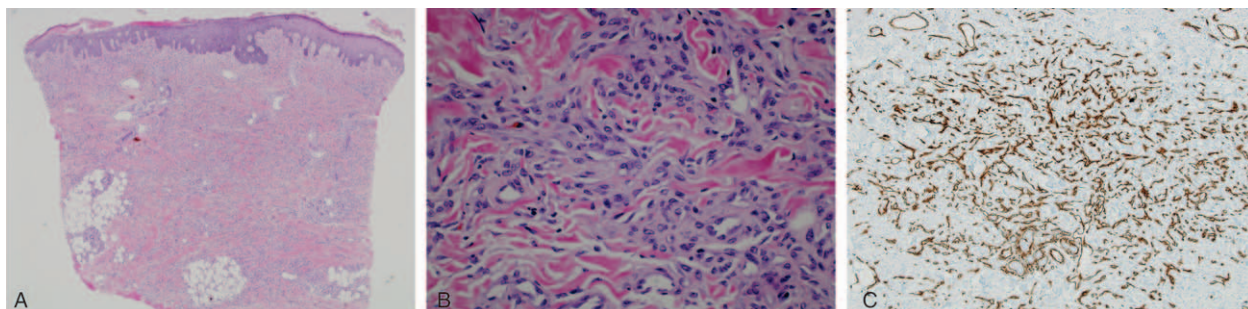


Figure 2. (A) Diffuse proliferation of endothelial cells involving the full dermal thickness, HE 40 \times . (B) Endothelial cells interstitially arranged between the collagen bundles, HE 100 \times . (C) The specimen was positive for CD34, stain at 200 \times . CD34=cluster of differentiation 34, HE=hematoxylin and eosin.

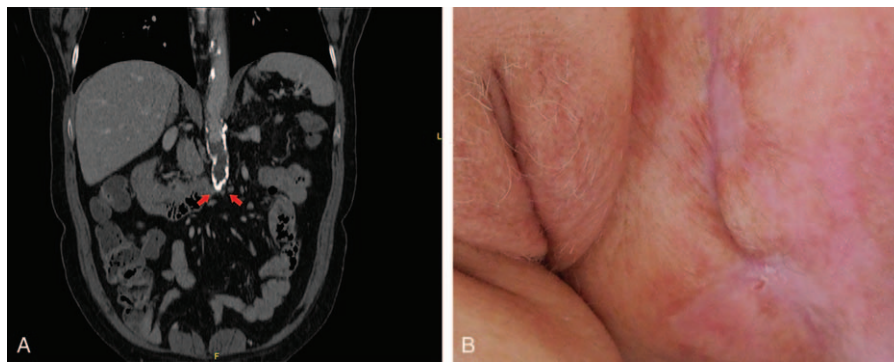


Figure 3. (A) CT scan showing total aortic occlusion below the renal arteries. (B) Healing of the ulcers after axillofemoral bypass surgery. CT=computed tomography.

cular proliferation of endothelial cells and pericytes.^[1] Clinically, they are usually manifested by erythematous–violaceous, lividoid, poorly demarcated plaques, which may evolve toward necrosis and ulceration. Constitutional symptoms such as fever, malaise, and weight loss may be present. The pathogenesis of CRA has not been fully elucidated, but it is considered to represent a vascular endothelial growth factor (VEGF)-mediated reactive endothelial cell hyperplasia because of an underlying vascular occlusion. A wide range of local and systemic disorders such as systemic infections (mainly bacterial endocarditis), valvular cardiac disease, severe atherosclerosis, vascular insufficiency, cholesterol emboli, arteriovenous shunt, cryoglobulinemia, monoclonal gammopathy, cold agglutinins, lymphoproliferative diseases, rheumatoid arthritis, hepatopathies, and adrenal diseases have been incriminated as potential causative factors.^[2–4] The reactive vascular proliferation usually resolves after withdrawing the triggering hypoxic stimulus.

DDA is an unusual variant of CRA initially described in 1994 by Krell et al.^[5] It is characterized by a cutaneous diffuse proliferation of endothelial cells within the full thickness of the dermis, interstitially arranged between the collagen bundles with minimal intravascular involvement, usually associated with severe peripheral vascular atherosclerosis disease.^[6,7] Clinically DDA is manifested by multiple, persistent skin ulcers, developing on retiform erythematous–violaceous plaques, often arising in nonacral areas (trunk, abdomen, proximal aspects of the extremities). The lesions may be asymptomatic or painful and they tend to be persistent or enlarge progressively.

The diagnosis of DDA should be suspected in patients with cardiovascular risk factors (smoking history seems to be a strong risk factor) who present persistent ulcerations in nonacral areas. The characteristic histopathological features along the vascular surgical evaluation and imaging complementary explorations may permit to establish the definitive diagnosis. The differential diagnosis should be established with the wide range of disorders manifested by retiform purpura secondary to microvascular occlusion, or by persistent deep necrotic ulcers such as bacterial

and fungal infections, pyoderma gangrenosum, systemic vasculitis, or even lymphoproliferative disorders or calciphylaxis.

Treatment should be based on the management of the underlying disease. In cases of peripheral vascular atherosclerotic disease, control of cardiovascular risk factors and revascularization are considered the treatment of choice.^[8] Systemic steroids and isotretinoin have been used in some cases with variable efficacy. Anticoagulation may be beneficial in cases associated with hypercoagulability.

An increased awareness of physicians regarding DDA as a potential causative disease of persistent multiple ulcerations seems to be important in order to avoid a diagnostic delay. The suspicion of an underlying atherosclerotic disease should lead to a rapid evaluation of potential therapeutic options including revascularization, which may lead to complete resolution of the skin lesions.

References

- [1] Franco Rongioletti, Alfredo Rebora. Cutaneous reactive angiomatoses: patterns and classification of reactive vascular proliferation. *J Am Acad Dermatol* 2003;49:887–96.
- [2] Ruiters M, Mandema E. New cutaneous syndrome in subacute bacterial endocarditis. *Arch Int Med* 1964;113:283.
- [3] Quinn TR, Alora MB, Momtaz KT, et al. Reactive angioendotheliomatosis with underlying hepatopathy and hypertensive portal gastropathy. *Int J Dermatol* 1998;37:382–5.
- [4] Creamer D, Black MM, Calonje E. Reactive angioendotheliomatosis in association with antiphospholipid syndrome. *Br J Dermatol* 2000;42:903–6.
- [5] Krell JM, Sanchez RL, Solomon AR. Diffuse dermal angiomatosis: a variant of reactive cutaneous angioendotheliomatosis. *J Cutan Pathol* 1994;2:363–70.
- [6] Kimyai-Asadi A, Nousari HC, Ketabchi N, et al. Diffuse dermal angiomatosis: a variant of reactive angioendotheliomatosis associated with atherosclerosis. *J Am Acad Dermatol* 1999;40:257–9.
- [7] Kirkland CR, Hawayek LH, Mtasim DF. Atherosclerosis-induced diffuse dermal angiomatosis with fatal outcome. *Arch Dermatol* 2010;146:684–5.
- [8] Morimoto K, Lioka H, Asada H, et al. Diffuse dermal angiomatosis. *Eur J Vasc Endovasc Surg* 2011;42:381–3.