



Extensive Idiopathic External Root Resorption in First Maxillary Molar: A Case Report

Behnam Bolhari¹, Naghmeh Meraji^{1*}, Ali Nosrat²

¹Department of Endodontics, Dental School, Tehran University of Medical Sciences, Tehran, Iran; ²Iranian Center for Endodontic Research, Research Institute of Dental Sciences, Shahid Beheshti University of Medical Sciences, Tehran, Iran

ARTICLE INFO

Article Type:
Case Report

Received: 25 Mar 2012

Revised: 21 May 2012

Accepted: 05 Nov 2012

*Corresponding author: Naghmeh Meraji, Department of Endodontics, School of Dentistry, Tehran University of Medical Sciences, Tehran, Iran.

Tel: +98-2188497390-8

Fax: +98-2188497400

E-mail: naghmeh_m82@yahoo.com

ABSTRACT

External root resorption of permanent teeth is a multifactorial process. Several etiologic and predisposing factors have been related to external root resorption. Idiopathic external root resorption is defined as cases of external root resorption without a distinct etiologic factor. This article presents an extensive idiopathic external root resorption of maxillary first molar with irreversible pulpitis in an 18-year-old patient. The resorption was diagnosed in conventional radiographs and confirmed with Cone Beam Computed Tomography (CBCT) images. Unlike other reports in this field, and despite the severe resorption of all roots, there was no abnormal tooth mobility. Cold and electric pulp tests confirmed tooth vitality and revealed irreversible pulpitis. Therefore the exact etiology of the resorption remained unclear. Considering the poor prognosis due to severe root resorption, extraction and implant replacement was indicated.

Keywords: Cone Beam Computed Tomography; Molar; Root Resorption; Tooth

1. Introduction

There are two types of external root resorption: physiologic and pathologic [1]. Physiologic root resorption is associated with primary teeth and is a desirable procedure, because it results in exfoliation of the teeth, thereby allowing eruption of the permanent successors [1]. Pathological root resorption is related to several local and systemic factors. Orthodontic therapy, trauma, periapical or periodontal inflammation, tumors, cysts, occlusal stress, impacted and supernumerary teeth, transplantation and re-implantation are among the local causes that could lead to pathological root resorption [2, 3]. Endocrine imbalances, Paget's disease of the bone, renal and hepatic disease have been reported as systemic causes of pathological root resorption [3].

Belanger and Coke [4] defined the term "idiopathic root resorption" as cases of root resorption where an etiologic factor cannot be found. Idiopathic external root resorption can be either localized to the apical region or the cervical part of the root [5]. The apical type causes a gradual shortening and rounding of tooth root [2]. Patients with idiopathic root resorption are commonly asymptomatic clinically with an occasional complaint of tooth mobility. Therefore, the condition is usually found in routine radiographic examinations after a considerable amount of root structure is lost [6].

This article describes a case of extensive idiopathic external root resorption without bone resorption and mobility in first maxillary molar with irreversible pulpitis.

2. Case Report

An 18-year-old healthy male with a chief complaint of spontaneous pain and pain to cold and heat in the left posterior maxilla was referred to the Endodontic Department, Dental School, Tehran University of Medical Sciences. Medical history of the patient was non-contributory and there was no history of dental trauma.

In clinical examinations, left maxillary first molar had extensive coronal caries and a pulp polyp. The tooth was not sensitive to percussion and palpation. In periodontal examinations the probing depths were normal (<3 mm), with normal mobility. While the adjacent teeth responded normally, the first molar showed a prolonged response to cold test (Roeko Endo-Frost, Coltene Whaledent, Germany) and a very sharp response to electric pulp test (Parkell Inc., Farmingdale, NY, USA) in lower degrees.

In radiographic examinations, extensive external root resorption was seen in all roots (Figures 1A, B). Considering the lingering pain and patient's complaint, an emergency pulpotomy was performed on the first molar for immediate pain control. Since the whole of the palatal root could not be seen in periapical radiographs taken with

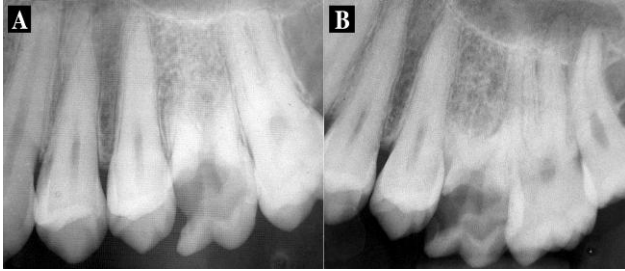

Figure 1. A) Periapical image of left maxillary first molar showing extensive coronal caries and severe root resorption in all three roots; B) A distal angulation showing extensive coronal caries and severe root resorption in all three roots

different angulations, cone beam computed tomography (CBCT) images were obtained. They confirmed the presence of the extensive external root resorption in all roots with no periradicular osseous lesion (Figures 2A, B). Hematological investigations, including complete blood count, serum calcium, phosphorus, parathormone and alkaline phosphates levels were taken to exclude any systemic disorders. All were found to be within normal limits.

A pulpal diagnosis of irreversible pulpitis with pulp polyp was made for the tooth. Since the palatal root, which is required for dowel crown restoration, showed extensive resorption the prognosis for tooth retention was poor. Therefore, extraction and implant replacement was indicated.

3. Discussion

Root resorption in the permanent dentition has a pathologic basis, and is classified into two types of internal and external resorption. Internal resorption is relatively rare and occurs as a result of trauma or caries-related inflammation of the pulp. External root resorption has various causes, including: infection and inflammation, traumatic injuries, pressure/mechanical stimulations, neoplastic conditions, systemic disorders, and idiopathic [3].

Conventional radiographic images are frequently used to detect root resorptions. However, the probability of false-negative results is a limitation of this method. Estrela *et al.* showed that CBCT scans were better for detecting root resorption than periapical radiographs; CBCT provided more accurate diagnosis with high-resolution images and lower observer interferences [7].

Treatment of inflammatory root resorption due to pulpal infection consists of long term calcium hydroxide therapy [8, 9]. Other treatment plans such as application of low power lasers [10] or even single visit root canal therapy with gutta-percha [11] have also been suggested. The conventional treatment plan in invasive cervical root resorption is to expose the resorption lacuna orthodontically or surgically, remove the granulation tissue, and restore the resorptive defect [8]. The main goal in these treatment plans is to remove the etiologic factor and stop the resorption process. However, in idiopathic resorptions the cause is unknown and therefore, the treatment is still a challenge.

External inflammatory root resorption involves the root

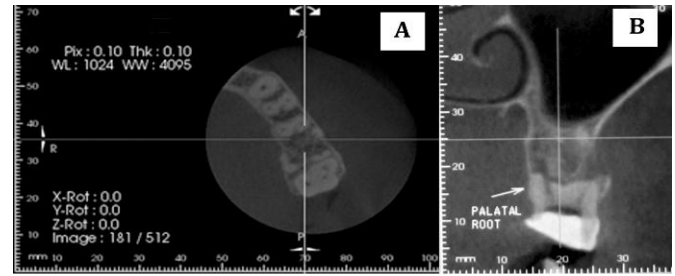


Figure 2. A) CBCT image of left maxillary first molar showing axial section in the mid-root. It shows extensive roots resorption; B) CBCT image of the tooth showing coronal view. Note the absence of roots due to extensive root resorption and normal bone structure

and adjacent alveolar bone of a necrotic tooth [12]. In the presented case, no alveolar bone resorption was seen and the tooth was not necrotic. Therefore we could not classify it as an external inflammatory root resorption.

Idiopathic root resorption was first defined by Belanger and Coke [4]. This term is applied to cases of root resorption with unknown etiology. This type of resorption is infrequent and may appear in localized or multiple forms [13]. The localized form occurs in one to three posterior teeth, whereas the multiple form may begin in the molars and bicuspids and eventually involve most of the dentition in a symmetrical pattern [2, 13].

Majority of the reported cases of “idiopathic root resorption” involve the apical part of several teeth and affects young people. The average reported age was 23.2 years [14]. The teeth were vital, asymptomatic, responded positively to pulp tests, had normal probing depths, had intact crowns, and over time, became mobile without other clinical symptoms [13-18]. Most of the teeth had attachment loss and insufficient alveolar bone support [19]. Saravia *et al.* reported a case of multiple idiopathic root resorption in monozygotic twins in which the involved teeth had normal mobility [18]. The radiographs revealed an almost identical resorptive pattern in both patients. This resorption involved all maxillary premolars and first molars and all mandibular premolars and molars.

Idiopathic apical root resorption does not seem to be mediated through pulp space. It is suspected that triggering factors exist for osteoblastic and odontoblastic activity causes root resorption. Therefore, treatment methods to arrest this type of apical resorption by interceptive endodontic procedures including pulp removal and placement of calcium hydroxide or any other intracanal medicament; obturation is not indicated [17].

In the presented case, there was only one involved tooth which had had symptomatic irreversible pulpitis, with prolonged response to the pulpal tests. There was no alveolar bone resorption, and the mobility of the tooth was normal. The extensive caries may be the cause of the atypical response of resorption, therefore this idiopathic root resorption is different from other reported cases.

Activation of interleukin (IL)-1 β inflammation pathway plays a main role in resorption of tooth root and bone; Al-Qawasmi *et al.* examined genetic factors predisposing to

external apical root resorption [20]. IL-1 β is a pro-inflammatory cytokine that is involved in inflammatory responses. They suggested that polymorphisms in IL-1 gene (presence of IL-1 β + C3953 allele and IL-1RN + 2018C allele) are involved in root resorption pathogenesis. Urban *et al.* demonstrated that IL-1 gene polymorphism presents a significantly higher risk for development of pathological root resorptions [21]. Linares *et al.* also suggested that variations in the interleukin 1 receptor antagonist gene (rs419598) and not only in the IL-1 β gene (rs1800587) are determinants of a predisposition to post-orthodontic external apical root resorption. Activation of IL-1 β inflammation pathway due to chronic pulpal inflammation might be responsible for external root resorption in the presented case, which should be studied more in future [22].

4. Conclusion

Although the exact etiology of the idiopathic root resorption is still unknown, the present case showed that there might be relationship between extensive pulpal inflammation and the idiopathic resorption. Further studies on the molecular basis of the root resorption are recommended.

Conflict of Interest: 'None declared'.

References

- [1] Patel S, Kanagasingam S, Pitt Ford T. External cervical resorption: a review. *J Endod.* 2009;35(5):616-25.
- [2] Schatzle M, Tanner SD, Bosshardt DD. Progressive, generalized, apical idiopathic root resorption and hypercementosis. *J Periodontol.* 2005;76(11):2002-11.
- [3] Bakland LK. Root resorption. *Dent Clin North Am.* 1992;36(2):491.
- [4] Belanger GK, Coke JM. Idiopathic external root resorption of the entire permanent dentition: report of case. *ASDC J Dent Child.* 1985;52(5):359-63.
- [5] Yusof WZ, Ghazali MN. Multiple external root resorption. *J Am Dent Assoc.* 1989;118(4):453-5.
- [6] Rivera EM, Walton RE. Extensive idiopathic apical root resorption. A case report. *Oral Surg Oral Med Oral Pathol.* 1994;78(5):673-7.
- [7] Estrela C, Bueno MR, De Alencar AHG, Mattar R, Valladares Neto J, Azevedo BC, De Araújo Estrela CR. Method to evaluate inflammatory root resorption by using cone beam computed tomography. *J Endod.* 2009;35(11):1491-7.
- [8] Fuss Z, Tsesis I, Lin S. Root resorption—diagnosis, classification and treatment choices based on stimulation factors. *Dent Traumatol.* 2003;19(4):175-82.
- [9] Trope M, Moshonov J, Nissan R, Buxt P, Yesilsoy C. Short vs. long-term calcium hydroxide treatment of established inflammatory root resorption in replanted dog teeth. *Endod Dent Traumatol.* 1995;11(3):124-8.
- [10] Vatanpour M, Javidi M, Zarei M, Shirazian S. External root resorption: Arrested or progressing? *Iran Endod J.* 2009;3(3):93-4.
- [11] Asgary S, Ahmadyar M. One-visit RCT of Maxillary Incisors with Extensive Inflammatory Root Resorption and Periradicular Lesions: A Case Report. *Iran Endod J.* 2011;6(2):95-8.
- [12] Ingle JL. *Ingle's endodontics.* 6th Edition: Pmph USA Limited; 2008. pp. 1358-80
- [13] Sogur E, Sogur HD, Baksi Akdeniz BG, Sen BH. Idiopathic root resorption of the entire permanent dentition: systematic review and report of a case. *Dent Traumatol.* 2008;24(4):490-5.
- [14] Khojastepour L, Bronoosh P, Azar M. Multiple idiopathic apical root resorption: a case report. *J Dent (Tehran).* 2010;7(3):165-9.
- [15] Armas JM, Savarrio L, Brocklebank LM. External apical root resorption: two case reports. *Int Endod J.* 2008;41(11):997-1004.
- [16] Di Domizio P, Orsini G, Scarano A, Piattelli A. Idiopathic root resorption: report of a case. *J Endod.* 2000;26(5):299-300.
- [17] Moazami F, Karami B. Multiple idiopathic apical root resorption: a case report. *Int Endod J.* 2007;40(7):573-8.
- [18] Saravia ME, Meyer ML. Multiple idiopathic root resorption in monozygotic twins: case report. *Pediatr Dent.* 1989;11(1):76-8.
- [19] Lydiatt DD, Hollins RR, Peterson G. Multiple idiopathic root resorption: diagnostic considerations. *Oral Surg Oral Med Oral Pathol.* 1989;67(2):208-10.
- [20] Al-Qawasmi RA, Hartsfield JK, Jr., Everett ET, Flury L, Liu L, Foroud TM, et al. Genetic predisposition to external apical root resorption. *Am J Orthod Dentofacial Orthop.* 2003;123(3):242-52.
- [21] Urban D, Mincik J. Monozygotic twins with idiopathic internal root resorption: A case report. *Aust Endod J.* 2010;36(2):79-82.
- [22] Iglesias-Linares A, Yañez-Vico R, Ballesta-Mudarra S, Ortiz-Ariza E, Ortega-Rivera H, Mendoza-Mendoza A, et al. Postorthodontic external root resorption is associated with IL1 receptor antagonist gene variations. *Oral Diseases.* 2012;18(2):198-205.

Please cite this paper as: Bolhari B, Meraji N, Nosrat A. Extensive Idiopathic External Root Resorption in First Maxillary Molar: A Case Report. *Iran Endod J.* 2013;8(2):72-4