



Four cases of pneumomediastinum

Case Report

Cite as: Aujayeb A, Miller J, Weatherhead M, *et al.* Four cases of pneumomediastinum. *Breathe* 2015; 11: e1–e5

Pneumomediastinum or mediastinal emphysema is defined as the presence of air in the mediastinum, the central compartment of the thoracic cavity that contains the heart and its vessels, the oesophagus, trachea, vagus and phrenic nerves, and thymus, among other organs. There are no concrete epidemiological data but case series point to an approximate incidence of one in 7000 to one to 45000 hospital admissions [1–3], with a predilection for young males [2].

There a number of different causes of pneumomediastinum, with acute asthma exacerbations being the most common. Valsalva manoeuvres; vomiting; respiratory infections; diabetic ketoacidosis; oesophageal rupture; helium gas, illicit drug or foreign body inhalation; dental extraction; and barotrauma have all been previously described [4].

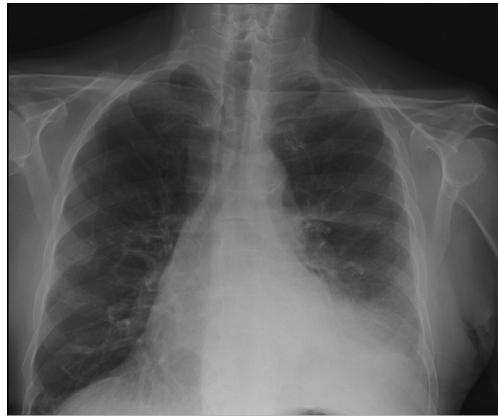

Figure 1 Chest radiography from case 1 showing left pleural effusion.

Case 1

An 83-year-old male presented to the specialist pleural clinic with a left pleural effusion (figure 1) and progressive dyspnoea that limited his exercise tolerance on the flat to 200 m. He had lost 10 kg in weight and had a mild cough but no haemoptysis. He was an ex-smoker of 40 pack-years and previously worked in a power station where he had had significant asbestos exposure. His past medical history included chronic obstructive pulmonary disease, a previous cerebrovascular accident, type 2 diabetes, atrial fibrillation and congestive cardiac failure.

His computed tomography (CT) scan (figure 2) shows a small left loculated pleural effusion with

some evidence of pleural thickening. A thoracic ultrasound showed a heavily septated effusion and we were unable to aspirate any fluid; therefore, single-port medical thoracoscopy was performed.

An artificial pneumothorax was created with a Boutin needle. Blunt dissection allowed 0° and 50° scopes to visualise the pleural space. 500 mL blood-stained fluid were removed, and a grossly abnormal pleura was biopsied and septations broken down. Talc poudrage was performed and a 24-French chest tube was inserted, with good swing noticed. There were no immediate complications. Chest radiography was performed post-procedure and showed a pneumomediastinum (figure 3).



@ERSpublications

Pneumomediastinum is an uncommon clinical entity that can have disastrous consequences

<http://ow.ly/UtYYh>



ERS 2016

HERMES syllabus link:
module B.13.3

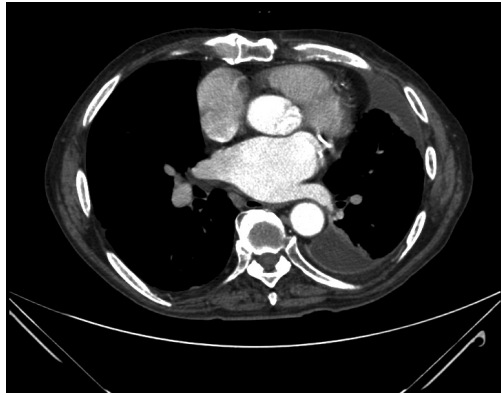


Figure 2 Computed tomography image from case 1 showing a small left loculated pleural effusion with some evidence of pleural thickening.

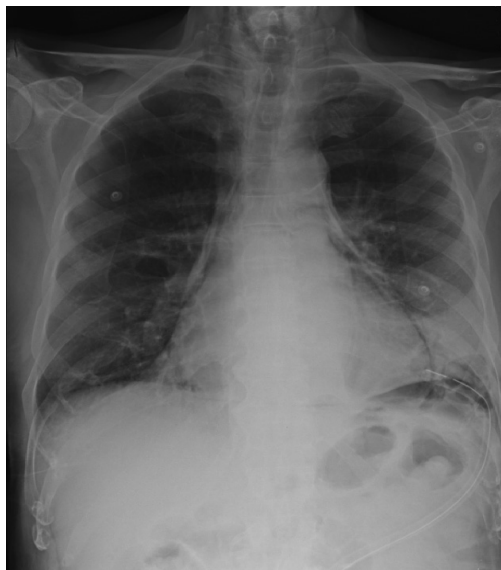

Figure 3 Chest radiography from case 1 showing a pneumomediastinum.

The patient was completely asymptomatic and had an oxygen saturation of 96% on air. He was observed overnight and discharged home the next day as he remained well, and there was no bubbling or output from the drain.

Follow-up chest radiography (figure 4) showed that his pneumomediastinum resolved with no intervention and he remained well. Thoracoscopic biopsies showed benign fibrinous pleuritis with no evidence of malignancy. We can find no report of pneumomediastinum occurring post-thoracoscopy. The patient had coughed a lot during the procedure, which is unusual. We surmise that coughing increased his bronchoalveolar pressures leading to air leakage into the mediastinum through the bronchovascular layers. The air dissects the path of least resistance onto the fascial planes of the neck, a process known as the Macklin effect [5].

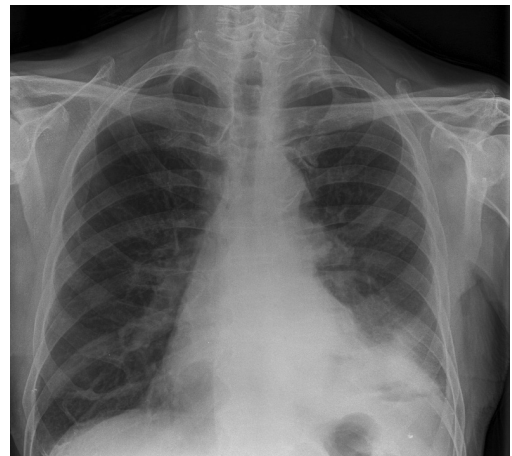

Figure 4 Follow-up chest radiography from case 1 showing resolution of the pneumomediastinum.

Case 2

A 17-year-old male with no past medical history and receiving no medications was on a night out when he lifted one of his friends. He remembers straining to lift that person and then developed mild exertional breathlessness over the space of 2 h. He presented to the accident and emergency department, where he was noted to be well with a respiratory rate of 14 breaths per minute and oxygen saturation of 98% on air. His examination revealed crepitus under the skin of his neck, cheeks and scalp, but normal air entry on chest auscultation bilaterally. There was no history of vomiting or retching.

Chest radiography (figure 5) showed extensive surgical emphysema but no obvious pneumothorax. He remained well and his breathlessness resolved quickly and spontaneously. He was observed overnight, but the next morning complained that his eyes felt swollen. CT was performed (figures 6–8).

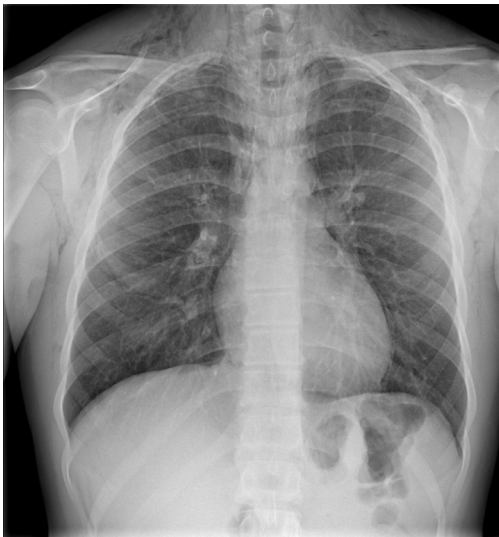

Figure 5 Chest radiography from case 2 showing extensive surgical emphysema.

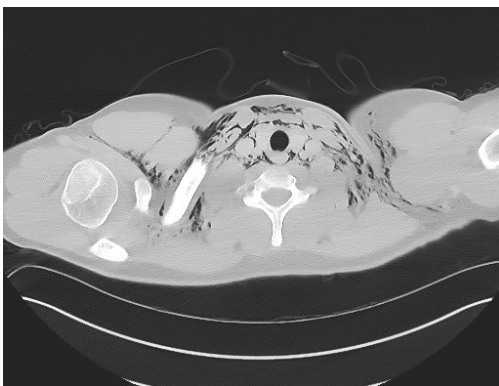

Figure 6 High-resolution cut showing significant surgical emphysema in neck tissues.

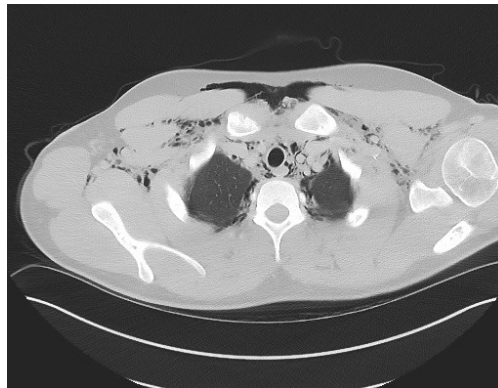


Figure 7 High-resolution cut showing air in anterior mediastinum.

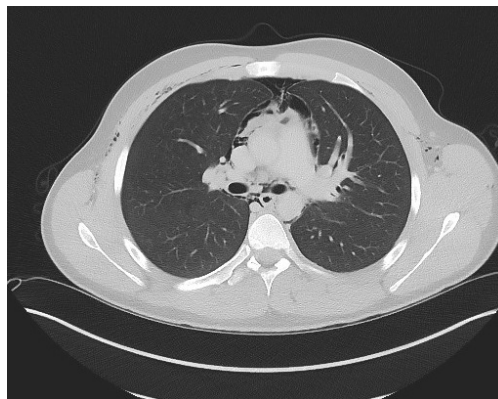


Figure 8 High-resolution cut showing air in pericardium.

Task 1

What does the CT (figures 6–8) show?

- A ruptured oesophagus
- Bilateral apical pneumothoraces
- A large pneumopericardium causing cardiac tamponade
- Extensive bullous disease
- None of the above

Task 2

What would be an appropriate management for the patient in case 2?

- Bilateral surgical drains
- Urgent referral to cardiothoracic team
- Urgent pericardiocentesis
- Observation on the ward for worsening symptoms
- Steroids, antibiotics and nebulisers

Answer 1

e. None of the above

Answer 2

a. Observation on the ward for worsening symptoms

Case 3

A 21-year-old male with poorly controlled asthma was celebrating his birthday in a nightclub when he developed acute breathlessness. He denied any illicit drug use or vomiting after alcohol ingestion and admitted to not taking any of his inhalers. He was mildly wheezy on admission to the accident and emergency department, with good air entry bilaterally on auscultation. His peak flows were 70% of predicted and his pulse rate was 60 beats per minute with oxygen saturations of 98%. His blood tests and ECG were normal as was his arterial blood gas. He was given 40 mg of prednisolone and bronchodilating nebulisers. Chest radiography was performed (figure 9).

Extensive pneumomediastinum was noted with surgical emphysema and air dissecting to the fascia, neck spaces, supraclavicular regions and anterior chest wall. The lung parenchyma was normal without bullae or blebs. The oesophagus was normal and there was a small pneumopericardium.

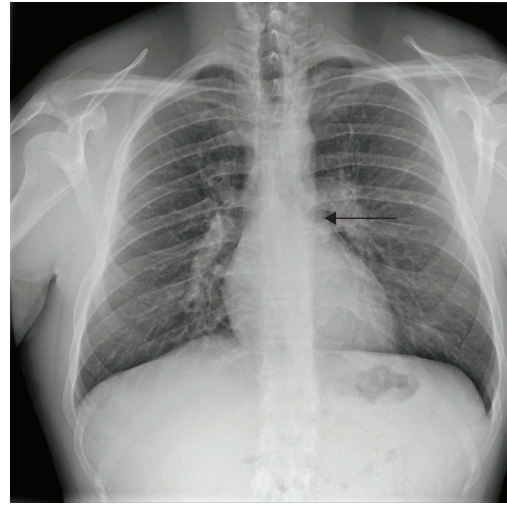


Figure 9 Chest radiography from case 3.

The chest radiograph was interpreted as being normal by the accident and emergency doctor, and the patient sent home. The radiograph was reported as showing a small pneumomediastinum by the radiologist in the morning and the patient was recalled for CT. The CT confirmed a small pneumomediastinum but no other abnormality of note. The patient had remained well and only mild wheeze was audible bilaterally.

Task 3

What does the arrow in the chest radiograph (figure 9) indicate?

- a. Left lower lobe collapse
- b. A small right sided pneumothorax
- c. A small pneumomediastinum
- d. A pericardial effusion
- e. None of the above

Answer 3

c. A small pneumomediastinum

The patient in case 2 had no symptoms at all and was in a stable cardiorespiratory condition. As such, observation for any signs of worsening was appropriate. There is no rationale behind placing surgical drains in the absence of any pneumothoraces. He remained stable for the next 24 h and was discharged the next day. The patient in case 3 was admitted for 24 h for steroids, antibiotics and nebulisers, and discharged when he was not wheezy anymore. Such cases of spontaneous pneumomediastinum are almost universally benign, self-limiting conditions with no intervention required and are due to the Macklin effect as well [4].

Case 4

A 59-year-old male with T3N2M1a squamous cell carcinoma of the right upper lobe presented with progressive dyspnoea and fevers. He had received palliative chemotherapy 1 month prior to presentation and had been under regular follow-up. He had a temperature of 38.9°C and was tachycardic but normotensive. His white cell count and C-reactive protein were markedly elevated. Chest radiography was performed and showed the lung cancer but also a pneumomediastinum; therefore CT was also performed.

Task 4

What do the CT (figures 10–12) images show?

- A large pneumopericardium
- Necrotic mediastinal nodes
- Large cavitating mass in right upper lobe
- Connection between mass and bronchus
- All of the above

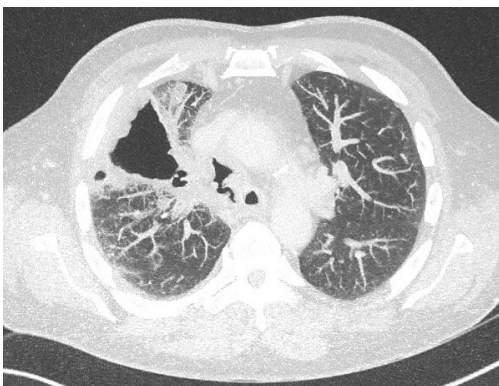


Figure 10 *Large cavitating mass in right upper lobe.*

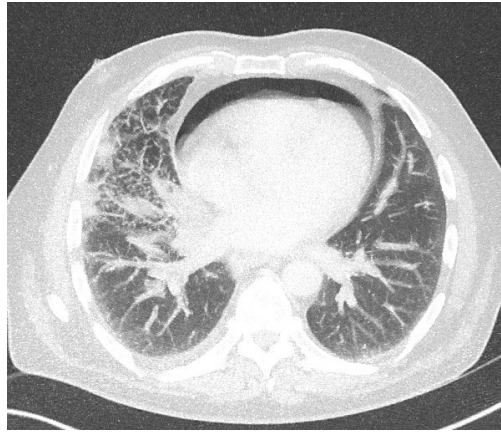


Figure 11 *Large pneumo-pericardium.*

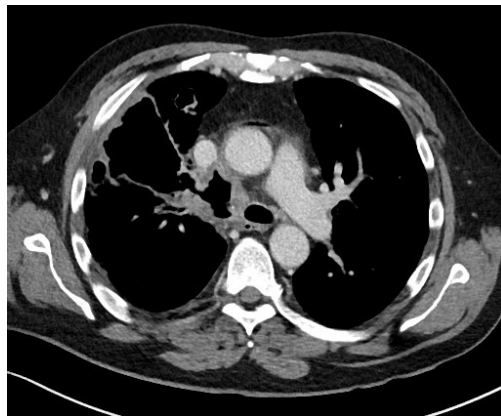


Figure 12 *Connection between mass and bronchus.*

Task 5

What would be the next appropriate steps?

- High-dose intravenous antibiotics
- Urgent discussion with cardiothoracic team
- Urgent discussion with cardiology
- Discussion with patient and family about a Do Not Resuscitate order
- All of the above

Answer 4

e. All of the above

Answer 5

e. All of the above

The patient was very unwell with progressive disease, sepsis and the pneumopericardium. It was

felt that he might be at risk of cardiac tamponade and an urgent echocardiography was performed by the on-call cardiologist did not show that. There was no cardiothoracic intervention possible. The patient was started on high-dose antibiotics and because his prognosis was poor, an appropriate treatment escalation plan was put in place, which included a Do Not Resuscitate order. After a prolonged admission, the patient died of progressive carcinomatosis. Case 4 is obviously different from the other three, and highlights the heterogeneity of the aetiology of pneumomediastinum.

Conflict of interest

None declared.

References

1. Iyer VN, Joshi AY, Ryu JH. Spontaneous pneumomediastinum: analysis of 62 consecutive adult patients. *Mayo Clin Proc* 2009; 84: 417-421.
2. Abolnik I, Lossos IS, Breuer R. Spontaneous pneumomediastinum. A report of 25 cases. *Chest* 1991; 100: 93-95.
3. Takada K, Matsumoto S, Hiramatsu T, *et al.* Management of spontaneous pneumomediastinum based on clinical experience of 25 cases. *Respir Med* 2008; 102: 1329-1334.
4. Meireles J, Neves S, Castro A, *et al.* Spontaneous pneumomediastinum revisited. *Respir Med CME* 2011; 4: 181-183.
5. Macklin CC. Transport of air along sheaths of pulmonic blood vessels from alveoli to mediastinum: clinical implications. *Arch Intern Med* 1939; 64: 913-926.