

[Physical Therapy]



The Development of Humeral Retrotorsion and Its Relationship to Throwing Sports

Elliot M. Greenberg, PT, DPT, OCS, CSCS,*^{†‡} Alicia Fernandez-Fernandez, PT, DPT, PhD,[§] J. Todd R. Lawrence, MD, PhD,^{||¶} and Philip McClure, PT, PhD, FAPTA[‡]

Context: Several investigations have noted that throwing athletes exhibit a more posteriorly oriented humeral head (humeral retrotorsion) in the dominant arm. This asymmetry is believed to represent an adaptive response to the stress of throwing that occurs during childhood. The significance of this alteration and factors that affect its development are currently not clear.

Evidence Acquisition: Basic science, research studies, and review articles were searched through PubMed with search terms including *humeral torsion*, *humeral retrotorsion*, and with 1 of the following: *pediatric*, *adult*, *baseball*, *pitching*, *shoulder*, and *range of motion*. The references from each article were reviewed for further inclusion. This review included articles through March 2015.

Study Design: Clinical review.

Level of Evidence: Level 4.

Results: The throwing motion creates stressors that result in bony adaptations that occur while skeletally immature. These osseous changes likely contribute to the observed shift in the arc of rotational range of motion noted in throwing athletes and may play a protective role against injury. However, too much or too little retrotorsion may predispose the shoulder to injury. The degree of “optimal” humeral retrotorsion and factors that influence its development are not fully understood.

Conclusion: Evidence supports the assertion that the throwing motion creates stressors that alter bony anatomy while young. It is important to determine what specific factors affect this adaptation and its relationship to injury.

Keywords: humeral retrotorsion; humeral torsion; pediatric; shoulder range of motion; throwing athlete

Several investigations have consistently noted an increase in humeral retrotorsion, a more posterior orientation of the humeral head associated with transverse plane humeral torsion, in the dominant shoulder of throwing athletes.^{7,8,27-29,39,41,45} The significance of this observed alteration in humeral alignment and its relationship to injury is currently not clear. Many authors propose that this alteration represents a healthy adaptation to the stress of the throwing motion, allowing for increased overall arm external rotation with reduced stress to the glenohumeral joint soft tissue.^{17,28,29,40} This adaptation may therefore have a protective effect against injury. However, there is also evidence that insufficient or excessive

humeral torsion may actually contribute to injury in the shoulder or elbow.^{25,26,29}

The purposes of this article are to describe the normal developmental process responsible for humeral orientation and the proposed mechanisms by which throwing athletes develop altered humeral alignment and to explore the association between injury risk and alterations in humeral torsion.

DEVELOPMENT OF HUMERAL TORSION

Humeral torsion is defined as the rotational difference in the relative position of the humeral head and the axis of the elbow

From [†]Sports Medicine and Performance Center at The Children’s Hospital of Philadelphia, Philadelphia, Pennsylvania, [‡]Department of Physical Therapy, Arcadia University, Glenside, Pennsylvania, [§]Department of Physical Therapy, Nova Southeastern University, Fort Lauderdale, Florida, ^{||}Division of Orthopaedic Surgery, The Children’s Hospital of Philadelphia, Philadelphia, Pennsylvania, and [¶]Department of Orthopaedic Surgery, University of Pennsylvania, Philadelphia, Pennsylvania

*Address correspondence to Elliot M. Greenberg, PT, DPT, OCS, CSCS, Sports Medicine and Performance Center at The Children’s Hospital of Philadelphia, Pediatric and Adolescent Specialty Care Center Bucks County, 500 West Butler Avenue, Chalfont, PA 18914 (email: greenberge@email.chop.edu).

The following authors declared potential conflicts of interest: Elliot M. Greenberg, PT, DPT, OCS, CSCS, receives payment for lectures, including service on speakers bureaus for the Professional Therapy Seminars Pediatric Sports Rehabilitation Course; J. Todd R. Lawrence, MD, PhD, received royalties from Sawbones Inc.; Philip McClure, PT, PhD, FAPTA, has grants/grants pending from the NIH and receives payment for lectures, including service on speakers bureaus for Rehab Education. A portion of this article was supported by the Legacy Fund Grand through the Sports Section of the APTA.

DOI: 10.1177/1941738115608830

© 2015 The Author(s)

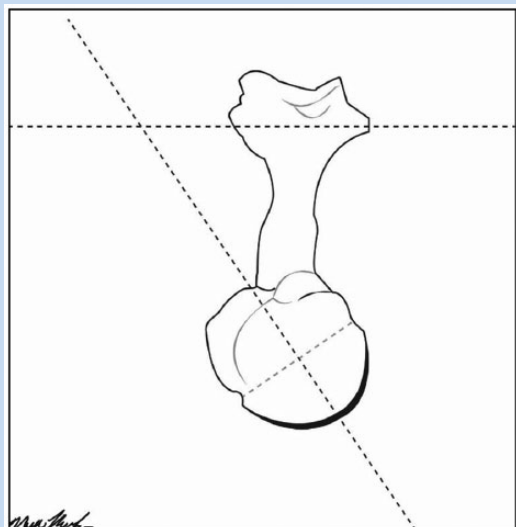


Figure 1. Schematic drawing of the left humerus, viewed from above. The dashed lines represent a line perpendicular to the proximal humeral articular surface (representing proximal humerus orientation) and the transepicondylar axis (representing distal humerus orientation). The difference between these angles is the degree of humeral retrotorsion present.

at the distal humerus.^{19,31} Humeral retrotorsion describes the bony architecture that occurs when the head of the humerus is oriented in a posterior medial direction and is associated with a transverse plane rotation within the humerus (Figure 1). The degree of humeral retrotorsion in adults varies depending on age, sex, limb dominance, and race, but the generally accepted “normal” value for adult retrotorsion is between 25° and 35°.¹¹

The final degree of humeral torsion is the result of 2 factors: a developmental derotation process and a secondary adaptive torsion caused by muscular forces acting on the humerus.^{10,19,32} At birth, the humeral head is in marked retrotorsion and undergoes a process of derotation (less retrotorsion) during the pediatric and adolescent years.^{10,19} Krahl¹⁹ proposed that there are opposing rotational stresses imparted by muscular forces above and below the proximal humeral physis, exerted by the external and internal rotators, respectively. These rotational stresses result in an adaptive response that derotates the humeral head and reduces the degree of retrotorsion during the growing years (Figures 2-4). This process occurs most rapidly up to the age of 8 years and then slows down, approaching mean adult values by the age of 16 years and ceasing with closure of the physis at skeletal maturity.^{10,18}

HUMERAL RETROTORSION AND THROWING ATHLETES

In the healthy adult population, the dominant shoulder tends to demonstrate a greater degree of humeral retrotorsion.²¹ Adult

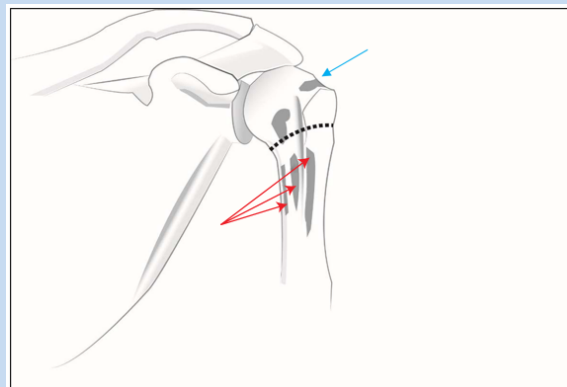


Figure 2. Anterior view of the proximal left humerus. Dashed line, location of the proximal humeral growth plate; red arrows, insertion points of medial rotator muscles (pectoralis major, latissimus dorsi, teres major) inferior to the growth plate; blue arrow, insertion of lateral rotators superior to growth plate.

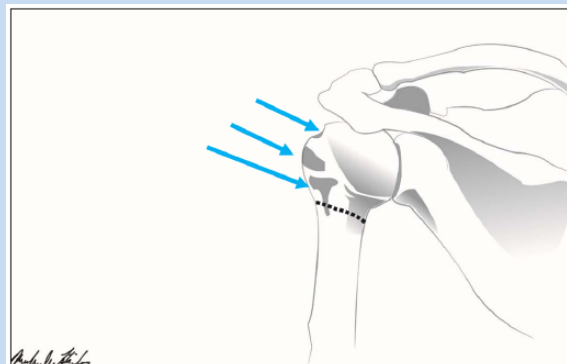


Figure 3. Posterior view of the proximal humerus. Dashed line, location of the proximal humeral growth plate; blue arrows, insertion of supraspinatus, infraspinatus, and teres minor superior to growth plate.

throwing athletes have larger side-to-side differences than nonthrowing athletes (Table 1).^{7,8,27-29,39,41,45} Although the studies in throwing athletes show similar patterns of increased retrotorsion on the dominant side, there is variability in the magnitude of these differences that likely reflects several confounding factors including age, throwing history, throwing mechanics, genetic variation, and measurement differences. Studies investigating side-to-side differences in humeral retrotorsion in young athletes are more limited. These studies indicate that in young throwing athletes, humeral retrotorsion tends to decrease with age; however, it is currently not clear at what age a significant side-to-side asymmetry develops (Table 2).^{15,46} The limited data available do appear to suggest that preadolescence or early adolescence is likely a pivotal time in

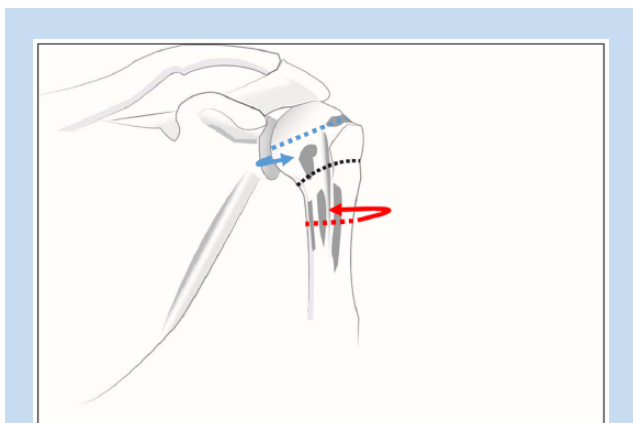


Figure 4. Anterior view of the proximal left humerus indicating the opposing rotational forces exerted by muscles above and below the physis (dashed line). These forces influence proximal humeral positioning during normal development. Assuming the humeral head begins in a greater degree of retrotorsion (more posteromedially oriented position), these forces would facilitate derotation, resulting in a more anteromedial humeral head orientation.

development of humeral asymmetry, but more research is required to fully understand this process.

In accordance with Wolff's law, bone growth is influenced by applied mechanical forces either through muscular forces or external stress.⁶ Sabick et al³² performed a biomechanical analysis of the forces acting on the proximal humerus during the pitching motion and concluded that the magnitude and direction of forces is consistent with the development of humeral retrotorsion. At the end of the arm-cocking phase, just before maximum external rotation, overall muscular forces and body acceleration act to create an internal rotation torque at the proximal humerus, while the distal humerus and forearm continue to apply a net external rotation torque until all of the energy is dissipated (Figure 5). In skeletally immature athletes, this net external rotation torque about the long axis of the humerus would be sensed at the proximal humeral physis. These stresses would thus facilitate an environment favoring a more posteriorly oriented humeral head, which is consistent with the position of humeral retrotorsion. These forces may be sufficient to delay the normal derotation process at the proximal humerus and account for side-to-side differences in humeral retrotorsion.³²

HUMERAL RETORTORSION AND RELATIONSHIP TO SHOULDER RANGE OF MOTION

Glenohumeral range of motion (ROM) is an important consideration when evaluating a throwing athlete, as deficits in motion have been associated with an increased likelihood of shoulder or elbow injuries.¹⁷ Throwing athletes exhibit a pattern of increased glenohumeral external rotation (GER) and limited

glenohumeral internal rotation (GIR) in their dominant shoulder.^{4,8,12,17} Often, the increased GER is balanced by a concurrent loss of GIR, such that the total arc of motion is the same just shifted into more external rotation in the throwing shoulder. This alteration in motion is most likely the result of both bony and soft tissue adaptation to the forces encountered during throwing,⁴²⁻⁴⁴ but the relative contribution of each remains unclear. Increased humeral retrotorsion may account for the altered motion by allowing increased external rotation in the distal humeral segment without requiring increased rotation at the glenohumeral articulation (Figure 6).^{24,27,30} However, soft tissue adaptations, such as anterior capsular laxity or posterior shoulder tightness (capsular and musculotendinous),^{22,23,33} may also play a role.

Several investigators have sought to determine how osseous torsional changes influence clinically measured glenohumeral motion (Table 3). Generally speaking, the correlations appear inconsistent and weak, indicating that the osseous influence on glenohumeral motion is variable. In addition, it is possible that humeral retrotorsion may affect shoulder ER and IR differently.²⁶ The association between bony torsion changes and expressed shoulder ROM may be stronger in younger throwing athletes. Hibberd et al¹⁵ studied the relationship of humeral retrotorsion to age-related changes in shoulder ROM in a group of youth athletes and found that after accounting for humeral retrotorsion, GIR asymmetry remained unchanged across age groups. This suggests that a loss of GIR during aging is primarily attributed to changes in humeral retrotorsion and supports the assertion that the degree of humeral retrotorsion influences shoulder ROM.

Determining the relative contribution of bony versus soft tissue adaptation to the ROM profile of the throwing athlete holds a high degree of clinical relevance, as isolated deficits in GIR motion of 20° or more³⁴ and deficits in total range of motion of greater than 5°⁴² have been identified as risk factors for the development of shoulder or elbow pain. Understanding how much of an effect humeral retrotorsion has on shoulder motion will assist clinicians in clinical decision making for directed interventions. Historically, computed tomography had been considered the most accurate method of assessing humeral retrotorsion; however, more recently, ultrasound imaging has been advocated for a valid, reliable, and clinically useful means of assessing humeral torsion.³ Palpation methods of evaluating humeral retrotorsion are considered too unreliable to be recommended for clinical use.¹³

HUMERAL RETORTORSION AND SHOULDER PATHOLOGY

The significance of altered proximal humeral alignment in the throwing arm of athletes and its relationship to injury is unclear. It has been hypothesized that increased humeral retrotorsion could play either a contributory or protective role in the development of upper extremity pathology in the overhead athlete (Table 4).

Table 1. Side-to-side differences in humeral retrotorsion in adult throwing athletes and normal population

Author	Subject	Measurement Type	Side-to-Side Difference in Retrotorsion, deg, mean
Pieper ²⁸	51 Olympic handball players	Radiograph	9.4
Crockett et al ⁸	25 professional pitchers, 25 nonthrowing adults	CT	17
Reagan et al ³⁰	54 collegiate baseball players	Radiograph	10.6
Osbaahr et al ²⁷	19 collegiate baseball players	Radiograph	10.1
Chant et al ⁷	19 baseball players (professional and collegiate)	CT	10.6
Thomas et al ³⁶	24 collegiate baseball players	US	15.6
Polster et al ²⁹	25 professional pitchers	CT	10.8
Shanley et al ³⁵	33 professional pitchers	US	13
Noonan et al ²⁶	222 professional pitchers	US	19.5 with GIRD ^a 12.3 without GIRD ^a
Healthy adult population			
Matsumura et al ²¹	205 healthy adults	CT	3

CT, computed tomography; GIRD, glenohumeral internal rotation deficit; US, ultrasound.

^aGIRD defined as >15° loss of internal rotation with concomitant loss of 10° total range of motion.

Table 2. Side-to-side differences in humeral retrotorsion in youth throwing athletes

Author	Age Group	Side-to-Side Difference in Humeral Retroversion, deg, mean
Yamamoto et al ⁴⁶	Third and fourth graders	5.3
	Fifth graders ^a	7.5
	Sixth graders	1.8
	Seventh graders	2.7
	Eighth graders	3.6
Hibberd et al ¹⁵	Youth (6-10 y; mean, 8.3 y) ^a	7.5 ± 10.1
	Junior high (11-13 y; mean, 11.9 y) ^a	10.7 ± 9.9
	Junior varsity (14-16 y; mean, 14.6 y) ^a	15.3 ± 11.1
	Varsity (16-18 y; mean, 16.9 y) ^a	16.2 ± 11.4
Whiteley et al ⁴⁰	Adolescent (mean, 16.6 ± 0.6 y) ^a	11.2

^aStatistically significant side-to-side differences noted.

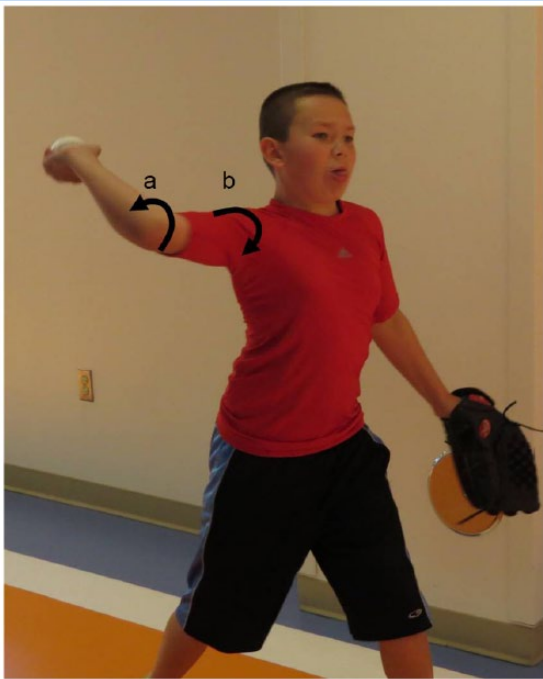

Figure 5. (a) While pitching, the weight of the forearm and ball produce an external rotation torsional force about the long axis of the humerus distally. (b) Body momentum, joint capsule, and muscular forces create an internal rotation torque at the proximal humerus. These opposing forces facilitate a more posteriorly oriented humeral head consistent with increased humeral retrotorsion.

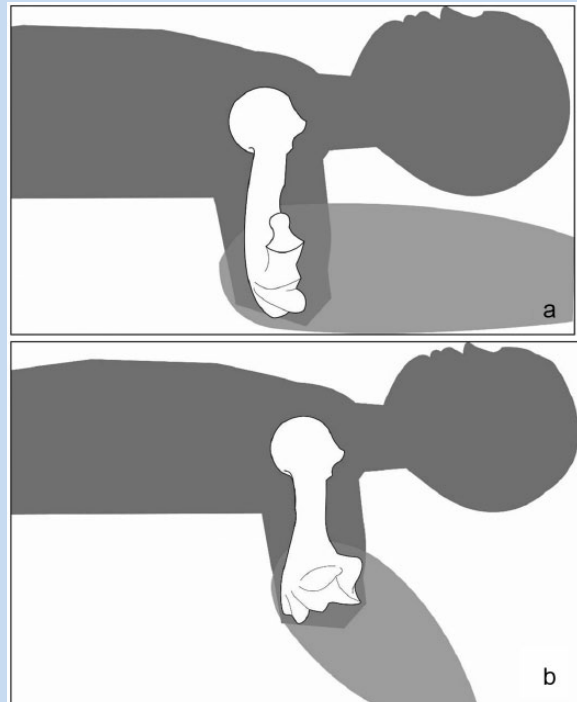


Figure 6. (a and b) Demonstration of how an increase in humeral retrotorsion would alter shoulder range of motion. The humeral head remains in the same orientation; however, if there is an increase in humeral retrotorsion (b), there is an apparent gain in external rotation range of motion.

A gain in overall external rotation brought about by increased humeral retrotorsion would allow a thrower to achieve the late cocking phase of throwing with less stress imparted to the anterior stabilizing structures of the shoulder.²⁸ Throwing athletes with insufficient humeral retrotorsion reach the end of allowable GER before their arm achieves the optimal position of overall ER to complete the late cocking phase of throwing. To get the extra rotation, these players may overstretch their anterior capsule, leading to the development of anterior instability and pain.²⁸ Alternatively, they may attempt to overrotate the glenohumeral articulation, imparting excessive twisting on the long head of the biceps insertion and internal impingement between the rotator cuff and the labrum between the greater tuberosity and posterior superior glenoid margin.²⁹ Since increased humeral retrotorsion allows the shoulder to achieve the same degree of GER while imparting less of a twisting force to the long head of the biceps and decreasing the likelihood of internal impingement, it may be protective against both rotator cuff and labral pathology.^{29,40}

Although a higher degree of humeral retrotorsion may serve a stress shielding function to the anterior and superior glenohumeral structures, it may impart increased stress to the posterior shoulder tissues. Greater humeral retrotorsion allows

for greater ER, which allows for greater angular velocity to be achieved during the acceleration phase of throwing.^{9,14} This subsequently leads to an increase in distraction forces during the deceleration phase of the throwing motion.^{35,36} After ball release, the posterior rotator cuff and capsule must absorb all of the stresses and decelerate the arm.⁵ The greater degree of stress may cause tissue overload leading to capsular thickening and a loss of posterior tissue flexibility.³⁶ These increased forces are also distributed over a much smaller range, as increased humeral retrotorsion decreases overall arm IR and thus compresses the available range to decelerate the arm after ball release.²⁶ The tight posterior capsule may then alter the normal contact points of the humeral head with the glenoid during GER, allowing the humeral head to shift posteriorly and superiorly on the glenoid and increase the risk of internal impingement and posterior superior labral pathology.^{5,17}

Because of the integrative nature of the throwing motion, it is plausible that alterations in the throwing motion proximally could have injurious effects distally. For example, the increased rotation associated with more humeral retrotorsion allows for an extreme degree of overall arm ER to be achieved during throwing. The greater degree of maximum overall arm ER at the late cocking phase of throwing may be associated with

Table 3. Relationship between humeral retrotorsion and glenohumeral rotation range of motion in the throwing arm of baseball players

Study	Sample	Correlation Between Humeral Retrotorsion and GER, <i>r</i>	Correlation Between Humeral Retrotorsion and GIR, <i>r</i>
Osborne et al ²⁷	19 college	0.86	0.01
Reagan et al ^{30a}	54 college ^a	0.43	0.40
Chant et al ⁷	19 subjects, professional and college; mean age, 23.4 y	0.55	-0.42
Thomas et al ³⁶	24 college	0.30	-0.47
Noonon et al ²⁶	222 professional pitchers ^b	-0.17	0.48
Hibberd et al ¹⁵	287 youth baseball players, age 6-18 y	Correlations not reported. Older youth had greater GIRD and humeral retrotorsion asymmetry. GIRD differences disappeared if GIR corrected for humeral retrotorsion. Total ROM not different across age groups.	

GER, glenohumeral external rotation; GIR, glenohumeral external rotation; GIRD, glenohumeral internal rotation deficit; ROM, range of motion.

^aCorrelation between retrotorsion and humeral rotation motion using side-to-side differences in each rather than absolute values.

^bSign of correlation varies depending upon convention of reporting humeral torsion versus humeral retrotorsion.

Table 4. Proposed effects of humeral retrotorsion relative to injury potential in throwing athletes

Degree of Humeral Retrotorsion		
Decreased	Adequate	Increased
Possible issues:	Protective effects:	Possible issues:
Anterior shoulder instability	Decreased stress to anterior shoulder stabilizers	Decreased posterior shoulder flexibility leading to GIRD or TROM loss
Superior labral pathology	Decreased stress imparted to anterior-superior labral complex	Increased valgus stress at elbow
Internal impingement at the shoulder	Decreased likelihood of internal impingement	

GIRD, glenohumeral internal rotation deficit; TROM, total range of motion.

increased tensile stress across the medial elbow and increased compression force in the radiocapitellar joint,^{14,32,38} which may result in an increased risk of elbow overuse injuries.¹ Collegiate pitchers with a history of elbow pain exhibited greater side-to-side limb differences in humeral retrotorsion.²⁵

In summary, the interplay between humeral torsion, shoulder range of motion, and the biomechanical effects on the throwing motion is complex. It is likely that there is a protective “sweet spot” of humeral retrotorsion that lies within a certain range and provides a healthy adaptation for throwing in the dominant shoulder; values outside of this range may impart an increased risk of upper extremity injury within these athletes.²⁹

IMPORTANT QUESTIONS FOR FUTURE INVESTIGATIONS

Does Throwing Activity Really Affect the Development of Humeral Retrotorsion?

There is a large body of literature demonstrating that throwing athletes exhibit increased humeral retrotorsion in their dominant shoulder.^{7,8,27,28,30,40,41,45,46} This position of the humerus likely occurs as a result of throwing activity during the early years of childhood, which limits the natural process of humeral derotation, creating the side-to-side asymmetry. Although many authors agree with this hypothesis, there are no longitudinal

studies documenting these bony changes throughout the developmental process in a group of throwing athletes. Yamamoto et al⁴⁶ performed a cross-sectional study in a group of 9- to 14-year-old throwers (n = 66) and found that humeral retroversion tended to decrease with age; however, the side-to-side difference was only significant in a single group of fifth graders. Humeral retroversion in 6- to 18-year-old baseball players (n = 287) showed statistically significant differences existed for every age group, even the youngest throwers (see Table 2).¹⁵ Without a control group, it is unclear whether this side-to-side difference represents a genetic variation in humeral torsion or if this difference is in fact accounted for by throwing at a very early age (adaptive vs genetic). Thus, while there is a clear difference noted in adult throwers, longitudinal studies in throwers and nonoverhead athletes will likely be necessary to firmly establish that humeral torsion asymmetry develops in response to throwing in developing athletes.

Does the Effect of Humeral Retroversion on Shoulder ROM Vary With Age?

During the aging process there is a natural change in the physical properties of connective tissue resulting in increased stiffness of muscles and tendons.² In the adolescent throwing athlete, this process of collagen turnover is layered over the development of humeral retroversion, and each may exert different influences on the shoulder ROM during the maturation process. The soft tissue surrounding the shoulder of young subjects may provide less constraint or influence on shoulder mobility, and therefore, shoulder motion may be more dependent on bony architecture. This hypothesis may account for the strong association of humeral retroversion and alteration in GIR in youth athletes,¹⁵ while others found a less distinct correlation in older populations.^{7,27,30,36}

What Are the Effects of Throwing Volume on Humeral Retroversion and Does a “Window of Opportunity” Exist for Its Development?

Currently, it is unknown how specific factors related to pitching volume and age affect the development of humeral retroversion in young throwers. If there is a “sweet spot” or safe zone of humeral retroversion that develops while skeletally immature, it would be beneficial to determine factors that would allow for optimal development of this adaptation. Recently, it has been suggested that too much throwing while young may induce excessive bony changes that can be harmful long term, and many groups recommend monitoring and limiting pitching in young athletes.²⁶

Similarly, it is logical to conclude that there is likely a “window of opportunity” that exists to develop this adaptation prior to skeletal maturity.⁸ Future studies may help elucidate what stage of skeletal development is the most susceptible to rotational remodeling by forces created during throwing and what level of overhead activity is necessary to induce this remodeling.⁴⁶ This information could help guide injury prevention standards and improve pitch count or age restriction recommendations.

Is Humeral Retroversion Protective Against Injury?

Currently, it is not clear where the optimal range of adaptive humeral retroversion lies in the throwing athlete, and perhaps the relative side-to-side differences in humeral retroversion may be more important than the overall degree or magnitude of retroversion positioning.^{25,40} Similarly, the effect that humeral retroversion has on the degree of available shoulder ROM may play a very important role in terms of likelihood of injury and should be considered for optimal treatment of throwing athletes.^{17,26} Although several studies have demonstrated that young throwers exhibit a pattern of increased GER and decreased GIR,^{16,20,37} further research focused on the young athlete is needed to improve our understanding of the developmental process of humeral retroversion, its effects on shoulder range of motion, and the interplay between bony and soft tissue changes within these athletes. This information could lead to more informed clinical decision making and may help with injury prevention strategies by directing interventions toward the appropriate cause.

CONCLUSION

The throwing motion creates stressors that result in altered bony and soft tissue anatomy of the throwing shoulder. Since these anatomic adaptations are likely occurring while skeletally immature, it is important to determine the influence increased throwing activity has on these young shoulders and how bony alterations may impact injury potential as a youth, and later on as an adult, throwing athlete.

ACKNOWLEDGMENT

We would like to thank Mikelle Hicks for her assistance with the artwork within this article.

REFERENCES

1. Anz AW, Bushnell BD, Griffin LP, Noonan TJ, Torry MR, Hawkins RJ. Correlation of torque and elbow injury in professional baseball pitchers. *Am J Sports Med.* 2010;38:1368-1374.
2. Bailey AJ, Paul RG, Knott L. Mechanisms of maturation and ageing of collagen. *Mech Ageing Dev.* 1998;106:1-56.
3. Bailey LB, Beattie PF, Shanley E, Seitz AL, Thigpen CA. Current rehabilitation applications for shoulder ultrasound imaging. *J Orthop Sports Phys Ther.* 2015;45:394-405.
4. Bigliani LU, Codd TP, Connor PM, Levine WN, Littlefield MA, Hershen SJ. Shoulder motion and laxity in the professional baseball player. *Am J Sports Med.* 1997;25:609-613.
5. Burkhart SS, Morgan CD, Kibler WB. The disabled throwing shoulder: spectrum of pathology. Part I: pathoanatomy and biomechanics. *Arthroscopy.* 2003;19:404-420.
6. Carter DR. Mechanical loading history and skeletal biology. *J Biomech.* 1987;20:1095-1109.
7. Chant CB, Litchfield R, Griffin S, Thain LM. Humeral head retroversion in competitive baseball players and its relationship to glenohumeral rotation range of motion. *J Orthop Sports Phys Ther.* 2007;37:514-520.
8. Crockett HC, Gross LB, Wilk KE, et al. Osseous adaptation and range of motion at the glenohumeral joint in professional baseball pitchers. *Am J Sports Med.* 2002;30:20-26.
9. Dillman CJ, Fleisig GS, Andrews JR. Biomechanics of pitching with emphasis upon shoulder kinematics. *J Orthop Sports Phys Ther.* 1993;18:402-408.

10. Edelson G. The development of humeral head retroversion. *J Shoulder Elbow Surg.* 2000;9:316-318.
11. Edelson G. Variations in the retroversion of the humeral head. *J Shoulder Elbow Surg.* 1999;8:142-145.
12. Ellenbecker TS, Roetert EP, Bailie DS, Davies GJ, Brown SW. Glenohumeral joint total rotation range of motion in elite tennis players and baseball pitchers. *Med Sci Sports Exerc.* 2002;34:2052-2056.
13. Feuerherd R, Sutherland MA, Hart JM, Saliba SA. Reliability of and the relationship between ultrasound measurement and three clinical assessments of humeral torsion. *Int J Sports Phys Ther.* 2014;9:938-947.
14. Fleisig GS, Andrews JR, Dillman CJ, Escamilla RF. Kinetics of baseball pitching with implications about injury mechanisms. *Am J Sports Med.* 1995;23:233-239.
15. Hibberd EE, Oyama S, Myers JB. Increase in humeral retroversion accounts for age-related increase in glenohumeral internal rotation deficit in youth and adolescent baseball players. *Am J Sports Med.* 2014;42:851-858.
16. Hurd WJ, Kaplan KM, ElAttrache NS, Jobe FW, Morrey BF, Kaufman KR. A profile of glenohumeral internal and external rotation motion in the uninjured high school baseball pitcher, part II: strength. *J Athl Train.* 2011;46:289-295.
17. Kibler WB, Kuhn JE, Wilk K, et al. The disabled throwing shoulder: spectrum of pathology-10-year update. *Arthroscopy.* 2013;29:141-161.e26.
18. Kocher MS, Waters PM, Micheli LJ. Upper extremity injuries in the paediatric athlete. *Sports Med.* 2000;30:117-135.
19. Krahl VE. The torsion of the humerus; its localization, cause and duration in man. *Am J Anat.* 1947;80:275-319.
20. Levine WN, Brandon ML, Stein BS, Gardner TR, Bigliani LU, Ahmad CS. Shoulder adaptive changes in youth baseball players. *J Shoulder Elbow Surg.* 2006;15:562-566.
21. Matsumura N, Ogawa K, Kobayashi S, et al. Morphologic features of humeral head and glenoid version in the normal glenohumeral joint. *J Shoulder Elbow Surg.* 2014;23:1724-1730.
22. Meister K. Injuries to the shoulder in the throwing athlete. Part one: biomechanics/pathophysiology/classification of injury. *Am J Sports Med.* 2000;28:265-275.
23. Meister K. Injuries to the shoulder in the throwing athlete. Part two: evaluation/treatment. *Am J Sports Med.* 2000;28:587-601.
24. Myers JB, Oyama S, Goerger BM, Rucinski TJ, Blackburn JT, Creighton RA. Influence of humeral torsion on interpretation of posterior shoulder tightness measures in overhead athletes. *Clin J Sport Med.* 2009;19:366-371.
25. Myers JB, Oyama S, Rucinski TJ, Creighton RA. Humeral retroversion in collegiate baseball pitchers with throwing-related upper extremity injury history. *Sports Health.* 2011;3:383-389.
26. Noonan TJ, Shanley E, Bailey LB, et al. Professional pitchers with glenohumeral internal rotation deficit (GIRD) display greater humeral retroversion than pitchers without GIRD. *Am J Sports Med.* 2015;43:1448-1454.
27. Osbahr DC, Cannon DL, Speer KP. Retroversion of the humerus in the throwing shoulder of college baseball pitchers. *Am J Sports Med.* 2002;30:347-353.
28. Pieper HG. Humeral torsion in the throwing arm of handball players. *Am J Sports Med.* 1998;26:247-253.
29. Polster JM, Bullen J, Obuchowski NA, Bryan JA, Soloff L, Schickendantz MS. Relationship between humeral torsion and injury in professional baseball pitchers. *Am J Sports Med.* 2013;41:2015-2021.
30. Reagan KM, Meister K, Horodyski MB, Werner DW, Carruthers C, Wilk K. Humeral retroversion and its relationship to glenohumeral rotation in the shoulder of college baseball players. *Am J Sports Med.* 2002;30:354-360.
31. Roach NT, Lieberman DE, Gill TJ 4th, Palmer WE, Gill TJ 3rd. The effect of humeral torsion on rotational range of motion in the shoulder and throwing performance. *J Anat.* 2012;220:293-301.
32. Sabick MB, Kim YK, Torry MR, Keims MA, Hawkins RJ. Biomechanics of the shoulder in youth baseball pitchers: implications for the development of proximal humeral epiphysiolysis and humeral retroversion. *Am J Sports Med.* 2005;33:1716-1722.
33. Sciascia A, Kibler WB. The pediatric overhead athlete: what is the real problem? *Clin J Sport Med.* 2006;16:471-477.
34. Shanley E, Rauh MJ, Michener LA, Ellenbecker TS, Garrison JC, Thigpen CA. Shoulder range of motion measures as risk factors for shoulder and elbow injuries in high school softball and baseball players. *Am J Sports Med.* 2011;39:1997-2006.
35. Shanley E, Thigpen CA, Clark JC, et al. Changes in passive range of motion and development of glenohumeral internal rotation deficit (GIRD) in the professional pitching shoulder between spring training in two consecutive years. *J Shoulder Elbow Surg.* 2012;21:1605-1612.
36. Thomas SJ, Swanik CB, Kaminski TW, et al. Humeral retroversion and its association with posterior capsule thickness in collegiate baseball players. *J Shoulder Elbow Surg.* 2012;21:910-916.
37. Trakis JE, McHugh MP, Caracciolo PA, Busciacco L, Mullaney M, Nicholas SJ. Muscle strength and range of motion in adolescent pitchers with throwing-related pain: implications for injury prevention. *Am J Sports Med.* 2008;36:2173-2178.
38. Weber AE, Kontaxis A, O'Brien SJ, Bedi A. The biomechanics of throwing: simplified and cogent. *Sports Med Arthrosc Rev.* 2014;22:72-79.
39. Whiteley R, Ginn K, Nicholson L, Adams R. Indirect ultrasound measurement of humeral torsion in adolescent baseball players and non-athletic adults: reliability and significance. *J Sci Med Sport.* 2006;9:310-318.
40. Whiteley RJ, Adams RD, Nicholson LL, Ginn KA. Reduced humeral torsion predicts throwing-related injury in adolescent baseballers. *J Sci Med Sport.* 2010;13:392-396.
41. Whiteley RJ, Ginn KA, Nicholson LL, Adams RD. Sports participation and humeral torsion. *J Orthop Sports Phys Ther.* 2009;39:256-263.
42. Wilk KE, Macrina LC, Fleisig GS, et al. Correlation of glenohumeral internal rotation deficit and total rotational motion to shoulder injuries in professional baseball pitchers. *Am J Sports Med.* 2011;39:329-335.
43. Wilk KE, Meister K, Andrews JR. Current concepts in the rehabilitation of the overhead throwing athlete. *Am J Sports Med.* 2002;30:136-151.
44. Wilk KE, Obma P, Simpson CD, Cain EL, Dugas JR, Andrews JR. Shoulder injuries in the overhead athlete. *J Orthop Sports Phys Ther.* 2009;39:38-54.
45. Wyland DJ, Pill SG, Shanley E, et al. Bony adaptation of the proximal humerus and glenoid correlate within the throwing shoulder of professional baseball pitchers. *Am J Sports Med.* 2012;40:1858-1862.
46. Yamamoto N, Itoi E, Minagawa H, et al. Why is the humeral retroversion of throwing athletes greater in dominant shoulders than in nondominant shoulders? *J Shoulder Elbow Surg.* 2006;15:571-575.

For reprints and permission queries, please visit SAGE's Web site at <http://www.sagepub.com/journalsPermissions.nav>.