

Correction

Correction: González-Rellán et al. Anatomy of the Palmar Region of the Carpus of the Dog. *Animals* 2022, 12, 1573

Sonia González-Rellán ^{1,*}, Andrés Barreiro ^{1,2}, José Manuel Cifuentes ¹ and Patricia Fdz-de-Trocóniz ¹

¹ Department of Anatomy, Animal Production and Clinical Veterinary Science, University of Santiago de Compostela, 27002 Lugo, Spain

² Rof Codina Veterinary University Hospital, 27002 Lugo, Spain

* Correspondence: sonia.gonzalez.rellan@gmail.com

Error in Figure

In the original publication [1], there was a mistake in Figure 3. In response to a suggestion from one of the reviewers (point 6 of Reviewer #2), the authors modified some figures to add a schematic drawing. After the publication of the article, the authors realized that, in Figure 3, this modification changed the placement of some arrows. We have corrected it, and now, the arrows point to the right structures (as it was initially, before the modification). The corrected Figure 3 appears below. The authors apologize for any inconvenience caused and state that the scientific conclusions are unaffected. This correction was approved by the Academic Editor. The original publication has also been updated.



Citation: González-Rellán, S.; Barreiro, A.; Cifuentes, J.M.; Fdz-de-Trocóniz, P. Correction: González-Rellán et al. Anatomy of the Palmar Region of the Carpus of the Dog. *Animals* 2022, 12, 1573. *Animals* 2022, 12, 2019. <https://doi.org/10.3390/ani12162019>

Received: 3 August 2022

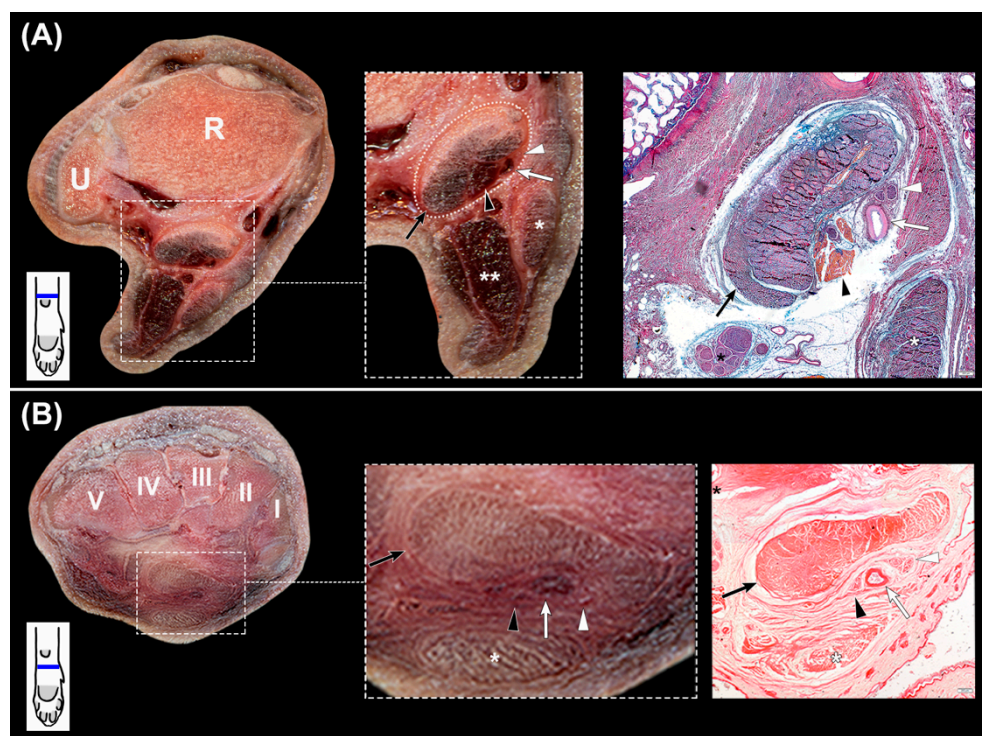
Accepted: 4 August 2022

Published: 10 August 2022

Publisher's Note: MDPI stays neutral with regard to jurisdictional claims in published maps and institutional affiliations.



Copyright: © 2022 by the authors. Licensee MDPI, Basel, Switzerland. This article is an open access article distributed under the terms and conditions of the Creative Commons Attribution (CC BY) license (<https://creativecommons.org/licenses/by/4.0/>).



Reference

1. González-Rellán, S.; Barreiro, A.; Cifuentes, J.M.; Fdz-de-Trocóniz, P. Anatomy of the Palmar Region of the Carpus of the Dog. *Animals* 2022, 12, 1573. [[CrossRef](#)] [[PubMed](#)]