JOURNAL OF THE
ANUS, RECTUM AND COLON
dx.doi.org/10.23922/jarc.2021-075
http://journal-arc.jp

Review Article

A Retrospective Critique of the Various Sphincter-preserving Surgical Procedures for Ischiorectal Fistula

Yoriyuki Tsuji, Shota Takano, Kazutaka Yamada and Masahiro Takano

Coloproctology Center Takano Hospital, Kumamoto, Japan

Abstract

In the 1950s, the cause of anal fistulas was identified as an infection of the anal gland (cryptoglandular infection theory). Thereafter, treatment for this disorder began in the 1960s with the lay-open procedure, which involved incising the sphincter and the fistula tract. However, it was found that too much invasion into the sphincter could result in postoperative fecal incontinence. Thus, to reduce such risk, sphincter-preserving surgery was applied for superficial anal fistula in 1961 and for deep anal fistula (ischiorectal fistula) in 1965. Over the years, more effective sphincter-preserving procedures for ischiorectal fistula have been developed to improve the quality of life of the patient. In this review article, we aim to first introduce the basic surgical techniques for ischiorectal fistula. We will discuss the anatomy of the anus and the pathogenesis of ischiorectal fistula and will provide some diagnostic methods. Representative sphincter-preserving procedures that have been performed for ischiorectal fistula since 1965 will also be categorized and outlined chronologically. The discussion will look at the following techniques for ischiorectal fistula and outline the advantages and disadvantages of each procedure so that they can be used as a reference for ischiorectal fistula surgery in the future: the lay-open procedure (fistulotomy and fistulectomy), the Hanley procedure (first partial sphincter-preserving procedure), the muscle-filling procedure, the Moriya method and Ui method (modified partial sphincter-preserving procedure), the Takano method and the sphincter-preserving lateral procedure (complete sphincter-preserving procedure), the seton method (a cross between the lay-open procedure and sphincter-preserving procedure), and the overseas sphincter-preserving procedure.

Keywords

anal fistula, sphincter-preserving procedure, lay-open procedure, seton method, anal manometry

J Anus Rectum Colon 2022; 6(2): 100-112

1. Introduction

Anal fistula has been found to be commonly caused by an infection of the anal glands[1]. With the introduction of the lay-open procedure in which the lesion is either incised or excised, the cure rate of this disorder has increased[2]. However, the average life expectancy for both men and women in our present society is well over 80 years of age. Therefore, even if a patient underwent lay-open surgery in their 40s or 50s and had no fecal incontinence at that time, there is still a possibility that they will experience fecal incontinence in the future[3]. Treatment of anal fistula is of course deemed essential, but preserving anal function is also extremely important. Care must be taken, especially when choosing the optimal surgical procedure for deep anal fistulas. When the lay open procedure is performed, there is a possibility that the internal sphincter, subcutaneous, superficial, deep external sphincters, and, in some cases, the levator

Corresponding author: Yoriyuki Tsuji, yorituji@yahoo.co.jp
Received: November 10, 2021, Accepted: January 6, 2022

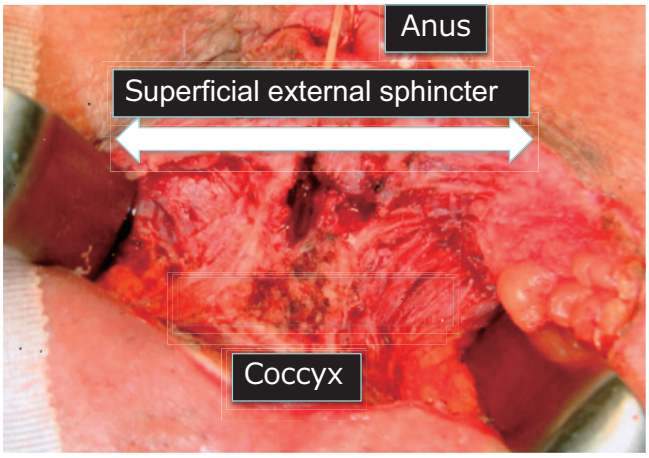

Figure 1. Anatomy of the posterior anus. Dissection of the posterior part of the anus. The spindle-shaped fascia of the left and right sides of the superficial external sphincter, which is quite wide, surrounds the anus and is attached to the coccyx as a ligament by the fusion of the left and right sides of the superficial external sphincters.
The superficial external sphincter is thought to play a major role in anal sphincter function; thus, invasion of the superficial external sphincter should be minimized when performing surgery for anal fistulas. (Adapted from Tsuji Y, Takano S, Nakamura Y, et al. Efficacy of the sphincter-preserving lateral procedure with an incision on the superficial part of the external anal sphincter for ischiorectal fistula. Surgery. 2018; 80 (13): 1335-42. Permitted by Nankodo Co.,Ltd).

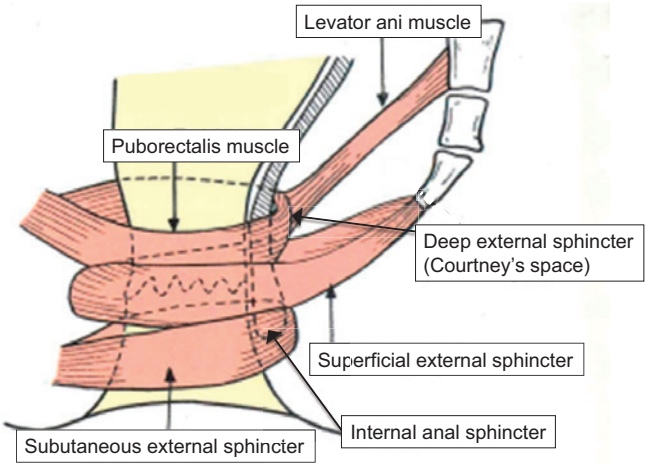

Figure 2. Anatomy of the posterior anus. (Adapted from Iwadare J. Practice in anorectal diseases for proctologists. 1st ed. Osaka (Japan): Nagai Shoten Co., Ltd; 2000. Anatomy and physiology of the anal canal; p. 17-30. Japanese. Permitted by Nagai Shoten Co., Ltd and Kurokawa A.).

ani muscles could be severed, which, in turn, may result in postoperative fecal incontinence[4]. Therefore, in this review article, we will focus on the sphincter-preserving surgical procedure for ischiorectal fistula (type III fistula), which is a deep anal fistula with a high rate of frequency (8%-23%)[5,6].

2. Anatomy of the Posterior Anus

Figure 1 is an image of the anal region of the postoperative Fournier's syndrome. In this photograph, a part of the subcutaneous external sphincter, the superficial posterior portion, a part of the internal sphincter, and the coccyx can be seen. The spindle-shaped muscle fascicles of the left and right sides of the superficial external sphincter, which are quite wide, thick, and strong, surround the anus and are attached to the coccyx as a ligament by the fusion of the left and right sides of the superficial external sphincter, posteriorly. Therefore, the superficial external sphincter is thought to play a major role in the sphincter function of the anus, and invasion of the superficial external sphincter should be minimized when conducting surgery for anal fistula. Also, the levator ani muscle and the deep external sphincter are out of the field of view and are covered with other muscle tissues. These muscles are known to play an important function in lifting the rectum anteriorly and form the anorectal angle. The puborectalis and the deep external sphincter originate near the symphysis pubis and form a U-shaped muscular sling around and behind the rectum, and the posterior side is attached to the sacral region (Figure 2)[7]. In general, the puborectalis is thought to be a thick muscle fascicle, but some reports suggest that it is tendinous[8].

3. The Pathogenesis of Ischiorectal Fistulas

An analysis of 57 cases of ischiorectal lesions (36 abscesses and 21 fistulas) was conducted using anal ultrasound in 1991, and the progression of the ischiorectal abscesses and fistulas was reported[9]. In general, the developmental pattern of an ischiorectal fistula is clear at the time of abscess, but when the lesion progresses into a fistula, the lesion is resorbed and shrinks, which makes a detailed analysis difficult. Therefore, the analysis was conducted primarily on cases of ischiorectal abscesses.

An analysis of the images revealed that most cases of ischiorectal abscesses begin as an abscess between the internal and deep external sphincters posterior to the anus (intermediate abscess), which then penetrates the deep external sphincter and develops into a lesion space surrounded on the left and right by the external sphincter and above by the levator ani muscle (Figure 3, 4). The left and right sides of the superficial external sphincter are then fused in a person without anorectal disease, but in cases where there is an ischiorectal abscess, the space between the left and right sides of the superficial external sphincter opens. Thus, when bacterial infection occurs in the anal crypt located posterior to

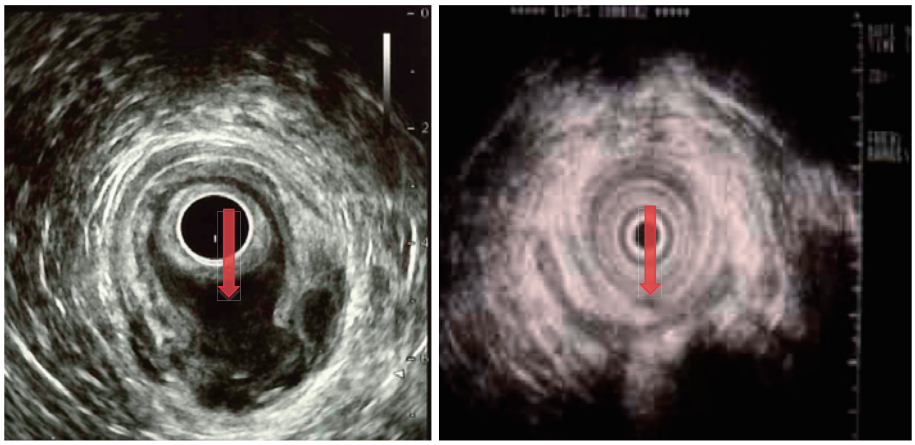

Figure 3. Intermediate abscess/fistula between the internal and deep external sphincters. There is always an arrow-shaped lesion (intermediate lesion) in the development of an ischiorectal abscess and an ischiorectal fistula.

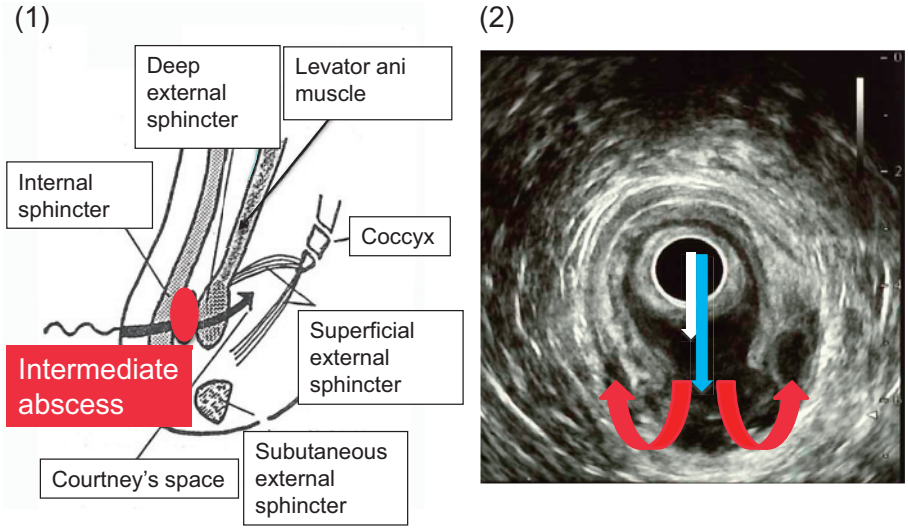

Figure 4. The pathogenesis of ischiorectal abscesses/fistulas. (1) When bacterial infection occurs in the posterior anal crypt, intermuscular abscesses (intermediate abscesses) occur between the internal sphincter and the deep external sphincter, with the deep external sphincter acting as a bulwark. (Cited Tsuji Y, Fujiyoshi T, Takagi K, et al. Study on the pathogenesis of ischiorectal abscess and fistula viewed from the standpoint of transanal ultrasonic examination. J Jpn Soc Coloproctol. 1991; 44 (2): 146-52. Permitted by the Japan Society of Coloproctology). (2) As the disease becomes more active, it may extend further back into the Courtney's space and even into the ischiorectal fossa. The result is an ischiorectal abscess and an ischiorectal fistula.

the anus, an intermuscular abscess (intermediate abscess) develops between the internal sphincter and the deep external sphincter, with the deep external sphincter acting as a bulwark. In some cases, the pressure to extend posteriorly is high, and the abscess penetrates the deep external sphincter and extends into the Courtney's space and further proceeds into the right and left ischiorectal fossa, resulting in an ischiorectal abscess (Figure 4). The abscess then gradually resorbs, resulting in a unilateral or horseshoe-shaped ischiorectal fistula. The intermediate abscess described above also shrinks posteriorly to form an ischiorectal fistula as well[9].

Kurihara et al. (2006) reported on the surgical findings of 320 cases of posterior deep complex fistulas, 30 cases of

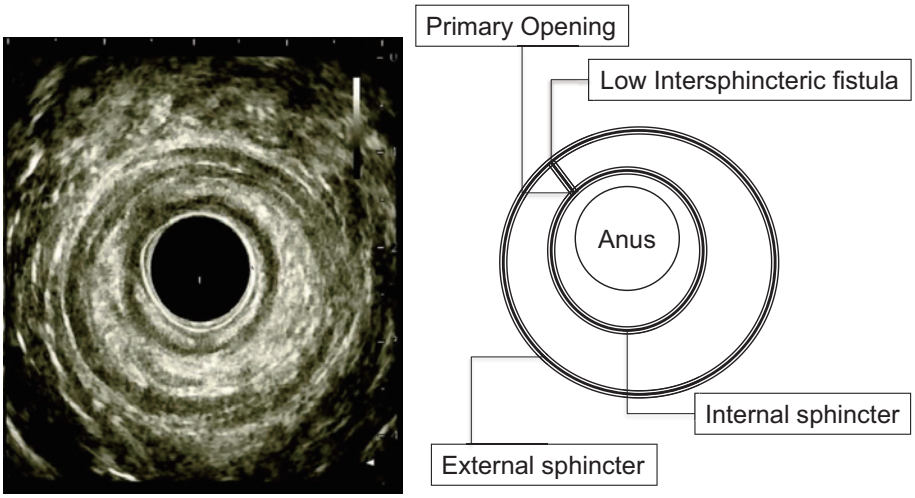

Figure 5. Diagnosis of the primary opening using anal ultrasound. A low intersphincteric fistula (IILS) and the primary opening (PO) at 10 o'clock (Adapted from Tsuji Y, Nakamura Y, Ogata S, et al. Recommended treatment for ischiorectal and supralevator fistula. J Jpn Soc Coloproctol. 2013; 66 (10): 1044-58. Permitted by the Japan Society of Coloproctology).

preoperative magnetic resonance imaging (MRI), and 2 cases of cadaver dissections. As per their findings, it was determined that the primary opening (PO) of posterior complex fistulas originates and develops from a bacterial infection in the anal crypt at 6 o'clock and proceeds into the posterior deep space, which is a region surrounded above by the internal sphincter, below by the deep external sphincter, and laterally by the anterior surface of the superficial external sphincter. In addition, due to the raised abscess pressure, the lesion may extend into the ischiorectal fossa, resulting in the development of an anal fistula[8].

Tsuji et al. (1991) had similar findings[9], but the difference seems to be due to the difference in the observed cases, as explained at the beginning of this section. A detailed analysis of the progression of the disease is difficult unless the abscess is in the acute stage.

Kagawa et al. (2008) examined preoperative MRI images of 65 cases of ischiorectal fistula and 10 cases of supralevator fistula and found that all primary abscesses were located in the posterior external sphincter or the intersphincteric space, often at the level of the deep external sphincter. In their report they discuss in detail the course of a fistula from the primary lesion[10].

4. Diagnostic Methods

The diagnosis of an ischiorectal fistula is done by conducting a digital examination, an anal ultrasound, and an MRI[10-13].

(1) *Digital examination*

The most important examination in the diagnosis of an anal fistula is a digital examination. It is important as a preoperative diagnosis and as an intraoperative assessment of the extent of the lesion; it is also vital for determining the extent of excision, so mastery of digital examination is essential for specialists[11]. In ischiorectal and supralevator fistulas, a broad induration from the puborectalis to the ischiorectal fossa, which is caused by the spread of inflammation from the lesion to the surrounding region, is palpable[6].

(2) *Anal ultrasound*

A probe fitted with an ultrasound device is inserted transanally, and an examination of the anal region is conducted. It is useful in identifying the presence or absence of an anal fistula, the type and course of the fistula, the location of the PO, the connection of the fistula to the sphincter, and the differential diagnosis of the ischiorectal lesions (Figure 5)[12]. There are various kinds of ischiorectal fistulas, such as fistulas existing only in the Courtney's space, running from the posterior region to the external sphincter in the ischiorectal fossa on one side or on both sides in the shape of a horseshoe[9]. The accuracy rate for the detection of ischiorectal fistulas using anal ultrasound has been reported to be about 89.5%[13]. A radial anal ultrasound has a high and accurate detection rate for ischiorectal fistulas, but a low detection rate for supralevator fistulas because the rectum is bent anteriorly by the puborectalis, making it difficult to see the posterior portion of the anus, and the probe cannot at-

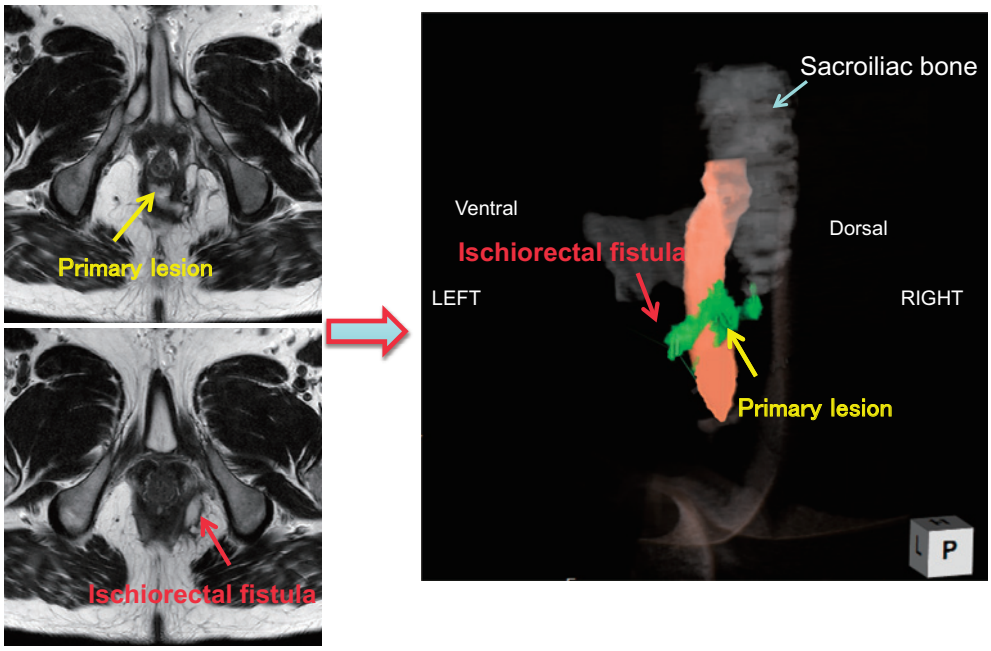

Figure 6. 3D-MRI image processing. Image processing to create 3D MRI images (Adapted from Tsuji Y, Yamada K, Takano M. The sphincter-preserving procedure using three-dimensional magnetic resonance imaging for the treatment of ischiorectal fistula. Surgery. 2021; 83 (5): 541-9. Permitted by Nankodo Co.,Ltd).

Figure 7. MRI image of the levator ani muscle and an ischiorectal fistula. An MRI scan revealed a fistula in the ischiorectal fossa below the inverse c-shaped levator ani muscle (Red arrow: levator ani muscle; Yellow arrow: Ischiorectal fistula). (Adapted from Tsuji Y, Yamada K, Takano M. The sphincter-preserving procedure using three-dimensional magnetic resonance imaging for the treatment of ischiorectal fistula. Surgery. 2021; 83 (5): 541-9. Permitted by Nankodo Co.,Ltd).

tach vertically to the lesion. An MRI is more appropriate for detecting supralevator fistulas[5].

(3) *MRI*

The abscess area within the ischiorectal fistula is detected using a high signal on fat-suppressed T2-weighted images, and fat and muscle tissues are imaged with a low signal. The difference in signals is used to create an MRI image. In addition, the fat-suppressed T2-weighted imagery taken with a slice thickness of 5 mm is interpolated and reconstructed at the image processing workstation to create an image with a thin slice thickness of about 0.5 mm and then interpolated and reconstructed in all three directions of transverse, sagittal, and coronal sections to create a three-dimensional image (Figure 6)[11]. It is possible to perform multiple fusions of any part of the body and to observe anatomical structures from any direction using MRI imaging, making it very useful in conducting detailed examinations and diagnosis. By imaging transverse and coronal sections perpendicular or parallel to the anal canal, it is possible to obtain concentric transverse images of the anal canal and observe the PO and the space between the internal and external sphincter and to detect the presence of intersphincteric anal fistulas. For deep anal fistulas, the coronal T2-weighted image of the coronal section parallel to the anal canal clearly shows the levator ani muscle in the shape of a "V", making it possible to detect ischiorectal and supralevator fistulas by observing the same region (Figure 7)[11]. Yamana et al. (2002) reported

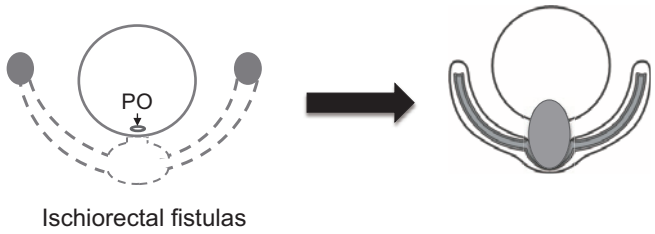

Figure 8. Lay-open procedure for ischiorectal fistulas. The entire tract is laid open from the primary opening to the secondary opening.

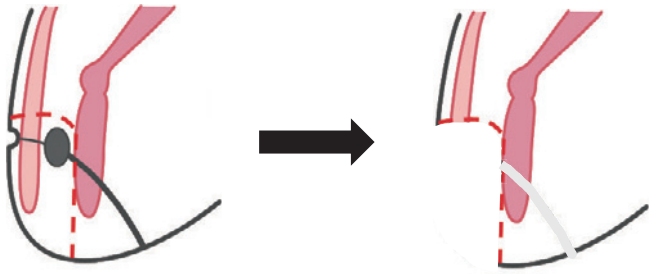

Figure 9. Parks procedure. The primary opening and primary lesion are excised by resecting the anoderm and internal sphincter, and the peripheral fistula tract is cored out from the secondary opening.

that the MRI findings and surgical results were consistent in 42 out of 54 cases (78%) of deep anal fistula[14].

5. History of the Sphincter-preserving Procedure for Ischiorectal Fistulas

(1) *Progress of the lay-open procedure for ischiorectal fistulas*

Studies in the 1950s revealed that anal fistulas were commonly caused by anal gland infections[1]. This led to the development of the lay-open procedure in which the fistula tract is incised from the PO, increasing the cure rate[2]. Up until the early 1960s, ischiorectal fistulas were treated with the total lay-open procedure, similar to how intersphincteric fistulas were treated. According to Sumikoshi (1973), if there is a secondary opening (SO), a grooved probe is inserted through the SO, and an incision is made[2]. The granulation tissue, if present, is scraped off using a sharp curet. Once the track of the fistula tract is identified, a probe or bent Lister forceps are inserted in the same way to incise the deep fistula tract. The incision is extended if the fistula goes beyond the posterior midline to the other side. A part of the fistula tract wall near the midline is then examined to find the fistula tract that leads into the anal canal, and a grooved probe is inserted into it to open it up to the PO, and then the entire fistula tract is laid open (Figure 8). However, it is reported that rectal deformity may occur if the entire fistula tract is laid open at the primary stage[2]. This is because the fistulas extend into the intersphincteric space and the deeper and more complex the fistulas are, the more likely the lay-open procedure will result in an anorectal deformation and sphincter dysfunction and the more likely that postoperative incontinence will occur[4]. The most serious adverse effect after performing the lay-open procedure is incontinence. Matsuda et al. (1996) administered a postoperative questionnaire to measure the adverse effects of low intersphincteric fistula surgery (including anterolateral fistula) and found that incontinence of flatus occurred in 30% of the cases and that sticking, minor soiling, and anal pain occurred in 13% of the cases[15]. Hyman et al. (2009) reported that major incontinence was observed in 13% of the cases, but that the cure rate was higher than that of the sphincter-preserving procedure[16]. Therefore, Yago (2013) recommends conducting a preoperative evaluation of anorectal function if there is a preoperative risk of soiling and that a detailed interview and evaluation of anorectal function by anal manometry and ultrasound should be considered[17].

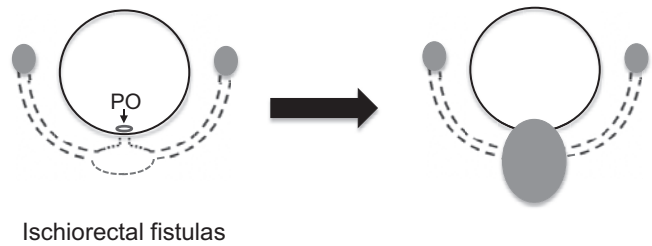

Figure 10. Modified Hanley procedure. Lay-open procedure is conducted from the primary opening to the Courtney's space. The secondary openings are incised and curetted.

(2) *Introduction of the partial sphincter-preserving procedure for ischiorectal fistulas*

The first sphincter-preserving technique for anal fistulas was developed by Parks in 1961. He performed the sphincter-preserving procedure instead of the lay-open procedure for superficial anal fistulas[18]. In this procedure, the PO and primary lesion are excised by resecting the anoderm and internal sphincter, and the peripheral fistula tract is cored out from the SO (Figure 9). This is not a complete sphincter-preserving procedure because the internal sphincter is resected, but it does reduce the frequency of anal deformity. This procedure was introduced to Japan by Sumikoshi (1973) was and further developed by Takano (1976) and Iwadare (1983)[2,19,20]. The same concept was later applied for ischiorectal fistulas, and in 1965, Hanley reported on a sphincter-preserving technique for ischiorectal fistulas (Figure 10)[21]. It was the first operation to incorporate the idea of preserving the sphincter and was performed based on the pathogenesis of ischiorectal fistulas. Most ischiorectal

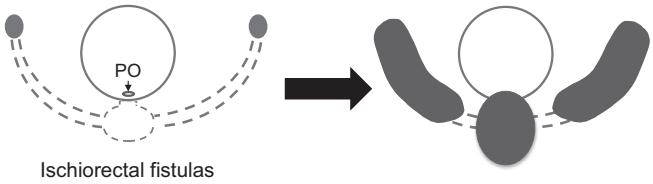

Figure 11. Goligher procedure. For horseshoe-shaped ischiorectal fistulas, the bilateral fistulas are exposed through a full incision, the posterior communicating tracts are curetted, and the fistula tract to the PO is excised from the crypt to the internal sphincter muscle.

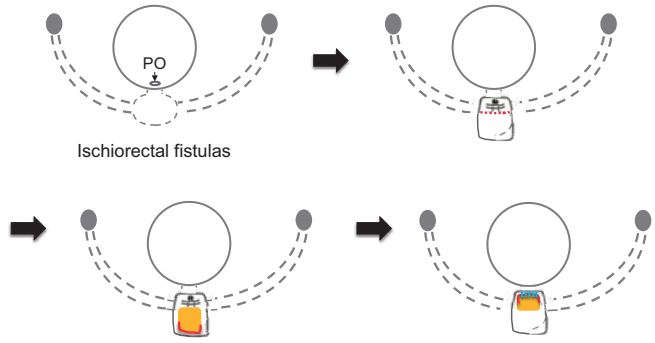

Figure 12. Muscle filling procedure. After resecting the mucosa, an arc-shaped incision is made outside the internal and external sphincters; then, an incision to a depth of just below the puborectalis is made with minimal invasion into the sphincter, and the primary lesion is resected. After the removal of the primary lesion, the recess is filled with a caulescent muscle flap from the posterior lateral side.

fistulas have a PO in the posterior crypt and an abscess in the Courtney's space that spreads to the ischiorectal fossa. In other words, the primary abscess is in the Courtney's space as Parks previously described, so it is necessary to lay open from the PO to the Courtney's space to treat the primary abscess. Hanley's surgery, which clinically applies this concept, was a significant breakthrough in the surgical treatment of ischiorectal anal fistulas[4]. In this procedure, an incision is made from the PO on the posterior midline via the primary lesion to the muscles attached to the coccyx, and the internal and external sphincters are then completely opened (including the deep portion). The fistula tract extending from the posterior to the lateral is drained by excision and curettage around the SO. This technique has improved the curability of deep anal fistulas and is still used today[6,8]. It is as low as the recurrence rate for the lay-open procedure for subcutaneous and low intersphincteric fistulas[22]. However, postoperative incontinence may occur in elderly patients with preoperatively insufficient anorectal pressure, in patients with grand multipara, and in postoperative patients with anorectal diseases[17,23].

Goligher (1970) developed a procedure that combined the advantages of the Parks procedure and the Hanley procedure. This procedure was specifically designed for horseshoe-shaped ischiorectal fistulas. The bilateral fistulas are exposed through a full incision, the posterior communicating tracts are curetted, and the fistula tract to the PO is excised from the crypt to the internal sphincter muscle. The fistula tract, which communicates from the lateral fistula tract to the posterior midline is only curetted (Figure 11)[24]. However, this technique may result in postoperative residual induration for a considerably longer period of time[2].

(3) *Development of the partial sphincter-preserving procedure*

This section will cover the modified Hanley, Parks, and Goligher procedures.

Firstly, in the 1970s, Sumikoshi et al. reported on the modified Hanley technique in which the excised primary lesion from the laid open PO is filled with the surrounding muscle[2]. This technique was further developed in the 1980s and was renamed muscle-filling procedure by Iwadare and Kono[25,26]. This procedure was specifically designed so that the posterior PO of the ischiorectal fistula is treated by resecting the mucosa, and an arc-shaped incision is made outside the internal and external sphincters. Then, an incision to a depth of just below the puborectalis is made with minimal invasion into the sphincter, and the primary lesion is resected. After the removal of the primary lesion, the recess is filled with a caulescent muscle flap from the posterior lateral side (Figure 12)[25]. This technique is performed between the internal and external sphincters; therefore, sphincter invasion is minimized until the primary lesion is reached. This surgical procedure is still performed today and is a surgical procedure with a low recurrence rate and low anal dysfunction[27]. The recurrence rate for ischiorectal fistulas is about 1.5%-4.8%, and compared with the preoperative score, the resting anal pressure is significantly lower at 3 months after surgery, but it eventually returns to the normal range[6,28,29]. However, considering that the entire fistula is not visible, the range of excision is limited, and that a part of the sphincter is incised when the lesion in the ischiorectal fossa is treated or the muscle filling is made, further studies on the long-term prognosis and on the anal function of patients who underwent this procedure are needed.

Secondly, Moriya et al. (1980) published a report on the development of the Parks procedure for intersphincteric fistula[30]. This procedure involves coring out the entire fistula tract and was reportedly used in 80% of all ischiorectal fistula cases. However, there exist many complex cases of ischiorectal fistulas, thus raising many questions as to whether it is possible to core out the entire fistula tract without excessive invasion of the anal sphincter in 80% of the cases,

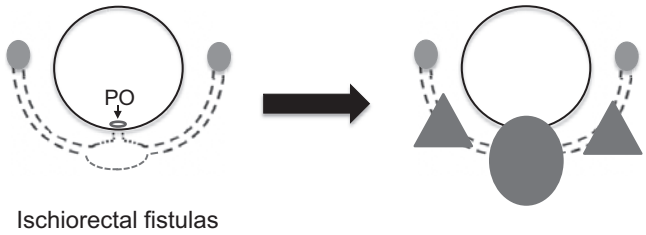

Figure 13. Ui method. The primary lesion is incised and laid open from the anus. For the fistula tract in the ischiorectal fossa, a triangular skin excision is made on both sides of the posterior anus, and then these are excised and curetted to make an open wound.

whether the PO should be laid open after excision, and whether the same region will close over time. Incidentally, the results of Moriya's follow-up for low intersphincteric fistulas showed a recurrence rate of 16%[20]. Matsuda et al. (1996) analyzed Moriya method for ischiorectal fistulas. In this procedure, the fistula tract is formed by draining the ischiorectal abscess, the fistula tract is cored out from the SO after a few months, and then the entire fistula tract is cored out from the PO side toward the Courtney's space. After that, drains are inserted into the left and right SO resected parts and fixed, and the PO resected parts are laid open in the early stage, but they eventually start to close. Then, the fistula lesion is filled with muscle to improve the cure rate. The recurrence rate is reported to be 8.6%[15].

The third method is the modified Parks and Goligher procedures; this was published by Ui in 1982. This procedure was specifically designed so that the primary lesion is incised along with the internal sphincter and laid open from the anal canal, similar to the Parks procedure. For the fistula tract in the ischiorectal fossa, a triangular skin excision is made on both sides of the posterior anus, and these are excised and curetted to make an open wound (Figure 13). One of the 14 cases experienced recurrence (7.1%), and the results of a questionnaire showed insufficient continence in 4 out 10 (40%) cases[31]. A disadvantage of this procedure and the Parks procedure is that the transsphincteric fistula and all the layers of the internal sphincter are excised. Also, there is a possibility of postoperative incontinence in patients with reduced anal tonus[17].

(4) *Introduction and development of the complete sphincter-preserving procedure*

Takano et al. (1985) published the Takano method, which further developed the Ui method[32]. In this procedure, instead of resecting all the layers of the internal sphincter in the PO, only the part where the fistula tract penetrates the internal sphincter is cored out and sutured closed to reduce invasion of the internal sphincter. The remaining fistula tract is then incised (excised) outside the sphincter and curetted (Figure 14)[33]. The Takano method is less invasive to the sphincter and less likely to cause postoperative sphincter insufficiency than the Ui method, and the recurrence rate is 10.5%[32]. Tsuji et al. (2009) analyzed the Takano method and found that the recurrence rate was 9.2% and that incontinence occurred in 7 out of 87 (8.0%) cases. There were two cases of incontinence of flatus and five cases of fecal incontinence due to diarrhea or soft stool, but these all stopped within 6 months after surgery[34].

Tsuji et al. (2013) modified the Takano method by making a lateral incision on the superficial part of the external anal sphincter muscle (lateral procedure)[35]. The incision is made from outside the superficial external sphincter; this method is now known as the sphincter-preserving procedure. This procedure was designed based on an observation using anal ultrasound for ischiorectal fistula as described by Tsuji in 1991[9]. This procedure is specifically designed to be performed from the lateral side of the superficial external sphincter. The fistula in the ischiorectal fossa, which occupies most of the fistula cavity, is cored out through an incision from the outside to the inside of the anus. The posterior ischiorectal fistula is excised, while traction using vascular tape is applied to the lesion; then, the PO is treated (Figure 15)[35]. The postoperative 24-month recurrence-free rate was 98% (Figure 16), and there was no significant difference between the preoperative and 24-month postoperative maximum resting pressure (MRP) measured using anal manometry (Figure 17)[36].

(5) *Seton method*

The recurrence rate of the sphincter-preserving procedure for ischiorectal anal fistula in Japan has been reported to be 1.5% to 9.2%[15,29,34]. Since the 1980s, the seton method was classified as radical treatment for deep anal fistula because of the poor results of this sphincter-preserving procedure[37,38]. According to Kurokawa et al. (2002), the basic idea of the seton method is to not open the fistula tract all at once, but to take time to open it with a rubber band or with medical wire. As the dissection gradually proceeds, the open wound heals, resulting in less dissection of muscle tissue and less functional impairment and recurrence. The recurrence rate of the seton method for deep anal fistula is 2.7% for ischiorectal fistula and 2.0% for minor incontinence of flatus[39]. However, from the perspective of maintaining anal function, the seton method eventually involves cutting all layers of the sphincter muscle, and if it is applied to cases with preoperatively reduced tonus, the possibility of postoperative incontinence will increase[17,40].

(6) *The overseas sphincter-preserving procedure*

In this section, the sphincter-preserving techniques performed overseas will be discussed.

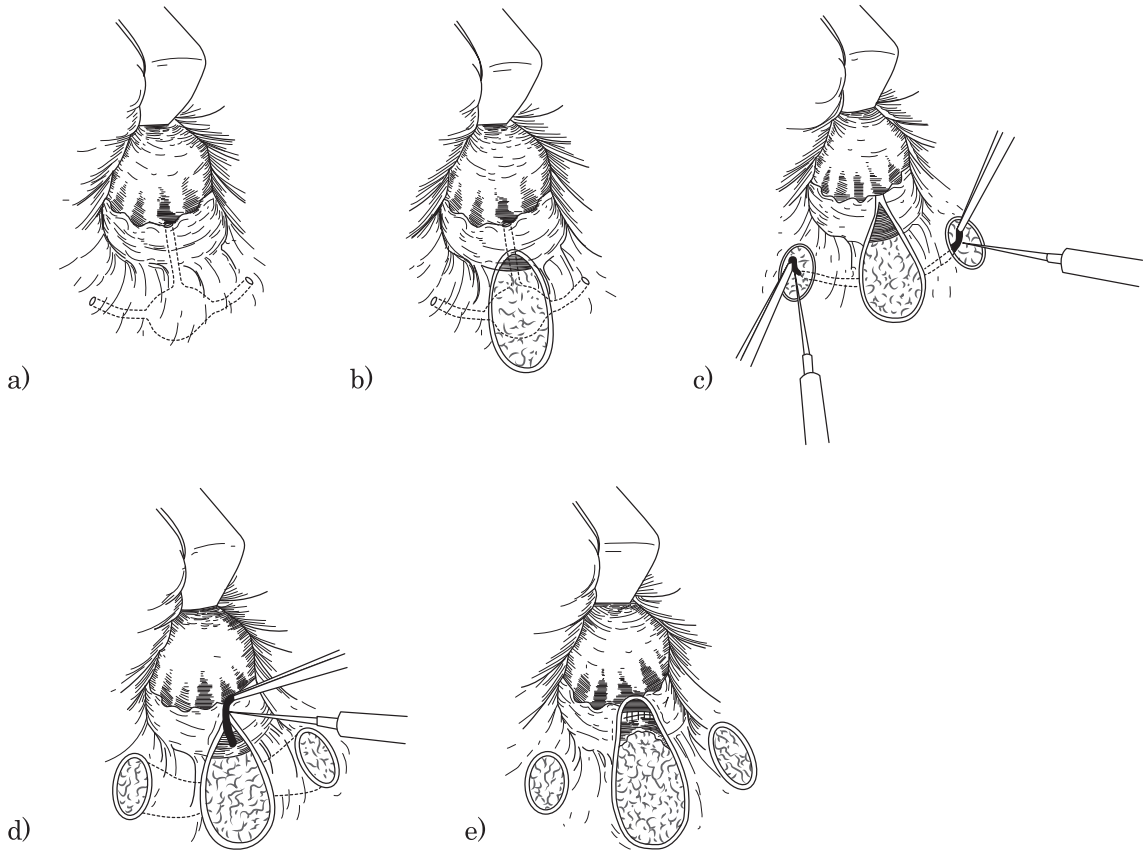

Figure 14. Takano method for deep anal fistulas. a: Check the spread of the lesion (unilateral or bilateral) by palpation. b: Incise the superficial external sphincter located at the posterior part of the anus and bluntly dissect it with a retractor to expose the Courtney's space. c: Curettage of the fistula wall and drain the pus with a sharp curet. If the fistula tract extends posteriorly on the unilateral or bilateral sides, the fistula tract can be grasped with Kocher forceps and dissected with a scalpel to the midline of the fistula tract or to the Courtney's space. d: Coring out and closure of the primary opening (PO). e: Suture and closure of the PO (Reprinted from Takano M, Tsuji Y. Practice in Anorectal Diseases by learning with explanations and videos of the surgical procedures. 1st. Tokyo (Japan): Nakayama Shoten Co., Ltd; 2007. Chapter 3, Perianal abscesses/fistulas; p 107-29. Japanese. Permitted by Nakayama Shoten Co., Ltd).

(a) Ligation of the intersphincteric fistula tract (LIFT) (Figure 18)

Rojanasakul et al. (2007) reported on the LIFT technique for sphincter preservation. This procedure is specifically designed so that the fistula tract is divided at the intersphincteric groove, ligated close to the internal sphincter, and isolated at the outer side. The outer fistula tract is then extracted from the intersphincteric space, and a sharp curet is inserted through the SO to curettage the inside of the fistula tract; the remaining anal glands are then removed. It is reported that this procedure can preserve anal function because it doesn't damage the sphincter and has a low recurrence rate. They performed LIFT on 13 transsphincteric fistula cases and on 5 horseshoe-shaped fistula cases and reported a non-healing rate of 6% and that no fecal incontinence occurred after a maximum follow-up period of 26 weeks[41]. Wallin et al. (2012) performed the LIFT method for transsphincteric fistulas and reported that the success rate for fistula healing was 40% after the first ligation, the number of LIFT retries was 47%, and the recurrence rate was 57%, including the additional fistulotomy after transition to intersphincteric fistulas, but anal function was maintained[42]. Abcarian et al. (2012) also performed the procedure for transsphincteric fistulas and reported a 74% cure rate with no fecal incontinence at a mean follow-up period of 18 weeks[43]. Moreover, Sada et al. (2013) performed the procedure on low intersphincteric fistulas and reported a cure rate of 93.8%, with no significant preoperative and postoperative difference in MRP or maximum squeeze pressure (MSP)[44]. The LIFT method is not a problem for small, thin anal fistulas due to the small drainage wound, but for cases that require large drainage (i.e., ischiorectal fistula), it remains unclear whether it will heal[17].

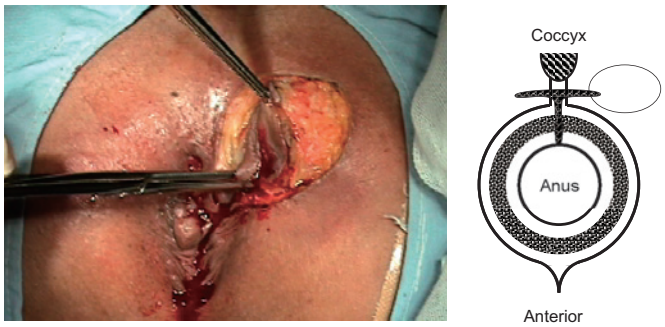

Figure 15-1. The sphincter-preserving lateral procedure (Step 1). A skin incision is made outside the superficial external sphincter from the 7 o'clock position.

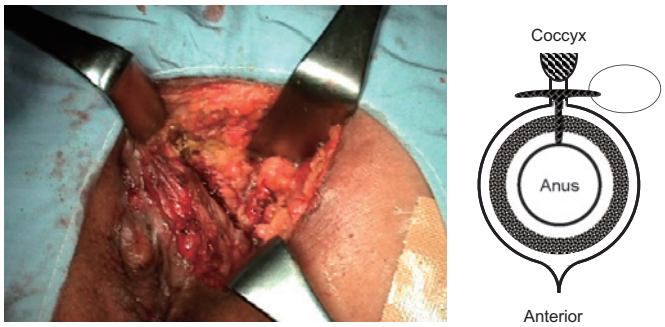

Figure 15-2. The sphincter-preserving lateral procedure (Step 2). Remove the right side of the fistula by dissecting the right-sided ischiorectal fossa outside the superficial external sphincter after skin incision.

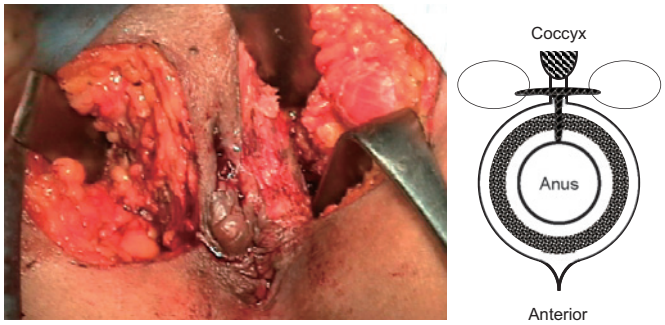

Figure 15-3. The sphincter-preserving lateral procedure (Step 3). A similar incision is made at the 5 o'clock position on the opposite side, and the ischiorectal fossa is dissected outside the superficial external sphincter. After the removal of the right-sided lesion, an incision is made outside the superficial external sphincter to remove the left-sided lesion of the fistula.

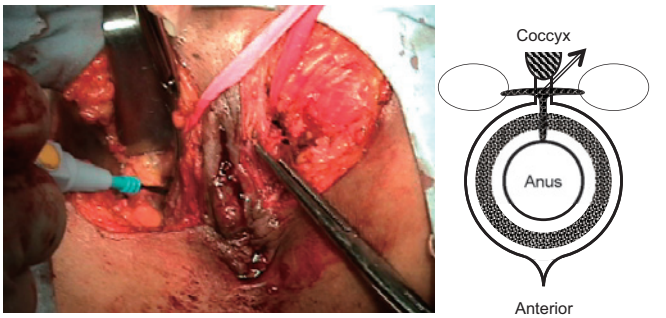

Figure 15-4. The sphincter-preserving lateral procedure (Step 4). Vascular tape is placed posteriorly between the external sphincter and rectum, and traction is applied posteriorly to remove the fistula just below the superficial external sphincter.

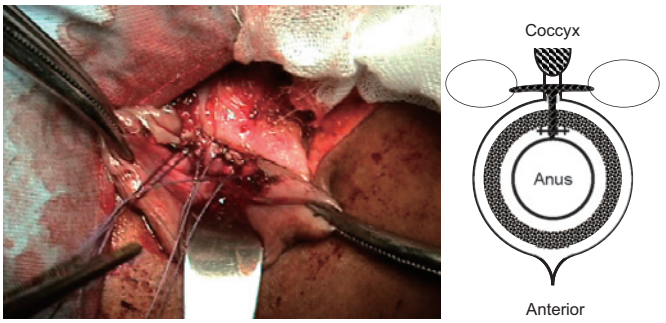

Figure 15-5. The sphincter-preserving lateral procedure (Step 5). The primary opening (PO) is excised and sutured closed. After the removal of the left, right and posterior fistulas, an incision is made between the internal sphincters in the posterior position to dissect the fistulas that are continuous from the PO to the main lesion and sutured closed with a caulescent muscle flap. (Figure 15-1~5. Adapted from Tsuji Y, Nakamura Y, Ogata S, et al. Recommended treatment for ischiorectal and supralevator fistula. J Jpn Soc Coloproctol. 2013; 66 (10): 1044-58. Permitted by the Japan Society of Coloproctology)

(*b*) *Fibrin glue*

Fibrin glue has been used in Europe and the United States to close PO since the 1980s[45]. Cirocchi (2009) published an article describing the use of fibrin glue[46]. The authors stated that once the SO and the fistula tract are identified and the tract is cleaned with curettage, fibrin glue is injected into the PO from the SO. It is a simple procedure, but the cure rate is only 42.5% for patients with complex fistulas and only 30% for patients with Crohn's disease[46].

(*c*) *Advancement flap repair*

Uribe (2007) and Soltani et al. (2010) reported on the endorectal advancement flap repair technique for complex anal fistulas[47,48]. It is described as a sphincter-preserving technique in which the PO is identified and closed with sutures before the PO or fistula tract is covered with a flap using a cutaneous anoderm or an endorectal flap made from the rectal mucosa (Figure 19). Soltani et al. reported a cure rate of 80.8% and a fecal incontinence rate of 13.3% in a review of endorectal flap surgery for transsphincteric fistulas and complex fistulas[48].

Although these overseas sphincter-preserving techniques that preserve the anal sphincter can avoid postoperative anal

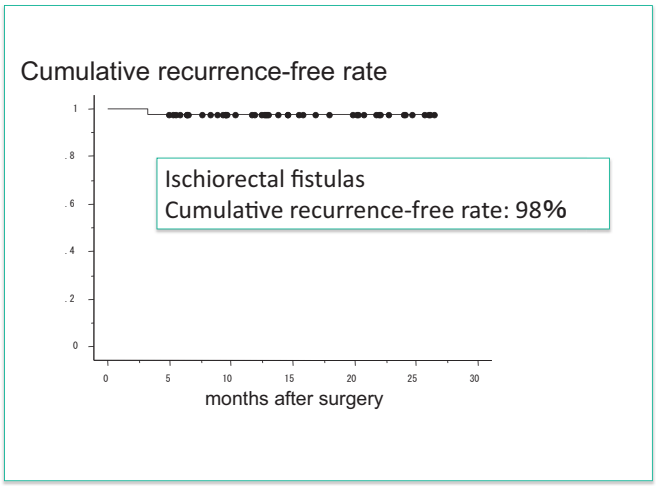

Figure 16. Cumulative recurrence-free rate of ischiorectal fistulas. (Adapted from Tsuji Y, Takano S, Nakamura Y, et al. Efficacy of the sphincter-preserving lateral procedure with an incision on the superficial part of the external anal sphincter for ischiorectal fistula. Surgery. 2018; 80 (13): 1335-42. Permitted by Nankodo Co.,Ltd).

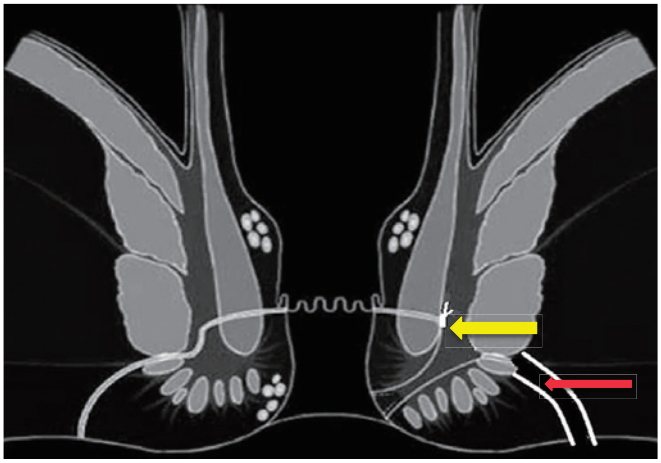

Figure 18. Ligation of the intersphincteric fistula tract (LIFT) method. The fistula tract between the internal and external anal sphincters is ligated and separated (yellow arrow); then, the fistula tract from the secondary opening to the outside of the external anal sphincter is excised (red arrow).

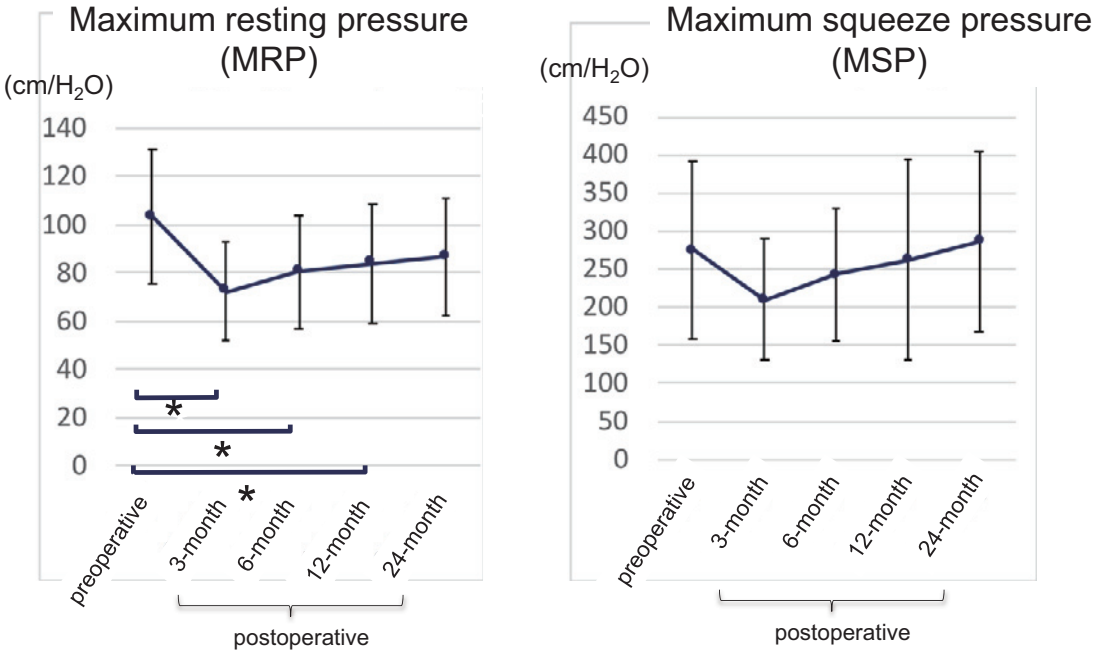

Figure 17. Preoperative & postoperative manometric results. MRP: There was a significant difference between the preoperative and 3, 6, and 12 month periods after surgery ($p < 0.05$) *
MSP: There was no significant difference between the preoperative and 3, 6, and 12 month periods after surgery (Adapted from Tsuji Y, Takano S, Nakamura Y, et al. Efficacy of the sphincter-preserving lateral procedure with an incision on the superficial part of the external anal sphincter for ischiorectal fistula. Surgery. 2018; 80 (13): 1335-42. Permitted by Nankodo Co.,Ltd).

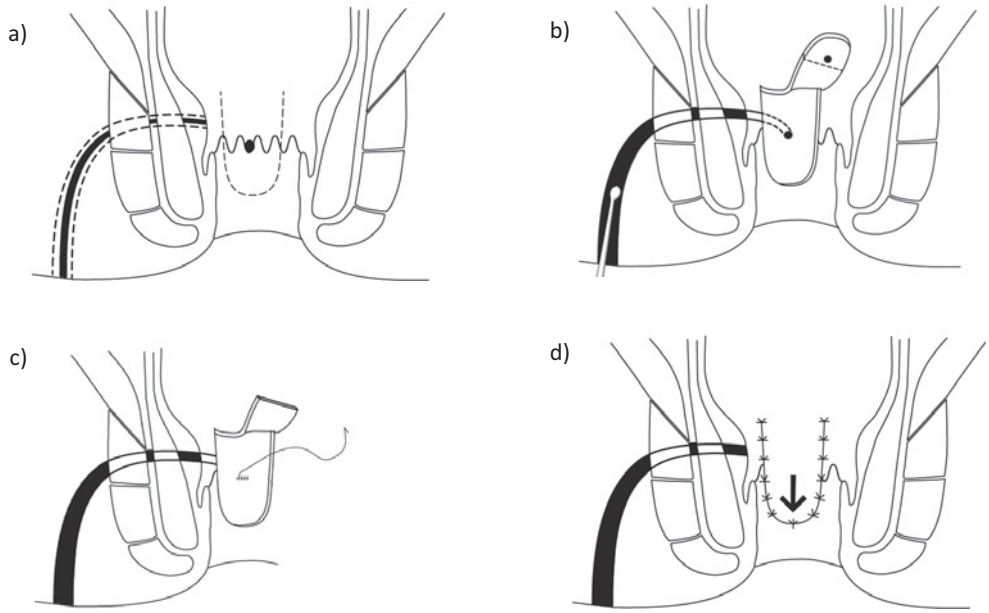

Figure 19. The endorectal advancement flap technique. a: The fistula tract is identified, and a flat cut is made around the opening. b: The flap is lifted, and the fistula tract is curetted. c: The end of the flap is then cut off. d: The flap is then pulled down and sutured in place, and the external opening is left open for drainage.

dysfunction, they are deemed not satisfactory as a radical cure for anal fistula. In the future, it will be necessary to further develop surgical techniques and examine the long-term results of these procedures.

6. Conclusion

The main sphincter-preserving procedures performed for ischiorectal fistula in Japan and abroad were discussed and analyzed in this review article. It was found that no matter what surgical procedure is used for anal fistula, there is always some invasion of the sphincter; the greater the invasion, the more likely the patient will experience postoperative incontinence.

Our goal in this review article was to clearly elucidate the advantages and disadvantages of past sphincter-preserving techniques so that they can be used as a reference for ischiorectal fistula surgery in the future.

Conflicts of Interest

There are no conflicts of interest.

Author Contributions

Yoriyuki Tsuji: concept; drafting of the text, and figures; responsible for the overall content. Shota Takano, Kazutaka Yamada, and Masahiro Takano: involved in the drafting of the article. All authors reviewed and approved the final document for publication.

Disclaimer

Shota Takano is one of the Associate Editors of Journal of the Anus, Rectum and Colon and on the journal's Editorial Board. He was not involved in the editorial evaluation or decision to accept this article for publication at all.

References

1. Nesselrod JP. Pathogenesis of common anorectal infections. Am J Surg. 1954 Nov; 88(5): 815-7.
2. Sumikoshi Y. Practice of hemorrhoids and anal fistula. 1st ed. Tokyo: Kanehara & Co., Ltd; 1973. 52-94 p. Japanese.
3. Tsuji Y, Takano M, Kubota I, et al. Change in anorectal functions depending on sex and aging. J Jpn Soc Coloproctol. 1995 Oct; 48 (9): 1026-32.
4. Takano M. Analysis of surgical methods in 185 cases of Ischiorectal fistula. J Jpn Soc Coloproctol. 1989; 42(6): 1000-11.
5. Matushima M, Tanaka Y, Shimozima Y, et al. Diagnosis and classification of ischiorectal fistulas. J Clin Surg. 2008 Oct; 63(11): 201-7. Japanese.
6. Iwadare J. Practice in anorectal diseases for proctologists. 1st ed. Osaka (Japan): Nagai Shoten Co., Ltd.; 2000. Treatment of ischiorectal fistulas in practice; p. 73-97. Japanese.
7. Iwadare J. Practice in anorectal diseases for proctologists. 1st. Osaka (Japan): Nagai Shoten Co., Ltd.; 2000. Anatomy and physiology of the anal canal; p. 17-30. Japanese.
8. Kurihara H, Kanai T, Ishikawa T, et al. A new concept for the surgical anatomy of posterior deep complex fistulas: the posterior deep space and the septum of the ischiorectal fossa. Dis Colon Rectum. 2006 Oct; 49(10): S37-44.
9. Tsuji Y, Fujiyoshi T, Takagi K, et al. Study on the pathogenesis of ischiorectal abscess and fistula viewed from the standpoint of transanal ultrasonic examination. J Jpn Soc Coloproctol. 1991; 44(2):

146-52.
10. Kagawa R, Nomura H, Takeda R, et al. Anatomical course of deep anal fistulous tracts as analyzed by MRI. J Jpn Soc Coloproctol. 2008 Apr; 61(4): 151-60.
11. Tsuji Y, Yamada K, Takano M. The sphincter-preserving procedure using three dimensional magnetic resonance imaging for the treatment of ischiorectal fistula. Surgery. 2021 Apr; 83(5): 541-9.
12. Nakajima Y, Tsujinaka Y. Effectiveness of combined radial and transcutaneous linear echo in the diagnosis for anal pyoderma and low intermuscular anal fistula. J Jpn Soc Coloproctol. 2008 Aug; 61(8): 521-6.
13. Takano M, Fujiyoshi T, Takagi K, et al. Comparison of the correct diagnosis of anal fistulas between digital and ultrasonic examination. J Jpn Soc Coloproctol. 1992; 45(7): 1033-8.
14. Yamana T, Makita K, Iwadare J. MRI diagnosis of pelvorectal fistulas. J Jpn Soc Coloproctol. 2002 Oct; 55(10): 799-806.
15. Matsuda Y, Tomochika H, Satoh S, et al. Operative assessment for fistula-in-ano from postoperative results. J Jpn Soc Coloproctol. 1996 Nov; 49(10): 1146-58.
16. Hyman N, O'Brien S, Osler T. Outcomes after fistulotomy: results of a prospective, multicenter regional study. Dis Colon Rectum. 2009 Dec; 52(12): 2022-7.
17. Yago N. Operation for posterior intersphincteric anal fistula - procedures of fistulotomy-. J Jpn Soc Coloproctol. 2013 Oct; 66(10): 1026-34.
18. Parks AG. Pathogenesis and treatment of fistula-in-ano. Br Med J. 1961 Feb; 18(1): 463-9.
19. Takano M, Sumie M, Jin J, et al. Surgical procedures for anal fistulas and anal sphincters (II) - sphincter preserving techniques for anal fistulas. Operation. 1976; 30(4): 417-24. Japanese.
20. Iwadare J, Yanagida T, Okada M, et al. Trends in Treatment—ischiorectal fistula-in-ano—the sphincter-preserving procedure. J Clin Surg. 1983 Jan; 38(1): 45-50. Japanese.
21. Hanley PH. Conservative surgical correction of horseshoe abscess and fistula. Dis Colon Rectum. 1965 Sep; 8(5): 364-8.
22. Hanley PH, Ray JE, Pennington EE, et al. Fistula-in-ano: a ten-year follow-up study of horseshoe-abscess fistula-in-ano. Dis Colon Rectum. 1976 Sep; 19(6): 507-15.
23. Ayantunde AA, Debrah SA. Current concepts in anal fissures. World J Surg. 2006 Dec; 30(12): 2246-60.
24. Goligher JC. Surgery of the anus, rectum and colon. 3rd ed. London: Bailliere, Tindall and Cassell Ltd; 1975. 237-42 p.
25. Iwadare J, Yanagida T, Okada M, et al. The muscle filling method for ischiorectal fistulas. J Jpn Soc Coloproctol. 1981; 34(4): 348. Japanese.
26. Kono K, Matsushima Y, Suzuki N, et al. Anal fistulotomy and the intracavitary filling of the muscle flap. J Jpn Soc Coloproctol. 1985; 38(6): 669-76.
27. Tanaka Y. Evaluation of the muscle-filling technique for ischiorectal fistula. J Jpn Soc Coloproctol. 1998 Mar; 51(3): 141-58.
28. Tanaka Y, Sugita H, Katori R, et al. Risk factors for postoperative recurrence of anal fistula based on manometry and transanal ultrasound-sonography examination. J Jpn Soc Coloproctol. 2009 Oct; 62(10): 857-65.
29. Iwadare J, Sumikoshi Y, Sahara R. Muscle-filling procedure for transsphincteric fistulas. Dis Colon Rectum. 1997 Oct; 40(10): S 102-3.
30. Moriya T, Matsuda Y, Takeda T. Coring-out method on the treatment of fistula-in-ano. J Jpn Soc Coloproctol. 1980; 33(5): 456-60.
31. Ui Y. Classification of anal fistula and its surgical treatment. J Jpn Soc Coloproctol. 1982; 35(4): 305-11.
32. Takano M, Fujiyoshi T, Sagara Y. Extrasphincteric radical operation of deep, complicated fistulae. J Jpn Soc Coloproctol. 1985 Jul; 38(4): 345-54.
33. Takano M, Tsuji Y. Practice in anorectal diseases by learning with explanations and videos of the surgical procedures. 1st ed. Tokyo (Japan): Nakayama Shoten Co., Ltd; 2007. Chapter 3, Perianal abscesses/fistulas; p.107-29. Japanese.
34. Tsuji Y, Yamada K, Takano M, et al. Different recurrence mechanisms by the procedures of fistulotomy. J Jpn Soc Coloproctol. 2009 Oct; 62(10): 850-6.
35. Tsuji Y, Nakamura Y, Ogata S, et al. Recommended treatment for ischiorectal and supralevator fistula. J Jpn Soc Coloproctol. 2013 Oct; 66(10): 1044-58.
36. Tsuji Y, Takano S, Nakamura Y, et al. Efficacy of the sphincter-preserving lateral procedure with an incision on the superficial part of the external anal sphincter for ischiorectal fistula. Surgery. 2018 Dec; 80(13): 1335-42.
37. Kurokawa A, Kitsuki K, Kurokawa Y. Our classic treatment of anal fistula. J Jpn Soc Coloproctol. 1995; 48(10): 1113-20.
38. Sakata H. Seton treatment of anal fistula. J Clin Surg. 2002 Nov; 57(12): 1511-22.
39. Kurokawa A, Kitsuki K, Kurokawa Y. Seton treatment of pelvirectal fistula. J Jpn Soc Coloproctol. 2002 Oct; 55(10): 829-33.
40. Tsuji Y, Takano M, Kuromizu J, et al. A comparative study on surgical technique for lateral intermuscular fistula by examination of anal physiology. J Jpn Soc Coloproctol. 1996 Nov; 49(10): 1182-90.
41. Rojanasakul A, Pattanaarun J, Sahakitrungruang C, et al. Total anal sphincter technique for fistula-in-ano; the ligation of intersphincteric fistula tract. J Med Assoc Thai. 2007 Mar; 90(3): 581-6.
42. Wallin UG, Mellgren AF, Madoff RD, et al. Does ligation of the intersphincteric fistula tract raise the bar in fistula surgery? Dis Colon Rectum. 2012 Nov; 55(11): 1173-8.
43. Abcarian AM, Estrada JJ, Park J, et al. Ligation of intersphincteric fistula tract: early results of a pilot study. Dis Colon Rectum. 2012 Jul; 55(7): 778-82.
44. Sada H, Tsunoda A, Sugimoto T, et al. Anal function and early results after the ligation of the intersphincteric fistula tract for anterior or lateral low transsphincteric fistula-in-ano. J Jpn Soc Coloproctol. 2013 Jun; 66(6): 406-11.
45. Venkatesh KS, Ramanujam P. Fibrin glue application in the treatment of recurrent anorectal fistulas. Dis Colon Rectum. 1999 Sep; 42(9): 1136-9.
46. Cirocchi R, Farinella E, La Mura F, et al. Fibrin glue in the treatment of anal fistula: a systematic review. Ann Surg Innov Res. 2009 Nov; 3(1): 12.
47. Uribe N, Millán M, Minguez M, et al. Clinical and manometric results of endorectal advancement flaps for complex anal fistula. Int J Colorectal Dis. 2007 Mar; 22(3): 259-64.
48. Soltani A, Kaiser AM. Endorectal advancement flap for cryptoglandular or Crohn's fistula-in-ano. Dis Colon Rectum. 2010 Apr; 53(4): 486-95.