



Since January 2020 Elsevier has created a COVID-19 resource centre with free information in English and Mandarin on the novel coronavirus COVID-19. The COVID-19 resource centre is hosted on Elsevier Connect, the company's public news and information website.

Elsevier hereby grants permission to make all its COVID-19-related research that is available on the COVID-19 resource centre - including this research content - immediately available in PubMed Central and other publicly funded repositories, such as the WHO COVID database with rights for unrestricted research re-use and analyses in any form or by any means with acknowledgement of the original source. These permissions are granted for free by Elsevier for as long as the COVID-19 resource centre remains active.



## Letter to the Editors-in-Chief

## Role of upfront CT pulmonary angiography at admission in COVID-19 patients



## ARTICLE INFO

## Keywords:

Coronavirus infections  
Pneumonia  
Tomography  
X-ray computed  
Contrast media

## 1. Introduction

Current guidelines recommend the use of unenhanced chest computed tomography (CT) as first-line imaging in patients suspected of having COVID-19 pneumonia, in order to assess the extent of lung damage [1,2]. Although most patients have a favorable disease course, some of them develop secondary disease worsening due to an excessive systemic inflammatory response, evidenced by high serum levels of biomarkers such as IL-6, which promotes an hypercoagulability state leading to thrombotic complications [3,4]. A D-dimer level greater than 1000 µg/L has been clearly identified as a risk factor for poor outcome [5].

However, little is known about the exact prevalence of thromboembolism in COVID-19 patients. Recent studies [6–8] have reported a high cumulative incidence of acute pulmonary embolism (PE), ranging from 23% to 30%, but these reports mainly concerned severe patients admitted in ICU. To date, the prevalence of acute PE at baseline presentation of unselected COVID-19 patients remains unknown, as is the benefit of a systematic CT pulmonary angiography (CTPA) at initial screening.

The objective of this study was to evaluate the prevalence of PE when systematically performing CT pulmonary angiography (CTPA) as first-line imaging modality in patients with COVID-19 suspicion.

## 2. Materials and methods

This retrospective study was approved by the local ethics committee of Saint-Etienne, which waived the need for patient consent.

## 2.1. Patient population and data

From March 26th, 2020, following the reports of frequent PE in COVID-19 patients [9,10], it was decided to systematically perform CTPA as first-line imaging modality in patients suspected of COVID-19 at Saint-Etienne University Hospital, unless there were contraindications to contrast medium administration. We retrospectively included all consecutive patients suspected of COVID-19 presenting at the emergency department who had undergone systematic CTPA between March 26th and April 17th, 2020.

All patients had reverse transcriptase - polymerase chain reaction (RT-PCR) nasopharyngeal swab test for SARS-Cov-2 on the same day as the CTPA. In case of first negative RT-PCR result and high clinical suspicion, swab test was repeated.

Demographics, clinical and biological data as well as patients' outcomes were collected from medical charts. The evaluated clinical parameters included age, sex, comorbidities (obesity, type 2 diabetes, respiratory or cardiovascular disease, hypertension), delay from symptoms onset as well as for oxygen needs, ICU admission or mechanical ventilation. Biological data included D-dimer, C-reactive protein, lactate dehydrogenase levels and lymphocyte count.

Patients with a single negative RT-PCR result, who had typical CT features of COVID-19 pneumonia in addition to suggestive symptoms and laboratory results were considered as COVID-19 positive.

Cases of contrast medium extravasation after intravenous administration or of serum creatinine increase in the following days after CTPA were reported.

## 2.2. CT protocol and imaging analysis

CT examinations were performed on a multidetector CT scanner using routine CTPA protocols. Images were acquired after intravenous administration of 50–70 mL of nonionic iodinated contrast media at a flow rate of 4 mL/s, using automatic detection of the contrast bolus in the pulmonary trunk, and reconstructed with 1-mm slice thickness. Images were analyzed on Picture Archiving and Communication System workstations (Carestream Vue PACS, version 12.1.5) by an experienced chest radiologist, aware of the COVID-19 suspicion but blinded to clinical and biological data. CT images were evaluated for signs of COVID-19 pneumonia, lung disease extent and presence of pulmonary embolism. For COVID-19 positive scans, disease extent was classified into 4 categories according to the percentage diseased lung: mild (< 25%), moderate (25–50%), severe (50–75%) or critical (> 75%) involvement. Signs of right ventricular dysfunction (right-to-left ventricle diameter ratio > 1, paradoxical septal bowing) were reported for PE positive cases.

<https://doi.org/10.1016/j.thromres.2020.08.037>

Received 24 July 2020; Received in revised form 11 August 2020; Accepted 24 August 2020

Available online 25 August 2020

0049-3848/ © 2020 Elsevier Ltd. All rights reserved.

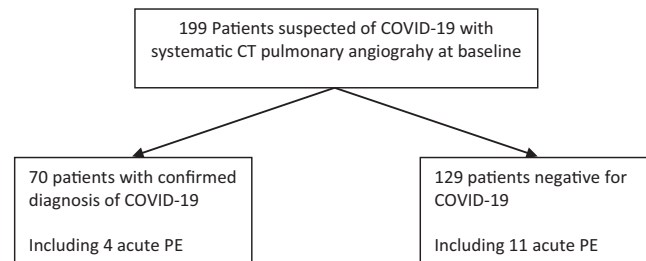


Fig. 1. Flowchart of the study.

2.3. Statistical analysis

Statistical analysis was performed using the statistical software package “R” (version 3.2.1, R Foundation, Vienna, Austria). Demographics, clinical and biological between patients with and without PE were compared using *t*-test and Fisher exact test. Disease extent was compared using a Cochran-Armitage trend test. *P* values less than 0.5 were considered as statistically significant.

3. Results

Fig. 1 shows the flowchart of the study. Patient characteristics are presented in Table 1.

Of the 199 patients who underwent CTPA, 70 were positive for COVID-19: 65 had a positive RT-PCR result whereas 5 other patients with typical CT features of COVID-19 pneumonia and only one negative RT-PCR result were also considered positive.

Four (4/70, 5.7%) of the COVID-19 patients had acute PE: 2 had segmental PE, one had lobar PE and the last patient a proximal defect in

the right main pulmonary artery, with signs of right ventricular dysfunction.

Eleven (11/129, 8.5%) of the 129 COVID-19 negative patients had acute PE, at the segmental level in seven patients, lobar level or more proximal level in four, two with signs of right ventricular dysfunction.

PE prevalence was not significantly different between patients with and without COVID-19 (*p* = 0.581).

Although disease extent was not significantly different between the PE positive and negative groups, COVID-19 patients with PE were more frequently admitted in ICU. Hypertension was more frequent in the PE positive group.

Of the 70 COVID-19 positive patients, 44 had abnormal age-adjusted D-dimer levels, but the proportion of those having D-dimer level > 5000 µg/L was significantly higher in patients with PE.

Regarding complications of contrast administration, 3 of the 199 patients who underwent CTPA presented contrast extravasation and 3 elderly patients (mean age 85.3 ± 4.7), of which 2 had type 2 diabetes, presented subsequent increase of the serum creatinine above 614 ± 100 µmol/L, resulting in a 3.0% (6/199) complication rate

Table 1 Patient characteristics.

	All COVID-19 patients (n = 70)	COVID-19 patients without PE (n = 66)	COVID-19 patients with PE (n = 4)	P value
Age (years)	65 ± [21–97]	65 ± 16 [21–97]	69 ± 3 [66–73]	0.226
Male	44/70 (63)	41/66 (62)	3/4 (75)	1.0
Positive RT-PCR	65/70 (93)	61/66 (92)	4/4 (100)	1.0
Delay from onset of symptoms to CT (days)	8 ± 4 [1–16]	8 ± 4 [1–16]	6 ± 2 [4–8]	0.354
Comorbidities				
Overweight or obesity	34/54 (63)	30/50 (60)	4/4 (100)	0.285
Type 2 diabetes	14/68 (21)	12/64 (19)	2/4 (50)	0.185
Hypertension	31/68 (46)	27/64 (42)	4/4 (100)	<b>0.039</b>
Smoking history	18/67 (27)	16/63 (25)	2/4 (50)	0.291
Respiratory disease	9/68 (13)	9/64 (14)	0/4 (0)	1.0
Cardiovascular Disease	14/68 (21)	13/64 (20)	1/4 (25)	1.0
CT disease extent*				
Absent	3/70 (4)	3/66 (5)	0/4 (0)	
Mild	36/70 (51)	35/66 (53)	1/4 (25)	
Moderate	22/70 (31)	20/66 (30)	2/4 (50)	
Severe	5/70 (7)	5/66 (8)	0/4 (0)	
Critical	4/70 (6)	3/66 (5)	1/4 (25)	
Disease severity				
Oxygen therapy	38/68 (56)	34/64 (53)	4/4 (100)	0.124
ICU	16/70 (23)	13/66 (20)	3/4 (75)	<b>0.035</b>
Mechanical ventilation	12/70 (17)	10/66 (15)	2/4 (50)	0.133
Death	1/68 (1)	1/64 (2)	0/4 (0)	1.0
Laboratory analysis				
D dimer (µg/L)	1694 ± 2890 [270–20,000]	1102 ± 538 [270–2210]	9394 ± 7024 [988–20,000]	0.133
D dimer > 5000 µg/L	3/56 (5)	0/52 (0)	3/4 (75)	< <b>0.001</b>
CRP (mg/L)	84 ± 72 [0–315]	77 ± 62 [0–263]	198 ± 118 [53–315]	0.176
CRP > 25 mg/L	55/69 (80)	51/65 (78)	4/4 (100)	0.575
LDH (UI/L)	413 ± 163 [197–1181]	407 ± 166 [197–1181]	488 ± 90 [355–608]	0.226
LDH > 250 UI/L	48/54 (89)	44/50 (88)	4/4 (100)	1.0
Lymphopenia	43/69 (62)	40/65 (62)	3/4 (75)	1.0

\* Cochran-Armitage trend test.

following contrast medium administration.

#### 4. Discussion

Since the outbreak of the COVID-19 epidemic, the impact of unenhanced chest CT has been widely reported and is no longer discussed [11,12]. Given the high risk of pulmonary embolism in the COVID-19 pneumonia, first-line CTPA is an option that deserves to be considered. To the best of our knowledge, this is the first study reporting PE prevalence in unselected COVID-19 patients at initial presentation. Previous studies on PE mainly concerned severe COVID-19 patients admitted to ICU. Our study shows that the prevalence of acute PE at initial presentation is low, below 6%, and not different from that observed for COVID-19 negative patients.

Dyspnea and desaturation are common symptoms of both COVID-19 and pulmonary embolism, and clinical triage is difficult. Furthermore, the Wells or Geneva pre-test probability scores usually used for outpatients with PE suspicion have not been validated for COVID-19 patients. Most patients with SARS-Cov2 infection had elevated D-dimers, but a value above 5000 µg/L was only observed in patients with PE. Even if it is not possible to draw a definitive conclusion on a limited series, our data suggest considering contrast administration at initial presentation of patients with COVID-19 suspicion who have marked elevation of D-dimers.

There was a 7-day median interval between symptoms onset and CTPA in our study which is shorter than that reported (12 to 14 days) in studies reporting 23% to 30% cumulative incidence of PE in COVID-19 patients [6,8]. These results support the hypothesis of a delayed hypercoagulability state, occurring during the second phase of the disease consecutively to the cytokine release syndrome [3].

Although complications of iodinated contrast administration were rarely observed in our study, a significant deterioration of the renal function occurred for 3 elderly patients. SARS-Cov-2 can deteriorate the renal function following direct endothelial invasion of the glomerular capillaries. Thus, routine use of contrast administration should be carefully considered in COVID-19 patients, especially if there are risk factors for renal function deterioration such as diabetes or advanced age.

This study has several limitations, including its retrospective nature, the small number of events and the lack of follow-up especially regarding late thromboembolic events. Nonetheless, we believe that the present study improves the current knowledge on COVID-19 disease, by reporting a low PE prevalence at initial presentation.

To conclude, this study does not provide clear evidence that there is a benefit to routinely perform CTPA as first-line imaging modality in patients suspected of COVID-19 pneumonia.

#### Declaration of competing interest

The authors declare that there is no conflict of interest.

#### References

- [1] G.D. Rubin, S.R. Desai, J.M. Goo, Y. Inoue, N. Tomiyama, C.J. Ryerson, et al., The role of chest imaging in patient management during the COVID-19 pandemic: a multinational consensus statement from the Fleischner Society, *Radiology* (2020) 201365.
- [2] M.-P. Revel, A.P. Parkar, H. Prosch, M. Silva, N. Sverzellati, et al., COVID-19 patients and the radiology department – advice from the European Society of Radiology (ESR) and the European Society of Thoracic Imaging (ESTI), *Eur. Radiol.* (2020), <https://doi.org/10.1007/s00330-020-06865-y>.
- [3] J.M. Connors, J.H. Levy, Thromboinflammation and the hypercoagulability of COVID-19, *J Thromb Haemost* 18 (7) (2020) 1559–1561, <https://doi.org/10.1111/jth.14849>.
- [4] F.A. Klok, M.J.H.A. Kruip, N.J.M. van der Meer, et al., Incidence of thrombotic complications in critically ill ICU patients with COVID-19, *Thromb. Res.* 191 (2020) 145–147.
- [5] N. Tang, D. Li, X. Wang, Z. Sun, Abnormal coagulation parameters are associated with poor prognosis in patients with novel coronavirus pneumonia, *J. Thromb. Haemost.* 18 (2020) 844–847.
- [6] I. Leonard-Lorant, X. Delabranche, F. Severac, J. Helms, C. Pautzet, O. Collange, et al., Acute pulmonary embolism in COVID-19 patients on CT angiography and relationship to D-dimer levels, *Radiology* (2020) 201561.
- [7] F. Bompard, H. Monnier, I. Saab, et al., Pulmonary embolism in patients with COVID-19 pneumonia, *Eur Respir J.* 56 (1) (2020) 2001365, <https://doi.org/10.1183/13993003.01365-2020> Published 2020 Jul 30.
- [8] F. Grillet, J. Behr, P. Calame, S. Aubry, E. Delabrousse, Acute pulmonary embolism associated with COVID-19 pneumonia detected by pulmonary CT angiography, *Radiology* (2020) 201544.
- [9] G.B. Danzi, M. Loffi, G. Galeazzi, E. Gherbesi, Acute pulmonary embolism and COVID-19 pneumonia: a random association? *Eur. Heart J.* (2020) ehaa254.
- [10] D.C. Rotzinger, C. Beigelman-Aubry, C. von Garnier, S.D. Qanadli, Pulmonary embolism in patients with COVID-19: time to change the paradigm of computed tomography, *Thromb. Res.* 190 (2020) 58–59.
- [11] K.K. Sahu, A. Lal, A.K. Mishra, An update on CT chest findings in coronavirus disease-19 (COVID-19), *Heart Lung* S0147-9563 (20) (2020) 30094–30097, <https://doi.org/10.1016/j.hrtng.2020.03.007>, Accessed date: 20 March 2020.
- [12] Y. Zheng, L. Wang, S. Ben, Meta-analysis of chest CT features of patients with COVID-19 pneumonia, *J. Med. Virol.* (2020), <https://doi.org/10.1002/jmv.26218>.

Carole Jalaber<sup>a,\*</sup>, Marie-Pierre Revel<sup>b</sup>, Guillaume Chassagnon<sup>b</sup>, Emma Bajoux<sup>c</sup>, Thibaut Lapotre<sup>d</sup>, Pierre Croisille<sup>a</sup>, Mathieu Lederlin<sup>d</sup>  
<sup>a</sup>Department of Radiology, University Hospital of Saint-Etienne, University Jean Monnet, Avenue Albert Raimond, 42270 Saint Priest en Jarez, France  
<sup>b</sup>Department of Radiology, Cochin Hospital, AP-HP, University Paris 5 Descartes, Rue de l'école de médecine, 75006 Paris, France  
<sup>c</sup>Department of Epidemiology, University Hospital of Rennes, University Rennes, 2 rue Henri le Guilloux, 35000 Rennes, France  
<sup>d</sup>Department of Radiology, University Hospital of Rennes, University Rennes, 2 rue Henri le Guilloux, 35000 Rennes, France  
 E-mail address: [carole.huyghe@etu.univ-st-etienne.fr](mailto:carole.huyghe@etu.univ-st-etienne.fr) (C. Jalaber).

\* Corresponding author at: Department of Radiology, University Hospital of Saint-Etienne, University Jean Monnet of Saint-Etienne, Avenue Albert Raimond, 42000 Saint-Etienne, France.