



Case report

Three cases of acute sterile corneal melt after cataract surgery

Kohei Harada^{a,*}, Yasser Helmy Mohamed^a, Masafumi Uematsu^a, Daisuke Inoue^a, Ryotaro Ueki^a, Shiori Harada^a, Naoki Imamura^a, Inamoto Miwako^b, Takashi Kitaoka^a

^a Department of Ophthalmology and Visual Sciences, Graduate School of Biomedical Sciences, Nagasaki University, 1-7-1 Sakamoto, Nagasaki, Nagasaki, 852-8501, Japan

^b Department of Ophthalmology, National Hospital Organization Nagasaki Medical Center, 2-1001-1 Kubara, Omura, Nagasaki 856-0835, Japan



ARTICLE INFO

Keywords:

Corneal melt
Corneal perforation
Nonsteroidal anti-inflammatory drugs
Dry eye
Autoimmune disease

ABSTRACT

Purpose: To report three cases of acute sterile corneal melt after cataract surgery.

Observations: Case 1 was a 21-year-old male presenting with a corneal perforation of his right eye at 10 days after cataract surgery. Case 2 was a 67-year-old male who developed a corneal melt in his left eye at 15 days after cataract surgery. Case 3 was a 70-year-old female with a corneal melt of her left eye at 7 days after cataract surgery. None of the cases exhibited any signs of infection. Topical nonsteroidal anti-inflammatory drug use, dry eye, systemic autoimmune diseases, and/or a combination of these were present in patients who developed corneal melt after cataract surgery.

Conclusions and Importance: Corneal melt cases can occur early after cataract surgery, thereby leading to corneal thinning and perforation.

1. Introduction

Progressive sterile keratolysis or corneal melt has been documented following cataract surgery.^{1,2} Corneal melt is a rare yet potentially blinding condition that manifests itself through rapid and severe corneal stromal thinning. Topical nonsteroidal anti-inflammatory drugs (NSAIDs) are used in the management of postoperative ocular inflammation and have been associated with corneal toxicity. While it has been suggested that NSAID usage can lead to corneal melt,^{3–5} evidence proving this association has yet to be definitively confirmed. We report three cases of corneal melt found to be associated with the use of topical NSAIDs and other factors.

2. Findings

2.1. Case 1

A 21-year-old male with a history of chronic graft-versus-host disease (chronic GVHD) following allogeneic stem cell transplantation for acute myelogenous leukemia, presented with bilateral painless progressive diminution of his vision in April 2013. The patient was diagnosed with dry eye and bilateral posterior sub-capsular cataract, which developed as a complication of steroid therapy (oral prednisolone 10 mg/day). Steroid therapy was used as a treatment of myasthenia gravis,

which had previously developed in 2012. The patient had uneventful right phacoemulsification with posterior chamber intraocular lens (IOL) implantation in August 2013. Postoperatively, he was placed on topical Berbesolone[®] F (betamethasone sodium phosphate/fradiomycin sulfate 0.1%), Cravit[®] (levofloxacin 1.5%), and Navanac[®] (nepafenac 0.1%) 4 times a day. At 10 days after surgery, he presented with a paracentral corneal melt and perforation surrounded by corneal haze in his right eye (Fig. 1a). Although penetrating keratoplasty was performed on the following day (Fig. 1b), postoperative corneal rejection occurred with secondary glaucoma and poor vision. However, the patient refused to undergo any further operations.

2.2. Case 2

A 67-year-old male with a past history of steroid pulse therapies for interstitial pneumonia and dermatomyositis had diminution of his vision in the left eye due to cataract development in November 2015. Uneventful phacoemulsification with IOL implantation was performed in the left eye. Postoperatively, he was placed on topical Flumetholon[®] (fluorometholone 0.02%), Ophthalon[®] (chloramphenicol 0.25%/colistin) 4 times a day, and Bronuck[®] (bromfenac 0.1%) 2 times a day. After presenting with paracentral corneal thinning at 2 weeks after surgery, topical Hyalein[®] (hyaluronic acid 0.3%) was added to his treatment. Progression of the corneal thinning continued and the

* Corresponding author.

E-mail address: nagasakiidejimadejima@yahoo.co.jp (K. Harada).

<https://doi.org/10.1016/j.ajoc.2018.12.004>

Received 5 May 2018; Received in revised form 23 July 2018; Accepted 3 December 2018

Available online 04 December 2018

2451-9936/ © 2018 The Authors. Published by Elsevier Inc. This is an open access article under the CC BY-NC-ND license (<http://creativecommons.org/licenses/by-nc-nd/4.0/>).

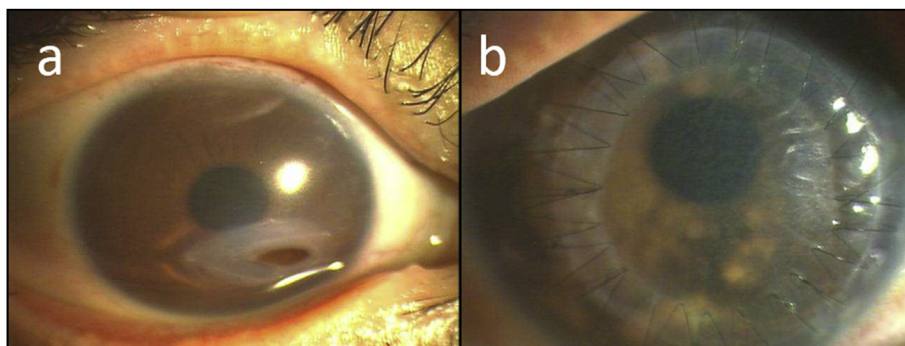


Fig. 1. a: Sterile corneal melt of the right eye 10 days after cataract surgery. b: At 14 days after penetrating keratoplasty.

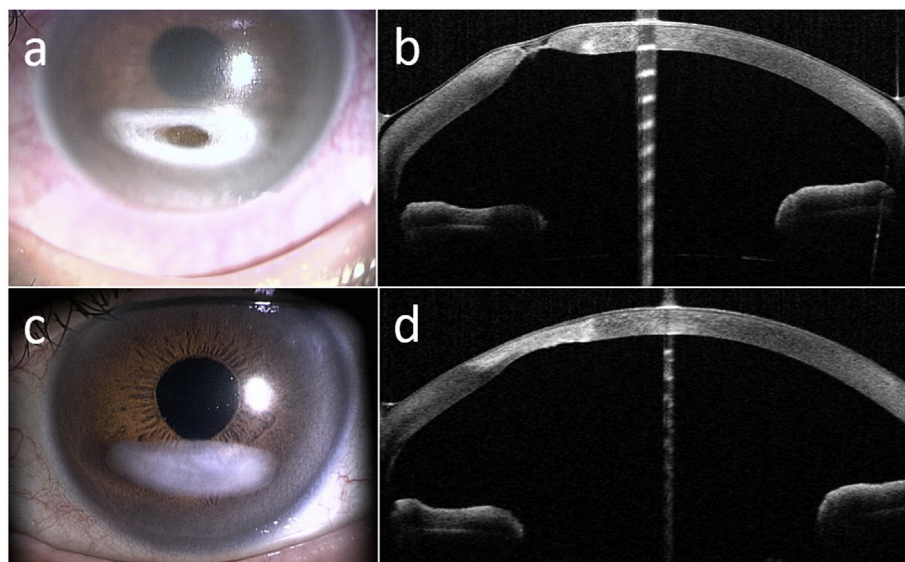


Fig. 2. a: Sterile corneal melt of the left eye after cataract surgery. b: Anterior OCT of the corneal melt with a protective SCL. c: Corneal melt resolved 4 months after treatment. d: Anterior OCT of the cornea shows the cornea regained its thickness.

patient was referred to our institute. The patient had paracentral corneal thinning surrounded by an annular opacity that was 5 mm in diameter (Fig. 2a and b). Although topical Vegamox[®] (moxifloxacin 0.5%), Panimycin[®] (dibekacin 0.3%), and Bestron[®] (cefmenoxime 0.5%) eye drops were applied every hour to exclude infection, there was no improvement in his corneal thinning. After the patient was hospitalized, punctal plugs along with a protective soft contact lens (SCL) were applied. In addition, the administration of Bronuck[®] was also stopped. The corneal melt exhibited epithelialization followed by the development of thickening of the cornea until the melt completely disappeared after 10 days of treatment (Fig. 2c and d).

2.3. Case 3

A 70-year-old female with a past history of hypertension and hyperlipidemia had left uneventful phacoemulsification with IOL implantation in April 2015. Postoperatively, she was placed on topical Berbesolone[®] F (betamethasone sodium phosphate/fradiomycin sulfate 0.1%), Diclofenac[®] (diclofenac 0.1%), and Cravit[®] (levofloxacin 1.5%) 4 times a day. As left paracentral corneal melt was diagnosed at 1 week after her operation, topical Hyalein[®] (hyaluronic acid 0.1%) was added to her treatment. At the time of her referral to our institute, the patient exhibited paracentral corneal melt and thinning, with fine and sparse inflammatory cells observed in the anterior chamber (Fig. 3a). The patient was diagnosed as having dry eye, with a Schirmer test of 2 mm. After the application of punctal plugs and a protective SCL, and the

cessation of the diclofenac administration, her melt completely disappeared at 2 weeks after the treatment procedure (Fig. 3b).

3. Discussion

Acute sterile corneal melt after uneventful cataract surgery is not generally recognized and thus, without appropriate treatment, progressive corneal thinning with perforation and loss of vision may occur.^{6–8} All of the cases in the present report developed corneal melt around the paracentral cornea shortly after cataract surgery without infection. In case 3, the healing of the corneal disorder occurred after the application of punctal plugs and a protective SCL without the addition of any new antibiotic drugs. Acute sterile corneal melt after cataract surgery is defined as: 1) the occurrence of keratolysis within 1 month after cataract surgery, 2) the absence of any signs of infection, and 3) appearance around the paracentral cornea. Furthermore, this condition has been shown to be related to a variety of factors including dry eye, topical medications, and immune mediated diseases. In this report, the related factors included the use of postoperative topical NSAIDs in all of these cases, along with GVHD with dry eye in the first case, autoimmune disease such as interstitial pneumonia and dermatomyositis in the second case, and dry eye in the third case.

It has been reported that severe dry eye can potentially lead to sterile corneal melt and perforation.⁹ It is also known that autoimmune diseases such as Sjögren's syndrome and rheumatoid arthritis can cause sterile corneal melt.^{10,11} It has also been presumed that acute sterile

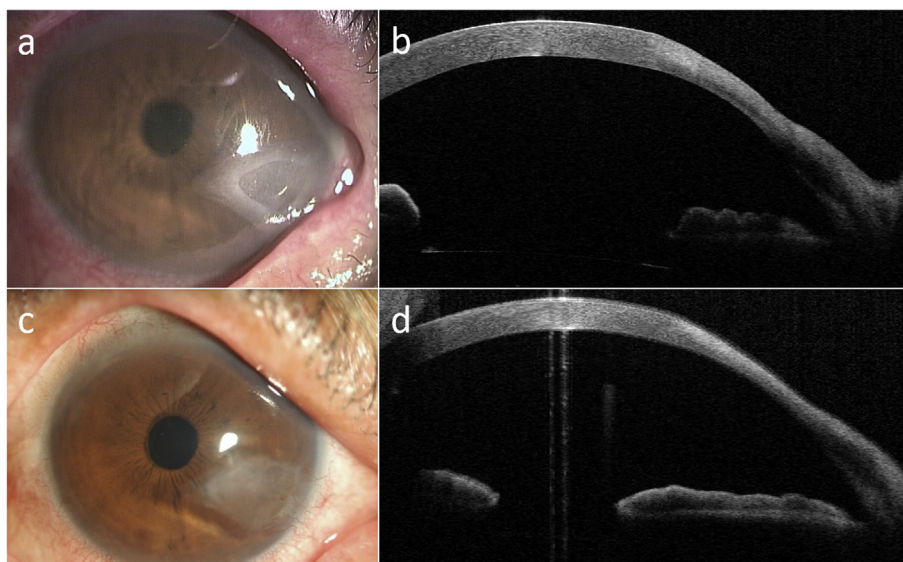


Fig. 3. a: Sterile corneal melt of the right eye at 7 days after cataract surgery. b: Anterior OCT of the corneal melt before treatment. c: Corneal melt resolved at 2 weeks after the treatment. d: Anterior OCT of the corneal melt 2 weeks after treatment. The cornea maintained its thickness.

corneal melt after cataract surgery might preferably occur in patients with these conditions.

Several previous studies have reported finding corneal melt following the use of NSAIDs after uncomplicated cataract surgery.^{3–5} NSAIDs shunt arachidonic acid to the lipoxygenase pathway, which results in higher leukotriene levels. Leukotrienes are potent neutrophil chemoattractants, as well as stimulators of neutrophil degranulation. The neutrophil granules contain powerful collagenases that may play a crucial role in the development of NSAID-related corneal melts and perforations.¹² However, Radtke et al. reported that acute sterile corneal melt after cataract surgery occurred without the use of NSAID eye drops in dry eye cases.⁶ Although NSAIDs are one of the main causes of corneal melt, they may not be a necessary condition for the occurrence of acute sterile corneal melt.

Histopathologic examination revealed a high level of matrix metalloproteinase (MMP)-8 in the corneal epithelium of the corneal button obtained from a case with corneal perforation caused by topical NSAIDs.¹³ Furthermore, corneal perforation in patients with chronic GVHD might be related to MMP9 and CD68 macrophage accumulation.¹⁴ MMPs are a family of collagenolytic enzymes that are responsible for the degradation of extracellular matrix components, such as collagen and proteoglycans. It is conceivable that MMP may be an important factor in the occurrence of sterile acute corneal melt after cataract surgery.

Overall, the factors responsible for causing acute corneal melt after cataract surgery may include topical NSAID use, dry eye, systemic autoimmune diseases, and/or any combination of these aforementioned factors. In addition, physicians should be aware that this can occur within one week after cataract surgery. Treatments that can be used include the cessation of NSAIDs, wearing a SCL, and punctal plug insertions, which may help to promote corneal epithelialization.^{6–8} After epithelialization, the corneal stroma is able to regain its thickness, as seen in the optical coherence tomography (OCT) image of the second case.

This may be the first OCT report to show corneal melt and its treatment. Further clinical and experimental studies will need to be undertaken in order to precisely clarify the mechanism of the disease and its treatment.

Acute sterile corneal melt after cataract surgery is a rare but significant complication. Detailed preoperative screening for both ocular and systemic risk factors is essential in these cases. Furthermore, long-term postoperative follow-ups should be undertaken in patients with

conditions that could potentially precipitate corneal melt.

Patient consent

Written informed consent was obtained from all of the patients for publication of these case reports and any accompanying images.

Funding

No funding or grant support.

Conflicts of interest

All authors have no financial disclosures.

Authorship

All authors attest that they meet the current ICMJE criteria for authorship.

Acknowledgements

None.

References

- Cohen KL. Sterile corneal perforation after cataract surgery in Sjögren's syndrome. *Br J Ophthalmol.* 1982;96(3):179–182.
- Maffett MJ, Johns KJ, Parrish CM, Elliott JH, Glick AD, O'Day DM. Sterile corneal ulceration after cataract extraction in patients with collagen vascular disease. *Cornea.* 1990;9(4):279–285.
- Lin JC, Rapuano CJ, Laibson PR, Eagle Jr RC, Cohen EJ. Corneal melting associated with use of topical nonsteroidal anti-inflammatory drugs after ocular surgery. *Arch Ophthalmol.* 2000;118(8):1129–1132.
- Tachibana R, Hamada S, Matsuo T, Otsuki H. A case of corneal melting and perforation following cataract surgery. *Rinsho Ganka.* 2013;67(2):188–190.
- Wolf EJ, Kleiman LZ, Schrier A. Nepafenac-associated corneal melt. *J Cataract Refract Surg.* 2007;33(11):1974–1975.
- Radtke N, Meyers S, Kaufman HE. Sterile corneal ulcers after cataract surgery in keratoconjunctivitis sicca. *Arch Ophthalmol.* 1978;96(1):51–52.
- Gelender H. Descemetocoele after intraocular lens implantation. *Arch Ophthalmol.* 1982;100(1):72–76.
- Chaudhary R, Mushtaq B. Spontaneous corneal perforation post cataract surgery. *BMJ Case Rep.* 2011. <https://doi.org/10.1136/bcr.11.2011.5099>.
- Deswal J, Arya SK, Raj A, Bhatti A. A case of bilateral corneal perforation in a patient with severe dry eye. *J Clin Diagn Res.* 2017;11(4):ND01–ND02.

10. Vivino FB, Minerva P, Huang CH, Orlin SE. Corneal melt as the initial presentation of primary Sjögren's syndrome. *J Rheumatol*. 2001;28(2):379–382.
11. Kervick GN, Pflugfelder SC, Haimovici R, Brown H, Tozman E, Yee R. Paracentral rheumatoid corneal ulceration. Clinical features and cyclosporine therapy. *Ophthalmology*. 1992;99(1):80–88.
12. Ujioka A, Matsumoto K, Miyajima S, Tanihara H. Two cases of corneal ulcer following instillation of diclofenac ophthalmic solution. *Rinsho Ganka*. 2002;56(5):852–856.
13. O'Brien TP, Li QJ, Sauerburger F, Reviglio VE, Rana T, Ashraf MF. The role of matrix metalloproteinases in ulcerative keratolysis associated with perioperative diclofenac use. *Ophthalmology*. 2001;108(4):656–659.
14. Inagaki E, Ogawa Y, Matsumoto Y, Kawakita T, Shimmura S, Tsubota K. Four cases of corneal perforation in patients with chronic graft-versus-host disease. *Mol Vis*. 2011;17:598–606.