

Received: 2010.10.01
Accepted: 2011.01.24
Published: 2011.08.01

Obstructive jaundice and cholangitis caused by an arterial ring of the proper hepatic artery around the common bile duct

Authors' Contribution:

- A** Study Design
- B** Data Collection
- C** Statistical Analysis
- D** Data Interpretation
- E** Manuscript Preparation
- F** Literature Search
- G** Funds Collection

Dragoljub Bilanovic^{1,2,ABD}, **Darko Zdravkovic**^{1,2,ABDF}, **Borislav Toskovic**^{1,2,BDF},
Tomislav Randjelovic^{1,2,AD}, **Srdjan Dikic**^{1,2,DF}, **Blagoje Djukanovic**^{1,2,DF},
Marija Zdravkovic^{1,2,EF}

¹ Faculty of Medicine, University of Belgrade, Belgrade, Serbia

² Department of Surgery, University Medical Centre "Bezanijska Kosa", Belgrade, Serbia

Source of support: Departmental sources

Summary

Background:

Many different benign and malignant diseases can cause obstruction of the extrahepatic biliary duct. One of the more serious complications of biliary obstruction is cholangitis leading to emergency decompression. Anatomic variations are frequent in this region; however, it has rarely been reported that the extrahepatic bile duct is compressed by the arterial vessels.

Case Report:

We present the case of a 68-year-old woman who was admitted through the emergency department of our hospital with jaundice, abdominal pain and fever. Biochemical analyses of liver function showed increased value of AST (113 IU/L) and ALT (128 IU/L). Total bilirubin was 5.88 mg/dl, conjugated bilirubin was 3.00 mg/dl, and alkaline phosphatase was 393 IU/L. We performed abdominal ultrasound (US), magnetic resonance cholangiopancreatography (MRCP), and computed tomography (CT) imaging. Multislice CT angiography showed that the arterial ring of the common hepatic artery around the common bile duct (CBD) originated from the superior mesenteric artery. Cholecystectomy and intraoperative cholangiography were performed, as well as decompression and lavage of the biliary tree. *Escherichia coli* was identified from bile. Dissection of the hepatoduodenal ligament confirmed that the proper hepatic artery made a vascular ring around the CBD. Finally, a T tube was placed into the CBD. During 5 years of follow-up the patient has been without recurrent episodes of jaundice. In such cases dissection of the proper hepatic artery from the common hepatic duct is the treatment of choice.

Conclusions:

If there are signs of cholangitis decompression and lavage of the biliary tree with "T", drainage should be performed. Vascular malformations should be considered as a possible cause of extrahepatic biliary obstruction. CT angiography may be helpful in identifying these malformations.

key words:

cholangitis • benign obstructive jaundice • vascular malformation

Full-text PDF:

<http://www.medscimonit.com/fulltxt.php?ICID=881888>

Word count:

825

Tables:

–

Figures:

1

References:

14

Author's address:

Darko Zdravkovic, Department of Surgery, University Medical Centre "Bezanijska Kosa", Belgrade Faculty of Medicine, University of Belgrade, Serbia, e-mail: majadare@eunet.rs

BACKGROUND

Many different benign and malignant diseases can cause an obstruction of the extrahepatic biliary system. Anatomic variations are frequent in this region; however, it has rarely been reported that the extrahepatic bile duct is compressed by arterial vessels. One of the more serious complications of biliary obstruction is cholangitis, eventually leading to emergency decompression.

We present a rare case of benign biliary obstruction complicated with cholangitis caused by the compression of the common bile duct by an arterial ring formed by the common hepatic artery which originated from the superior mesenteric artery.

CASE REPORT

A 68-year-old woman was admitted through the emergency department of our hospital with jaundice, abdominal pain, vomiting and fever. Biochemical analyses of the liver functions showed increased values of AST (113 IU/L) and ALT (128 IU/L). Total bilirubin was 5.88 mg/dl, conjugated bilirubin was 3.00 mg/dl and alkaline phosphatase was 393 IU/L.

An abdominal ultrasonography and a magnetic resonance cholangiopancreatography (MRCP) revealed a distended gallbladder and dilation of the intrahepatic and extrahepatic bile ducts with unknown cause of the obstruction. For further evaluation we performed multi-slice computed tomography (MDCT) imaging, which showed an arterial ring formed by the common hepatic artery which originated from the superior mesenteric artery (Figure 1).

Accordingly, operative treatment was indicated. The operative approach was through a right subcostal incision. A cholecystectomy was done as well as an intraoperative cholangiography. Extraluminal compression was confirmed. The dissection of the hepatoduodenal ligament showed that the common hepatic artery was crossing the common bile duct posteriorly, and then laterally, anteriorly and medially, making an arterial ring around the CBD. After dissection, the proper hepatic artery became mobile and detached from the CBD. The infected bile content was evacuated from the CBD and sent to the bacteriology lab, where *Escherichia coli* was identified. A lavage of the biliary tree was performed and a T tube was placed into the CBD. Control cholangiography through the T tube was normal. During 5-year follow-up the patient has been without any recurrent episodes of jaundice.

DISCUSSION

Various benign or malignant pathological entities can cause biliary obstruction.

Benign conditions include stones, Mirizzi's syndrome, post-operative stricture, polyps and anatomic variations and anomalies [1–3]; malignant conditions include metastasis in the lymph nodes, as well as tumors of the CBD, the head of the pancreas and the papilla Vateri.

Anatomic variations of the biliary tract are common, with vascular anomalies frequently playing an important role.

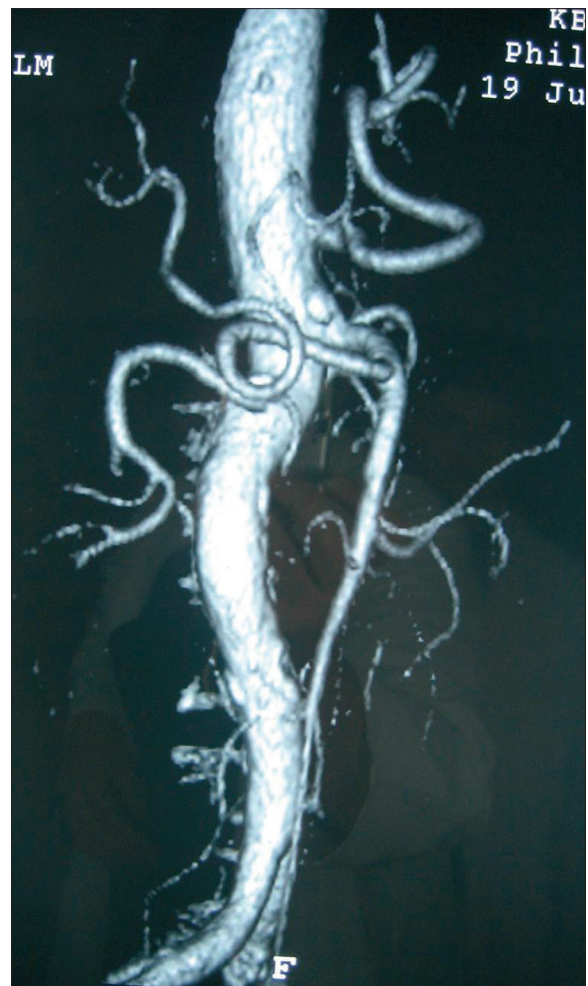


Figure 1. CT angiography of the abdominal aorta and its branches – arterial ring of the proper hepatic artery is clearly visible.

Koops [4] analyzed 604 angiographic specimens and showed a normal anatomy of the hepatic artery in 79.1% of his sample, whereas anomalous anatomies of this artery were noticed in 20.9% of cases. Anatomically, the branches of the common hepatic artery are positioned closely to the extrahepatic bile ducts. Miyashita [5] was the first to reveal a case of bile duct obstruction due to posterior compression of the extrahepatic duct by the hepatic artery, in contrast with most cases, where the hepatic artery crosses the extrahepatic duct anteriorly [6].

Luttwak and Schwarts first described jaundice due to an obstruction of the common hepatic duct by an aberrant artery – a celiac artery – in 1961 [7]. In the English literature, Tsuchiya first (1984) described 2 cases of jaundice due to compression by the right hepatic artery [8]. Aneurysm of the hepatic artery can also cause obstructive jaundice [9]. Dusanovic et al. reported a missing right branch of the hepatic artery that was replaced by 2 segmental arteries, so that these segmental arteries formed an arterial ring around the common hepatic duct, thus completely encircling it, but without jaundice [10]. We are reporting a case complicated with symptoms of cholangitis, of a complete arterial ring around the CBD caused by the proper hepatic artery which originated from the superior mesenteric artery. Baek

et al. [11] described obstructive jaundice due to compression of the common bile duct by the hepatic artery which originated from the gastroduodenal artery. Watanabe [12] classified compression of bile ducts into the lateral type, in which the bile duct is compressed by the artery lateral to it, and the transverse type, in which the bile duct is compressed by the artery crossing it. We believe a third type should be added, in which the artery (in our case the proper hepatic artery which originated from mesenteric superior artery) makes a ring around the CBD.

The accurate assessment of the presence, level and cause of extrahepatic biliary obstruction requires the use of different imaging modalities [13] including transabdominal US, CT, MRCP, ERCP and PTC. Conventional or CT (as in our case) angiographies will diagnose vascular malformations. In such cases, the dissection of the proper hepatic artery from the CBD is the treatment of choice. If there are signs of cholangitis, decompression and lavage of the biliary tree with T drainage should be performed. The prognosis is very good and no recurrence of obstructive jaundice has been reported.

CONCLUSIONS

Vascular malformations should be considered as a possible cause of extrahepatic biliary obstruction, jaundice and cholangitis.

REFERENCES:

1. Takehara H, Komi N, Okada A et al: Unusual cases of benign stricture of the biliary tract. *Tokushima J Exp Med*, 1992; 39(3-4): 135-43
2. Kossak J, Janik J, Debski J et al: Pseudoaneurysm of the gastroduodenal artery as a cause of obstructive jaundice. *Med Sci Monit*, 2001; 7(4): 759-61
3. Tsalis KG, Zacharakis E, Kirou IE et al: Mirizzi syndrome with a fistula at the confluence of the hepatic ducts. *Med Sci Monit*, 2009; 15(3): CS54-57
4. Koops A, Wojciechowski B, Broering DC et al: Anatomic variations of the hepatic arteries in 604 selective celiac and superior mesenteric angiographies. *Surg Radiol Anatomy* 2004; 26: 239-44
5. Miyashita K, Shiraki K, Ito T et al: The right hepatic artery syndrome. *World J Gastroenterol*, 2005; 11: 3008-9
6. Ju JW, Kim MC, Kim YH et al: Hepatolithiasis due to compression of the common hepatic duct by right hepatic artery. *Korean J Hepatobiliary Pancreat Surg*, 2000; 4: 241-45
7. Luttwak EM, Schwartz A: Jaundice due to obstruction of the common duct by aberrant artery: demonstration of celiac anomaly by translumbar aortography and simultaneous choledochogram. *Ann Surg*, 1961; 153: 134-37
8. Tsuchiya R, Eto T, Harada N et al: Compression of the common hepatic artery by the right hepatic artery in intrahepatic gallstones. *World J Surg*, 1984; 8: 321-26
9. Mazziotti S, Blandino A, Gaeta M et al: Hepatic artery aneurysm, an unusual cause of obstructive jaundice: MR cholangiography findings. *Abdom Imaging*, 2003; 28: 835-37
10. Dusanović AM, Ignjatović DM, Knezević PA et al: Arterial ring encircling the bile duct with coexisting anomalous liver irrigation. *Dig Surg*, 1999; 16: 72-75
11. Baek YH, Choi SR, Lee JH et al: Obstructive jaundice due to compression of the common bile duct by right hepatic artery originated from gastroduodenal artery. *Korean J Gastroenterol*, 2008; 52: 394-98
12. Watanabe H, Iwase H, Sugitani M et al: Compression of the common bile duct by the posterosuperior pancreaticoduodenal artery: case report. *Abdom Imaging*, 2005; 30: 214-17
13. Mustafa AM, Pawlak J, Cieszanowski A et al: Imaging techniques in patients with biliary obstruction. *Med Sci Monit*, 2000; 6(6): MT1197-202
14. Prokop M: Multislice CT angiography. *Eur J Radiol*, 2000; 36: 86-96