

Original Article
Clinical Pathology



Investigation of chlamyphilosis from naturally infected cats

Madarina Wasissa ¹, Fajar Budi Lestari ^{2,3}, Alfarisa Nururrozi ⁴,
Ida Tjahajati ^{2,4}, Soedarmanto Indarjulianto ⁴, Siti Isrina Oktavia Salasia ^{1,*}

¹Department of Clinical Pathology, Faculty of Veterinary Medicine, Universitas Gadjah Mada, Yogyakarta 55281, Indonesia

²Department of Bioresources Technology and Veterinary, Vocational College, Universitas Gadjah Mada, Yogyakarta 55281, Indonesia

³Interdisciplinary Program of Biomedical Sciences, Faculty of Graduate School, Chulalongkorn University, Bangkok 10330, Thailand

⁴Department of Internal Medicine, Faculty of Veterinary Medicine, Universitas Gadjah Mada, Yogyakarta 55281, Indonesia

 OPEN ACCESS

Received: May 6, 2021

Revised: Jul 10, 2021

Accepted: Jul 16, 2021

Published online: Aug 3, 2021

*Corresponding author:

Siti Isrina Oktavia Salasia

Department of Clinical Pathology, Faculty of Veterinary Medicine, Universitas Gadjah Mada, Jl. Fauna 2, Karangmalang, Depok, Sleman, Yogyakarta 55281, Indonesia.
E-mail: isrinasalasia@ugm.ac.id

Parts of the contents of this article were presented in the 1st International Conference of Advanced Veterinary Science and Technologies for Sustainable Development (ICAVESS, 28-29 March 2021) organized by the Faculty of Veterinary Medicine Gadjah Mada University, Indonesia.

© 2021 The Korean Society of Veterinary Science

This is an Open Access article distributed under the terms of the Creative Commons Attribution Non-Commercial License (<https://creativecommons.org/licenses/by-nc/4.0>) which permits unrestricted non-commercial use, distribution, and reproduction in any medium, provided the original work is properly cited.

ABSTRACT

Background: *Chlamydomphila felis*, formerly known as *Chlamydia psittaci* var. *felis*, is frequently associated with ocular, respiratory, and occasionally reproduction tract infections. Even though the infection is sometimes asymptomatic, it potentially results in a latent immunosuppressive infection.

Objective: This study aimed to identify occurrences of feline chlamyphilosis, rarely reported in cats in Indonesia.

Methods: The observation was conducted in three cats with clinical signs of *Cp. felis* infection, particularly relapsing conjunctivitis. The cats' histories were recorded based on owners' information. Conjunctival swabs were sampled for cytology examination and molecular assay detection. A phylogenetic tree was generated using MEGA-X software to reveal group clustering. A post-mortem examination was performed on the cat that died during an examination.

Results: *Cp. felis* was detected in both cytological examination and polymerase chain reaction assay. The phylogenetic tree demonstrated that the *Cp. felis* isolated in this study clustered with several other isolates from the other countries. *Cp. felis* can be isolated from cats with different clinical manifestations and levels of severity. The chronic fatal infection demonstrated interstitial broncho-pneumonia under histopathological examination.






Conclusions: Molecular assay of *Cp. felis* is always recommended to obtain a definitive diagnosis of feline chlamyphilosis since the disease can have various clinical manifestations. Even though it may be subclinical and is often not fatal, an infected cat may be a carrier that could spread the pathogen in the surrounding environment. Serious disease management is suggested to avoid high costs associated with regularly relapsing disease.

Keywords: Cat; feline chlamyphilosis; *Chlamydomphila felis*; co-infection; conjunctivitis

INTRODUCTION

Chlamydomphila felis (*Cp. felis*), formerly *Chlamydia psittaci* var. *felis*, is frequently associated with ocular, respiratory, and occasionally reproduction tract infection [1]. The pathogen is a

ORCID iDs

Madarina Wasissa 
<https://orcid.org/0000-0001-6056-7189>
Fajar Budi Lestari 
<https://orcid.org/0000-0002-9684-5344>
Alfarisa Nururrozi 
<https://orcid.org/0000-0001-9605-1731>
Ida Tjahajati 
<https://orcid.org/0000-0001-8554-2893>
Soedarmanto Indarjulianto 
<https://orcid.org/0000-0002-0945-6325>
Siti Isrina Oktavia Salasia 
<https://orcid.org/0000-0003-4171-4256>

Funding

This study was funded by Pendidikan Menuju Doktor untuk Sarjana Unggul (PMDSU) Scholarship No. 2185/UN1/DITLIT/DIT-LIT/PT/2020 from the Ministry of Education and Culture of the Indonesian Government for Madarina Wasissa. Support for Fajar Budi Lestari was provided by Beasiswa Pendidikan Pascasarjana Luar Negeri (BPP-LN) Scholarship from the Ministry of Education, Culture, Research and Technology of the Indonesian Government.

Conflict of Interest

The authors declare no conflicts of interest.

Authors Contributions

Conceptualization: Salasia SIO, Wasissa M;
Investigation: Wasissa M, Lestari FB, Nururrozi A;
Formal analysis: Wasissa M, Lestari FB, Nururrozi A;
Funding acquisition: Salasia SIO;
Supervision: Salasia SIO;
Writing - original draft: Wasissa M, Lestari FB;
Writing - review & editing: Tjahajati I, Indarjulianto S, Salasia SIO.

member of *Chlamydiales*, in which the bacterial membrane contains major outer membrane proteins (MOMPs) and polymorphic outer membrane proteins (POMPs) [2]. *Cp. felis* cannot survive outside the host and is transmitted directly by host-to-host contact [3]. Additionally, evidence of zoonotic transmission from animal to human has been mentioned in several reports related to ocular conjunctivitis in humans [4,5]. Even though the pathogen's characteristics are well known, the disease still frequently occurs. Hence, a study of *Cp. felis* is needed to develop new strategies for the management or control of chlamyphilosis.

The main characteristics of *Cp. felis* infections are ocular conjunctivitis and upper respiratory disease. In cats, conjunctivitis and upper respiratory disorder are also related to several other infectious pathogens, including feline herpesvirus type 1 (FHV-1), feline calicivirus, and *Mycoplasma* spp. [1]. Therefore, clinical diagnosis in the absence of sufficient laboratory findings is challenging. Improper treatment may worsen the host's condition and result in higher medical costs. Furthermore, an underdiagnosed asymptomatic cat will be a pathogen carrier that can spread the disease more widely. Ocular swabs are generally used to diagnose *Cp. felis* infection, but a polymerase chain reaction (PCR)-based technique is preferred for diagnosis [2].

This report highlights disease manifestation and pathogen species-specific detection. It reveals the disease's occurrence and existence based on molecular-level evidence. Molecular detection is helpful for species identification and proof of pathogen presence. Herein, it provides information on the occurrence of chlamyphilosis in cats in Indonesia. The result of this investigation may increase concern and awareness levels regarding its zoonotic potential.

MATERIALS AND METHODS

Samples and clinical signs

The patient's data, specimen samples, and publication permission were obtained with the owners consent. This study was also a part of feline infectious peritonitis (FIP) research project specifically related to secondary infection; hence all conducted procedures were approved and supervised by the Faculty of Veterinary Medicine Universitas Gadjah Mada (UGM) Ethical Clearance Committee (005/EC-FKH/06/2017).

The included patients were two cats under 2-years-old (local breed, male cats, weighing 0.9 kg and 1.2 kg) and one 5-year-old, local breed, female cat, weighing 3 kg. The patients were admitted to the UGM Veterinary Medicine Animal Clinic after showing recurrence of eye disorders. After a full examination and relevant sampling, the patients were treated with 10 mg/day oral doxycycline for 4 weeks. A cat with mild clinical signs (**Fig. 1A**) showed improvement, while the two other cats with severe conditions (**Fig. 1B and C**) did not survive.

The clinical signs of chlamyphilosis, including ocular and upper respiratory disorders, have been previously described [1], [2]. Specimen samples from ocular conjunctival swabs were obtained from three clinically suspected chlamyphilosis cat patients with relapsing conjunctivitis. The ocular conjunctival swab was collected in a sterile tube containing 0.9% NaCl and used for cytological assessment and PCR assay. The moribund patient with severe manifestations was subsequently necropsied. A post-mortem and a histological examination of lung tissue were performed.

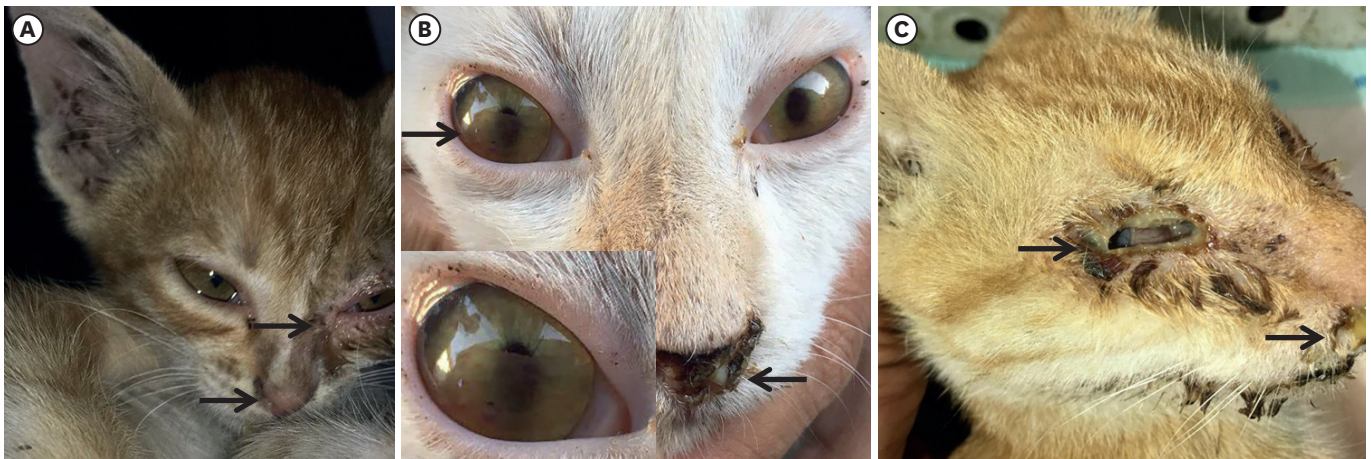

Fig. 1. *Chlamydomphila felis* isolated from cats with different clinical manifestations. (A) Unilateral conjunctivitis with muco-purulent ocular and nasal discharge (arrows). (B) Corneal opacity and purulent nasal discharge. (C) Unilateral eye-globe rupture with purulent ocular and nasal discharge.

***Cp. felis* detection**

The cytological examination was performed using May-Grünwald-Giemsa staining to evaluate cellular composition. *Cp. felis* is identified as basophilic, bright magenta stained, round to oval inclusion bodies of various sizes in epithelial cells [6,7].

The DNA extraction was performed from the conjunctival swabs specimens using a commercial extraction kit (PureLink Genomic DNA Kits, Invitrogen, USA) and following the manufacturer's guidelines. Molecular detection was conducted following previously described methods [8,9] to amplify the conserved region of the chlamydial outer membrane protein gene (277 base pairs).

The phylogenetic tree was generated using MEGA-X software to identify the clustering of the study isolates with other isolates. Multiple alignments of each segment were performed using ClustalW, and maximum-likelihood phylogenetic trees were constructed. The best substitution gene models were determined based on the corrected Bayesian information criterion value as implemented in MEGA-X. The model used in this study was Tamura 3-parameter (T92). The reliability of the branching order was estimated from 1000 bootstrap replicates.

RESULTS

Cp. felis was detected in all three cats with clinically suspected feline chlamydophilosis. During the examinations, the cats showed conjunctivitis with inflammation of conjunctival tissue that showed redness and swelling with or without ocular discharge. Interestingly, in this study keratitis characterized by corneal opacity was observed in one cat, and a whole eye-globe rupture accompanied by a purulent discharge accumulation was observed in another (**Fig. 1**). According to the owner's information, the eye-globe rupture had been observed when the cat was rescued. The cats were admitted to animal clinics after showing severe respiratory disorders. Other general clinical signs, including lameness and inappetence for days, were recorded.

Basophilic, oval intra-cytoplasmic inclusion of ocular epithelial cells was observed in the cytological results of two specimens (**Fig. 2**). The inclusions were easily visualized as dark

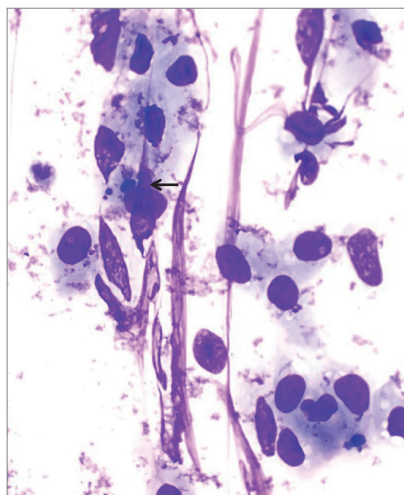


Fig. 2. Ocular conjunctiva epithelial cell contains basophilic, intra-cytoplasmic inclusion body of *Chlamydomphila felis* (Giemsa staining, 100 \times).

purple, round to granular shapes of various sizes. However, inclusions were absent in one sample, which only exhibited degenerated neutrophils and abundant coccus bacteria cells.

Molecular detection using PCR assay and gene sequencing supported evidence of *Cp. felis* infection in the three cat patients with suspected chlamyphilosis. In addition, the generated phylogenetic tree demonstrated that the *Cp. felis* isolates in this study clustered with other *Cp. felis* isolates from other countries (**Fig. 3**). The study's isolate sequences were submitted to the GenBank database with accession numbers MW720855, MW720856, and MW720857.

A post-mortem examination was performed in the cat that died during examination. Notable pathological changes were observed in lung tissue, indicating interstitial-bronchopneumonia (**Fig. 4**) characterized by thickening of interstitial alveolar septa by inflammatory cells infiltration and an inflammatory exudate within the bronchial tissue.

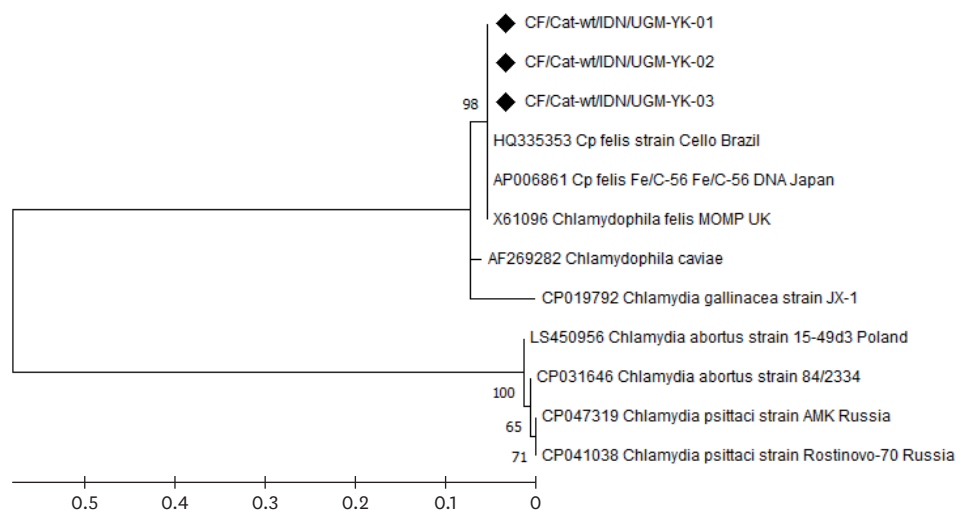


Fig. 3. Phylogenetic tree of *Chlamydomphila felis* isolated in this study (\blacklozenge) compared to several *Chlamydia* spp. from other countries and based on 277 bp nucleotide sequences of the outer membrane protein gene.

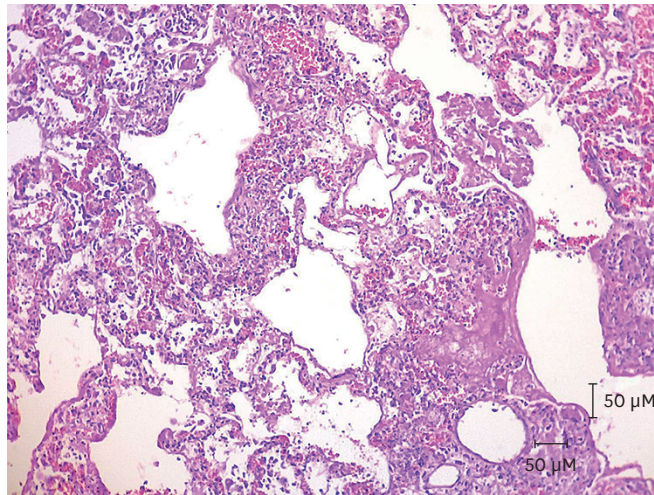


Fig. 4. A photomicrograph of lung tissue indicates interstitial-branchopneumonia is characterized by thickening of interstitial alveolar septa and infiltration of inflammatory cells (hematoxylin and eosin staining, 10 \times).

DISCUSSION

The three cat patients came from different cat houses; however, they had similar living conditions and environmental backgrounds, typical of high-population, multi-age, and poor sanitation rescue shelters. According to the owners' information, the diseased cats were rescued stray cats with no vaccination records. Two of the three diseased cats were approximately 2-years-old, and one cat was older than two years and had been living in the shelter for more than a year. The shelter staff complained that the cat exhibited relapsing conjunctivitis and a respiratory disorder for the previous four to eight months.

According to a previous study, poor environmental conditions are associated with a high percentage of feline chlamydophilosis incidence [10]. The detection of *Cp. felis* in stray cats in a multi-cat environment supports previous evidence of a higher prevalence of chlamydophilosis in a multi-cat environment and in younger and stray cats [11,12]. In this study, *Cp. felis* was also detected in an older cat which was in a severe and fatal condition. It was assumed that chlamydophilosis was not the only disease of that cat as there was a possibility of co-infections. Additionally, clinical manifestation showed uncommon chlamydophilosis manifestations, including corneal inflammation involvement and whole eye-globe rupture.

According to a previous report, even though a chlamydial infection may occur with other pathogens, such co-infection is not significantly associated with the disease severity [10]. Corneal involvement in chlamydophilosis is not commonly observed; hence, it is assumed that a viral co-infection disease may be related to the observed manifestation. Based on several reports, an ocular disorder is sometimes associated with other diseases such as FIP caused by feline coronavirus (FCoV) [13,14]. However, in this study, the potential presence of FCoV was rejected due to the negative PCR assay and immunohistochemistry tissue staining results (data not shown). Furthermore, upper respiratory disease is closely related to ocular disease such as keratitis in FHV-1. Unfortunately, the presence of FHV-1 was not investigated in this study. It may be assumed that the recurrent and incidentally fatal manifestation of chlamydophilosis in one of the cats in this study was caused by an underdiagnosed pathogen

or co-infection disease. Therefore, clinical manifestations should be followed by laboratory tests aimed at gaining a definitive diagnosis.

The observed histopathological changes supported the initial diagnosis of suspected chlamyphilosis. Feline pneumonitis characterized with bronchiolitis, thickening of the septum, and infiltration of inflammation cells are typically observed in chlamyphilosis cats. However, it may be assumed that besides *Cp. Felis*, concomitant infections may be present. According to a previous report, severe feline pneumonitis is commonly observed in viral respiratory infections or in immunosuppressed hosts following bacterial intervention [15]. Additionally, *Cp. felis* can suppress a host's immune system, allowing other pathogens to complicate the initial *Cp. felis* infection. Therefore, due to the presence of overlapping manifestations, we suspect that the pathological manifestation in the sampled lung tissue of one of the cats was not solely caused by *Cp. felis*.

Routine cytological examination is a reliable diagnostic tool for detecting *Cp. felis* [16] since its morphological characteristics are easily recognizable. However, in subclinical or chronic cases, *Cp. felis* is rarely identified by cytological examination. Therefore, a molecular-level assay is suggested for application in clinically suspected *Cp. felis* patients due to its outstanding sensitivity and specificity [2,16,17].

The *Cp. felis* pathogen may result in severe disease and can gradually but significantly affect the host's immune system. Therefore, proper and early detection chlamyphilosis could help prevent spread of this potentially severe and fatal disease. This study reveals evidence of relapsing *Cp. felis* infections occurring in cats that live in a high-population shelter. The disease may become fatal and a burden without the proper treatment. An owner has suggested regular vaccination of cats with a commercially available multivalent vaccine product [3]. The results of this study may raise awareness of the potential severity of *Cp. felis* infections and increase the level of concern for human health due to the zoonotic potential *Cp. felis* [18], notably to cat owners and the surrounding environment.

ACKNOWLEDGMENTS

We thank Bernadetta Evi, DVM of Prosper Pet and Vet Animal Clinic, Arief Nurdiansyah, DVM, and staff in the Department of Internal Medicine UGM for their help in collecting and processing the samples.

REFERENCES

1. Sykes JE. Feline chlamydiosis. *Clin Tech Small Anim Pract.* 2005;20(2):129-134.
[PUBMED](#) | [CROSSREF](#)
2. Gruffydd-Jones T, Addie D, Belák S, Boucraut-Baralon C, Egberink H, Frymus T, et al. *Chlamydomphila felis* infection. ABCD guidelines on prevention and management. *J Feline Med Surg.* 2009;11(7):605-609.
[PUBMED](#) | [CROSSREF](#)
3. Scherk MA, Ford RB, Gaskell RM, Hartmann K, Hurley KF, Lappin MR, et al. 2013 AAEP feline vaccination advisory panel report. *J Feline Med Surg.* 2013;15(9):785-808.
[PUBMED](#) | [CROSSREF](#)
4. Wons J, Meiller R, Bergua A, Bogdan C, Geißdörfer W. Follicular conjunctivitis due to *Chlamydia felis*-case report, review of the literature and improved molecular diagnostics. *Front Med (Lausanne).* 2017;4:105.
[PUBMED](#) | [CROSSREF](#)

5. Hartley JC, Stevenson S, Robinson AJ, Littlewood JD, Carder C, Cartledge J, et al. Conjunctivitis due to *Chlamydomphila felis* (*Chlamydia psittaci* feline pneumonitis agent) acquired from a cat: case report with molecular characterization of isolates from the patient and cat. *J Infect.* 2001;43(1):7-11.
[PUBMED](#) | [CROSSREF](#)
6. Raskin R, Meyer D. *Canine and Feline Cytology*. 2nd ed. St. Louis: Saunders; 2010.
7. von Bomhard W, Polkinghorne A, Lu ZH, Vaughan L, Vögtlin A, Zimmermann DR, et al. Detection of novel chlamydiae in cats with ocular disease. *Am J Vet Res.* 2003;64(11):1421-1428.
[PUBMED](#) | [CROSSREF](#)
8. Buxton D, Rae AG, Maley SW, Thomson KM, Livingstone M, Jones GE, et al. Pathogenesis of *Chlamydia psittaci* infection in sheep: detection of the organism in a serial study of the lymph node. *J Comp Pathol.* 1996;114(3):221-230.
[PUBMED](#) | [CROSSREF](#)
9. Rampazzo A, Appino S, Pregel P, Tarducci A, Zini E, Biolatti B. Prevalence of *Chlamydomphila felis* and feline herpesvirus 1 in cats with conjunctivitis in northern Italy. *J Vet Intern Med.* 2003;17(6):799-807.
[PUBMED](#) | [CROSSREF](#)
10. Gonsales FF, Brandão PE, Melville PA, Zuniga E, Benites NR. *Chlamydia felis*: Lack of association between clinical signs and the presence of the cryptic plasmid. *Microb Pathog.* 2016;97:14-18.
[PUBMED](#) | [CROSSREF](#)
11. Wu SM, Huang SY, Xu MJ, Zhou DH, Song HQ, Zhu XQ. *Chlamydia felis* exposure in companion dogs and cats in Lanzhou, China: a public health concern. *BMC Vet Res.* 2013;9(December):104.
[PUBMED](#) | [CROSSREF](#)
12. Halánová M, Sulínová Z, Cisláková L, Trbolová A, Páleník L, Weisssová T, et al. *Chlamydomphila felis* in cats--are the stray cats dangerous source of infection? *Zoonoses Public Health.* 2011;58(7):519-522.
[PUBMED](#) | [CROSSREF](#)
13. André NM, Miller AD, Whittaker GR. Feline infectious peritonitis virus-associated rhinitis in a cat. *JFMS Open Rep.* 2020;6(1):2055116920930582.
[PUBMED](#) | [CROSSREF](#)
14. Malbon AJ, Meli ML, Barker EN, Davidson AD, Tasker S, Kípar A. Inflammatory mediators in the mesenteric lymph nodes, site of a possible intermediate phase in the immune response to feline coronavirus and the pathogenesis of feline infectious peritonitis? *J Comp Pathol.* 2019;166:69-86.
[PUBMED](#) | [CROSSREF](#)
15. McGavin MD. *Pathologic Basis of Veterinary Disease*, 4th ed. St. Louis: Mosby Elsevier; 2007.
16. Hillström A, Tvedten H, Källberg M, Hanås S, Lindhe A, Holst BS. Evaluation of cytologic findings in feline conjunctivitis. *Vet Clin Pathol.* 2012;41(2):283-290.
[PUBMED](#) | [CROSSREF](#)
17. Harley R, Herring A, Egan K, Howard P, Gruffydd-Jones T, Azuma Y, et al. Molecular characterisation of 12 *Chlamydomphila felis* polymorphic membrane protein genes. *Vet Microbiol.* 2007;124(3-4):230-238.
[PUBMED](#) | [CROSSREF](#)
18. Rodolakis A, Yousef Mohamad K. Zoonotic potential of *Chlamydomphila*. *Vet Microbiol.* 2010;140(3-4):382-391.
[PUBMED](#) | [CROSSREF](#)