

## Silicoproteino-tuberculosis: Three distinct entities or a unique entity: A case report and review of the literature

Ali Cheraghvandi<sup>1</sup>, Saeid Fallah Tafti<sup>2</sup>, Firouzeh Talischi<sup>3</sup>, Seyed Mohammad Seyedmehdi<sup>4</sup>, Elham Ghazanchaei<sup>5</sup>, Beheshteh Jebelli<sup>6</sup>, Mihan Pourabdollah<sup>7</sup>

Received: 2 Mar 2013

Accepted: 12 June 2013

Published: 15 Mar 2014

### Abstract

Silicosis is considered to be among the occupational lung diseases and associated with sandblasting, mining, quarrying and tunneling. Acute silicosis is usually progressive disease and despite treatment with corticosteroids it leads to cardio-respiratory failure and death. Alveolar silicoproteinosis is one of its acute presentations due to exposure to silica dust and lungs filling with proteinaceous material. Here, we have presented a 29 year old male sandblaster with the three conditions of acute silicosis, secondary alveolar proteinosis and pulmonary tuberculosis on four anti tuberculous medications who presented with respiratory distress.

**Keywords:** Silicotuberculosis; Silicosis; Pulmonary Alveolar Proteinosis; Tuberculosis, Drug-Resistant.

*Cite this article as:* Cheraghvandi A, Fallah Tafti S, Talischi F, Seyedmehdi S. M, Ghazanchaei E, Jebelli B, Pourabdollah M. Silicoproteino-tuberculosis: Three distinct entities or a unique entity: A case report and review of the literature. *Med J Islam Repub Iran* 2014 (15 Mar). Vol. 28:23.

### Introduction

Silicosis occurs in association with mining, quarrying and tunneling. Yet recently, sandblasting with purpose of abrasion and in preparing metal surfaces for painting, cleansing foundry castings and cleaning building exteriors has become an important etiology for silicosis (1-3). Acute silicosis is usually a progressive disease and despite treatment with corticosteroids it leads to death due to cardio-pulmonary causes and respiratory distress. One of the acute presentations of silicosis is alveolar silicoproteinosis which develops due to pulmo-

nary exposure to silica dust and consequent filling of lungs with proteinaceous material.

Silicotuberculosis is seen in 25% of patients with acute and classic silicosis and presents in chest radiography as irregular nodules or opacities and cavitations with rapid progression of disease (3). The prevalence of silicotuberculosis in South African gold-miners who were also Human immunodeficiency virus (HIV) positive is considerable (4,5). There are rare reports of association between silicotuberculosis and alveolar proteinosis. The latter condition which results from excessive accumu-

1. Assistant Professor, Lung Transplantation Research Center, National Research Institute of Tuberculosis and Lung Diseases (NRITLD), Shahid Beheshti University of Medical Sciences, Tehran, Iran. [cheraghvandi@yahoo.com](mailto:cheraghvandi@yahoo.com)

2. Professor Medicine, Nursing and Respiratory Health Management Research Center, National Research Institute of Tuberculosis and Lung Diseases (NRITLD), Shahid Beheshti University of Medical Sciences, Tehran, Iran. [saeid-ftafti@yahoo.com](mailto:saeid-ftafti@yahoo.com)

3. Assistant Professor, Chronic Respiratory Diseases Research Center, National Research Institute of Tuberculosis and Lung Diseases (NRITLD), Shahid Beheshti University of Medical Sciences, Tehran, Iran. [firouzeh\\_talischi@yahoo.com](mailto:firouzeh_talischi@yahoo.com)

4. (**Corresponding author**) Assistant Professor, Telemedicine Research Center, National Research Institute of Tuberculosis and Lung Diseases (NRITLD), Shahid Beheshti University of Medical Sciences, Tehran, Iran. [mseyedmehdi@gmail.com](mailto:mseyedmehdi@gmail.com)

5. MS in Nursing, Chronic Respiratory Diseases Research Center, National Research Institute of Tuberculosis and Lung Diseases (NRITLD), Shahid Beheshti University of Medical Sciences, Tehran, Iran. [el\\_gh2008@yahoo.com](mailto:el_gh2008@yahoo.com)

6. MS in Nursing, Chronic Respiratory Diseases Research Center, National Research Institute of Tuberculosis and Lung Diseases (NRITLD), Shahid Beheshti University of Medical Sciences, Tehran, Iran. [sam\\_jeb@yahoo.com](mailto:sam_jeb@yahoo.com)

7. Associate Professor, Pediatric Respiratory Diseases Research Center, National Research Institute of Tuberculosis and Lung Diseases (NRITLD), Shahid Beheshti University of Medical Sciences, Tehran, Iran. [mihanp@yahoo.com](mailto:mihanp@yahoo.com)

lation of surfactant lipoprotein is caused by defect in the cleansing properties of alveolar macrophages and in 5 to 10 percent of cases is secondary and mainly occurs in association with other underlying medical conditions specially blood cancers or defects in the immune system such as severe combined immunodeficiency syndrome (SCID) or hypogammaglobulinemias and is seen after transplantation as well (6). Patients with alveolar proteinosis are at risk for secondary infections with opportunist pathogens such as Aspergillosis, Nocardia and Mycobacterium Avium (6, 7, 8). The presented patient in this article was a case of acute silicosis accompanied by tuberculosis which clinically did not respond to first line treatment.

### Case report

The patient is a 29 year old sandblaster from Tehran with history of acute silicosis, pulmonary tuberculosis and secondary alveolar proteinosis on anti TB medications for a month and lung transplant candidate who presents with acute respiratory distress to our hospital. His respiratory symptoms have worsened in 10 days and in the past two days later was bed-bound. He denied fevers, chills or night sweats but produced small amounts of sputum. He also denied hemoptysis, and lost weight of 8 Kg in the two months with decreased appetite in few days. Two months prior to this admission, he was hospitalized in the TB ward with complaint of weakness, shortness of breath, cough and fever and chills. He also complained of headaches. He denied contact with a tuberculosis patient or any other medical conditions. Sputum smear was once positive for Acid Fast bacilli. He had undergone bronchoscopy and transbronchial biopsy and was diagnosed with silicosis and secondary alveolar proteinosis with an inflammatory necrotic lesion consistent with tuberculosis. Bronchoalveolar fluid lavage smear and biopsy showed numerous dust laden macrophages, squamous and columnar epithelial cells and was negative for malignancy. At this time, he was diag-

nosed with acutely exacerbated silicosis and secondary alveolar proteinosis. After

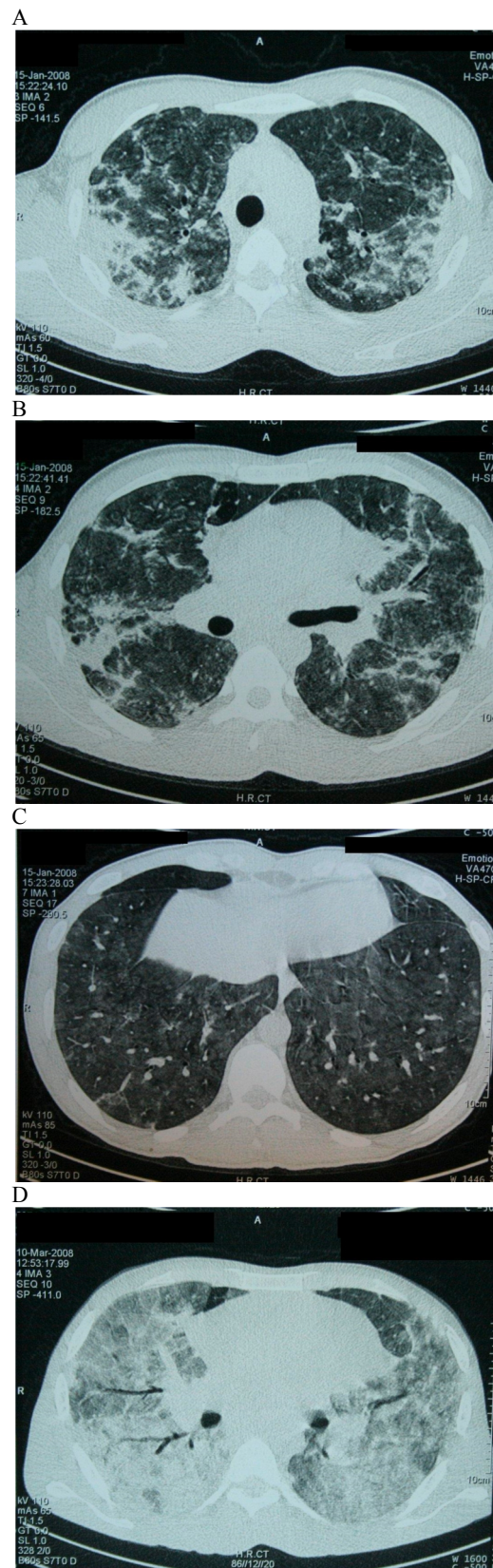


Fig. 1. Patient's chest CT scans, 2 month before last admission (a-c) and last admission (d).

Table 1. Patient Lab results

Laboratory Value	Patient's Values
WBC	9.8 cells/MicroL
Hgb	12.6 g/dl
Hct	38.5 %
Plt-Count	365*10 <sup>3</sup> /MicroL
Diff % Neut (seg)	92
MCV	80.2 fl
Blood Sugar	112
Urea	20 mg/dl
Creatinine	1.0 mg/dl
Na	130 Meq/Lit
K	4.8 Meq/Lit
Ca	9.0 mg/dl
Albumin	3.8 g/dl
ESR	92 mm/h
ABG	PH 7.477-PCO2 29.8-BE (-0.7) Bicarb 21.6-PO2 33.6- O2sat 69.7%
ADA (Serum)	19 U/L
Urinalysis	Negative
Sputum Microscopy	Negative*3 with 2+ reading on 1/7 smears for AFB from first hospitalization
BAL	Many dust laden alveolar macrophages, negative for malignancy AFB smear and PCR negative PCR for viral infection was positive for Adenovirus
BAL Total White Cell Count	100000

evaluation, he was placed in lung transplant list. He received anti TB medications and intravenous hydrocortisone. At presentation, his medications were isoniazid, ethambutol, rifampin, pyrazinamide and prednisolone. He was prevented from medication allergies. He was married, worked as a sandblaster and denied smoking or substance abuse. He did not have family history of any diseases.

On physical examination, the patient was in respiratory distress. Blood oxygen saturation on arrival was 55-60% and oxygenation with a reserve bag mask eventually improved oxygen measurement upto 90 to 95%. The patient had a temperature of 38.3 °C, pulse rate 160, respiratory rate 22 and blood pressure 120/80. He was cyanotic due to respiratory distress. No lymphadenopathy was found. Cardiac exam showed present heart sounds S1 and S2 with no murmurs. Rales in both lungs were found. Abdominal exam was soft, nontender with no organomegally. Clubbing and edema was not present. Cardiac, neurologic and abdominal exam were all normal.

High resolution computed tomography (HRCT) of the lungs showed bilateral alve-

olar ground glass opacities and consolidations prominently in mid upper zones with interlobular septal thickening. The patterns were noted to be characteristic but not diagnostic for pulmonary alveolar proteinosis with silicoproteinosis. In comparison with previous CT scan (two months prior) disease progression was noted (Fig. 1).

Laboratory values are shown in Table 1 and the report for radiology and pathology shown at the end of the report.

Sputum cultures, from previous hospitalization was negative for mycobacteria, BAL smear and polymerase chain reaction (PCR). He had negative TB cultures from this hospitalization as well.

The patient had spiked fevers up to 38.5°C and sweats during his hospital stay. Multiple arterial blood gases (ABG's) showed hypoxemia so oxygenation with reserve bag mask was administered. He was continued with TB medications and started on broad spectrum antibiotics clindamycin, Cefazidime. Parenteral hydrocortisone was administered for diagnosis of acute silicosis. Furthermore, the aggressive nature of the disease caused concern about pneumocystis carinii (PCP) and cotrimoxazole was administered. Medica-

tions were continued during hospital stay of 16 days. Sputum for bacteriology was collected and bronchoalveolar lavage done with BAL.

Bronchoalveolar lavage (BAL) microscopic study showed many dust laden alveolar macrophages and was negative for malignancy and diagnosis of accelerated (cellular) phase of silicosis associated with secondary alveolar proteinosis was made.

Upon negative sputum and BAL smear and cultures on discharge and according to previous positive pathology, the overriding diagnosis of tuberculosis was settled and medications switched to TB coverage. He was a candidate for therapeutic lung lavage but too ill to undergo it. He was discharged from hospital with an oxygen mask, TB medications and prednisolone 40mg/day.

Resistant tuberculosis and acute silicosis was in the differential diagnosis for this patient with sudden progression of disease (1).

Shortly in a few days, the patient returned to the hospital emergency department with respiratory failure and hypoxemia. SPO<sub>2</sub> on arrival was 55-60% with reserve bag mask. In attempt to intubate the patient, he suffered from cardiopulmonary arrest and died despite continued effort.

### Discussion

Acute silicosis is usually an advance disease. Despite treatment with corticosteroids, it leads to cardio-respiratory failure and death. Alveolar silicoproteinosis is one of the presentations of acute silicosis due to exposure to silica dust and lungs filled with proteinaceous material (3).

Pulmonary alveolar proteinosis (PAP) has been associated with TB. A PAP patient with resistant tuberculosis and without any improvement has been reported. The authors note extreme rareness of the association of PAP and TB in patients without a comprised immune status. They cite four cases reported, one of which was HIV positive and one who was a diabetic (9). Another article cites eight cases, whose primary diagnosis was TB and co-illness with

PAP was diagnosed at autopsy in four of them. In one case where PAP was the primary diagnosis, antitubercular drugs were ineffective until pulmonary lavage was done (10).

Our patient presented with a rapidly progressive picture of pulmonary disease, with acute silicoproteinosis and pulmonary (TB). Pertinent findings from this patient's previous and first hospitalization were a transbronchial lung biopsy specimen showing caseating granulomatous lesion with findings consistent with silicosis accompanied by alveolar proteinosis. Additionally, in a patient with rapid progression of disease, multi-drug resistant tuberculosis accompanied with acute silicosis in the differential diagnosis. Furthermore, infection with other mycobacteria needed to be in the differential diagnosis although culture results were not positive. Also, in this patient, persistent infection with tuberculosis could have exacerbated the pulmonary alveolar proteinosis (8,10).

Aspirating silica particles leads to two forms of silicosis acute and classic. The acute form presents as alveolar silicoproteinosis.

In alveolar silicoproteinosis, symptoms of progressive dyspnea during one month to a year are evidence of exposure to abundant amounts of silica dust. The classic form involves the interstitium of the lung in the forms of nodules or reticulations and is itself considered to have two main forms. One is simple or alveolar and presents as small round or irregular opacities on chest imaging. The other is complicated which involves massive fibrosis with large joining lesions evident on radiology (3,11).

Different pathophysiologies for alveolar proteinosis have led to division of patients into three groups. First is excessive accumulation of surfactant lipoprotein in the alveoli and resultant abnormal gas exchange and is considered the cause of primary acquired cases. Pathogenesis in the acquired form is by inhibition of the action of GM-CSF by blocking antibodies and resultant impairment of surfactant clearance

by alveolar macrophages. Treatment with GM-CSF is promising in the acquired but not other forms (6).

Second which involves congenital cases (2% of all cases) results from several genetic defects in the surfactant protein (SP)-B gene or the  $\beta$ c molecule of the GM-CSF receptor? Surfactant-C gene mutation has also been seen. Infants die within the first year of life despite medical treatment. Third are secondary cases (5-10% of total cases) which are associated with other underlying diseases especially hematopoietic and other malignancies (7,12).

On Histology, deposits of Periodic Acid Schiff (PAS)-positive proteinaceous material in the alveoli with absence of cellular infiltrate and normal intraalveolar septa are evident.

Coexisting autoimmune disorders (in 1.7% according to one study) including rheumatoid arthritis, positive smooth muscle antibodies, immunoglobulin. A nephropathy, multiple sclerosis and possible celiac disease are found in the patients. Elevated cholesterol level has also been found. The disease resembles Goodpasture's clinically, HLA associations and future therapeutic modalities such as plasmapheresis and immunosuppressive therapies targeting antibody production are among the considerations (6).

A key step in the pathogenesis of Mycobacterium tuberculosis is its first interaction with the host macrophage. This interaction is mediated by several receptors on the macrophage and in association with ligands on the bacterium including the complement receptors of CR1, CR3, and CR4, FC $\gamma$ Rs, mannose and glucan receptors, scavenger receptors and surfactant protein receptors A and D. Also CD43 may be important in providing stable interaction of mycobacteria with macrophages. This receptor has been isolated from patients with PAP (13).

Surfactant protein D binds to TB agent via the cell wall lipoglycan lipo-arabomannan (LAM) and reduces adherence and therefore opsonization of the mycobacteria (14).

PAP involves accumulation of surfactant,

defects in surfactant and GM-CSF genes, and antibodies made against the latter which is detrimental to macrophage activity and their processing of surfactant.

Our case was one with rapidly progressive disease which in a sandblaster agrees with the diagnosis of acute silicosis. Pathologic finding was consistent with this diagnosis. Yet, response to corticosteroid treatment was not seen and the patient's condition continued to deteriorate. In this situation, patient was also diagnosed with tuberculosis, resistant tuberculosis should be considered as well as infection with other mycobacteria (8,10). Finally, whole lung lavage was the only useful treatment for secondary PAP, and our patient was in an unstable condition to undergo this procedure.

In the modern era, whole lung lavage is performed using general anesthesia and single lung ventilation via a double-lumen endotracheal tube which is the treatment of choice for PAP. A total of 20L to 40L of saline is required for initially milky or turbid BAL fluid to clear fluid. Recently alternative techniques use fluid delivery by fiberoptic bronchoscopy (7).

Whole lung lavage is difficult and dangerous in most severely hypoxemic patients. Venoarterial extracorporeal membrane oxygenation (ECMO) has been used to avoid dangerous hypoxemia during lavage (15). Our first experience gained in our center National Research Institute for Tuberculosis and Lung Diseases (NRITLD) occurred in 2003 about an 11 year old child with idiopathic PAP where univent tracheal tube was used under general anesthesia.

In this patient, preparation for whole lung lavage was made but unfortunately due to irreversible respiratory distress and dismal condition, the procedure was not performed.

If the patient had probably shown up for follow up between his first and second hospitalizations, earlier whole-lung lavage could have been performed and he could have had better result. Finally, a few experiences in cases where TB has complicated

alveolar silicoproteinosis to have mostly a poor outcome for the patient.

### Acknowledgement

Authors would like to thank colleagues at Masih Daneshvari Hospital who helped prepare this manuscript.

### References

1. Silicosis and Silicate Disease Committee. Diseases associated with exposure to silica and nonfibrous silicate minerals. *Arch Pathol Lab Med* 1988; 112: 673-720.
2. Suratt P M, Winn W C, Brody A R, et al. Acute silicosis in tombstone sandblasters. *Am Rev Respir Dis* 1977; 115:521-9.
3. Chong S, Lee KS, Chung MJ, Han J, Kwon OJ, Kim TS. Pneumoconiosis: comparison of imaging and pathologic findings. *Radiographics* 2006; 26: 54-77.
4. Corbett E L, Churchyard GJ, Clayton T, Herselman P, Williams B, Hayes R, Mulder D, De Cock KM. Risk factors for pulmonary mycobacterial disease in South African gold miners A Case-Control Study. *Am J Respir Crit Care Med* January 1999; 159(1): 94-99.
5. Kleinschmidt I, Churchyard G. Variation in incidences of tuberculosis in subgroups of South African gold miners. *Occup Environ Med* 1997; 54(9): 636-641.
6. Seymour JF, Presneill JJ. Pulmonary alveolar proteinosis progress in the first 44 years. *Am J Respir Crit Care Med* 2002; 166:215-235.
7. Presneill J, Nakata K, Inoue Y, Seymour JF. Pulmonary alveolar proteinosis. *Clin Chest Med* 2004; 593-613.
8. Pereira-Silva JL, Marinno MM, Veloso TV, Coelho TCTC. Pulmonary alveolar proteinosis and tuberculosis in a diabetic patient-a rare or a seldom diagnosed association? *Braz J Infect Dis*. 2002 Aug; 6(4): 188-95.
9. Dragomir A, Ciontu M, Martius M, Munteanu I, Stoica R, Ulmeanu R, et al.. Superinfection with mycobacterium tuberculosis in a patient with pulmonary alveolar proteinosis. *Mædica J Clin Med* 2008; 3(1): 59.
10. Chaudhuri R, Prabhudesai P, Vaideeswan P, Mahashur AA. Pulmonary alveolar proteinosis with pulmonary tuberculosis. *Ind J Tub*. 1996; 43:27.
11. Beuchner HA, Ansari A. Acute silicoproteinosis. *Dis Chest* 1969; 55(4):274-284.
12. Poletti V, Costabel U, Casoni GL, Bigliuzzi C, Drent M, Olivieri D. Rare infiltrative lung diseases: A Challenge for Clinicians. *Respiration* 2004;71: 431-443.
13. Randhawa AK, Ziltener HJ, Merzaban JS, Stokes RW. CD43 is required for optimal growth inhibition of mycobacterium tuberculosis in macrophages and in mice. *J Immunol* 2005; 175:1805-1812.
14. Ferguson JS, Voelker DR, Mc Cormack FX, Schlesinger L. Surfactant protein D binds to mycobacterium tuberculosis bacilli and lipoarabinomannan via carbohydrate - lectin interactions resulting in reduced phagocytosis of the bacteria by macrophages. *J Immunol* 1999; 163:312-321.
15. Hou-rong C, Shu-yang C, Ling T, Yi-zhen H, Zhe-yan W, Bin C, et al. Pulmonary alveolar proteinosis treated with whole-lung Lavage utilizing extracorporeal membrane oxygenation: a case report and review of literatures. *Chinese Med J* 2004; 117(11): 1746-1749.