

Sternal fractures: “Operative treatment” should be kept in mind

Banu Yoldas, Hidir Esme¹, Mustafa Calik¹

Izmir Dr. Suat Seren Chest Diseases and Surgery Education and Research Hospital, Thoracic Surgery Department, Izmir, ¹Konya Education and Research Hospital, Meram, Konya

Isolated sternal fracture is a benign condition which generally heals with conservative treatment. But sometimes surgical intervention is necessary due to pain, other organ injury and union problems. There are several ways for repair; however, the best method is not yet defined. In this report, we presented two cases who were treated surgically for different indications with different suture materials. When anatomically correction can be achieved, using suture materials is a safe and effective method.

Key words: Repair, sternal fracture, surgery

INTRODUCTION

Sternal fractures are not so common as rib fractures. They usually get recovered without any surgical intervention. But whenever conservative treatment fails than surgery comes to order. Indications for surgical repair include severe pain, cosmetic problems, malunion, disunion, and compression to the heart.^[1-4] The best way of repair is controversial. Herein we report of two cases who were successfully treated without any sternal plates due to different surgical indications.

CASE REPORT

Case 1

A 55-year-old man was admitted to our hospital’s emergency service (Konya Education and Research Hospital, Konya, Turkey, 2009) after a motor vehicle accident. On physical examination, there was a hematoma on the sternum and he suffered from severe pain. Lateral chest X-ray [Figure 1] and computed tomographic (CT) scans [Figure 2] viewed sternal fracture and CT reported a 6 × 2 cm hematoma on the fractured sternum. Surgical repair was planned to relieve his pain. A vertical incision was preferred for exposure. The irregular ends of the fractured sides were resected

and sternum was sutured with steel wire. He is under control since December 2009.

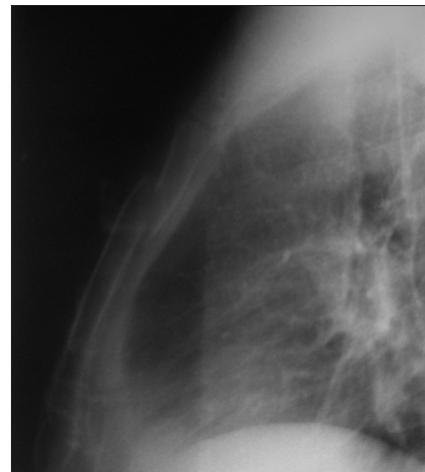


Figure 1: Displaced sternum fracture on lateral X-ray

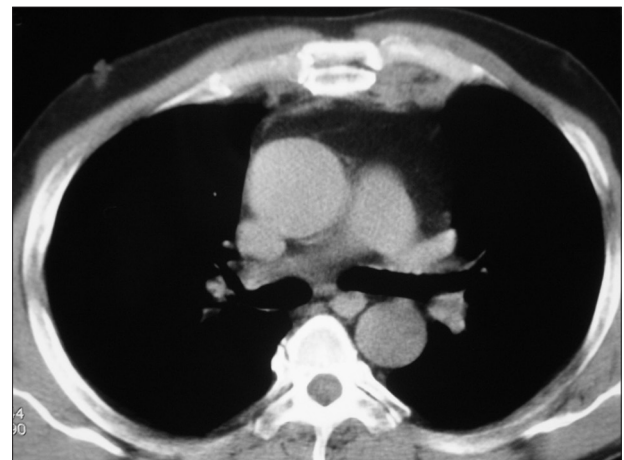


Figure 2: Overlapping fractured sides on computed tomography

Access this article online	
Quick Response Code:	Website:
	www.journals.mui.ac.ir/jrms
	DOI:

Address for correspondence: Dr. Suat Seren Chest Diseases and Surgery Education and Research Hospital, Thoracic Surgery Department, Yenisehir, Izmir. E-mail: banuaktin@yahoo.com

Received: 11-01-2012; **Revised:** 05-05-2012; **Accepted:** 11-05-2012

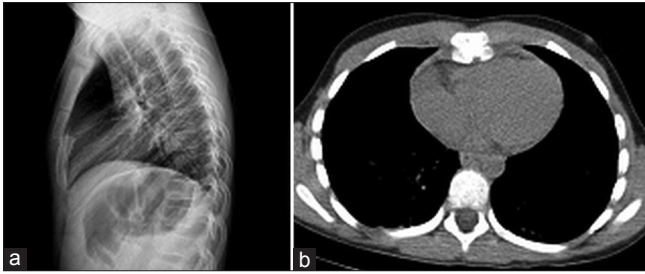


Figure 3: (a) Displaced sternum on lateral chest X-ray. (b) Computed tomography scan demonstrating cardiac compression and displaced sternum

Case 2

A 10-year-old boy was referred to our hospital (Konya Education and Research Hospital, Konya, Turkey, 2011) do to a disturbing pain on his sternum which was existed after a crush into his bicycle steering wheel. After his physical inspection posteroanterior and lateral chest X-rays were done demonstrating the displaced sternal fracture [Figure 3a]. On thorax computed tomography a transverse fracture and 8.5 mm pericardial effusion was detected [Figure 3b]. Echocardiography showed a minimal compression to the right ventricle of the heart due to the fractured and posteriorly depressed sternum. Because of this compression, his young age – taking into account malunion problems – and disturbing pain, surgical repair was planned. A vertical 4 cm. incision was done on the fractured segment, both sides of the fracture were elevated with sutures and a right angle clamp making them face to face and were sutured with loop polydioxanone (PDS) suture material. Control lateral chest X-ray showed the improved sternum [Figure 4]. The patient is on follow up without any problems and complications.

DISCUSSION

Costal fractures are the most common pathology detected in the patients with blunt thoracic injury applying emergency departments. Whereas sternal fractures are more rare as 10% in a group of 448 patients.^[5] Most sternal fractures are seen as simple, undisplaced fractures and do not require any surgical repair.^[6] Conservative treatment with nonsteroidal anti-inflammatory drugs – against pain – is sufficient in most of the cases. Moreover, according to some researchers it is not necessary to admit every patient with sternal fracture when there is not a severely displacement, complex analgesic requirement, and important comorbidities.^[6] But when pain cannot be controlled with pain killers and disables the patient or other conditions such as cosmetic reasons, nonunion, malunion, or cardiac compression, surgery is necessary.^[1-4] In one of our patients, indication for surgery was severe pain, in the other compression to the heart.

Sternal nonunion and pain is associated with several factors. Grosse *et al.*^[7] defined the magnetic resonance (MR) findings of sternal fractures of five patients and highlighted the usefulness of MR in this condition.

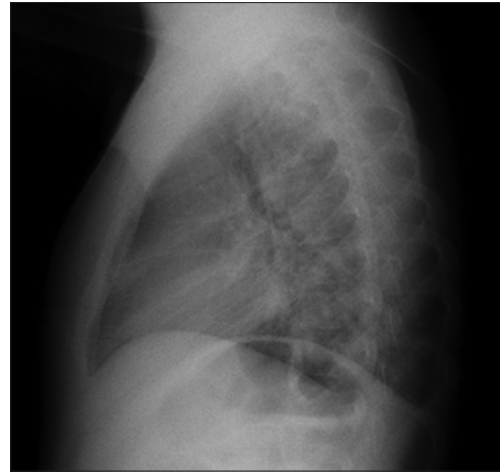


Figure 4: Lateral chest X-ray after the operation viewing improved sternum

Gill *et al.*^[8] offer to use ultrasound therapy before surgical alternatives which is a noninvasive and safe method. They reported a poststernotomy nonunion successfully treated with low intensity pulsed ultrasound.

Because of breathing and the movements of thoracic cavity healing of the sternum seems to be more difficult than of other fractures like radius or ulna.^[2] Movement of sternal fractures cause pain and discomfort during respiration. Chou *et al.*^[2] believe that fixation will minimize pain and prevent the development of pulmonary complications. In case one the pain was disturbing the patient making it difficult to breath, there was a hematoma on the sternum and the fracture was displaced.

There are different ways of sternal repair. Steel wire, suture materials, a seven hole aluminium plate, eight-holed Sternolock X plate, sternum-osteosynthesis plate, t-shaped plate are some of these methods.^[1-4] There is not a consensus on the best method of repair. Not only costs of surgery but also a successful treatment without any infection or a necessity of revision must be taken into account. The most cost-effective method seems like repair with suture materials or steel wire as we reported in our two cases. Unfortunately, some researchers are against to this idea thinking that this way of repair may be unsuccessful and cause secondary costs as revision surgery and mention the necessity to look for a more reliable method.^[3]

Hoschtitzky *et al.*^[11] emphasize some important points when choosing a sternal plate such as preferring a single plate rather than two and a plate which does not necessity removal after surgery adding a significant morbidity to the patient. Qeitsch *et al.*^[3] reported a removal of metalwork in six cases (%54) in their study due to pain. Because we were able to repair the fractures with suture and steel wire in our two patients we did not need to use any plates. In this case

the method of repair might be decided according to the state of the fracture, age of the patient, time interval till applying to a doctor and etiology of the fracture.

CONCLUSION

In conclusion, in displaced sternal fractures, compression to the heart should be kept in mind and necessarily controlled with echocardiography. Although most of the sternal fractures heal without any surgical intervention, in selected patients with severe pain, signs of compression or displaced fracture, surgery should be remembered. Repair with suture materials is a safe and cost-effective method to be considered.

REFERENCES

1. Hoschitzkya JA, Khalidb R, Aua J, Sampathb S. Open reduction and internal fixation of a non-united transverse sternal fracture. *Injury Extra* 2005;36:214-6.
2. Stephanie SC, Matthew JS, Michael SW. Use of SternaLock Plating System in Acute Treatment of Unstable Traumatic Sternal Fractures. *Ann Thorac Surg* 2011;91:597-9.
3. Queitsch C, Kienast B, Voigt C, Gille J, Jürgens C, Schulz A. Treatment of posttraumatic sternal non-union with a locked sternum-osteosynthesis plate (TiFix). *Injury* 2011;42:44-6.
4. Al-Qudah A. Operative Treatment of Sternal Fractures. *Asian Cardiovasc Thorac Ann* 2006;14:399-401.
5. Cangır AK, Nadir A, Akal M, Kutlay H, Özdemir N, Güngör A, *et al.* Toraks travması 532 olgunun analizi. *Turk J Trau, Ulusal Travma Derg* 2000;6(2):100-5
6. Velissaris T, Tang ATM, Patel A, Khallifa K, Weeden DF. Traumatic sternal fracture: Outcome following admission to a Thoracic Surgical Unit. *Injury* 2003;34:924-7.
7. Grosse A, Grosse C, Steinbach L, Anderson S. MRI findings of prolonged post-traumatic sternal pain. *Skeletal Radiol* 2007;36:423- 9.
8. Gill IPS, Montgomery RJ, Wallis J. Successful treatment of sternal non-union by ultrasound. *Interact CardioVasc Thorac Surg* 2009;9:389-90.

How to cite this article: Yoldas B, Esmel H, Calik M. Sternal fractures: "Operative treatment" should be kept in mind. *J Res Med Sci* 2012;17:814-6.
Source of Support: Nil, **Conflict of Interest:** None declared.