



Anesthetic management for dental surgery in a child with glycogen storage disease type IIIa: a case report

Buğra Aykenar, Nedim Çekmen

Baskent University, Faculty of Medicine, Department of Anesthesiology, Ankara, Turkey

Glycogen storage disease (GSD) is a group of inherited disorders, which result in the deficiency of enzymes involved in glycogen metabolism, leading to an accumulation of glycogen in various organs. Deficiency of amylo-1-6-glicosidase (debranching enzyme) causes glycogen storage disease type III (GSD III). The main problems that anesthesiologists face in patients with GSD III include hypoglycemia, muscle weakness, delayed awakening due to abnormal liver function, possible difficulty in airway, and cardiomyopathy. In the face of these difficulties, airway preparation and appropriate glucose monitoring and support during the fasting period are important. The doses of the drugs to be used should be calculated considering the increased volume of distribution and decreased metabolic activity of the liver. We present the case of a child with GSD IIIa who underwent dental prosedation under general anesthesia. She was also being prepared for liver transplantation. This case was additionally complicated by the patient's serious allergic reaction to eggs and milk.

Keywords: Anesthesia; Dental Procedure; Difficult Airway; Glycogen Storage Disease; Hypoglycemia; Milk Allergies.



This is an Open Access article distributed under the terms of the Creative Commons Attribution Non-Commercial License (<http://creativecommons.org/licenses/by-nc/4.0/>) which permits unrestricted non-commercial use, distribution, and reproduction in any medium, provided the original work is properly cited.



INTRODUCTION

Glycogen storage disease (GSD), an autosomal recessive genetic disorder, is a group of inherited disorders that result in deficiencies of enzymes involved in glycogen metabolism and lead to glycogen accumulation in various organs [1]. GSD type III (GSD III) is an autosomal recessive genetic disorder. Mutation of the AGL gene, which is located at 1p21.2, causes the formation of an abnormal, partially broken-down glycogen structure called limit dextrin. This abnormal glycogen cannot be further hydrolyzed and stored in hepatocytes, myocytes, and cardiomyocytes. Abnormal glycogen storage and impaired glycogenolysis in

hepatocytes cause hypoglycemia, especially during longer periods of starvation and hepatomegaly [2]; thus, cirrhosis and hepatocellular carcinoma may develop. Muscle weakness can occur in adolescence [3,4]. A patient with GSD can be challenging for an anesthesiologist. The main problems for anesthesiologists in patients with GSD include hypoglycemia, muscle weakness, delayed awakening due to abnormal liver function, difficult airway due to glycogen storage in the tongue, and cardiomyopathy. We present the case of a 4 years and 7 months old girl with GSD IIIa in addition to milk and egg allergy, who underwent dental procedures under general anesthesia prior to liver transplantation.

Received: August 18, 2022 • Revised: October 16, 2022 • Accepted: November 9, 2022

Corresponding Author: Buğra Aykenar, Baskent University, Faculty of Medicine, Department of Anesthesiology, Fevzi Çakmak Caddesi 10, Sokak No:45 Bahçelievler, 06490 Ankara, Turkey

Tel: +0312 203 68 68 - 4867 GSM: 05452013559 E-mail: aykenarbugra@gmail.com

Copyright© 2022 Journal of Dental Anesthesia and Pain Medicine

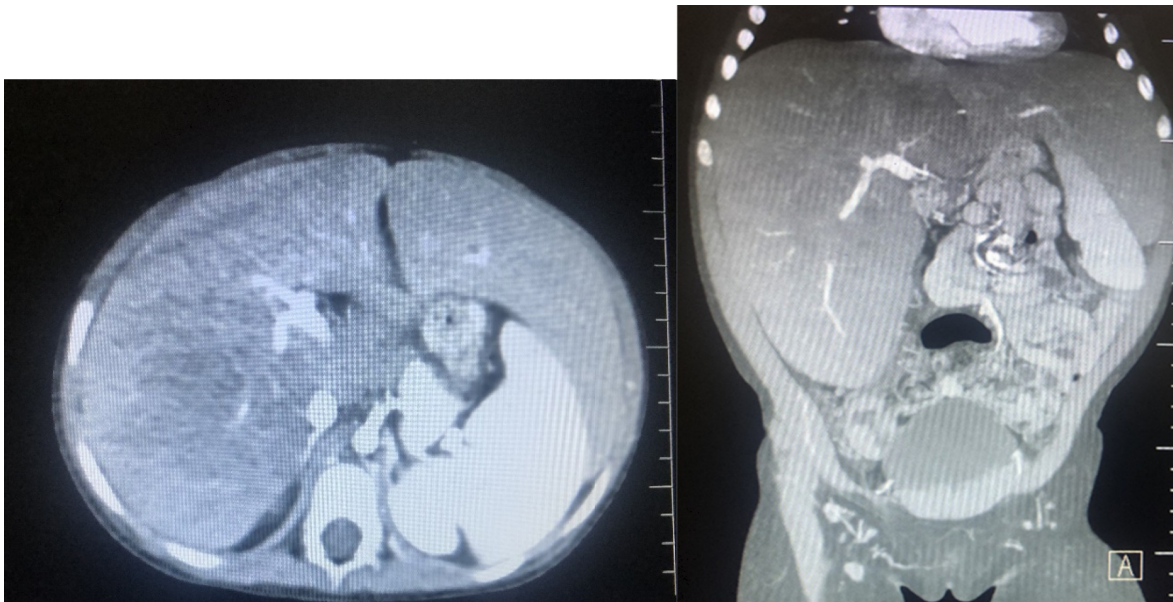


Fig. 1. Abdomen CT with contrast dye shows excess hepatosplenomegaly, with heterogenous hypodense lesions in liver. CT, computed tomography.

CASE PRESENTATION

1. Preoperative situation

A 38-week-old girl was diagnosed with GSD III after investigation because of prolonged jaundice and elevated transaminase levels at 3 weeks of age. She did not comply with her diet and had poor metabolic control; her growth and development were evaluated as insufficient. She had occasional gliding eyes, which were thought to be due to episodes of hypoglycemia. A pediatric gastroenterologist suggested liver transplantation because the growth of the patient, who was 4 years and 6 months old, was slow, the hepatic condition had progressed to cirrhosis, and the heart was not affected. The patient had no mental or motor deficits. During the preparation for liver transplantation, a dental procedure was planned for the patient. Because of poor cooperation and narrow mouth opening, the procedure was performed under general anesthesia. At the time of the dental procedure, she was 4 years and 7 months old, weighed 14 kg, and was 85 cm tall. She was regularly taking a 2×250 mg ursofalk suspension. Four months earlier, she had a positive COVID-19 PCR test, but was not hospitalized owing to

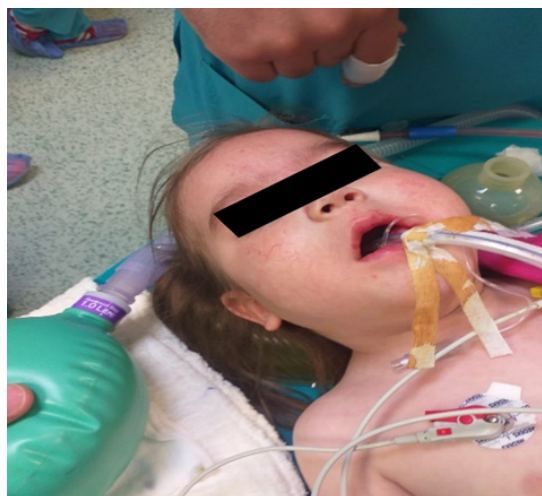

Fig. 2. Image shows intubated patient.

the lack of clinical findings of COVID-19. Widespread liver necrosis, fibrotic changes in the liver, and hepatosplenomegaly were reported on upper abdominal computed tomography (CT) (Fig. 1). Except for the pulmonary arteriovenous fistula without pulmonary hypertension, the echocardiographic findings were normal. She was referred to the Pediatric Allergy Department because of milk and egg allergies. They recommended that propofol and lactate-containing agents, such as prednol, should not be used during anesthesia.

2. Anesthetic management

The patient's American Society of Anesthesiologists (ASA) physical classification was class IV. Her hemoglobin was 10.9 g/dL, platelet count was $129 \times 10^3/\text{mm}^3$, and leukocyte count was $9.15 \times 10^3/\text{mm}^3$ at CBC. INR was 1.2, aPTT was 22 s, fibrinogen level was 169 mg/dL, and albumin level was 3.7 g/dL. Bilirubin and transaminase levels were high (T. Bil, 1.7 mg/dl; D. Bil, 0.97 mg/dl; AST, 646 U/L; and ALT, 308 U/L). Due to the risk of hypoglycemia, infusion of 40 ml/h 1/3 physiological serum prepared with 10% dextrose was administered during the preoperative fasting period and continued intraoperatively. Standard monitoring, including pulse oximetry, electrocardiography, and noninvasive blood pressure, was followed. After preoxygenation by 80 % O₂ for 3 min, general anesthesia was induced with ketamine 2 mg/kg, rocuronium 0.6 mg/kg, and 6% sevoflurane with fresh gas flow 3 l/min, FiO₂ 0.8. A cuffed endotracheal tube sized 4.5 mm diameter was used for intubation (Fig. 2). The expected difficulty in mask ventilation and airway instrumentation did not occur. The Cormack–Lehmann score was 3 on laryngoscopy, but no guides or gum bougies were required. After induction and intubation, arterial blood samples were collected for blood gas analysis. Findings were: pH, 7.37; PaO₂, 208 mmHg; PaCO₂, 44 mmHg; lactate level, 1.0 mmol/L; blood sugar, 97 mg/dL; and the electrolytes were within the normal range. She was ventilated in volume control mode: tidal volume, 8 ml/kg; frequency, 20 breaths/minute; PEEP, 3 cmH₂O; and FiO₂ 0.4. The dental procedure (compomer filling for tooth 74; extraction to teeth 64, 54, 51, 61, 62; Fissure sealant treatment for teeth 65, 55, 85, 75) took approximately 45 minutes. During the procedure, the vital signs were normal (heart rate 100-120/minute, blood pressure 100-80/55-50 mmHg, SpO₂ 98-100%, and ETCO₂ 32-40 cmH₂O). We used 10 mg of tramadol for analgesia and did not use any additional rocuronium doses. After the procedure, spontaneous ventilation recovered without neostigmine administration. When the spontaneous breath volume

exceeded 5 ml/kg after laryngeal secretions aspirated, the patient was extubated. No laryngospasm or bronchospasm was observed during extubation. The patient was transferred to the post-anesthesia recovery unit. After becoming conscious and recovering from muscle weakness, she was transported to a pediatric inpatient service.

3. Post-surgical course

In the pediatric inpatient service, 1 h after the operation, her blood pressure dropped to 50/30 mmHg. Despite the absence of dyspnea, pruritus, or urticaria, pediatricians suspected anaphylaxis and intramuscular adrenaline 0.3 mg, dexamethasone (8 mg), and a proton pump inhibitor was administered. Dextrose infusion continued until the postoperative 6th hour, and then the patient was started on regimen 2. They performed a latex prick allergy test and the results were negative. Two days after surgery, the patient was discharged in good condition with normal vital signs.

DISCUSSION

Pediatric patients in chronic hepatic failure are generally uncooperative for most medical procedures, especially at our institute. These patients may become more anxious about doctors and procedures over time, as they are exposed to several medical procedures during the perioperative period. To prevent this situation and failure of the procedure, it is our institutional policy to provide anesthesia to these patients during the procedures. Patients with GSD III have certain characteristics that anesthesiologists must consider. These patients may have a difficult airway and difficult mask ventilation because of glycogen storage in the tongue. Our patient did not have a difficult in mask ventilation. The patient's Mallampati score was 2. At laryngoscopy, the Cormack–Lehman grade was 3, but no auxiliary tool was used, and intubation was not difficult.

Hepatic dysfunction and insufficiency are the main

problems associated with GSD III. Hypoglycemia, cirrhosis, and altered pharmacodynamics of drugs can be observed in the perioperative period. Hypoglycemia, especially during longer periods of starvation, is the main concern in patients with GSD III when preparing them for surgery. These patients cannot use glycogen to maintain normal glucose levels. In the perioperative period, especially during the preoperative starvation period, intravenous dextrose infusion can maintain the blood glucose levels within the normal range. Close monitoring of blood glucose levels helps preventing hypoglycemia [5]. In our case, the anesthesia department and pediatric department used dextrose infusion during the perioperative period; no hypoglycemic measurements were recorded. Hepatomegaly can cause abdominal distention and gastroesophageal reflux. Tracheal aspiration may occur during anesthesia induction. Although our patient had abdominal distention, aspiration was not observed during anesthesia induction and laryngoscopy. Hepatic dysfunction can alter the metabolism of drugs and recovery from anesthesia may be delayed. Nerve stimulators can be used to monitor muscle function. We did not observe delayed emergence from anesthesia, although we used rocuronium for neuromuscular blockade. The nerve stimulator was not prepared in the operating room before the operation. However, due to the large number of cases in the operating room, the nerve stimulator was used in another operation. Determination of muscle strength by visual or physical examination may be interpreted as a false-positive recovery from muscle relaxant activity. At our institute, we do not have atracurium or cis-atracurium, which may be used more safely for hepatic or renal dysfunction [6]. Hepatic dysfunction due to GSD is another major problem during anesthesia. In the pediatric age group, the potential for hepatic injury with sevoflurane is expected to be negligible [7]. We used sevoflurane at induction and maintenance anesthesia. There were no alterations in liver function test results. In GSD III, cardiac dysfunction can develop at adolescence. Our patient's echocardiography showed no

cardiac pathology except for pulmonary AV fistula.

In conclusion, GSD poses challenges in anesthetic management. Strict monitoring of blood glucose levels and dextrose infusion during the perioperative period to prevent hypoglycemia are the most important aspects of anesthetic management. These patients may have a difficult airway; therefore, anesthesiologists must be prepared to manage any challenging situation. It must be noted that, altered liver functions can cause altered drug metabolism and delayed emergence from anesthesia. A multidisciplinary approach and collaboration among surgeon, anesthesiologist, and pediatrician is imperative when operating upon these patients.

AUTHOR ORCIDs

Buğra Aykenar: <https://orcid.org/0000-0002-3025-9326>

Nedim Çekmen: <https://orcid.org/0000-0002-6916-1772>

AUTHOR CONTRIBUTIONS

Buğra Aykenar: Project administration, Writing - original draft

Nedim Çekmen: Supervision, Writing - review & editing

DECLARATION OF INTERESTS: The authors declare no conflicts of interest.

CONSENT: Informed consent was obtained from the patient in this case report. This report was approved by the Institutional Ethics Committee of the Baskent University (Decision No. 22/153).

REFERENCES

1. Özer E. Anaesthetic management of a patient with glycogen storage disease type 1A. *Türkiye Klinikleri J Case Rep* 2018; 26: 171-3.
2. Anwar S, Rahaman AM, Matin A, Saha D, Rashid M. Glycogen storage disease type III-Cori's disease: a case report and review literature. *Bangladesh J Child Health* 2015; 39: 161-3.
3. Vetencourt YRH, Hernández SSM, Romero MF, Peñab

- RJS. Cori-Forbes disease. About two cases. CIMEJ 2020; 27: 3-8.
4. Gurneri C, Sprung J, Weingarten TN, Warner ME. Patients with glycogen storage diseases undergoing anesthesia: a case series. BMC Anesthesiol 2017; 17: 134.
 5. Biçer C, Öner M, Ülgey A, Adem B. Perioperative anesthetic management of a patient with glycogen storage Disease Type III. Erciyes Med J 2008; 30: 288-91.
 6. Bion JF, Bowden MI, Chow B, Honisberger L, Weatherley BC. Atracurium infusions in patients with fulminant hepatic failure awaiting liver transplantation. Intensive Care Med 1993; 19: S94-8.
 7. Ekmekçi P, Kazak Z, Pampal A, Kazbek K, Suer AH. Anesthesia for a patient with glycogen storage disease type Ia. Anestezi Dergisi 2010; 18: 172-4.