

Soft tissue mass of the chest wall as the sole manifestation of brucellosis in a 7-year-old boy

Mohammed S. Al-Ayed,^a Ibrahim Z. Bin-Hussain,^b Sami Al Hajjar,^b Saleh Al Nassar^c

From the ^aDepartment of Pediatrics, Armed Forces Hospital, Southern Region, Khamis Mushayt, Saudi Arabia, ^bDepartment of Pediatrics, ^cDepartment of Surgery, King Faisal Specialist Hospital and Research Centre, Riyadh, Saudi Arabia

Correspondence: Mohammed Al-Ayed, MD · Pediatric Infectious Diseases Armed Forces Hospital, Khamis Mushayt, Saudi Arabia · drmazayed2000@yahoo.com · Accepted: June 2010

Ann Saudi Med 2011; 31(3): 311-313

DOI: 10.4103/0256-4947.75584

We report the case of a child who presented with a subcutaneous mass on the left side of the chest wall of one month's duration. The mass was painful and increasing in size over time. He had a history of weight loss and a decrease in appetite, but no history of fever or trauma. He had ingested raw camel milk, but had no history of contact with animals. He was diagnosed by the standard tube agglutination titer and tissue culture for brucellosis, treated with surgery and three months of antibrucella antibiotics. The report includes a brief review of the current pediatric literature to familiarize pediatricians with this uncommon presentation.

Human brucellosis has a serious medical impact worldwide. The disease is caused by small, gram-negative, intracellular coccobacilli that are oxidase- and urease- positive. Transmission to humans occurs through the consumption of infected, unpasteurized animal-milk products, or through direct contact with infected animal parts (such as the animal placenta by inoculation through ruptures of the skin and mucous membranes), and rarely through the inhalation of infected aerosolized particles. Airborne transmission of brucellosis has been studied as a biologic weapon. It is a systemic disease that can infect any organ system, causing different clinical manifestations. Practically every organ and system of the human body can be affected in brucellosis—a fact that underscores the importance of including brucellosis in the differential diagnosis in areas of endemic disease, even if clinical features are not entirely compatible.

The serum agglutination test remains the most popular diagnostic tool for brucellosis. Titers above 1:160 are considered diagnostic in conjunction with a compatible clinical presentation. However, in areas where brucellosis is an endemic disease, using a titer of 1:320 as diagnostic may be more specific. A high prevalence in certain geographic areas is well recognized, although largely under-diagnosed. Human brucellosis affects all age groups. Childhood brucellosis generally exhibits a more benign course in terms of the rate and severity of

complications and the response to treatment, but isolated subcutaneous tissue involvement in children is rare.

CASE

A 7-year-old boy was referred to King Faisal Specialist Hospital and Research Centre with a complaint of a chest wall mass of 1-month duration to rule out malignancy. This mass was painful and increasing in size. He had a history of weight loss of about 1 kg and a decrease in appetite over the previous 1 month, but no history of fever or trauma. He had ingested raw camel milk, but had no history of contact with animals. Clinically he was comfortable, oriented, afebrile, not in pain or respiratory distress, with average body weight. His clinical examination was unremarkable except for a mass on the left chest wall, measuring about 54 cm, tender, firm, not fluctuating, mobile, with no skin changes. His laboratory workup was as follows: white blood cell count was $8.8 \times 10^9/L$, lymphocytes were 53%, absolute neutrophil was 42%, hemoglobin level was 9.9 g/dL and the platelet count was $332 \times 10^9/L$. The erythrocyte sedimentation rate was 54 mm/h. Alkaline phosphatase was 177 IU/L. CT of the chest revealed a left chest wall mass with a layering effect (**Figure 1**) with a subpleural mass retrosternally (**Figure 2**).

During surgery, a subfascial swelling filled with a whitish fluid with a small cavity was found. Histopathological examination showed mixed inflam-

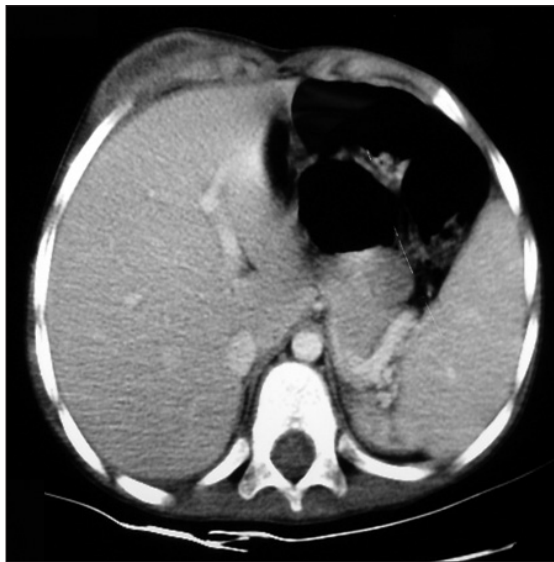

Figure 1. CT scan of the chest revealed a left chest wall mass with layering effects.

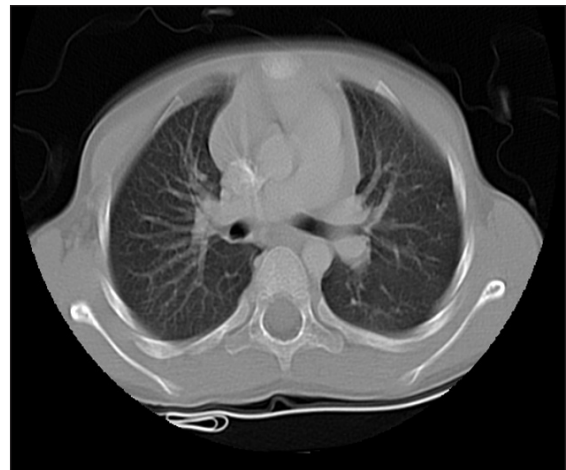


Figure 2. CT scan of the chest three months after treatment showed complete resolution of the mass.

mation with histiocytic/granulomatous reaction with a foci of necrosis. *Brucella* serology showed that the standard tube agglutination titer (STAT) was more than 20 480 at first; 2-mercaptoethanol was more than 1:20 480. Fastidious tissue culture was reported as gram-negative coccobacilli identified as *Brucella* species. A peripheral blood culture for fastidious organism was discontinued at day 2 of incubation because of growth of coagulase-negative staphylococci, which was considered a contaminant. The patient was started on *antibrucella* treatment including trimethoprim/sulfamethoxazole of standard formulation (80 mg trimethoprim/400 mg sulfamethoxazole) 2 tablets per day and rifampicin 20 mg/kg/d for 3 months.

Three months later, the patient was seen in the clinic in good condition; a repeat STAT was 1:5120. Repeated CT chest 6 months after the surgery was completely normal.

DISCUSSION

Brucellosis is a zoonotic disease that causes health problems in many areas worldwide,¹ especially in the Mediterranean basin, Arabian Peninsula, Indian sub-

continent and parts of Mexico and Central and South America.² Humans are accidental hosts. It is an occupational risk in adults working with livestock, while in children it is mainly foodborne.³ It is a systemic disease that can affect any part of the body,^{4,5} with nonspecific complaints, with a paucity of physical findings, and with an onset that can be insidious or acute. Symptoms begin 2 to 4 weeks after exposure—mainly fever, sweating, malaise, lethargy, anorexia and joint pains.⁶⁻¹⁴

Refusal to eat or to bear weight, failure to thrive and lassitude are the common complaints in young children. Brucellosis is a chronic granulomatous disease in which multisystem manifestations are well recognized. Although a case of brucellosis presenting with mass formation suggestive of tumor in soft tissue has been reported recently in an adult,¹⁵ to the best of our knowledge this is the first reported pediatric case of an isolated subcutaneous tissue mass as the sole manifestation of brucellosis, an unusual presentation of brucellosis in a child. In endemic areas, brucellosis should always be considered in the differential diagnosis of subcutaneous tissue mass even without any other constitutional symptoms.

REFERENCES

1. Ozgocmen S, Kocakoc E, Kiris A, Sen Y, Ardico_lu O. Calcaneal apophysitis due to brucellosis. *J Trop Pediatr* 2003;49:55-8.
 2. Texas Department of Health. Underreporting of four infect diseases by Texas hospitals. *Dis Prev News* 1993;53:1-3.
 3. Al-Orainey IO. Skin lesions in brucellosis: Report of two cases, *Ann Saudi Med* 1988;8.
 4. Al-Eissa YA. Unusual suppurative complications of brucellosis in children. *Acta Paediatr* 1993;82:987-92.
 5. Resendiz-Sánchez J, Contreras-Rodríguez A, López-Merino A, Bravo-Guzmán L, Valle-Valdez JG. Isolation of *Brucella melitensis* from an abscess on the left foot of a 3-year-old infant. *J Med Microbiol* 2009;58:267-9.
 6. Thapar M, Young EK. Urban outbreak of goat cheese brucellosis. *Pediatr Infect Dis* 1986;5:640-3.
 7. Feiz J, Sabbaghian H, Miralou M. Brucellosis due to *B. melitensis* in children. Clinical and epidemiologic observations on 95 patients studied in central Iran. *Clin Pediatr (Phila)* 1978;17:904-7.
 8. Street L, Grant WW, Alva JD. Brucellosis in childhood. *Pediatrics* 1975;55:416-21.
 9. al-Eissa YA, Kambal AM, al-Nasser MN, al-Habib SA, al-Fawaz IM, al-Zamil FA. Childhood Brucellosis: A study of 102 cases. *Pediatr Infect Dis J* 1990;9:74-9.
 10. Benjamin B, Annobil SH. Childhood brucellosis in southwestern Saudi Arabia: A 5-year experience. *J Trop Pediatr* 1992;38:167-72.
 11. Rowen JL, Englang JA. Brucellosis presenting with cough. *Pediatr Infect Dis J* 1995;14:721-2.
 12. Sharda DC, Lubani M. A study of Brucellosis in Childhood. *Clin Pediatr (Phila)* 1986;25:492-5.
 13. Gottesman G, Vanunu D, Maayan MC, Lang R, Uziel Y, Sagi H, et al. Childhood Brucellosis in Israel. *Pediatr Infect Dis J* 1996;15:610-5.
 14. Galanakis E, Bourantas KL, Leveidioton S, Lapatsanis PD. Childhood Brucellosis in North Western Greece: A retrospective analysis. *Eur J Pediatr* 1996;155:1-6.
 15. Karsen H, Akdeniz H, Irmak H, Buzgan T, Karahocagil MK, Kocak Z, et al. A brucellosis case presenting with mass formation suggestive for tumor in soft tissue. *South Med J* 2007;100:1137-9.
-