

MSK Ultrasound Bites: Tips and Tricks

The Use of MSK Ultrasound with Quadriceps Muscle Injury

Robert C Manske, PT, DPT, SCS, ATC, CSCS^{1, a}, Michael Voight, PT, DHSc, SCS, OCS, ATC, CSCS, FAPTA², Chris Wolfe, PT, DPT, OCS, Cert MDT², Phil Page, PT, PhD, ATC, CSCS, FACSM³

¹ Doctor of Physical Therapy Program, Wichita State University, ² School of Physical Therapy, Belmont University, ³ Doctor of Physical Therapy Program, Franciscan University

Keywords: quad tendon, MSK ultrasound, knee imaging

<https://doi.org/10.26603/001c.68077>

International Journal of Sports Physical Therapy

Vol. 18, Issue 1, 2023

Quadriceps muscle injury is a common occurrence, especially among athletes. While a careful history and a thorough physical examination are important steps in the assessment of quadriceps muscle pathology, it is still difficult to differentiate the type and severity of the pathology. Because of this difficulty, musculoskeletal ultrasound (MSK-US) is an invaluable tool in the diagnosis of quadriceps muscle or tendon injury. Utilizing this noninvasive imaging technique, medical professionals can easily diagnose and monitor muscle and tendon disorders to quickly determine the correct treatment plan for each individual case. The ability to view these structures in real-time allows identification of any present pathologies. MSK-US has become a useful component in diagnosing quadriceps muscle and tendon injuries due to its ability to clearly display the affected structures without exposing the patient to radiation or utilizing ionized contrast media. MSK-US provides valuable insight into fluid dynamics around joints and can even detect myotendinous tears that might otherwise be overlooked with the clinical examination or symptoms usually reported by patients. MSK-US can provide precise visualization of edema and can easily distinguish between benign and potentially pathological findings which make it an integral part of any holistic evaluation of quadriceps muscle and tendon injury. Additionally, it can be used to track the progress of physical therapy treatments and monitor tissue healing. This information is invaluable in ensuring an optimal outcome for any quadriceps muscle and tendon injury. Therefore, when used in combination with clinical tests, MSK-US can drastically increase the accuracy of the clinical examination. By utilizing this technology, healthcare practitioners have reliable access to more comprehensive diagnostics for musculoskeletal injuries and diseases than ever before. Clinicians are then able to tailor rehabilitation plans more effectively and ensure their patients receive proper treatment. As a result, recovery times may be shortened, and patients are able to return to their normal activities more quickly.

INTRODUCTION

Traditionally, quadricep complex soft tissue injury has been difficult to quantify with the clinical evaluation. Clinical success is always predicated upon an accurate diagnosis and understanding of the pathological process. MSK-US imaging of the has revolutionized the diagnosis of quadriceps muscle and tendon injuries. It provides high-resolution images and animations that enable successful visualization and separation of soft tissues from adjoining bones and ligaments. While a careful history and a thorough physical examination are important steps in the as-

essment of quadriceps pathology, MSK-US provides high-resolution static or dynamic images that enable successful visualization and separation of soft tissues from adjoining bones and ligaments. MSK-US has become an invaluable component in diagnosing quadriceps muscle and tendon injuries due to its ability to clearly display the affected structures without exposing the patient to radiation or utilizing ionized contrast media. MSK-US can provide precise visualization of edema and can easily distinguish between benign and potentially pathological findings which make it an integral part of any holistic evaluation of quadriceps muscle tendon injury. The speed and accuracy of ultrasound imaging make it a useful tool in differentiating mus-

^a Corresponding author:
Robert.Manske@wichita.edu

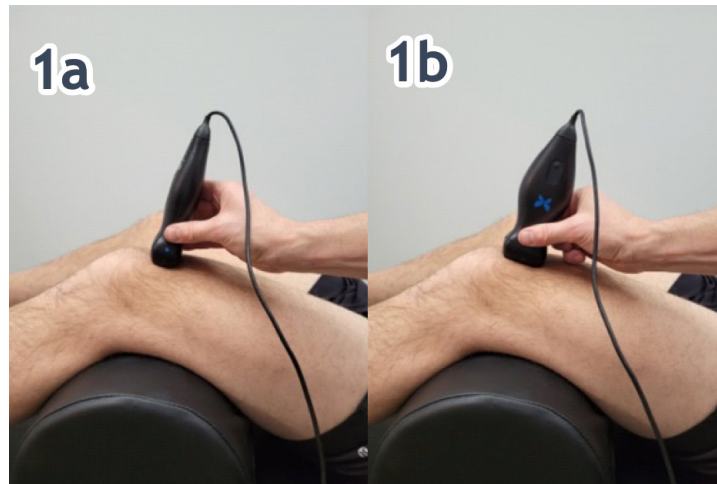


Figure 1. Patient Position

Figure 1a. (Left)

Patient is supine with a bolster placed under the knee for 30 degrees of flexion, reducing the patella “locking” on the femur as in full extension.

Transducer Placement: Short Axis (SAX) Probe is placed one probe width proximal to the patella.

Figure 1b. (Right)

Patient is supine with a bolster placed under the knee for 30 degrees of flexion, reducing the patella “locking” on the femur as in full extension.

Transducer Placement: Long Axis (LAX). Probe is placed on the proximal portion of the patella.

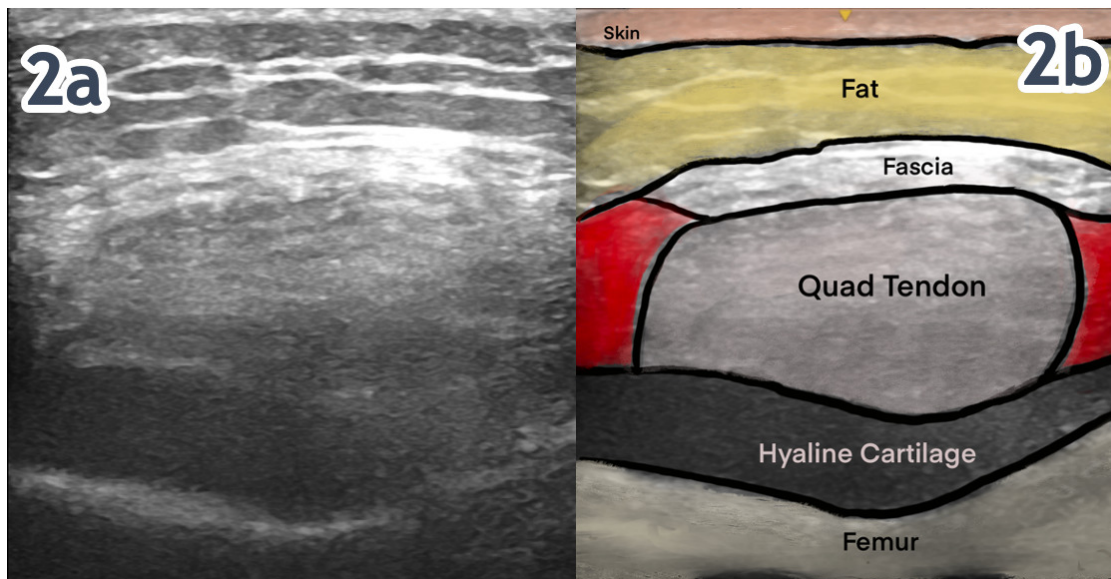


Figure 2. NORMAL TENDON IN SHORT AXIS (SAX)

Figures 2a/b: The cortex of the femur is the linear reflection deep on the image. Mixed echoes of fat and muscle are superficial to the bony margin.

cle contusion from tendinopathy or strain. In addition to the diagnostic benefits, MSK-US is also beneficial for monitoring progression and recovery of quadriceps muscle and tendon injuries. The accuracy of images helps clinicians evaluate patient progress during physical therapy sessions and make necessary adjustments to treatment plans if needed. This allows for more precise tracking of muscle healing, enabling clinicians to identify any setbacks early on and provide timely intervention if required.

CONCLUSION

In conclusion, MSK-US is an effective diagnostic tool for assessing quadriceps muscle and tendon injuries. MSK-US has minimal risk with no radiation involved and it can provide valuable information about the extent and progression of injury. By understanding MSK-US and its benefits, medical professionals can better diagnose and treat patients with quadriceps muscle and tendon injuries, leading to more successful outcomes. This makes it an invaluable tool for healthcare professionals when treating musculoskeletal disorders. MSK-US should always be used alongside other techniques such as physical examinations, laboratory tests

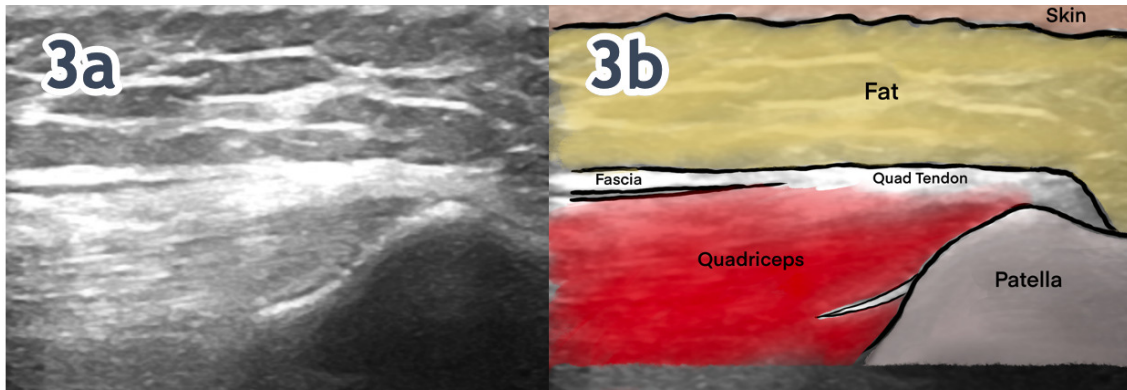


Figure 3. NORMAL TENDON IN LONG AXIS (LAX)

Figures 3a/b: The patellar cortex is superficial and to the right on the image. Hyperechoic fibrous echotexture of the quadriceps tendon is superficial and tapers to its attachment on the patella.

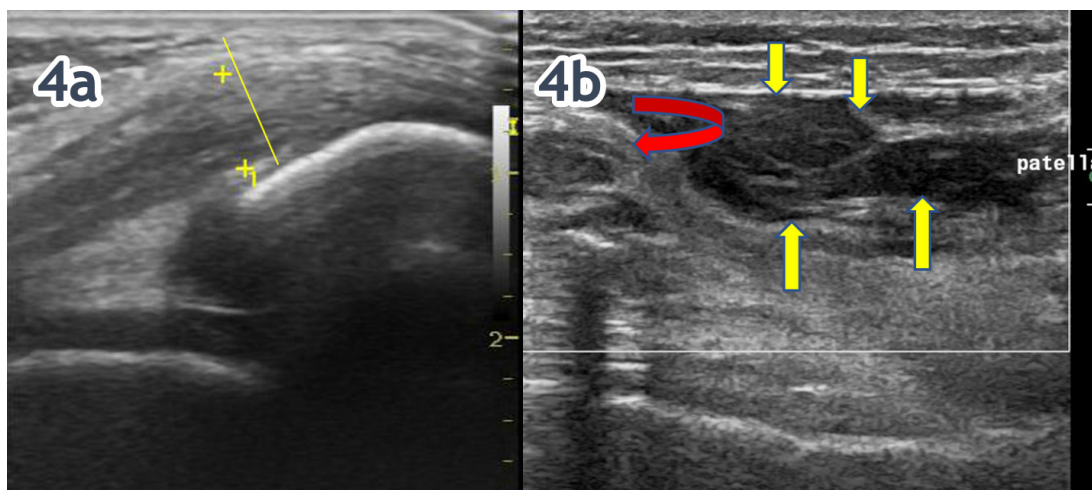


Figure 4. QUADRICEPS TENDON PATHOLOGY

Figure 4a. LAX View of Quadriceps Tendon: Case courtesy of Maulik S Patel, [Radiopaedia.org](https://radiopaedia.org), rID: 25215

Quadriceps tendinopathy associated with symptoms has a higher rate of tendon hypoechoicities, hyperechoicities and neo-vascularization, with the tendon appearing thicker and with a greater cross-sectional diameter

Figure 4b. LAX View of Quadriceps Tendon: Case courtesy of Craig Hacking, [Radiopaedia.org](https://radiopaedia.org), rID: 56032

Curved Red Arrow: Quadriceps tendon rupture with 3.4 cm retraction of the tendon.
Yellow Arrows: large heterogeneous 3.5 x 1.2 x 6 cm suprapatellar bursal hematoma.

and patient history in order to accurately diagnose quadriceps muscle and tendon injuries. MSK-US is essential for providing insight into the structures affected by injury and helps clinicians create tailored physical therapy plans that lead to optimal outcomes. With its accuracy, precision, and non-invasive nature, MSK-US has become an integral part

of diagnosing and treating quadriceps muscle injuries. The goal of this article is to provide a few tips and tricks to assist in using MSK-US as a diagnostic tool for the assessment of quadriceps pathology.



This is an open-access article distributed under the terms of the Creative Commons Attribution 4.0 International License (CCBY-NC-4.0). View this license's legal deed at <https://creativecommons.org/licenses/by-nc/4.0> and legal code at <https://creativecommons.org/licenses/by-nc/4.0/legalcode> for more information.