

Research article

Open Access

Does a small central Nd:YAG posterior capsulotomy improve peripheral fundal visualisation for the Vitreoretinal surgeon?

Niall Patton*, Tariq M Aslam, Harry G Bennett and Baljean Dhillon

Address: Department of Ophthalmology, Princess Alexandra Eye Pavilion, Chalmers Street, Edinburgh. EH9 3HA

Email: Niall Patton* - niallpatton@hotmail.com; Tariq M Aslam - TAslam@aol.com; Harry G Bennett - Harry.Bennett@luht.scot.nhs.uk; Baljean Dhillon - Baljean.Dhillon@luht.scot.nhs.uk

* Corresponding author

Published: 30 June 2004

Received: 20 February 2004

BMC Ophthalmology 2004, 4:8 doi:10.1186/1471-2415-4-8

Accepted: 30 June 2004

This article is available from: <http://www.biomedcentral.com/1471-2415/4/8>

© 2004 Patton et al; licensee BioMed Central Ltd. This is an Open Access article: verbatim copying and redistribution of this article are permitted in all media for any purpose, provided this notice is preserved along with the article's original URL.

Abstract

Background: To evaluate the effect of Nd:YAG capsulotomy for posterior capsular opacification (PCO) on visualisation of the peripheral fundus with scleral indentation.

Methods: Patients undergoing Nd:YAG capsulotomy for PCO were examined pre- and four weeks post- Nd:YAG capsulotomy. In order to give a quantitative measure of visualisation of the peripheral retina, a novel scalar measurement was developed. Changes in the degree of visualisation following Nd:YAG capsulotomy were calculated.

Results: There was a significant improvement in fundal visualisation of the retinal periphery with scleral indentation following Nd:YAG capsulotomy ($p = 0.001$).

Conclusion: Peripheral fundal visualisation with scleral indentation improves following a small central Nd:YAG capsulotomy. This finding is important in relation to the detection of peripheral pseudophakic retinal breaks, particularly in those patients deemed at high risk following Nd:YAG capsulotomy.

Background

Posterior capsular opacification (PCO) is the commonest complication of cataract surgery [1]. It has implications not only for the immediate visual function of the patient, but also for the ophthalmologists' diagnostic ability, as PCO may have a significant impact on the ability of the vitreoretinal surgeon to visualise the peripheral fundus. This may be particularly important for patients at risk of retinal detachment.

After uneventful extracapsular cataract surgery, Nd:YAG capsulotomy has been shown to increase the risk of developing a retinal detachment [2-11]. Proposed mechanisms include liquefaction of the vitreous [12] and interruption of the anterior hyaloid face [13]. Whilst some authors con-

sider the increased risk to be as a result of opening the capsule and not a specific complication of the laser procedure itself [10,12,14], minimising the energy used to create the capsulotomy is generally considered advisable to minimise the associated risk of retinal detachment [15]. It has been suggested that current practise should be wary of performing Nd:YAG capsulotomy on high risk patients, such as high myopes. However when making this decision, one must also consider that there may be an increased difficulty in fundal visualisation and assessment in these patients, if the posterior opacified capsule is left intact. In a previous study examining the fundi of patients undergoing Nd:YAG capsulotomy, a vitreoretinal surgeon could not visualise the entire fundus in 25% of cases [16]. Improved visualisation of the peripheral fundus may

allow the attending clinician to be better able to detect any retinal tears or other breaks that may be amenable to prophylactic treatment. Furthermore, those patients at high risk of retinal detachment may present to their ophthalmologist earlier as their improved visual function may allow easier detection of visual symptoms. Thus, a proportion of retinal detachments may even be prevented in these patients by earlier detection and treatment.

No studies to date have assessed the degree of improvement in fundal visualisation after Nd:YAG capsulotomy. We performed a prospective study, in order to quantify the degree of change in peripheral fundal visualisation following a small central Nd:YAG capsulotomy. We developed a grading scale of the peripheral fundus and examined patients pre- and 4 weeks post- Nd:YAG capsulotomy, in order to estimate the effect on peripheral fundal visualisation with scleral indentation.

Methods

Local research ethical committee approval for the study was obtained, and the study was carried out according to the tenets of the Declaration of Helsinki. Consecutive patients undergoing Nd:YAG capsulotomy for posterior capsular opacification were recruited and full informed consent was obtained. Patients excluded were those that had medial opacities other than PCO and those unable to tolerate scleral indentation. Patients with peripheral retinal pathology requiring treatment were also excluded from the study. Prior to Nd:YAG capsulotomy, the patients' visual function was assessed in terms of best corrected distance visual acuity using Bailey Lovie logMAR type charts. Pupils were dilated with topical 1% tropicamide. After a minimum of 20 minutes, the size of the pupil was recorded, using a millimetre ruler. These tests were performed by one practitioner (TA). The peripheral fundus was examined with scleral indentation in each of the four quadrants using a 20-dioptre Volk (Volk Optical, Mentor, Ohio, USA) lens and stereoscopic indirect biomicroscopy, set at a standard illumination, and in a dark room with no other source of light.

Visualisation of the peripheral fundus was subjectively graded in each of the four quadrants (superotemporal, inferotemporal, inferonasal and superonasal) according to the following scale:

0 Visualisation of the scleral indent with clear retinal detail on the indent visible

1 Visualisation of the scleral indent with retinal detail on the indent obscured

2 Visualisation of scleral indent only with no retinal detail on the indent visible

3 No visualisation of the scleral indent

The grading score for each of the four quadrants was combined to provide a total peripheral fundus Visualisation Score, ranging from 0 to 12, in order of decreasing visualisation. A time limit of 30 seconds for examining each quadrant was used, as there may have been a tendency on the part of the examiner to continue to indent excessively until visualisation of the indent was obtained.

All examinations of the peripheral fundus were carried out by the same examiner (NP), who was skilled in fundal examination with scleral indentation. In order to be masked as to whether the patient was pre- or post-Nd:YAG capsulotomy, inspection of the anterior segment was deliberately avoided, by always examining the fundus, with the lenses already placed before the eye, thus obscuring any anterior segment view. Each patient underwent Nd:YAG laser capsulotomy via a set protocol by one surgeon (TA). This involved an initial setting of 1 mJ and subsequent rises of 0.5 mJ as necessary to pierce the posterior capsule. The laser treatment was initiated off axis in a horizontal line across centre, followed by a line in the vertical axis to form a cross. Any obvious lines of capsule tear were treated with laser if deemed beneficial and overall energy used was kept to a minimum. Treatments were performed to produce small central capsulotomies of size approximately 2–3 mm diameter, in keeping with previously published research by the authors[17].

Four weeks post Nd:YAG capsulotomy, the patients were reassessed again in terms of visual function using the same methods described earlier by the same practitioner (TA). The pupils were dilated using 1% tropicamide and after a minimum 20 minute interval, the size of the pupil was recorded. The Visualisation Score was graded according to the same scale as before, by the same examiner (NP). Assessments included patients both pre- and post-Nd:YAG capsulotomy in random order, in an attempt to further increase masking of the examiner. Four weeks was chosen for re-examination as capsulotomies enlarge progressively up to one month, and then stabilise in size thereafter[18].

A small number of random cases had their contralateral eye examined on the same two occasions as the eye undergoing Nd:YAG capsulotomy. The contralateral eyes served as controls, in order to obtain a measure of the repeatability of the Visualisation Score.

Data are represented as means \pm standard deviations (S.D.). Kolmogorov-Smirnov one sample Z test was used to check for normality of data distribution. Student t test for paired data was used to compare means for data with a normal distribution. Statistical significance was

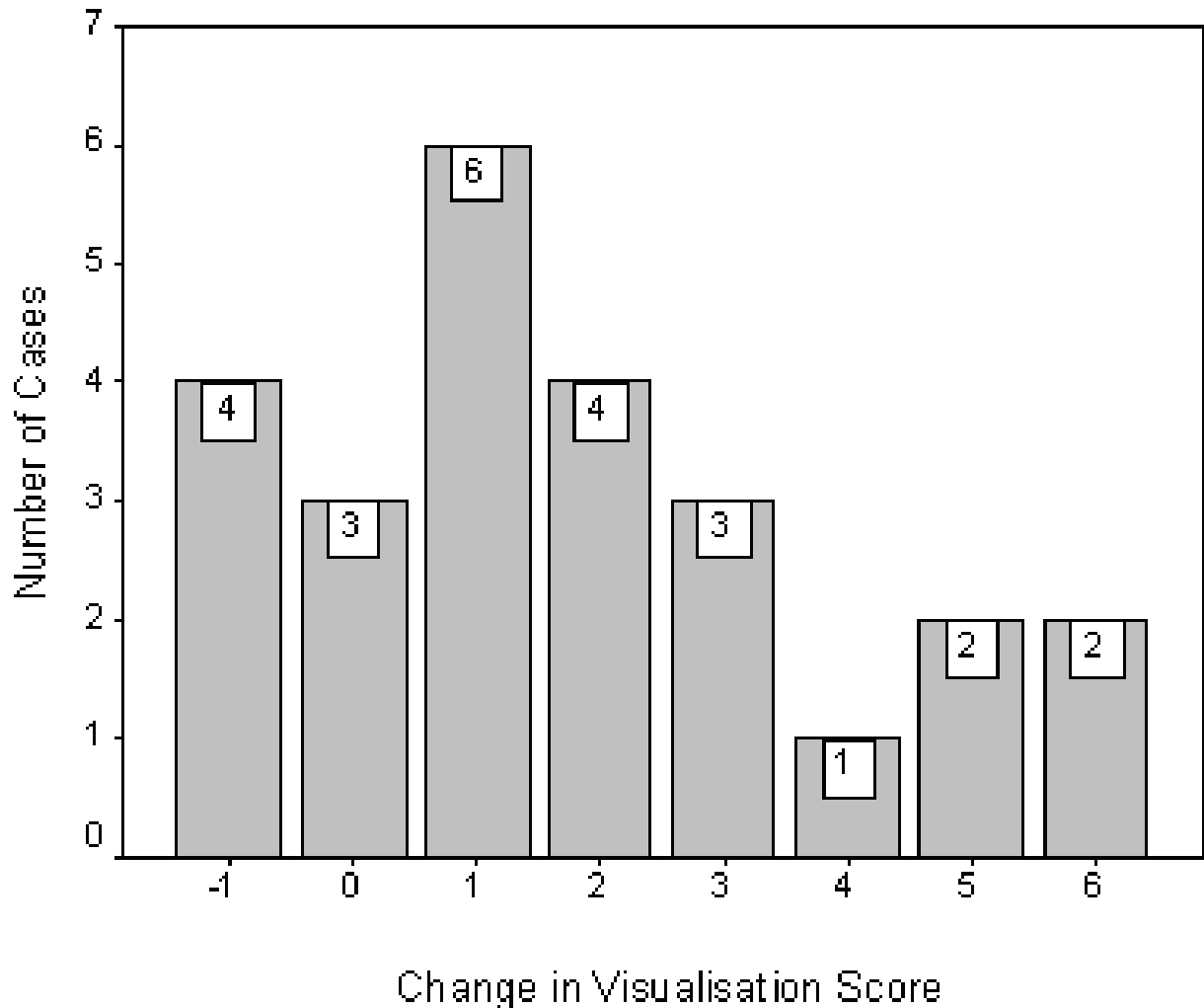


Figure 1
Bar chart of changes in Visualisation Score following Nd:YAG capsulotomy.

considered when $p < 0.05$. Because the total Visualisation Score was composed of a combination of sub-scales (4 quadrants), internal validity was determined by the Cronbach test of reliability[19,20]. This is a test statistic to determine the degree with which constituent items within a scale correlate with each other. An alpha coefficient of = 0.7 is considered necessary for a composite of measurements to be considered an internally reliable scale. Cohen's kappa coefficient (κ) was used to determine the reproducibility of the Visualisation Score in the control eyes. Statistical analysis was performed using SPSS for Windows (version 8.0) for all calculations.

Results

A total of 29 eyes of 29 patients were recruited into the study. Mean age was 75.9 years (range 52 – 90). There were 16 females and 13 males. 2 cases declined a second examination post-Nd:YAG capsulotomy. 1 case had asteroid hyalosis, and was excluded from the study. One further case was unable to tolerate indentation. There were no cases of peripheral retinal pathology requiring treatment, necessitating exclusion from the study. Therefore, a total of 25 eyes had their retinal periphery examined pre and post-Nd:YAG capsulotomy. There were no significant differences in terms of age or gender between those that did or did not complete the study.

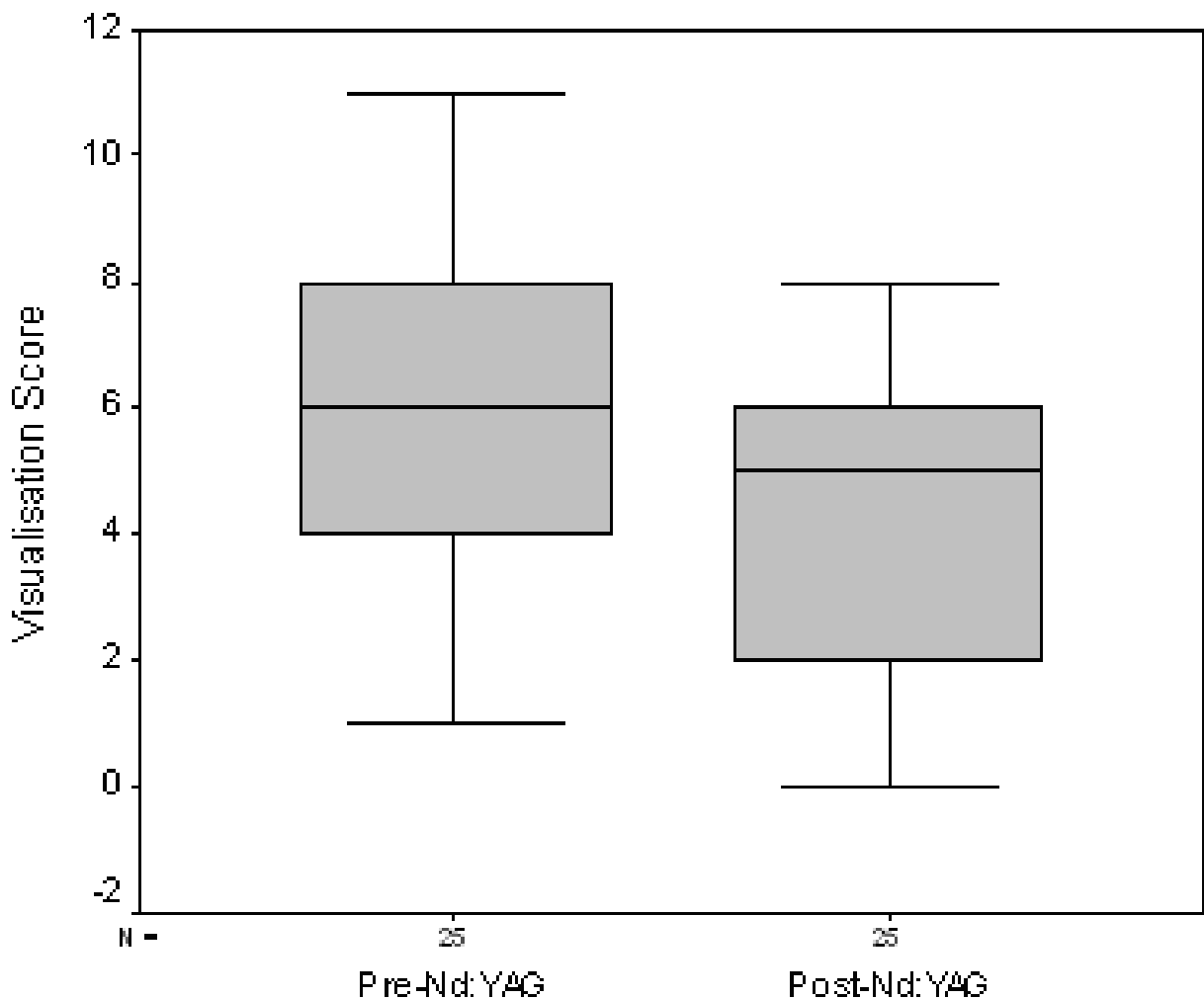


Figure 2
Boxplots of Visualisation Score pre- and post-Nd:YAG capsulotomy.

Mean improvement in logMAR visual acuity was 0.31 ± 0.28 . There was no significant difference in mean pupil size pre- (7.17 ± 0.86 mm) and post- (7.22 ± 0.81 mm) Nd:YAG assessments ($p = 0.668$). The Visualisation Score showed good internal consistency and reliability (Cronbach's α coefficient = 0.78 pre-Nd:YAG and 0.73 post-Nd:YAG).

Of the 25 cases, 18 had an improvement in Visualisation Score of = 1. In 3 cases, there was no change following Nd:YAG capsulotomy, and in 4 cases, the Visualisation Score decreased by -1 (figure 1).

Overall, there was a significant improvement in Visualisation Score. Mean Visualisation Score pre-Nd: YAG was 6.12 ± 2.93 . Mean Visualisation Score post-Nd: YAG was 4.32 ± 2.43 . There was a mean improvement of 1.80 ± 2.14 (95% C.I. 0.92 to 2.68) ($p < 0.0001$, paired student t test) (Figure 2).

11 cases had their contralateral eye examined peripherally on two separate occasions, to evaluate the reproducibility of the Visualisation Score. There was complete agreement in 8 of 11 cases. The kappa coefficient (κ) was 0.686 (standard error 0.153).

Discussion

This study aimed to provide a quantitative evaluation of the degree of change in visualisation of the peripheral fundus following a small central Nd:YAG capsulotomy. The scalar measurements are limited by being subjective assessments. However, the scale was found to be internally consistent and reliable, repeatable and has face validity as a measurement of peripheral fundal visualisation in these patients, as they appear to be able to discriminate changes in fundal visualisation following Nd:YAG capsulotomy. Inter-rater variability was not assessed in this study, as all examinations were carried out by the same examiner.

There was an overall mean improvement in visualisation of the retinal periphery with scleral indentation of 1.8 (on a scale ranging from 0 to 12) following Nd:YAG capsulotomy. This approximates to an improvement of peripheral visualisation in approximately 2 of the 4 quadrants examined for each case. This improvement in peripheral fundal visualisation occurred despite the use of a small central capsulotomy, which may be most appropriate for those patients considered at high risk following Nd:YAG capsulotomy. However, 5/25 (20%) patients' peripheral fundal visualisation improved by = 4. Further studies are required to address whether this improvement in peripheral fundal visualisation will lead to earlier detection and prophylactic treatment of retinal breaks, and hence reduce the incidence of retinal detachment post-Nd:YAG capsulotomy. However, this is the first study quantifying an improvement in the peripheral fundal visualisation, post-Nd:YAG capsulotomy. Whether a larger capsulotomy would produce even greater improvement in peripheral fundal visualisation requires further study.

When a clinician is evaluating the risks and benefits of performing Nd:YAG capsulotomy in a pseudophakic individual who is considered at high risk of developing retinal detachment, the benefit of improved fundal visualisation following the procedure may be significant in the decision-making. By performing a small central Nd:YAG capsulotomy, there is a significant improvement in peripheral fundal view, whilst minimising the risk in these patients by using the minimum energy possible.

Conclusions

In conclusion, based on this study's findings, performing a small central Nd:YAG capsulotomy in high risk patients will improve peripheral fundal visualisation, and may minimise the inherent risks associated with performing a capsulotomy.

Competing interests

None declared.

Author's Contributions

Niall Patton jointly conceived the idea of the study with Tariq Aslam. Niall Patton performed all fundal examinations, and wrote the article and performed all statistical analyses.

Tariq Aslam jointly conceived the idea of the study. He performed all visual tests and the Nd:Yag capsulotomies.

Baljean Dhillon helped with the design and methodology of the study.

Harry Bennett helped with the design and methodology of the study.

References

1. Wormstone IM: **Posterior capsule opacification: a cell biological perspective.** *Exp Eye Res* 2002, **74**:337-347.
2. Ranta P, Tommila P, Kivela T: **Retinal breaks and detachment after neodymium:YAG laser posterior capsulotomy; Five-year incidence in a prospective cohort.** *J Cataract Refract Surg* 2004, **30**:65-73.
3. Ambler JS, Constable IJ: **Retinal detachment following Nd:YAG capsulotomy.** *Aust N Z J Ophthalmol* 1988, **16**:337-341.
4. Dardenne MU, Gerten GJ, Kokkas K, Kermani O: **Retrospective study of retinal detachment following neodymium:YAG laser posterior capsulotomy.** *J Cataract Refract Surg* 1989, **15**:676-680.
5. Javitt JC, Tielsch JM, Canner JK, Kolb MM, Sommer A, Steinberg EP: **National outcomes of cataract extraction. Increased risk of retinal complications associated with Nd:YAG laser capsulotomy. The Cataract Patient Outcomes Research Team.** *Ophthalmology* 1992, **99**:1487-97; discussion 1497-8.
6. Koch DD, Liu JF, Gill EP, Parke D. W., 2nd: **Axial myopia increases the risk of retinal complications after neodymium-YAG laser posterior capsulotomy.** *Arch Ophthalmol* 1989, **107**:986-990.
7. Ninn-Pedersen K, Bauer B: **Cataract patients in a defined Swedish population, 1986 to 1990. V. Postoperative retinal detachments.** *Arch Ophthalmol* 1996, **114**:382-386.
8. Rickman-Barger L, Florine CW, Larson RS, Lindstrom RL: **Retinal detachment after neodymium:YAG laser posterior capsulotomy.** *Am J Ophthalmol* 1989, **107**:531-536.
9. Shah GR, Gills JP, Durham DG, Ausmus WH: **Three thousand YAG lasers in posterior capsulotomies: an analysis of complications and comparison to polishing and surgical dissection.** *Ophthalmic Surg* 1986, **17**:473-477.
10. Steinert RF, Puliafito CA, Kumar SR, Dudak SD, Patel S: **Cystoid macular edema, retinal detachment, and glaucoma after Nd:YAG laser posterior capsulotomy.** *Am J Ophthalmol* 1991, **112**:373-380.
11. Tielsch JM, Legro MW, Cassard SD, Schein OD, Javitt JC, Singer AE, Bass EB, Steinberg EP: **Risk factors for retinal detachment after cataract surgery. A population-based case-control study.** *Ophthalmology* 1996, **103**:1537-1545.
12. Winslow RL, Taylor BC: **Retinal complications following YAG laser capsulotomy.** *Ophthalmology* 1985, **92**:785-789.
13. Terry AC, Stark WJ, Maumenee AE, Fagadau W: **Neodymium-YAG laser for posterior capsulotomy.** *Am J Ophthalmol* 1983, **96**:716-720.
14. Powell SK, Olson RJ: **Incidence of retinal detachment after cataract surgery and neodymium: YAG laser capsulotomy.** *J Cataract Refract Surg* 1995, **21**:132-135.
15. Charles S: **Vitreoretinal complications of YAG laser capsulotomy.** *Ophthalmol Clin North Am* 2001, **14**:705-710.
16. Ranta P, Tommila P, Immonen I, Summanen P, Kivela T: **Retinal breaks before and after neodymium:YAG posterior capsulotomy.** *J Cataract Refract Surg* 2000, **26**:1190-1197.
17. Aslam T.M., Dhillon, B.: **Neodymium:YAG laser capsulotomy: a clinical morphological analysis.** *Graefes Arch Clin Exp Ophthalmol* 2002, **240**:972-976.

18. Hu CY, Woung LC, Wang MC: **Change in the area of laser posterior capsulotomy: 3 month follow-up.** *J Cataract Refract Surg* 2001, **27**:537-542.
19. Bland JM, Altman DG: **Cronbach's alpha.** *Bmj* 1997, **314**:572.
20. Bland JM, Altman DG: **Statistics Notes: Validating scales and indexes.** *Bmj* 2002, **324**:606-607.

Publish with **BioMed Central** and every scientist can read your work free of charge

"BioMed Central will be the most significant development for disseminating the results of biomedical research in our lifetime."

Sir Paul Nurse, Cancer Research UK

Your research papers will be:

- available free of charge to the entire biomedical community
- peer reviewed and published immediately upon acceptance
- cited in PubMed and archived on PubMed Central
- yours — you keep the copyright

Submit your manuscript here:
http://www.biomedcentral.com/info/publishing_adv.asp

