

Case Report

Pembrolizumab-Induced Toxic Epidermal Necrolysis

Luca Borg^a Malcolm Buhagiar^b Elisa La Ferla^a David Pisani^c
Janabel Said^b Michael J. Boffa^d

^aDepartment of Medicine, Mater Dei Hospital, Msida, Malta; ^bDepartment of Oncology, Sir Anthony Mamo Oncology Centre, Msida, Malta; ^cDepartment of Pathology, Mater Dei Hospital, Msida, Malta; ^dDepartment of Dermatology, Mater Dei Hospital, Msida, Malta

Keywords

Pembrolizumab · Toxic epidermal necrolysis · Steroids · Intravenous immunoglobulin · Cyclosporin · Non-small cell lung cancer · Immunotherapy

Abstract

Immunotherapy has nowadays become part of the mainstay of treatment for several cancers. In this report, we present a case of toxic epidermal necrolysis (TEN) occurring as a relatively rare complication of pembrolizumab, which is a humanized monoclonal anti-programmed cell death-1 (anti-PD1) IgG4 antibody that targets tumours expressing PDL-1. In our case, this monoclonal antibody (MAB) was being used for the treatment of metastatic non-small cell lung cancer, before being withheld because of this potentially life-threatening reaction. There are no guidelines on the optimal management of TEN, with varying reports on the efficacy on steroids, intravenous immunoglobulin (IVIg), and cyclosporin. In this report, we describe a case of TEN following the second dose of three-weekly pembrolizumab in a 50-year-old man, comparing it to four similar cases reported in the literature. It is important that oncologists are aware of this potentially life-threatening adverse reaction of pembrolizumab, as early recognition and treatment of TEN are essential to improve clinical outcome.

© 2022 The Author(s).
Published by S. Karger AG, Basel

Introduction

TEN is a rare, potentially life-threatening cutaneous adverse reaction, which is characterized by erythema, desquamation, and possibly mucosal involvement. Stevens-Johnson syndrome (SJS) and TEN are considered to be two ends of a spectrum of the same dermatosis

Correspondence to:
Luca Borg, luca-andrea.borg@gov.mt

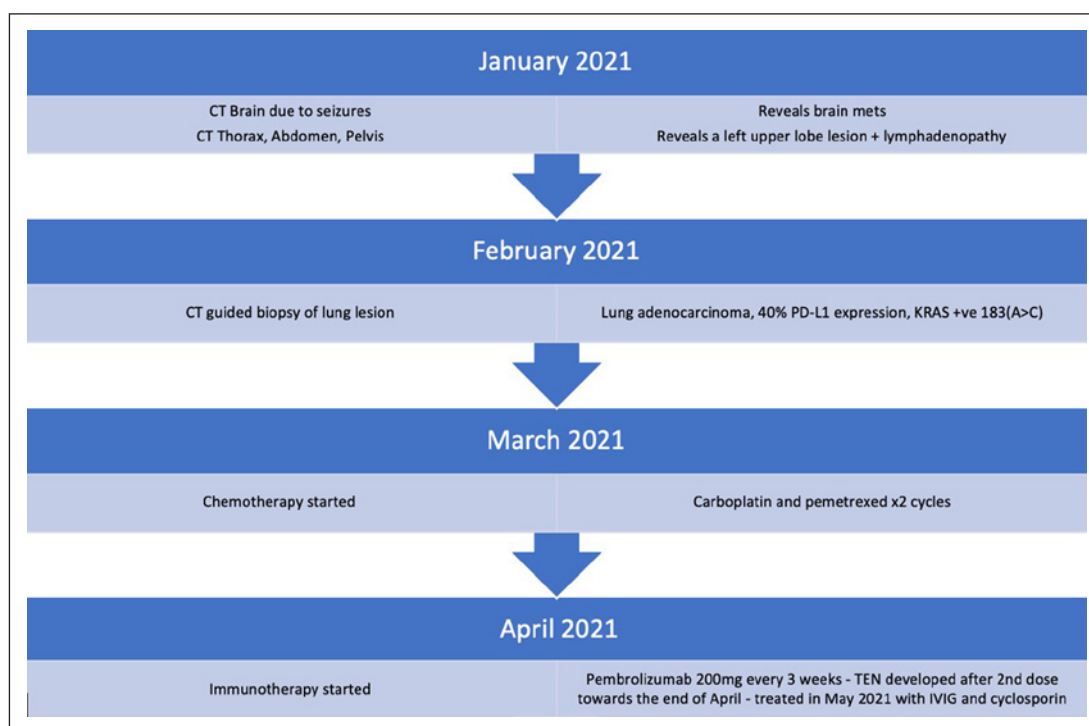


Fig. 1. Timeline highlighting the patient's diagnoses and treatment.

associated with epidermolysis. SJS is associated with detachment of <10% skin surface area whilst TEN is associated with detachment of >30% skin surface area [1]. In most cases, TEN is drug-induced, and less commonly, it may be associated with infections [2]. It is most often attributed to the use of certain antibiotics (mainly beta-lactams and sulfonamides) and antiepileptic drugs. Other less commonly implicated drugs include nonsteroidal anti-inflammatory drugs (NSAIDs), paracetamol, allopurinol, and nevirapine [1]. In this case, we will describe the presentation and management of TEN caused by pembrolizumab, which was being used in the management of stage IV non-small cell lung cancer. TEN is a rare complication of pembrolizumab treatment, and there are no established guidelines on its management in this clinical scenario. In this report, we compare the way we managed our case with four other cases documented in the literature. Further studies are required to establish the ideal management pathway in such scenarios. Being familiar with the presentation of this cutaneous adverse reaction is important since early recognition and treatment reduce morbidity and mortality.

Case Report

A 50-year-old man with metastatic non-small cell lung cancer developed an extensive and tender skin eruption a few days after receiving his second dose of three-weekly pembrolizumab. The patient was being treated with 200 mg pembrolizumab every 3 weeks after having received two cycles of carboplatin and pemetrexed in the previous month (shown in Fig. 1).

At presentation he had extensive, confluent erythema involving the back, chest, upper arms, and upper abdomen, with four large bullae, all containing clear fluid, over the back

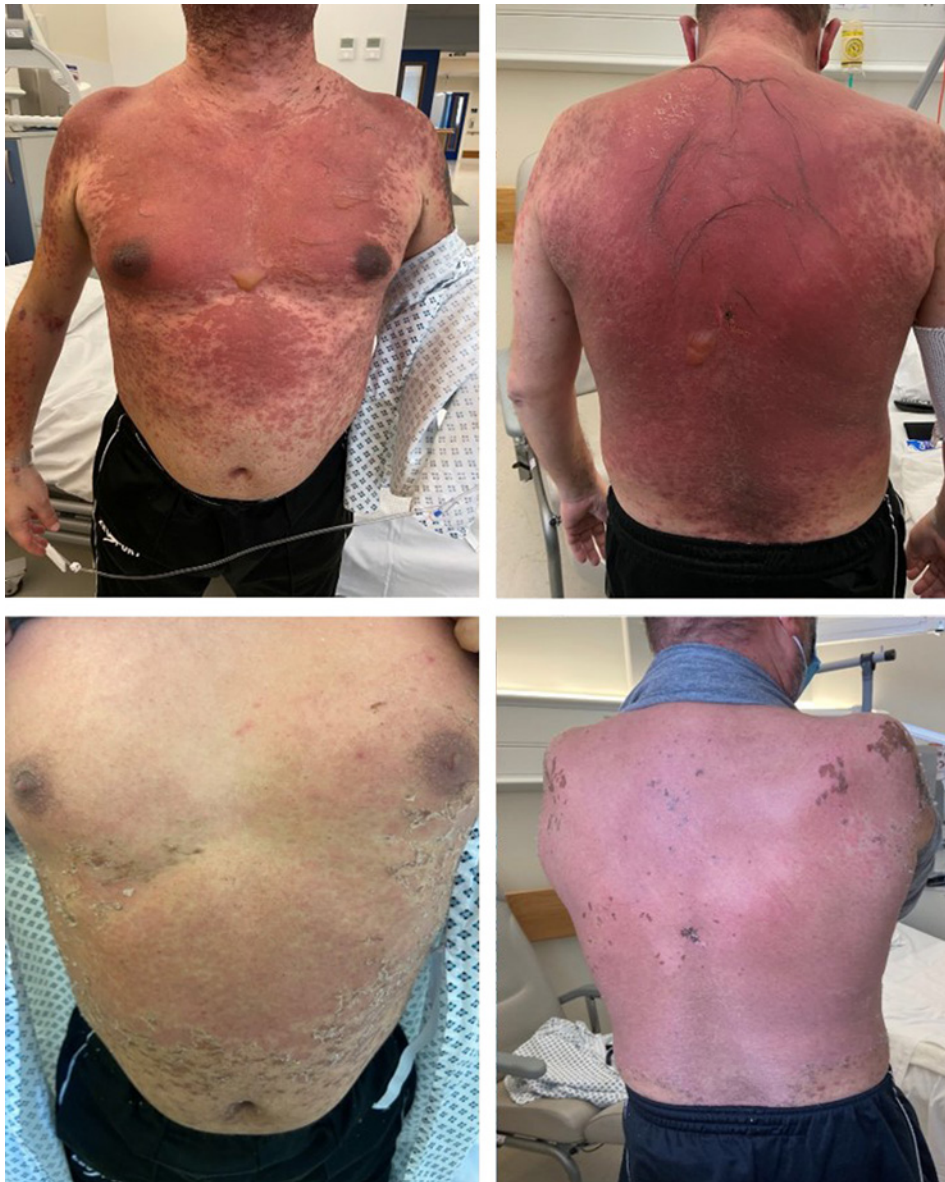


Fig. 2. Extensive erythema and blistering on the chest, back, upper limbs, and abdomen at presentation compared to significant improvement after 5 doses of IVIGs and 2 weeks of cyclosporin therapy.

(shown in Fig. 2). Minimal rubbing of the skin resulted in the detachment of the epidermis (positive Nikolsky's sign). There was no oral or genital ulceration; however, a single 6 mm erythematous macule was noted over the hard palate.

The clinical impression was of toxic epidermal necrolysis (TEN) secondary to pembrolizumab, which was the only recently added drug. The only other drug the patient had been on was sodium valproate for 4 months with no recent change in dose. Furthermore, he had no history of previous skin problems or autoimmune conditions.

A punch biopsy from an area of confluent erythema on the back revealed skin covered by a partly detached, subtotally necrotic epidermis. Areas of confluent epidermal necrosis were seen, associated with epidermal detachment at the level of the dermo-epidermal junction with associated formation of paucicellular subepidermal blisters. Scattered apoptotic keratinocytes

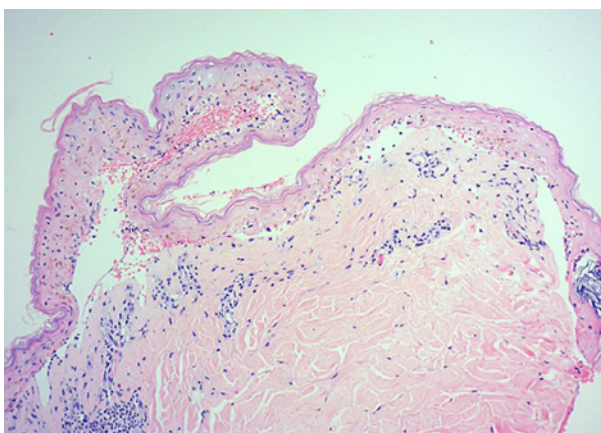


Fig. 3. Histology of skin showing clefting and separation of the epidermis at the dermoepidermal junction, with associated erythrocytic extravasation. A patchy perivascular lymphocytic infiltrate is also noted. (H&E $\times 100$).

were also noted focally within the epidermis. A sparse perivascular lymphocytic infiltrate was present in the underlying dermis, associated with scattered melanophages and pigment incontinence. The findings were those of lichenoid dermatitis with epidermal necrosis and subepidermal blister formation, consistent with TEN (shown in Fig. 3).

We used the SCORTEN (TEN severity score) to help us predict mortality in our patient [3]. SCORTEN utilizes seven independent risk factors for high mortality evaluated during the first 24 h of admission (1 point for the presence of each of the following: age >40 years, presence of associated malignancy, skin surface area detached or compromised $>10\%$, heart rate >120 beats/min, serum urea >10 mmol/L, serum bicarbonate <20 mmol/L, and serum glucose >14 mmol/L). Our patient had a score of 3 (range 0–7), which is associated with a 35% mortality.

Planned further treatment with pembrolizumab was withheld and the patient was initially treated with intravenous immunoglobulin (IVIg, 200 g [3 g/kg] divided over five consecutive days) together with supportive therapy and analgesia. He was nursed on an air-fluidized bed. Aqueous cream was applied as a general emollient with silver sulfadiazine cream to blistering areas. Although the intensity of the erythema decreased and no new blisters appeared after starting IVIg, new skin areas became involved. At this point (2 days after completing IVIg), cyclosporin 200 mg twice daily (5 mg/kg/day) was started, with close monitoring of blood pressure and renal function. The patient's condition improved rapidly and after 7 days, the cyclosporin dose was reduced to 100 mg twice daily for another week and then stopped. The patient recovered fully without any complications (shown in Fig. 2).

Discussion/Conclusion

Pembrolizumab is a humanized monoclonal anti-programmed cell death-1 (anti-PD1) IgG4 antibody, which targets tumours expressing PDL-1. This MAB has various therapeutic indications including the treatment of non-small cell lung cancer. In our case, the patient was diagnosed with lung adenocarcinoma which showed 40% PD-L1 expression. Furthermore, KRAS mutation 183(A>C) was detected.

Pembrolizumab is associated with several cutaneous adverse reactions including maculopapular eruptions, pruritus, and areas of hypopigmentation [4] reported in about 22% of patients receiving the drug [5]; however, Stevens Johnson syndrome and TEN are rare complications [6]. To our knowledge, apart from our case, there have been, so far, only four other reports of pembrolizumab-induced TEN, none of which proved fatal [6–9] (Table 1).

Table 1. Comparing our case to another four cases of pembrolizumab-induced TEN

Gender	Age	Malignancy	Timing of reaction after starting pembrolizumab	SCORTEN	Management	Outcome
F [5]	55	Non-small cell lung cancer	5 months after 1st dose	N/A	Pulsed methylprednisolone, IVIG, prednisolone	Complete resolution
M [4]	63	Lung adenocarcinoma	3 days after 1st dose	N/A	Prednisolone, Cyclosporin	Complete resolution
F [9]	55	Cervical squamous cell carcinoma	17 days after 1st dose	N/A	N/A	N/A
F [8]	72	Lung cancer	35 days after 1st dose (14 days after 2nd dose)	3	Pulsed methylprednisolone, IVIG, prednisolone	Complete resolution
M [our case]	50	Lung Cancer	24 days after 1st dose	3	IVIG, cyclosporin	Complete resolution

The exact mechanism by which pembrolizumab causes TEN is not yet well understood. However, TEN is known to be a T-cell mediated reaction and may be related to activation of T cells following PD1 inhibition, which in turn target the skin [5].

Apart from developing TEN, our patient also suffered from immune-mediated hepatitis. This responded well to methylprednisolone. There was no evidence of concurrent pneumonitis or thyroiditis.

Whereas in the reported cases the mean time between the first infusion of pembrolizumab and the onset of a cutaneous reaction was about 37 weeks [10], the mean time for the onset of pembrolizumab-induced TEN, including our case, was approximately 17 days (Table 1). Treatments utilized include systemic corticosteroids, cyclosporin, and IVIG, with variable results.

In our case, IVIG appeared to initially stabilize the cutaneous changes; however, erythema continued spreading. Cyclosporin produced rapid improvement and was well tolerated. Optimum management of TEN is still debated. The use of corticosteroids is controversial [11] however studies have reported good results with IVIG, cyclosporin, and recently, etanercept [12].

This case report has its limitations, and more studies are required to compare efficacies and side effect profiles of different treatments for pembrolizumab-induced TEN. Furthermore, further studies to elucidate the exact mechanisms involved in pembrolizumab-induced TEN might pave the way for more targeted treatment and help develop treatment guidelines.

TEN is potentially life-threatening. Oncologists should be aware of this rare possible adverse reaction of pembrolizumab, as early recognition and treatment are essential to reduce morbidity and mortality.

Statement of Ethics

Written informed consent was obtained from the patient for publication of this case report and any accompanying images. Ethical approval is not required for this study in accordance with local or national guidelines.

Conflict of Interest Statement

The authors have no conflicts of interest to declare.

Funding Sources

The submission and publishing of this case report is not sponsored, and the authors have no funding sources to declare.

Author Contributions

Luca Borg – Corresponding author; encountered the patient and was involved in the direct management on the ward; came up with the idea of writing the paper; and heavily involved in the design and writing of the case, discussion, and background research. Malcolm Buhagiar – Oncology senior reviewing the patient after the first signs of TEN after being administered pembrolizumab; gave significant contributions to the oncology aspect of the

discussion and to the description of the initial presentation prior to contacting the dermatologist on call; and reviewed the paper prior to submission. Elisa La Ferla – Ward junior doctor; made significant contribution to research of other papers describing cases of pembrolizumab-induced TEN and heavily involved in designing the layout of this case report and revising the text. David Pisani – Histopathologist; made significant contribution to writing the histopathology aspect of the case report and providing the histology images and descriptions and involved in revising the text. Janabel Said – Consultant oncologist caring for the patient; made significant contribution to the oncology aspect of the case discussion and presentation; gave significant input regarding the use of pembrolizumab and its common adverse reactions; and involved in text revision. Michael J. Boffa – Consultant dermatologist responsible for the management of 10 in this patient; made significant contributions to the design, layout, and writing of the case report and discussion, especially about the use of SCORTEN and the management of TEN. All the authors approved the final version to be submitted for publication and all agreed to be accountable for all aspects of the work.

Data Availability Statement

All data generated or analysed during this study are included in this article. Further enquiries can be directed to the corresponding author.

References

- 1 Fakoya AOJ, Omenyi P, Anthony P, Anthony F, Etti P, Otohinoi DA, et al. Stevens – Johnson syndrome and toxic epidermal necrolysis; extensive review of reports of drug-induced etiologies, and possible therapeutic modalities. *Open Access Maced J Med Sci*. 2018 Apr;6(4):730–8.
- 2 Schneider JA, Cohen PR. Stevens-Johnson syndrome and toxic epidermal necrolysis: a concise review with a comprehensive summary of therapeutic interventions emphasizing supportive measures. *Adv Ther*. 2017 Apr;34(6):1235–44.
- 3 Fouchard N, Bertocchi M, Roujeau JC, Revuz J, Wolkenstein P, Bastuji-Garin S. SCORTEN: a severity-of-illness score for toxic epidermal necrolysis. *J Invest Dermatol*. 2000 Aug;115(2):149–53.
- 4 Sanlorenzo M, Vujic I, Daud A, Algazi A, Gubens M, Luna SA, et al. Pembrolizumab cutaneous adverse events and their association with disease progression. *JAMA Dermatol*. 2015 Nov;151(11):1206–12.
- 5 Goldinger SM, Stieger P, Meier B, Micalletto S, Contassot E, French LE, et al. Cytotoxic cutaneous adverse drug reactions during anti-PD-1 therapy. *Clin Cancer Res*. 2016 Mar;22(16):4023–9.
- 6 Cai ZR, Lecours J, Adam JP, Marcil I, Blais N, Dallaire M, et al. Toxic epidermal necrolysis associated with pembrolizumab. *J Oncol Pharm Prac*. 2019 Dec;26(5):1259–65.
- 7 Storandt MH, Seth R. A case of Stevens-Johnson syndrome/toxic epidermal necrolysis in a patient receiving chemo-immunotherapy with pemetrexed and pembrolizumab. *Curr Probl Cancer Case Rep*. 2021 Mar;3:100048.
- 8 Aoyama R, Kondo Y, Azuma N, Kira M. Toxic epidermal necrolysis as a complication of pembrolizumab treatment in a lung cancer patient. *J Cutan Immunol Allergy*. 2020 Nov;4(2):41–2.
- 9 Robinson S, Saleh J, Curry J, Mudaliar K. Pembrolizumab-induced stevens-johnson syndrome/toxic epidermal necrolysis in a patient with metastatic cervical squamous cell carcinoma: a case report. *Am J Dermatopathol*. 2020 Apr;42(4):292–6.
- 10 Wang LL, Patel G, Chiesa-Fuxench ZC, McGettigan S, Schuchter L, Mitchell TC, et al. Timing of onset of adverse cutaneous reactions associated with programmed cell death protein 1 inhibitor therapy. *JAMA Dermatol*. 2018 Sep;154(9):1057–61.
- 11 Hsieh MH, Watanabe T, Aihara M. Recent dermatological treatments for Stevens-Johnson syndrome and toxic epidermal necrolysis in Japan. *Front Med*. 2021 Jul;8:636924.
- 12 Paradisi A, Abeni D, Didona D, Ricci F, Canzona F, Didona B. A new case series on etanercept treatment for toxic epidermal necrolysis. *Eur J Dermatol*. 2020 Oct;30(5):561–8.