

Case Report

Survived traumatic hemipelvectomy with salvage of the limb in a 14 months old toddler

Hendrik Jansen^{a,*}, Timo M. Heintel^a, Martin Jordan^a, Rainer H. Meffert^a, Soenke P. Frey^b^a Dept. of Trauma-, Hand-, Plastics- and Reconstructive Surgery, University Clinics Wuerzburg, Oberduerrbacher Str. 6, D-97080 Wuerzburg, Germany^b Dept. of Orthopaedics and Trauma Surgery, St. Josef Hospital Bochum, University Clinics Bochum, Germany

ARTICLE INFO

Keywords:

Hemipelvectomy
Toddler
Survival
Limb salvage

ABSTRACT

We report on a 14 months old toddler who sustained a traumatic hemipelvectomy by being crushed between a car and a stone wall. After stabilization in the resuscitation room he was treated operatively by laparotomy, osteosynthesis of the pelvic ring, reconstruction of the both external iliac vessels and the urethra and reposition of the testicles. After 66 days he was discharged into rehabilitation. Implants were removed after eight months. 20 months after the injury, the leg was plegic, initial radiological signs of femoral head necrosis showed up but the infant was able to walk with an orthosis and a walker.

Up to our knowledge, this is the youngest patient described in the literature with a survived traumatic hemipelvectomy and salvaged limb.

Background

Traumatic hemipelvectomy is rare injury and mortality is high [1]. Less than 70 survivors are reported in the literature and successful limb salvage is extraordinary [2,3]. Less than ten children with this injury are reported in scattered case reports and up to now, the youngest patient to survive this devastating injury was 16 months old with a subsequent loss of his leg [4–6].

Case

The infant was sitting in a pushchair and was crushed by approximately 50 km/h fast jeep against a stone wall. He was administered 20 min after the accident to our trauma unit. Upon arrival in the resuscitation room he had a Glasgow Coma Scale of 11 and was in hemorrhagic shock with an initial haemoglobin-level of 8.5 g/dl. The patient showed an open wound above the left iliac crest with visible guts and an unstable pelvis at the clinical examination. **Without external compression there was extensive active bleeding out of the wound.** The left leg was pale, palsy and no pulses were not detachable by ultrasound. After a short diagnostic period with an ultrasound of the abdomen, x-rays of the thorax and pelvis and start of blood transfusion, the toddler was taken to immediate surgery (Fig. 1).

The priority in treatment was to control the active bleeding and to explore the amount of injury, being prepared for an acute complete surgical hemipelvectomy with immolation of the limb. An explorative laparotomy was performed, the aorta was **identified and** temporarily clamped and hematoma was washed out. The exploration showed following initial injuries: A degloving of the soft

* Corresponding author at: Oberduerrbacher Str. 6, D-97080 Wuerzburg, Germany.

E-mail address: jansen_h@ukw.de (H. Jansen).

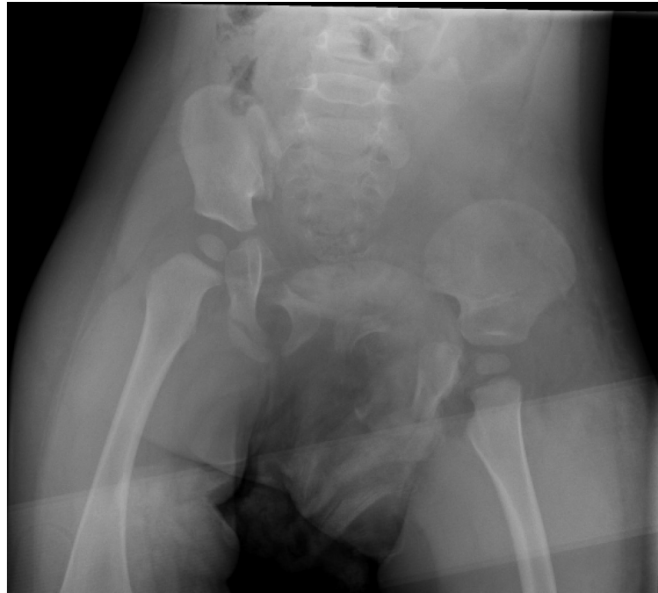


Fig. 1. X-ray of the pelvis.

tissues antero-lateral of the pubic bones. The guts were intact, the left external iliac artery and vein were ruptured, as well as the urethra at the membranaceous part. The bony pelvic ring was unstable with fractures of both upper and lower pubic bones and a severe sacro-iliac joint dislocation on the left side. The lumbosacral nerve was torn out of the leg above the level of the inguinal ligament and both testicles were dislocated into the belly. **The ruptured external artery and vein were clamped and aortic clamping could be repealed after a total of approximately 30 min.**

The bleeding diminished satisfactory, hemodynamics became more and more stable. As the injury of the external iliac vessels appeared reconstructable with a sensible amount of effort and no known practical experience of survived traumatic hemipelvectomies –much less in toddlers- existed (not to mention that in this situation there is no time for a prolonged research of the literature), the team proceeded in salvation of the limb by fixation of the fractures and reconstruction of the vessels:

Stabilization of the pelvic ring was performed by open reposition of the sacro-iliac joint and both superior pubic bones and osteosynthesis of the fractures using 2.8 mm angle-stable plates. A supraacetabular external fixator was additionally applied to achieve maximum stability (Fig. 2). Primary anastomosis of the external iliac artery and vein could be achieved (Fig. 3). After removing the clamp of the artery, peripheral pulses of the femoral and poplitealartery were detachable. After reposition of the testicles, a primary anastomosis of the urethra was undertaken. A suprapubic urine catheter was applied under sight and the abdomen was closed. Intraoperatively, a total of 1200 ml of blood, 400 ml of fresh frozen plasma and 150 ml of concentrated thrombocytes were administered. **Postoperative no more blood had to be administered with a constant haemoglobin-level of > 14 g/dl.**

The toddler was brought to the intensive care unit. Total operation time was 365 min (Figs. 4,5).

In the course of the first days, traumatic rhabdomyolysis with a peak of 40.000 U/l on the third day took place and was treated by forced diuresis. There were no signs for the onset of a crush kidney at any time, whether in the laboratory results or diminished urine production. In the course the soft tissue in the antero-lateral groin and anterior proximal thigh became necrotic. Revision surgery with necrosectomie, removal of the necrotic left testicle, removal of the external fixator and temporary vacuum sealing took place on the 30th day. Six days later (36th day) wound closure was achieved by a combination of a local skin flap and mesh graft from the thigh. Further wound healing was uneventful.

After successful weaning at the 11th day, the infant could be transferred to the normal pediatric ward on the 24th day and was dismissed for rehabilitation on the 66th day after initial trauma.

After eight months, the three plates were removed and the scars were revised with an uneventful intraoperative and postoperative course. Initial decentralization of the left femoral head was visible on the x-ray (Fig. 6).

At the last follow-up 20 months after the initial trauma, the child was independently mobile, using an orthosis for the left leg and a walker. The leg was well perfused but still palsy. On the x-ray, initial signs of femoral head necrosis were visible (Fig. 7).

Conclusion

To our knowledge, this is the youngest patient ever described in the literature with a survived traumatic hemipelvectomy and even a salvaged limb. The further course, especially regarding the palsy of the leg, ongoing of the femoral head necrosis and possible development of growth disorders have to be monitored.

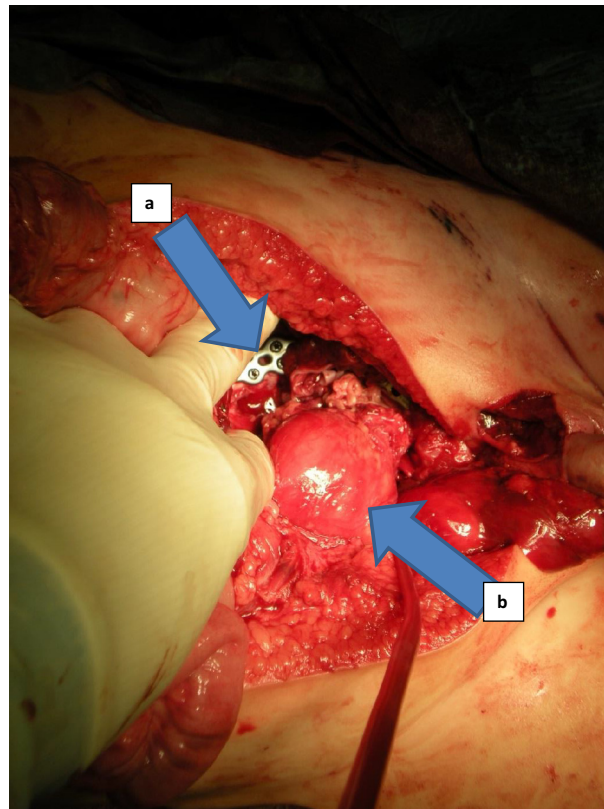


Fig. 2. Intraoperative view: 2.8 mm plate osteosynthesis of the iliaco-sacral joint (a) and exploration of the bladder (b).

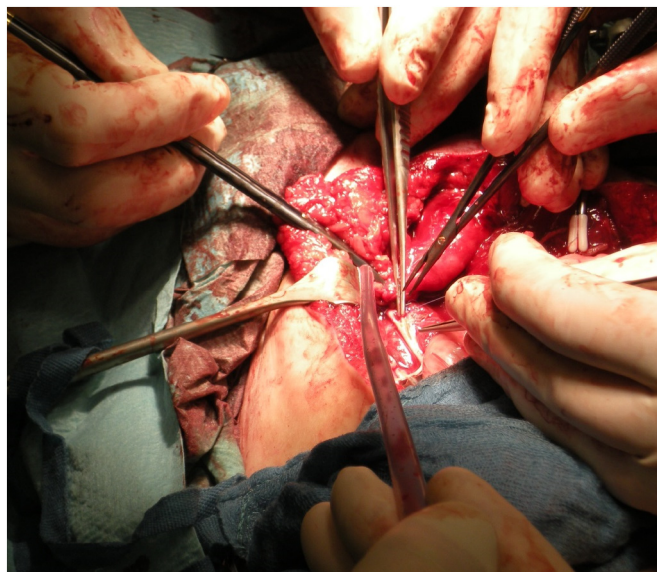


Fig. 3. Reconstruction of the external iliac artery.

Declaration of Competing Interest

The author reports no conflicts of interest in this work.

This publication was funded by the German Research Foundation (DFG) and the University of Wuerzburg in the funding programme Open Access Publishing.

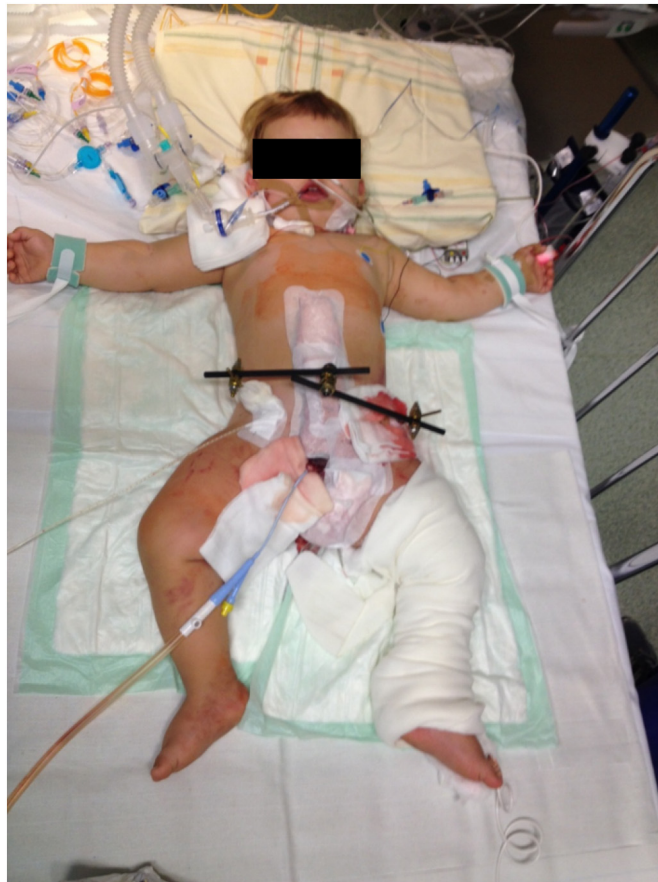

Fig. 4. Clinical view postoperatively.

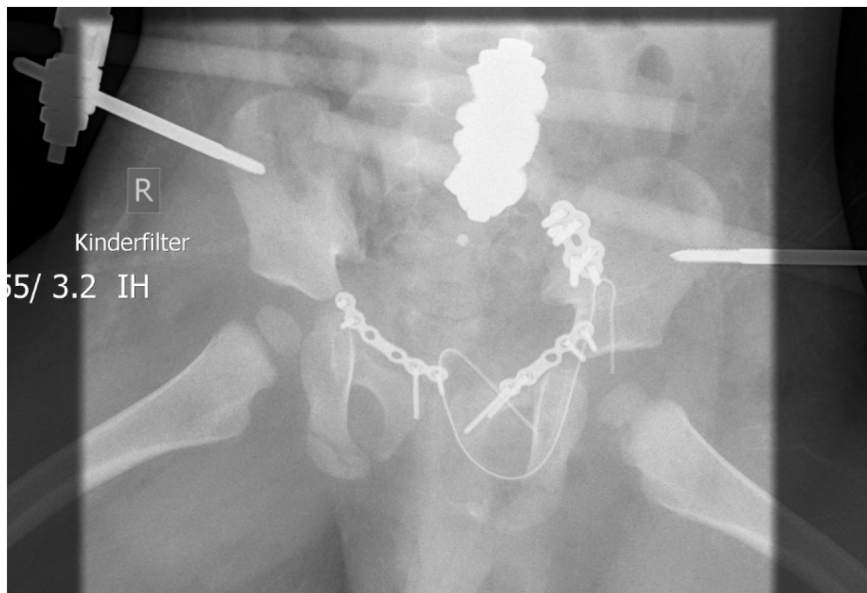


Fig. 5. X-ray postoperatively.

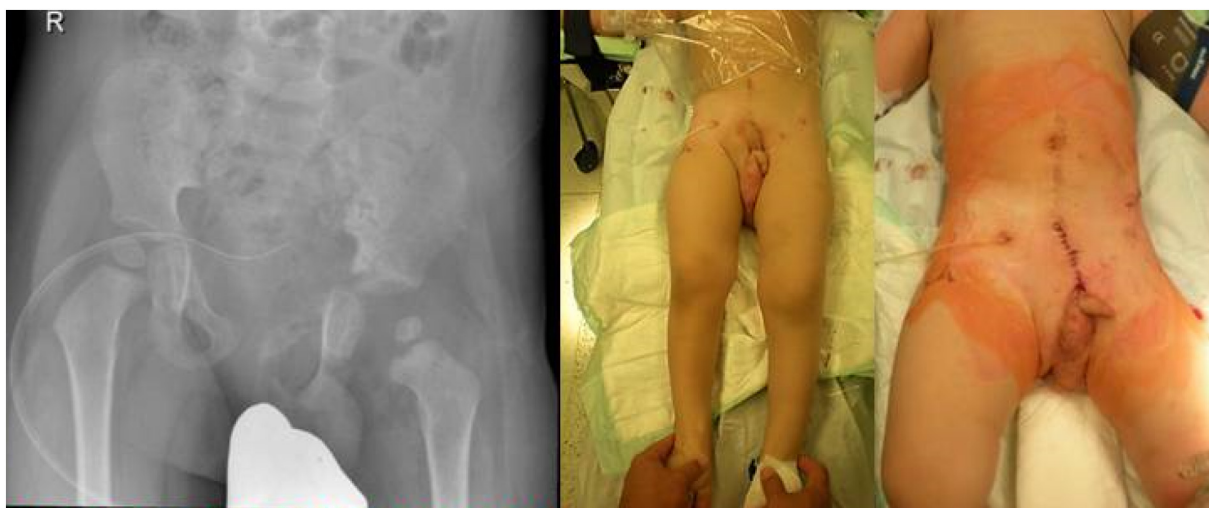

Fig. 6. X-ray and clinical aspect at the time of implant removal 8 months after injury.

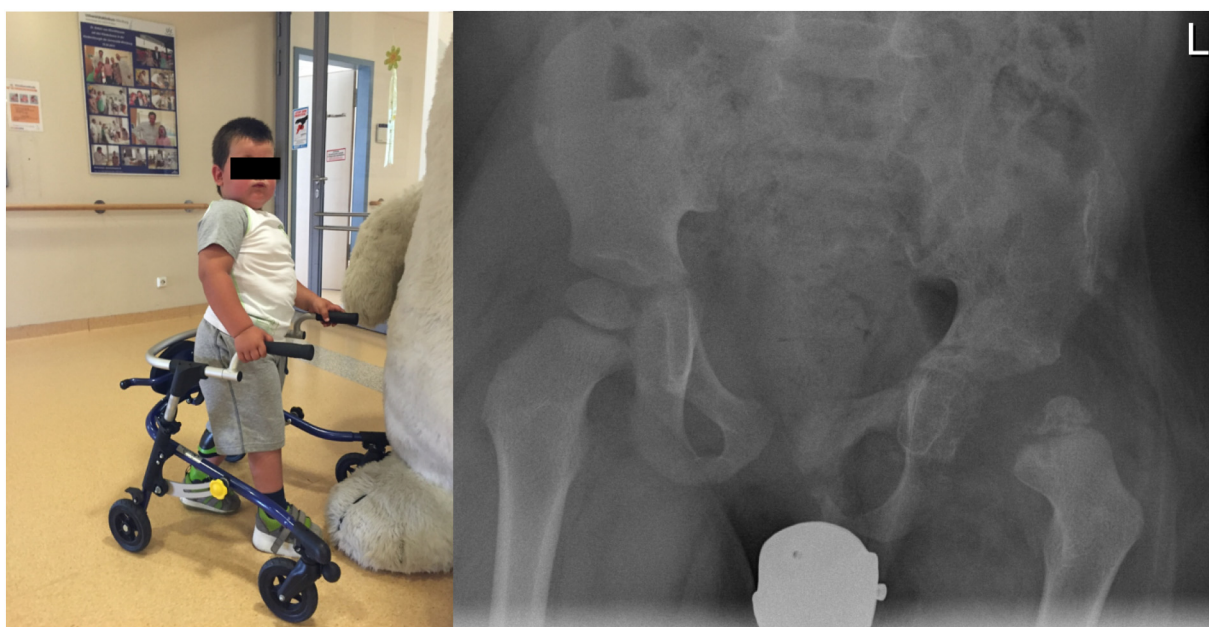


Fig. 7. Clinical and radiological follow-up 20 months after injury.

References

- [1] H. Rieger, K.H. Dietl, Traumatic hemipelvectomy: an update, *J. Trauma* 45 (1998) 422–426.
- [2] M. Osti, C. Mittler, M. Putzke, K.P. Benedetto, Traumatic hemipelvectomy: a report of successful reimplantation, *Injury* 37 (2006) 1015–1018.
- [3] T. Pohleman, C. Paul, A. Ganssle, G. Regel, H. Tscherne, Traumatic hemipelvectomy. Experiences with 11 cases, *Unfallchirurg* 99 (1996) 304–312.
- [4] S. Haim, Y. Laufer, K. Leonid, et al., Hemipelvectomy after severe pelvic injury in Factor VII deficiency toddler, *Injury* 46 (2015) 1178–1182.
- [5] R.J. Schoderbek, T.C. Battaglia, E.R. Dorf, D.M. Kahler, Traumatic hemipelvectomy: case report and literature review, *Arch. Orthop. Trauma Surg.* 125 (2005) 358–362.
- [6] W.M. Calonge, I. Alova, M.R. Ramos, et al., Traumatic hemipelvectomy in children: report on 2 survivors with urological involvement, *J. Pediatr. Surg.* 45 (2010) 2260–2264.