



## Case Report



## Laparoscopy and intraoperative enteroscopy, a helpful tool in a rare tumor (inflammatory fibroid polyp) of the small bowel. A case report

F. Xavier Moyón<sup>a</sup>, Gabriel A. Molina<sup>b,c,\*</sup>, Katherine Romero<sup>d</sup>, Miguel A. Moyón<sup>a,i</sup>,  
B. Andres Cardenas<sup>e</sup>, Jorge Tufiño<sup>a</sup>, Maria B. Almeida<sup>f</sup>, Hernán R. González<sup>g</sup>, Paola Moyon<sup>h</sup>

<sup>a</sup> Department of General Surgery at Hospital General San Francisco, IESS, Quito-Ecuador

<sup>b</sup> Hospital Iess Quito Sur, Quito-Ecuador

<sup>c</sup> Universidad San Francisco de Quito (USFQ), Quito-Ecuador

<sup>d</sup> PGY4 General Surgery (PUCE), Quito-Ecuador

<sup>e</sup> Department of Endoscopic Surgery at Hospital General San Francisco, IESS, Quito-Ecuador

<sup>f</sup> Department of Gastroenterology at Hospital General San Francisco, IESS, Quito-Ecuador

<sup>g</sup> Hospital de Especialidades Carlos Andrade Marín IESS, Quito-Ecuador

<sup>h</sup> Universidad Central del Ecuador (UCE), Quito-Ecuador

<sup>i</sup> Universidad de las Americas (UDLA), Quito-Ecuador

## ARTICLE INFO

## Keywords:

Inflammatory fibroid polyps

Small bowel tumors

Intraoperative enteroscopy

## ABSTRACT

**Introduction and importance:** Inflammatory fibroid polyps (IFPs) are rare, benign tumors that can arise throughout the gastrointestinal tract, they are usually asymptomatic, and clinical presentation depends on the site of involvement. Gastric and colon IFPs are traditionally identified incidentally, whereas small intestinal lesions are often encountered in the setting of intussusception or during imaging studies. Complete resection via endoscopy or surgery is recommended.

**Case presentation:** Patient is a 52-year-old male without past medical history; he had a five-month history of mild colicky abdominal pain. A mass was detected in the small bowel, and surgery was decided. Since the mass was small a cooperative approach with an intraoperative enteroscopy was needed to locate the mass and achieve complete resection.

**Discussion:** IFPs of the small bowel require complete resection. Surgery should be performed as early as possible to prevent complications like intussusceptions, ischemia, and necrosis.

**Conclusions:** In these rare tumors, the collaboration between surgeons and endoscopists is indispensable to improve the patient's prognosis.

## 1. Introduction

Inflammatory fibroid polyps (IFPs) one of the least common benign tumors [1,2]. They can be found throughout the gastrointestinal tract but most commonly in the gastric antrum or ileum [1]. The etiology of IFPs is still unknown, and in most cases, as symptoms are non-specific, preoperative diagnosis is challenging, and malignancy is suspected, resection is usually necessary [2]. In locations where endoscopic access is complex, a multidisciplinary approach becomes essential to improve patients' prognosis [1].

We present a case of an otherwise healthy 52-year-old male, he

presented with abdominal pain, and a mass was detected in the small bowel. After a laparoscopy combined with intra-operative enteroscopy, the mass was completely resected, and the patient underwent complete recovery. IFP was the final diagnosis.

This work has been reported in line with the SCARE 2020 criteria [11].

## 2. Case report

The patient is a 52-year-old male without past medical history; he had a five-month history of mild colicky abdominal pain. At first, the

\* Corresponding author. Hospital Iess Quito Sur & Department of General Surgery, Universidad San Francisco de Quito, Quito, MD, Ecuador.

E-mail addresses: [xavomcons@hotmail.com](mailto:xavomcons@hotmail.com) (F.X. Moyón), [gabomolina32@gmail.com](mailto:gabomolina32@gmail.com) (G.A. Molina), [angelicakatherineromero@gmail.com](mailto:angelicakatherineromero@gmail.com) (K. Romero), [mmoyon.surgeon@gmail.com](mailto:mmoyon.surgeon@gmail.com) (M.A. Moyón), [bolocardenas@yahoo.com.mx](mailto:bolocardenas@yahoo.com.mx) (B.A. Cardenas), [jorgetufino@msn.com](mailto:jorgetufino@msn.com) (J. Tufiño), [belenalmeida2@hotmail.com](mailto:belenalmeida2@hotmail.com) (M.B. Almeida), [hernangonzalezospina@gmail.com](mailto:hernangonzalezospina@gmail.com) (H.R. González), [paodanymc@gmail.com](mailto:paodanymc@gmail.com) (P. Moyon).

<https://doi.org/10.1016/j.amsu.2021.102355>

Received 22 February 2021; Received in revised form 16 April 2021; Accepted 25 April 2021

Available online 12 May 2021

2049-0801/© 2021 The Authors. Published by Elsevier Ltd on behalf of IJS Publishing Group Ltd. This is an open access article under the CC BY-NC-ND license

(<http://creativecommons.org/licenses/by-nc-nd/4.0/>).

pain was diffuse and accompanied by abdominal distention and flatulence; these symptoms became more frequent over time and were accompanied by a 3kg weight loss and frequent episodes of postprandial vomits; thus, he presented to our office. Clinical evaluation was unremarkable, mild pain on touch was found in the lower abdomen without tenderness, but no masses or lymph nodes were found. Laboratory exams, abdominal x-ray, abdominal echography, upper endoscopy, and colonoscopy were requested; however, they all returned normal, and still, the patient remained with these symptoms. Therefore a contrast-enhanced computed tomography (CT) was requested, revealing a 22 mm mass in the small bowel; the tumor had an asymmetrical but circumferential wall thickening with associated luminal dilatation, and most of the mass protruded into the lumen, no other masses, free liquid or lymph nodes were seen (Fig. 1a and b). With these findings, surgical consultation was required, and a laparoscopic approach was decided.

On laparoscopy, no masses or lymph nodes were detected. A thorough evaluation of the small bowel from the ileocecal valve to the Treitz ligament was done; regrettably, we couldn't locate the tumor. Due to this, a laparoscopy combined with intra-operative enteroscopy was decided. The combined effort of general surgery and gastroenterology was needed and enabled both the mucosal and serosal surfaces of the bowel to be inspected.

A small 0.5 cm enterotomy was made in the ileum, 10 cm away from the ileocecal valve; the endoscope was inserted, and laparoscopic-assisted enteroscopy was performed (Fig. 2a & b). We achieved a complete examination of the small bowel, and we finally located the tumor. The grayish, polyp-like mass was found 1-m distally from the ligament of Treitz, causing partial obstruction of the small bowel lumen. After this, the endoscope was removed, and the enterotomy was closed with an absorbable suture. The tumor was resected entirely with margins, and a side to side anastomosis was completed, the rest of the procedure was achieved without complications (Fig. 3a & b).

Pathology reported a 25 mm, pedunculated grey tumor that projected into the bowel lumen. Its mucosal surface was pale without ulcers, and on microscopic evaluation, a vascular and fibroblast proliferation was found with multiple eosinophils and spindle cells infiltrate. Immunohistochemistry was negative for KIT, DOG-1, S100, and positive for vimentin. Inflammatory fibroid polyp of the small bowel was the final diagnosis.

His postoperative course was uneventful; sips of liquids were started on his first postoperative day and were followed by a full diet. He was discharged without complication on his third postoperative day. On

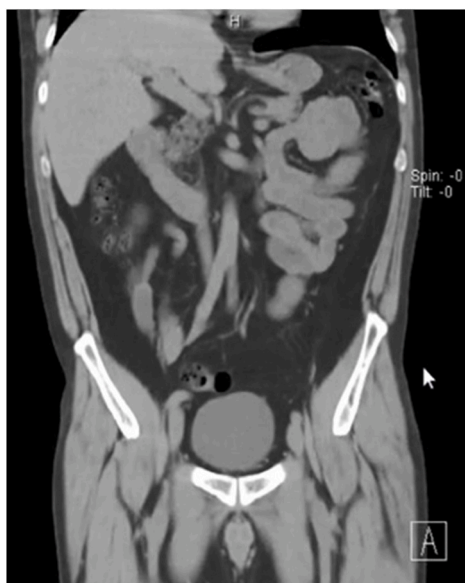

Fig. 1a. CT revealing dilated loops of small bowel.

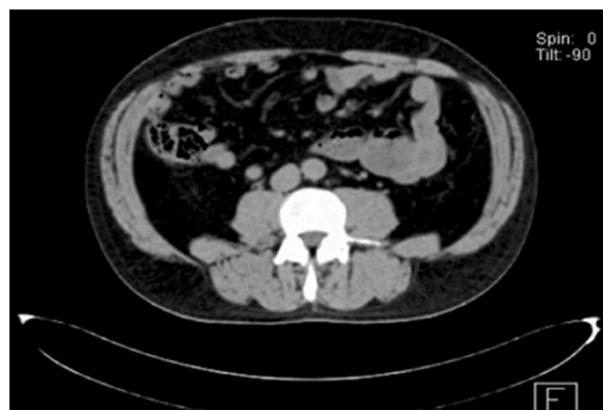


Fig. 1b. CT, a mass is seen in the bowel.

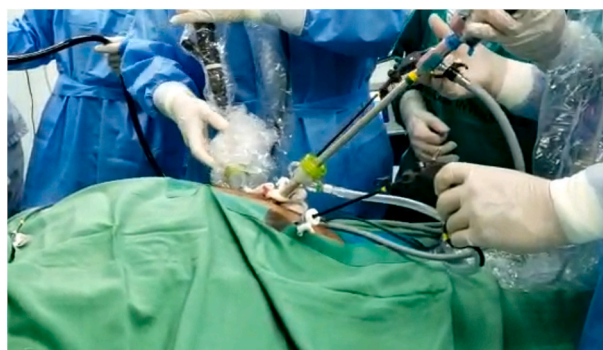


Fig. 2a. Laparoscopy combined with intraoperative enteroscopy.

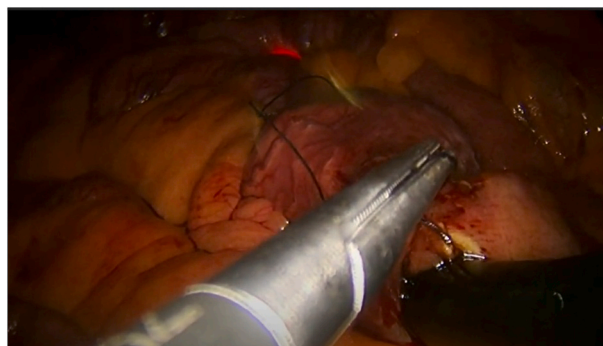


Fig. 2b. Tumor is finally located, and resected.

follow-ups, the patient is doing well and has completely recovered six months after surgery.

### 3. Discussion

Inflammatory fibroid polyps (IFP) are rare idiopathic and benign tumors of the gastrointestinal tract. Vanek first described them in 1949 as a submucosal granuloma with eosinophilic infiltration [1,2]. They are extremely rare, generally solitary, and intraluminal masses that can affect any part of the gastrointestinal tract. (Gastric antrum 66%, small bowel 20%, colorectal, 4%, gallbladder 1% esophagus 1%) [2,3]. These lesions show a slight female preponderance (1.3:1) and occur over a wide age range, varying from 2 to 90 years [1,4]. In our case, our patient was an otherwise young male patient with an IFP in his jejunum.

Although the exact pathophysiology and etiology are still under study, it is presumed that these tumors appear as a response to an



Fig. 3a. Inflammatory fibroid polyp of the small bowel.

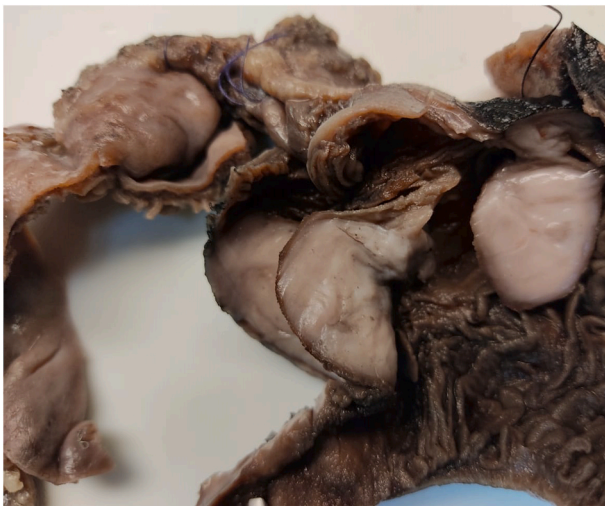


Fig. 3b. Tumor obstructing the bowel lumen.

infection, trauma, bacterial, allergic reaction, or even autoimmune reaction [1,3,5]. Even if it is described as a benign tumor, a malignant potential might be present, although infrequent due to its unknown etiology [1,4]. In recent years a PDGFR-A mutation has been implicated as a critical element in their pathogenesis and is still under research [2,3]. In our patient, we didn't recognize any etiology for his jejunal IFP.

IFPS appear as solitary, polypoid, or sessile lesions and usually measure less than 5 cm [2,6]. They are submucosa-based; nonetheless, they almost always extend into the mucosa [1]. They typically have dilated blood vessels at their base and can have a smooth or ulcerated surface [3,4]. They are formed by a proliferation of vascular fibrous tissue from the submucosa with an extensive inflammatory response, mostly composed of eosinophils [2,4]. They contain spindle cells without proliferative activity and can show positivity for desmin, CD34, CD117, and S100 [3]. As it was found in our patient.

IFP are usually asymptomatic and can remain undetected until their size and location cause problems to the surrounding organs [1,7]. Unfortunately, when they become symptomatic, their symptoms are generally non-specific and can be easily missed [1,2]. Abdominal pain is the prominent symptom followed by obstruction, vomiting, diarrhea, and gastrointestinal bleeding [3,4]. Patients with IFPs of the small bowel usually present with chronic episodes of colicky pain, GI bleeding, and rarely obstruction, perforation, or intussusception [5,8]. In our case, our

patient experienced chronic episodes of abdominal pain and weight loss.

Diagnosis is difficult based only on clinical symptoms, and complementary exams are needed to aid in the diagnosis [1,2]. Ultrasound and abdominal x-ray can be helpful. Nonetheless, abdominal CT is the most used method to diagnose enteric lesions larger than 3 cm [1,9]. Endoscopy or colonoscopy can be used in gastric or colonic lesions; however, in small bowel lesions, if a double-balloon endoscopy is not available, it can be challenging to assess the polyp [1,5]. Although capsule endoscopy can be useful, intraoperative endoscopy can help localize a suspicious lesion during surgery allowing the surgeon to mark the site with a suture on the small bowel serosa prior to small bowel resection or biopsy [10]. Although the CT revealed the small bowel tumor, due to its size, we couldn't detect it on laparoscopy; nonetheless, with the aid of an intraoperative enteroscopy, we founded the tumor and resected it.

Malignancy, lipomas, leiomyomas, adenomas, and GIST are among the differential, and since diagnosis is difficult, complete resection is typically required [1,2]. Endoscopic resection can be useful, nonetheless, as the risk of malignancy cannot be overruled when approaching a small bowel tumor, and complete resection is usually necessary [3,4]. Following resection, IFPS typically do not recur [1,6].

#### 4. Conclusions

When treating rare pathologies like IFP, teamwork, the availability of multiple surgical techniques, and strong support from the medical staff can completely change the patient's prognosis. In these scenarios, the collaboration between surgeons and endoscopists will only benefit the patient, and if available, we should hesitate to be part of them.

In a special way, this case proves that an adequate restructuring concerning schedules and workload will be crucial to enhance personnel availability. In these tumors and many other diagnoses, time is of the essence, and many patients don't have the luxury of losing it. Adequate care, precise diagnosis, and sufficient trained personnel will ultimately improve the patient's prognosis.

#### Patient perspective

At first, the patient was unsure about his treatment, he was scared as he heard the word "tumor". Nonetheless, after the final diagnosis he was calmed and grateful to the medical team.

#### Ethical approval

We have written permission from our ethics committee.

#### Sources of funding

No funding.

#### Author contribution

All authors read and approved the final manuscript.

XM played a key role in drafting the manuscript, GM wrote the manuscript and collected key data of the patient, AC and MA, helped us with the enteroscopy and writing the manuscript, MM and helped us in correcting the manuscript and revising the paper, HG and PM revised the manuscript and helped writing the final version of the paper.

#### Registration of research studies

None.

#### Guarantor

Gabriel A. Molina MD, IESS Quito Sur and Universidad San Francisco de Quito (USFQ), Quito-Ecuador, [gabomolina32@gmail.com](mailto:gabomolina32@gmail.com), + 593

998352535.

### Consent

Written informed consent was obtained from the patient for publication of this case report and accompanying images. A copy of the written consent is available for review by the Editor-in-Chief of this journal on request.

### Provenance and peer review

Not commissioned, externally peer-reviewed.

### Funding

No funding was obtained for this study.

### Declaration of competing interest

The authors certify that they have no affiliations with or involvement in any organization or entity with any financial interest, or non-financial interest in the subject matter or materials discussed in this manuscript. We have no conflict of interest to disclose. The submission has not been previously published, nor is it with another journal for consideration. All authors listed on the paper have reviewed and approved the manuscript in its current form and are aware that it has been submitted.

### Acknowledgments

None.

### References

- [1] B. Abboud, Vanek's tumor of the small bowel in adults, *World J. Gastroenterol.* 21 (16) (2015) 4802, <https://doi.org/10.3748/wjg.v21.i16.4802>.
- [2] N. Garpis, C. Damaskos, A. Garpis, V.E. Georgakopoulou, S. Sakellariou, A. Liakea, D. Dimitroulis, Inflammatory fibroid polyp of the gastrointestinal tract: a systematic review for a benign tumor, *Vivo*, <https://doi.org/10.21873/inviv.o.12235>, 2021, 35, 1, 81-93.
- [3] S. Akbulut, Intussusception due to inflammatory fibroid polyp: a case report and comprehensive literature review, *World J. Gastroenterol.* 18 (40) (2012) 5745, <https://doi.org/10.3748/wjg.v18.i40.5745>.
- [4] F. Smith-Chakmakova, YJ Liu, DM Karamchandani, Inflammatory Fibroid Polyp of the Ileocecal Valve: Case Report, Review, and Recent Advances, *Ann Clin Lab Sci.* 45 (4) (2015) 441–445. Summer; PMID: 26275697, <https://pubmed.ncbi.nlm.nih.gov/26275697/>.
- [5] T.-C. Liu, M.-T. Lin, E.A. Montgomery, A.D. Singhi, Inflammatory fibroid polyps of the gastrointestinal tract, *Am. J. Surg. Pathol.* 37 (4) (2013) 586–592, <https://doi.org/10.1097/pas.0b013e31827ae11e>.
- [6] O. Daum, O. Hes, T. Vanecek, Z. Benes, R. Sima, M. Zamecnik, M. Michal, Vanek's tumor (inflammatory fibroid polyp). Report of 18 cases and comparison with three cases of original Vanek's series, *Ann. Diagn. Pathol.* 7 (6) (2003) 337–347, <https://doi.org/10.1016/j.anndiagpath.2003.09.003>.
- [7] S. Rehman, Z. Gamie, T.R. Wilson, A. Coup, G. Kaur, Inflammatory fibroid polyp (Vanek's tumour), an unusual large polyp of the jejunum: a case report, *Cases J.* 2 (1) (2009) 7152, <https://doi.org/10.1186/1757-1626-2-7152>.
- [8] J. Vanek, Gastric submucosal granuloma with eosinophilic infiltration, *Am. J. Pathol.* 25 (3) (2020).
- [9] H. Neishaboori, I. Maleki, O. Emadian, Jejunal intussusception caused by a huge Vanek's tumor: a case report, in: *Gastroenterology and Hepatology from Bed to Bench* 6, 2013, pp. 210–213, 4, <https://www.ncbi.nlm.nih.gov/pmc/articles/PMC4017524/>.
- [10] T.A. Bowden, V.H. Hooks, A.R. Mansberger, Intraoperative gastrointestinal endoscopy, *Ann. Surg.* 191 (6) (1980) 680–687, <https://doi.org/10.1097/0000658-198006000-00004>.
- [11] R.A. Agha, T. Franchi, C. Sohrabi, G. Mathew, for the SCARE Group, The SCARE 2020 guideline: updating consensus surgical CAse REport (SCARE) guidelines, *Int. J. Surg.* 84 (2020) 226–230.