

## Staged correction of an equinovarus deformity due to pyoderma gangrenosum using a Taylor spatial frame and tibiotalar calcaneal fusion with an intramedullary device

Jaime L. Bellamy · Courtney A. Holland ·  
Mark Hsiao · Joseph R. Hsu · STReC (Skeletal Trauma  
Research Consortium)

Received: 24 April 2009 / Accepted: 9 August 2011 / Published online: 24 August 2011  
© The Author(s) 2011. This article is published with open access at Springerlink.com

**Abstract** Pyoderma gangrenosum is a rare autoinflammatory syndrome manifested by skin lesions eventually creating ulcers. Surgical management can lead to scarring and contracture at the site of the lesion due to the pathergy phenomenon. A 43-year-old woman presented with a 5-year history of severe equinovarus deformity due to chronic pyoderma gangrenosum on her posteromedial ankle. She underwent a staged fusion. A gradual “closed” correction was performed in a Taylor spatial frame for 8 weeks in order to obviate the need for a surgical release in the area of the ulcer. She was ambulatory and full weight-bearing within 4 weeks of her frame removal. She maintained her correction with an accommodative foot orthosis until she had an uneventful tibiotalar calcaneal fusion with an intramedullary device. This case represents the success of using a Taylor spatial frame for staged fusion involving soft-tissue correction of severe, rigid equinovarus deformity due to pyoderma gangrenosum.

**Keywords** Pyoderma gangrenosum · Equinovarus · Staged fusion · Taylor spatial frame

### Introduction

Pyoderma gangrenosum (PG) is a rare autoinflammatory syndrome of unknown etiology. In up to 70% of cases, PG is associated with underlying systemic disease, such as inflammatory bowel disease, rheumatoid arthritis or malignancy [1]. PG is a noninfectious neutrophilic dermatosis that causes recurrent painful inflammatory ulcerations [2]. Lesions are commonly found on the dorsal surface of the feet and legs but may occur on the arms, chest, stoma and the face. Skin lesions are tender, contain fluctuant nodules with surrounding erythema and spread peripherally creating an ulcer. Additionally, epidermal necrosis gives ulcers a blue hue [3]. Successful treatment most importantly involves addressing the underlying disease.

PG management includes medical and surgical modalities. The unknown etiology and pathophysiology have made the treatment for PG difficult [4]. Management of PG is divided into systemic and topical medical therapy and local wound care with surgical debridements [5]. Recently, infliximab and tacrolimus have been shown to be effective systemic and topical medical treatments for PG, respectively [6, 7]. Wound debridement has been beneficial but has the potential to worsen the lesion due to the pathergy phenomenon. Pathergy is the development of new skin lesions at sites of minor trauma, biopsy or needle sticks [8]. This phenomenon of PG limits and complicates surgical procedures as repeated debridements can lead to scarring and contracture at the site of the lesion.

Contractures over tendons of the foot can lead to foot deformities. The posterior tibialis and the flexor digitorum

---

J. L. Bellamy (✉)  
Brooke Army Medical Center, Fort Sam Houston,  
San Antonio, TX, USA  
e-mail: jaime.bellamy@amedd.army.mil

C. A. Holland  
William Beaumont Army Medical Center, El Paso,  
TX, USA  
e-mail: courtney.holland@amedd.army.mil

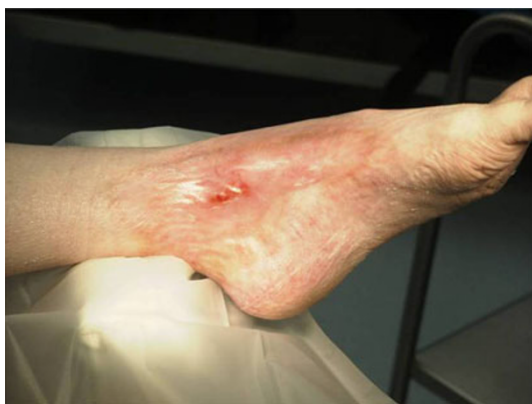M. Hsiao  
Creighton University, Omaha, NE, USA

J. R. Hsu  
United States Army Institute of Surgical Research,  
Fort Sam Houston, San Antonio, TX, USA  
e-mail: joseph.hsu@amedd.army.mil

longus muscles pull the foot into an equinus and cavovarus position. Severe scarring after burns, crush injuries or venous stasis may pull the foot into the cavovarus position [9]. Equinovarus foot deformities are most often due to spasticity of the posterior tibialis muscle and/or the anterior tibialis muscle, which are active in the stance phase and swing phase of gait, respectively. For body weight to advance onto the forefoot, a 5° angle is necessary and is often absent with a plantar flexion contracture [10]. The most common surgical treatments for foot deformities due to soft-tissue malfunction include tendon releases, tendon transfers and arthrodesis [11, 12]. We describe a case using gradual “closed” correction using the Taylor spatial frame (TSF; Smith & Nephew, Memphis, Tennessee) technique.

### Case report

A 43-year-old woman presented with a severe (80° equinus), rigid equinovarus foot deformity due to chronic PG.



**Fig. 1** Pre-operative pyoderma gangrenosum

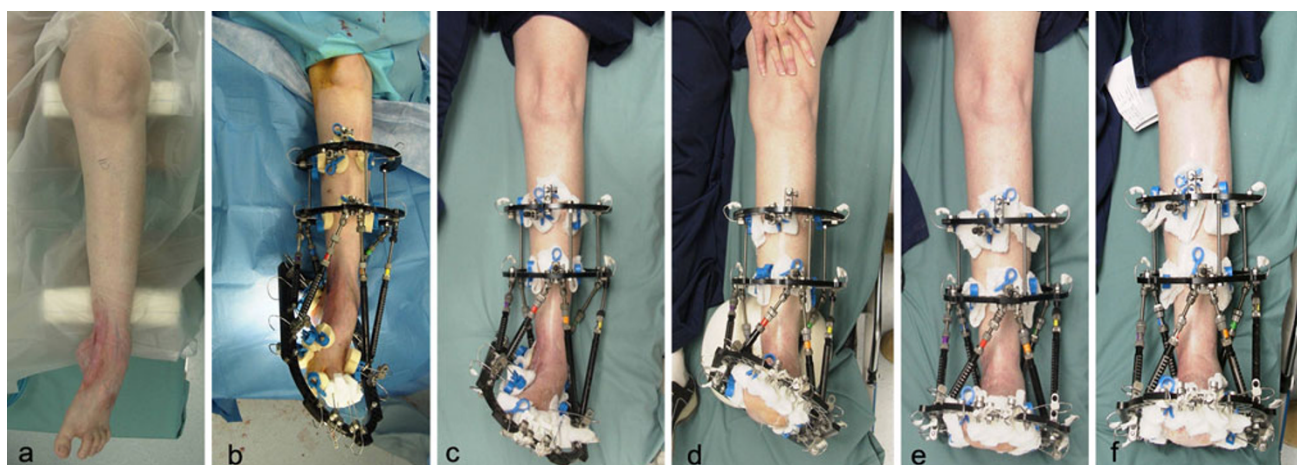
She had a 5-year history of a large, nonhealing ulcer centered over the left medial malleolus and underwent multiple debridements resulting in her worsening scar tissue (Fig. 1). The patient gradually developed a severe equinovarus deformity (Fig. 2a). It progressed to the point that she was non-weight-bearing for 3 years prior to this intervention. Pre-operative computed tomography demonstrated loss of articular space along the posterior one-third of the tibial plafond and talus.

The likelihood of an eventual fusion was discussed with the patient. She desired to stage the fusion. In her case, a one-stage arthrodesis would have likely necessitated an open posteromedial release directly through the zone of inflammation. Furthermore, a single-stage approach may have required a complete talectomy with resultant shortening to safely achieve the correction without neurovascular compromise.

To avoid an open surgical release to achieve correction, which could exacerbate her PG, a gradual “closed” correction was performed using a TSF. The posteromedial skin edge was designated as the “structure at risk” so it and the underlying tibial neurovascular bundle could be stretched no more than 1 mm a day.

### Surgical technique

A standard equinus correction frame was constructed with a TSF. The frame was fixed to the extremity with a combination of wires and hydroxyapatite (HA)-coated half-pins. Additional points of fixation were added at each level due to the patient’s extreme disuse osteopenia. Despite this severe osteopenia, HA-coated half-pins were utilized in a crossing manner in the calcaneus with adequate purchase [13]. We elected not to fix the talus with a transosseus wire, since this would have placed the wire directly through the



**Fig. 2** Pre-operative (a) and intra-operative placement of TSF (b). Twenty days (c), 5 weeks (d), 6 weeks (e) and 8 weeks (f) post-operative gradual correction in the TSF

zone of inflammation. We performed no open or percutaneous soft-tissue releases.

We utilized the TSF software to create a “virtual hinge” at the center of rotation of the ankle. This “virtual hinge” allowed precise correction of the deformity without the need for frame adjustments beyond routine strut changes as described by the software.

The TSF software allows for the identification of a “structure at risk” (SAR). The SAR can then be used to determine the pace of the correction. We defined the posteromedial skin edge as the SAR, so we could stretch this slowly at 1 mm/day. This slow, gradual correction took 8 weeks (Fig. 2b–f). We held the foot in an overcorrected position for an additional 4 weeks. At frame removal, the patient was placed in a custom accommodative foot orthosis for maintenance of the correction.

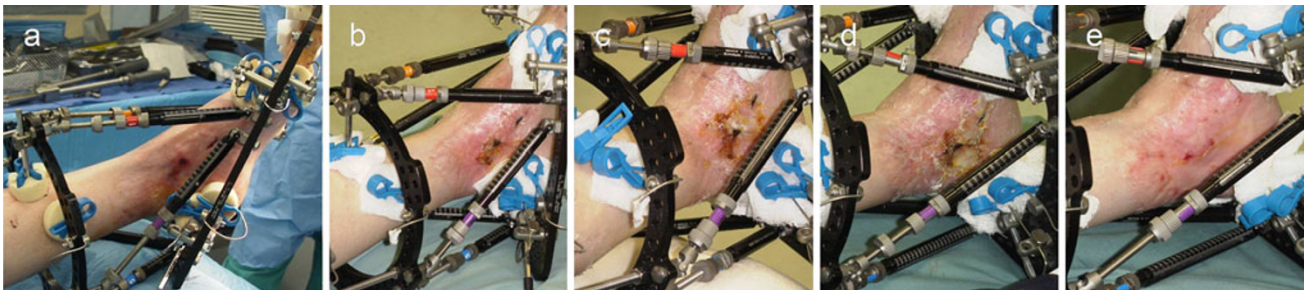
The patient’s longstanding deformity was corrected without additional incisions beyond those necessary for percutaneous placement of wires and half-pins. No open soft-tissue releases were required. There were no deep pin tract infections. The half-pins in the calcaneus did not loosen and had adequate extraction torque at the time of removal. There was no neurovascular compromise. The patient did not have an exacerbation of her PG (Fig. 3a–e).

The patient was ambulatory and full weight-bearing within 4 weeks of her frame removal. She maintained her correction with an accommodative foot orthosis until she had an uneventful tibiotalar calcaneal fusion with an intramedullary device (Fig. 4a–b). She is currently more than 18 months from her “closed” procedure with the TSF and 6 months from her ankle arthrodesis. She has healed her fusion without signs of deep infection. She has a minimal leg length discrepancy (<1 cm) and has no pain in the ankle or hind foot.

## Discussion

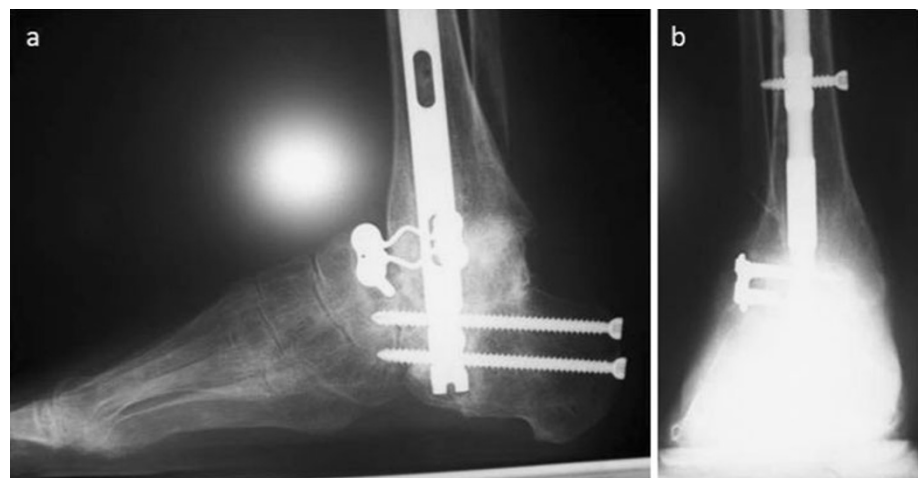
PG is a rare autoinflammatory syndrome of unknown etiology in which treatment is complicated by the pathergy phenomenon: debridements that scar can lead to contractures and subsequent foot deformities. Tendon releases, tendon transfers, arthrodesis and ring external fixators, like the TSF, may be used to correct these deformities.

The TSF is safe and minimally invasive. The slow, gradual correction obviated the need for an open surgical procedure to obtain correction. Due to the pathergy phenomenon, surgical release of tendons would likely



**Fig. 3** Intra-operative PG (a). Twenty days (b), 5 weeks (c), 6 weeks (d) and 8 weeks (e) post-operative in the TSF showed no exacerbation of PG

**Fig. 4** Lateral (a) and AP (b) post-operative tibiotalar calcaneal fusion with an intramedullary device



exacerbate soft-tissue injury in patients with PG. The TSF is an external fixation device that achieves correction by stretching soft tissues gradually [13–15], including foot and ankle deformities [14, 16, 17], over time. There are no reported cases in the literature regarding surgical correction of complex rigid equinovarus foot deformities due to PG.

The benefits of a gradual correction over acute correction with fusion in our case were twofold. First, this eliminated the need for a medial incision through the ulcer to release the scar contracture. Second, this allowed for correction to a plantigrade foot without neurovascular compromise. A safe acute correction would have necessitated unacceptable shortening and possible talectomy. In this case, the patient was ambulatory and full weight-bearing within 4 weeks after frame removal. This case highlights the TSF technique as a powerful tool for safe treatment for severe, rigid equinovarus deformity due to PG.

**Open Access** This article is distributed under the terms of the Creative Commons Attribution License which permits any use, distribution and reproduction in any medium, provided the original author(s) and source are credited.

## References

1. Su WP, Davis MD, Weenig RH, Powell FC, Perry HO (2004) Pyoderma gangrenosum: clinicopathologic correlation and proposed diagnostic criteria. *Int J Dermatol* 43:790–800
2. Fonder MA, Lazarus GS, Cowan DA, Aronson-Cook B, Kohli AR, Mamelak AJ (2008) Treating the chronic wound: a practical approach to the care of nonhealing wounds and wound care dressings. *J Am Acad Dermatol* 58:185–206
3. Ma G, Jones G, MacKay G (2002) Pyoderma gangrenosum: a great marauder. *Ann Plast Surg* 48(5):546–552
4. Su WPD, Schroeter AL, Perry HO, Powell FC (1986) Histopathologic and immunopathologic study of pyoderma gangrenosum. *J Cutan Pathol* 13:323–330
5. Gettler S, Rothe M, Grin C et al (2003) Optimal treatment of pyoderma gangrenosum. *Am J Clin Dermatol* 4:597–608
6. Brooklyn TN et al (2006) Infliximab for the treatment of pyoderma gangrenosum: a randomized, double blind, placebo controlled trial. *Gut* 55:505–509
7. Chiba T, Isomura I, Suzuki A et al (2005) Topical tacrolimus therapy for pyoderma gangrenosum. *J Dermatol* 32:199–203
8. Callen JP, Jackson JM (2007) Pyoderma gangrenosum: an update. *Rheum Dis Clin N Am* 33:787–802
9. Younger ASE, Hansen ST (2005) Adult cavovarus foot. *J Am Acad Orthop Surg* 13:302–315
10. Simon SR et al (2000) Kinesiology. In: Buckwalter JA, Einhorn TA, Simon SR (eds) *Orthopaedic basic science: biology and biomechanics of the musculoskeletal system*, 2nd edn. American Academy of Orthopaedic Surgeons, Rosemont, pp 731–827
11. Sammarco GJ, Taylor R (2001) Combined calcaneal and metatarsal osteotomies for the treatment of cavus foot. *Foot Ankle Clin* 6:533–543
12. Giannini S, Ceccarelli F, Benedetti MG, Faldini C, Grandi G (2002) Surgical treatment of adult idiopathic cavus foot with planar fasciotomy, naviculocuneiform arthrodesis, and cuboid osteotomy. *J Bone Joint Surg Am* 84(Supp 2):62–69
13. Catagni MA (2002) Hindfoot. In: Maiocchi AB (ed) *Atlas for the insertion of transosseous wires and half-pins: ilizarov method*. Medi Surgical Video, Italy, p 45
14. Conway JD (2008) Charcot salvage of the foot and ankle using external fixation. *Foot Ankle Clin N Am* 13:157–173
15. Greisberg J (2004) Recent innovations and future directions in external fixation of the foot and ankle. *Foot Ankle Clin N Am* 9:637–647
16. Pinzur MS (2008) Simple solutions for difficult problems: a beginner's guide to ring fixation. *Foot Ankle Clin N Am* 13:1–13
17. Beaman DN, Bellman RG (2008) The basics of ring external fixator application and care. *Foot Ankle Clin N Am* 13:15–27