

Received: 2018.12.02
Accepted: 2019.03.11
Published: 2019.07.03

Management of Extracranial Carotid Artery Aneurysms: A 6-Year Case Series

Authors' Contribution:

Study Design A
Data Collection B
Statistical Analysis C
Data Interpretation D
Manuscript Preparation E
Literature Search F
Funds Collection G

ABE 1,2 **Zuoguan Chen***
BE 2,3 **Lidan Chen***
B 4 **Jun Zhang***
F 2,5 **Yuexin Chen**
B 2,5 **Changwei Liu**
C 1,2 **Yongpeng Diao**
D 1,2 **Yuqing Miao**
C 1,2 **Qing Gao**
ADF 1,2 **Yongjun Li**

1 Department of Vascular Surgery, Beijing Hospital, National Center of Gerontology, Beijing, P.R. China
2 Peking Union Medical College, Chinese Academy of Medical Science, Beijing, P.R. China
3 Department of Craniomaxillofacial Plastic Surgery, Plastic Surgery Hospital, Chinese Academy of Medical Science, Beijing, P.R. China
4 Department of Vascular Surgery, Hefei Binhu Hospital, Third Affiliated Hospital of Anhui Medical University, Hefei, Anhui, P.R. China
5 Department of Vascular Surgery, Peking Union Medical College Hospital, Beijing, P.R. China

* These authors contributed equally to this work (Zuoguan Chen and Lidan Chen are co-first authors)

Corresponding Author: Yongjun Li, e-mail: liyongjun4679@bjhmoh.cn
Source of support: Departmental sources

Background: We discuss the presentation and management of extracranial carotid artery aneurysms (ECAAs) and to develop a new type of classification.





Material/Methods: A retrospective review of 35 ECAAs patients who were admitted in our institution from January 2010 to June 2016 was conducted. The mean follow-up period was 25.58±22.13 months.

Results: During the study period, 35 aneurysms were diagnosed and treated (mean age, 50.8±15.6 years; 15 men). There were 28 true aneurysms, 5 false aneurysms, and 2 dissecting aneurysms. A total of 16 patients with true aneurysms underwent open surgical treatment (group 1), whereas 15 received endovascular management, including all false and dissecting aneurysms (group 2). The remaining 4 true aneurysms were treated with hybrid operation (group 3). The patency rates of groups 1, 2, and 3 were 100%, 93.3%, and 100%, respectively. According to the Peking Union Medical College Hospital (PUMCH) Classification, all 24 cases of type Ia aneurysms were treated by either open surgery and/or endovascular treatment, whereas all 3 type Ib cases were treated solely by open surgery. All 5 type IIa patients were treated by endovascular treatment, with the exception of 1 failure that was transferred to hybrid operation. All 3 type IIb patients were treated by hybrid operation.

Conclusions: Open surgery was more frequently feasible in true aneurysms, and endovascular surgery was the first choice for false and dissecting aneurysms. Hybrid operation was available for complicated cases. The PUMCH classification may be helpful for selection of management strategies for ECAAs.

MeSH Keywords: **Aneurysm • Arteriovenous Shunt, Surgical • Carotid Artery Diseases • Endovascular Procedures • Two-Hybrid System Techniques**

Full-text PDF: <https://www.medscimonit.com/abstract/index/idArt/914374>

 2951  3  3  20



Background

Extracranial carotid artery aneurysms (ECAAs) are an uncommon yet serious condition [1,2]. The morbidity and mortality rates of ECAAs are high if the condition remains untreated. ECAAs are usually distinguished in true aneurysms, false aneurysms, and dissecting aneurysms [3,4]. The etiology of ECAAs is diverse and ranges from atherosclerosis to infection and trauma [5]. An ECAA may present with central neurologic symptoms due to cerebral embolism, although it may also present with mass, pain, and/or local compression that causes nerve palsy. Vascular surgical intervention is frequently considered essential to relieve local symptoms and decrease the risk of stroke and aneurysm rupture. Both surgical and endovascular treatments have been used in the past decades. However, due to the accessibility of the carotid artery and the lack of evidence-based guidelines, the selection of treatment for ECAAs is challenging. The location, etiology, and features of the aneurysm in combination with previous experience are important factors that determine the selection of the optimal intervention strategy.

The present study retrospectively reviewed a large series of ECAAs treated at our institution in the past 6 years, and may be the only series that has described all the management techniques, including surgical, endovascular, and hybrid. Additionally, we propose a new classification scheme, named the Peking Union Medical College Hospital (PUMCH) classification, based on the anatomic location and the morphology of the aneurysm. Given the rarity of ECAAs, this study adds to the literature and fund of knowledge.

Material and Methods

Patients

Following approval by the Institutional Review Board, a retrospective review was conducted between January 2010 and April 2016. All ECAA patients treated in our institution were included in the present study. Computed tomography angiography (CTA), ultrasound examination, and/or magnetic resonance imaging methodologies were used to diagnose ECAA. We reviewed patient demographics, comorbidities, aneurysm size, symptoms, etiology, interventional methods, operation details, and disease-associated complications. The patient follow-up was recorded with clinical notes and repeated imaging.

Operative information

Several interventional methods were available for the management of these patients. The choice of interventional methods was based on the etiology, aneurysm location, and artery

morphology, as well as the professional experience of the medically qualified investigator. The patients provided signed informed consent before surgery. Open surgical intervention was conducted under general anaesthesia with shunt insertion during carotid clamping. Endovascular procedures were typically carried out under conscious sedation, unless general anaesthesia was required for hemodynamic instability. A hybrid operation was selectively conducted in patients with complicated conditions. All patients accepted anti-platelet and/or anti-coagulant therapy before and after the intervention. The dose of the drugs was adjusted according to patient condition and surgical outcome. We recorded complications related to death, as well as cardiac and cerebral vascular events. Success was defined as improvement of the manifestations and the absence of major complications during hospital treatment.

Post-operative follow-up

The patency of the reconstructed arteries and complications, including bleeding, infection, nerve injury, stroke, and death, that were related to the intervention, were investigated. Restenosis was defined as greater than 50% stenosis of the lumen. Early complications consisted of all events that occurred within 30 days after treatment and late outcomes that occurred at the 30th day and/or beyond. The patients in the outpatient group were routinely (1, 3, 6, and every 12 months) examined by CT and/or duplex ultrasound imaging. All patients were interviewed by telephone contact prior to the initiation of treatment.

Statistical analysis

Continuous data are presented as the median \pm standard deviation and categorical data are presented as percentages. Statistical analysis was conducted using the *t* test and the χ^2 test using SPSS 20.

Results

Clinical characteristics

A total of 35 ECAAs patients received treatment in our academic institution during the past 6 years. The diagnosis was confirmed by computed tomography angiography (CTA), ultrasound examination, and/or magnetic resonance imaging. Open surgery was conducted in 16 patients (group 1), endovascular repair was carried out in 15 cases (group 2), and hybrid operation was performed in 4 (group 3). The demographic data of the patients, including the comorbidities and symptoms, were recorded (Table 1). A total of 29 (82.9%) patients presented with symptoms related to ECAAs, whereas 12 (34%) patients experienced hypertension and 6 (17%) patients had cerebrovascular disease. The causes of the 28 true aneurysms included

Table 1. Patients' demographic data and comorbidities.

	Open surgery (n=16)	Endovascular (n=15)	Hybrid (n=4)	Total (n=35)
Age, mean \pm SD (years)	50.25 \pm 14.64	49.07 \pm 16.81	60 \pm 15.68	50.8 \pm 15.62
Male, sex	5 (31%)	9 (60%)	1 (25%)	15 (43%)
Smoker or past smoker	3 (19%)	1 (7%)	0 (0%)	4 (11%)
Hypertension	5 (31%)	5 (33%)	2 (50%)	12 (34%)
Diabetes	0 (0%)	1 (7%)	0 (0%)	1 (3%)
Hyperlipaemia	0 (0%)	1 (7%)	1 (25%)	2 (6%)
Coronary artery disease	2 (13%)	1 (7%)	1 (25%)	4 (11%)
Cerebrovascular disease	2 (13%)	3 (20%)	1 (25%)	6 (17%)
Peripheral arterial disease	0 (0%)	2 (13%)	0 (0%)	2 (6%)
Symptoms				
Mass	9 (56%)	8 (53%)	3 (75%)	20 (57%)
Pain	4 (25%)	4 (27%)	0 (0%)	8 (23%)
TIA/stroke	5 (31%)	6 (40%)	3 (75%)	14 (40%)
Nerve compression	1 (6%)	3 (20%)	1 (25%)	5 (14%)

SD – standard deviation; TIA – transient ischemic attack.

Table 2. Classification of aneurysm (attigah, structure).

		Open surgery (n=16)	Endovascular (n=15)	Hybrid (n=4)
Attigah	I	4	4	0
	II	1	2	0
	III	2	1	0
	IV	4	3	4
	V	5	5	0
Structure	TRUE	16	8	4
	FALSE	0	5	0
	Dissecting	0	2	0

Type I, aneurysm of the internal carotid artery distal to the carotid bifurcation; type II, aneurysm of the internal carotid artery; type III, aneurysm of the carotid bifurcation; type IV, aneurysm of the internal carotid artery and the common carotid artery; type V, aneurysm of the common carotid artery.

atherosclerosis in 25 patients, Takayasu arteritis in 2, and possible Phace syndrome in 1. False aneurysms were formed from carotid endarterectomy in 2 patients, while trauma was noted in 1 and unexplained causes in 2. The causes of the remaining 2 dissecting aneurysms were unknown.

Aneurysm characteristics

The records of the aneurysm diameters were available for 28 patients, of which the diameter ranged from 0.90 cm to 5.90 cm.

The average diameter was 2.93 \pm 1.25 cm. The relationship between the aneurysm diameter and other characteristics was analysed in terms of 6 aspects: type of aneurysm, presence of mass, pain, TIA, nerve compression, and thrombus in aneurysm). The average diameter of the aneurysms with thrombus was 3.39 \pm 1.55 cm and 2.52 \pm 0.84 cm without thrombus ($P=0.045$), which suggests that larger aneurysms were more likely to occur in the presence of thrombus formation. In addition, the aneurysm diameter showed no significant difference with regard to the remaining aneurysm characteristics.

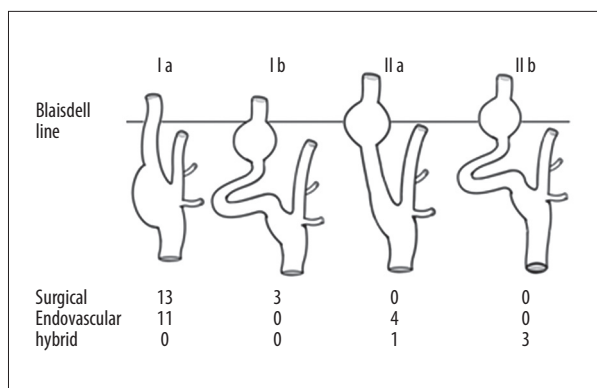


Figure 1. PUMCH classification. Type Ia: aneurysm below the line of Blaisdell in the absence of kinking; Type Ib: aneurysm below the line of Blaisdell in the presence of kinking; Type IIa: aneurysm up to the line of Blaisdell in the absence of kinking; Type IIb: aneurysm up to the line of Blaisdell in the presence of kinking.

Aneurysm classification

Several ECAA classifications have been suggested by previous studies. According to the structure classifications, 28 of the cases were true aneurysms, 5 were false aneurysms, and 2 were dissecting aneurysms. The treatment varied for the true aneurysm cases. A total of 16 cases out of 28 were treated by open repair, 8 by endovascular treatment, and 4 by hybrid operation. All 7 false aneurysms and dissecting aneurysms were treated

by endovascular repair. Attigah and Kulkens [4] reported an ECAA classification, which used Blaisdell classification to divide ECAA into 5 types, although it provides limited information for selection of intervention methods (Table 2). Therefore, a new classification – the PUMCH classification – was developed, which considers the location and proximal artery morphology of the aneurysm. The location of the aneurysm according to the Blaisdell classification was regarded as type II and all other cases were regarded as type I. Furthermore, the ECAA was classified as kinking, in the presence of an angle of the proximal artery higher than 60 degrees. The ECAs that exhibited kinking were classified as type b, whereas those that did not present with kinking were classified as type a. A total of 24 patients were classified as type Ia and were treated with open surgery and/or endovascular repair. All 3 type Ib patients were treated with open surgery. All 5 type IIa patients were treated with endovascular repair, with the exception of 1 failure that was transferred to hybrid therapy. All 3 type IIb patients were treated with hybrid operation (Figures 1, 2).

Treatment and follow-up

In the open surgery group, general anaesthesia was administered in 16 patients. Aneurysm resection with end-to-end anastomosis was conducted in 6 patients, whereas aneurysm resection with vein graft was performed in 7 patients and aneurysm resection with artificial blood vessel graft was performed in 3 patients. In the endovascular group, local anaesthesia was

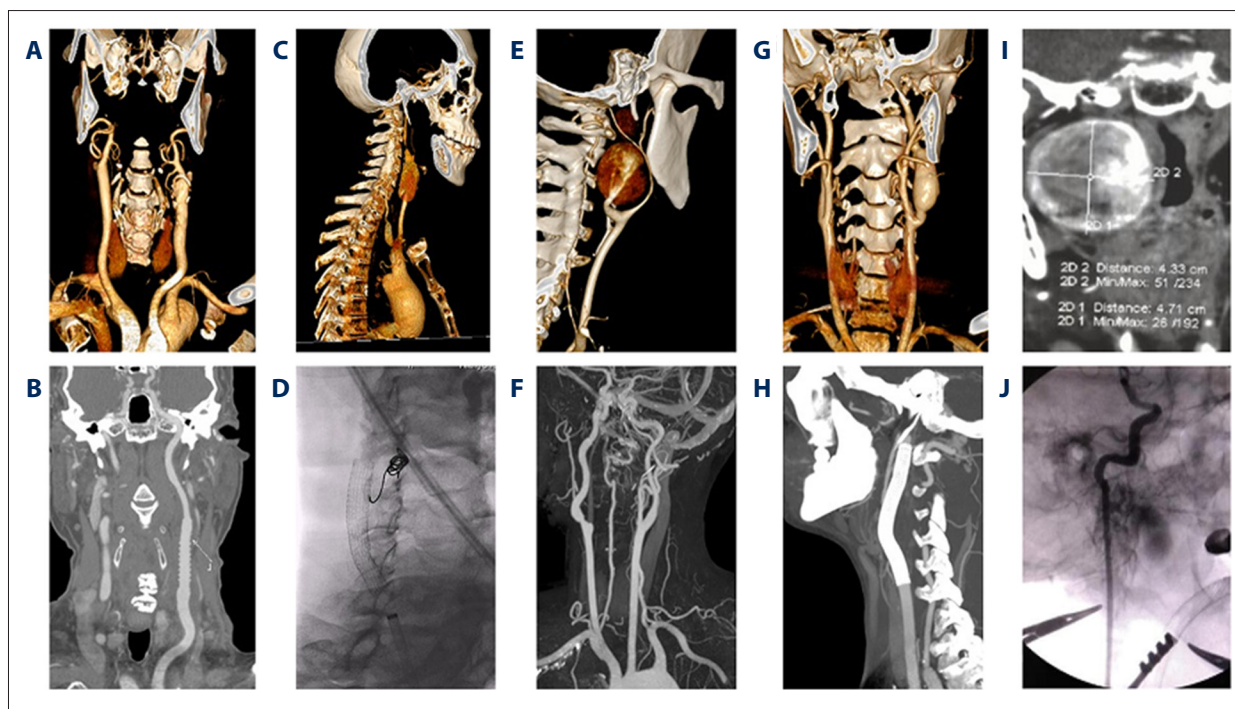


Figure 2. Typical cases of PUMCH classification. (A, B) Open surgery for type Ia; (C, D) Endovascular treatment for type Ia; (E, F) Open surgery for type Ib; (G, H) Endovascular treatment for type IIa; (I, J) Hybrid operation for type IIb.

Table 3. General conditions, arterial lesions, surgical procedures and follow-up results.

Case no.	Surgical technique	Medical treatment		Complication		Follow up	Patency
		Pre	Post	Early	Late	Duration (m)	
1	ABV	AC	AC	–	–	2.9	Patent
2	VG	AP	AP	RLNp	–	45.9	Patent
3	VG	AP	AP	–	–	39.6	Patent
4	VG	AP	AP	HGNp	–	44.1	Patent
5	VG	AP	AP+AC	FNp+hematoma	–	12.5	Patent
6	VG	AP	AP	RLNp+ HGNp	–	38.1	Patent
7	AVB	AP	AC	–	–	8.3	Patent
8	REE	AP	AP	HGNp	–	18.8	Patent
9	REE	AP	AP	Stroke+hematoma	–	22.4	Patent
10	REE	AP	AP	–	–	75.2	Patent
11	REE	AP	AP	–	–	77.7	Patent
12	VG	AP	AP	RLNp	–	53	Patent
13	AVB	AP	AP	–	–	75	Patent
14	REE	AP	AP+AC	–	–	62.7	Patent
15	VG	AP	AC	–	–	2.8	Patent
16	REE	AP	AP	–	–	13.1	Patent
17	Nr	AP	AP	–	–	8.5	Patent
18	Viabahn (7–50 mm)	AP	AC	–	–	12.8	Patent
19	Viabahn (7–50 mm)	AP	AP+AC	–	–	11.3	Patent
20	Viabahn (8–100 mm)	AP	AP+AC	–	–	17.6	Patent
21	Viabahn (8–50 mm)	AP	AC	–	–	35.3	Patent
22	Nr	AP	AP	–	–	5	Patent
23	Viabahn (9–100 mm)	AP	AP+AC	–	–	21.5	Patent
24	Viabahn (6–8–40 mm)+Coil	AP	AP	–	–	6.4	Patent
25	Viabahn (6–50 mm, 8–100 mm)+Coil	AP	AC	–	–	7.2	Patent
26	Acculink (6–8–40 mm)	AP	AP+AC	–	–	13.6	Patent
27	Coil	AP	AP	–	–	36.2	Patent
28	Coil	AP	AP	–	–	14.4	Patent
29	Viabahn (6–50 mm)	AP	AP+AC	–	–	16.8	Reoperation
30	Nr	AP	AP	–	–	37.6	Patent
31	Acculink (6–8–40 mm)+Coil	AP	AP	–	–	32.7	Patent
32	Viabahn (5–100 mm)+ES	AP	AP+AC	Stroke	–	8.5	Patent
33	Viabahn (6–50 mm, 5–50 mm)+REE	AP	AP	HGNp	–	2.6	Patent
34	Viabahn (6–100 mm)+ABV+ES	AP	AP+AC	–	–	4.5	Patent
35	Viabahn (5–50 mm)	AP	AP+AP	–	–	10	Patent

VG – vein graft; REE – resection and end-to-end anastomosis; EE – end-to-end anastomosis; ABV – artificial blood vessel; ES – end-to-side anastomosis; AP – antiplatelet; AC – anti-coagulant; RLNp – recurrent laryngeal nerve palsy; HGNp – hypoglossal nerve palsy; FNp – facial nerve palsy; Nr – no record.

administered in 12 cases and general anaesthesia in 3 patients. The endovascular interventions included stent graft in 6 cases, stent graft with coil in 2 cases, bare-metal stent (BMS) in 1 case, BMS with coil in 1 case, and coil in 2 cases. The remaining 3 patients had incomplete medical information. A total of 4 cases were treated with hybrid operation due to their specific conditions (Table 3).

Follow-up data were available for all 35 patients, with a mean follow-up period of 25.58 ± 22.13 months. The mean follow-up periods in groups 1, 2, and 3 were 37.07 ± 26.35 , 18.46 ± 11.51 , and 6.4 ± 3.44 months, respectively. In group 1, 7 (43.8%) patients experienced early complications, 6 (37.5%) presented with nerve palsy, 2 (5.7%) had cervical hematoma, and 1 (2.8%) had stroke. All subjects that exhibited nerve palsy recovered during the 3-month follow-up period. One patient who had a cervical hematoma underwent evacuated surgery 10 days after the operation. Another patient simultaneously experienced cervical hematoma and stroke and received conservative treatment, including anti-platelet drugs, neural nutrition medication, and physiotherapy. However, no early complications were noted in group 2, in which the subjects experienced fewer early complications compared with group 1 ($P=.004$). In group 3, 2 (50%) subjects experienced early complications, of which 1 had stroke and the other had hypoglossal nerve palsy. All the patients who experienced early complications recovered during follow-up. No patients suffered late complications such as TIA, stroke, and/or death.

The patency rates of groups 1, 2, and 3 were 100%, 93.3%, and 100%, respectively. Only 1 patient experienced stent-graft stenosis at 11 months after treatment (endovascular therapy). Balloon dilation and stent grafting were used to achieve a second patency. Stent occlusion, migration, and graft fracture, as well as intracranial infection and/or persistent endoleak, were not reported in any patients.

Discussion

Epidemiologic information on ECAAs

Aneurysms of the extracranial internal carotid artery are infrequent lesions, accounting for less than 1% of all aneurysms [6,7]. The confirmation of the exact cause of the formation of the aneurysm remains a challenge. Atherosclerosis is the most frequently cited cause of true aneurysms, and has been proposed as the leading factor in 37% to 42% of aneurysms [8]. In the present study, atherosclerosis accounted for 70.6% of the causes of aneurysm formation. Carotid false aneurysms are principally related to trauma during the carotid endarterectomy operation [9,10]. Among the 5 false aneurysms of the present study, 2 patients experienced carotid endarterectomy

and 1 patient underwent local debridement due to an injured cervix. Younger patients may present with true ECAAs originating from various diseases (e.g., tuberculosis and human immunodeficiency virus), disorders of connective tissue (e.g., collagen-vascular disease), fibromuscular dysplasia, irradiation, Behcet disease, Takayasu arteritis, Phace syndrome, and/or Cogan syndrome. Mycotic aneurysms are usually caused by salmonella and/or syphilis [11,12]. A total of 2 patients were diagnosed with Takayasu arteritis and 1 was diagnosed with Phace syndrome.

The symptoms related to ECAA varied. Neurological events have been shown to be the most frequent symptoms, accounting for 42.0–50.9% of cases investigated. Neurological events usually occur due to embolization of the thrombus from the aneurysm. In the present study, the development of neurological dysfunction was noted in 40% of the cases. In concordance with these findings, thrombus in the aneurysmal sac was observed in 23.5% of the aneurysms of the present study, while Li et al. reported an incidence rate in the range of 18.4% [13]. According to our analysis, an association between increased diameter of the aneurysm and thrombus formation may be present. This association may account for the enlarged aneurysm cavity that can affect hemodynamics in the sac. Therefore, a larger-diameter aneurysm is considered a significant risk factor for development of neurological events. In addition, the presence of mass, pain, TIA, and nerve compression varies according to the type of aneurysm, whereas the aneurysm diameter was not found to differ significantly. The main etiological factors affecting the severity of the symptoms were the effects of the course and location of CEAA and the degree of obesity.

ECAAs classification

According to the structure classification, endovascular intervention is recommended for false and/or dissecting aneurysms due to the higher risk of aneurysm rupture. In the present study, all 5 false aneurysms and 2 dissecting aneurysms were treated by endovascular intervention. For the remaining 28 true aneurysms, all open surgery, endovascular repair, and hybrid operation were available treatment options [11]. Therefore, several ECAAs classifications that were based on the anatomical location of the aneurysms were developed. Attigah et al. used the classification of Blaisdell, which uses a virtual line between the mastoid process and the angle of the mandible, to divide ECAAs into 5 types. This classification includes only the aneurysm location, which further limits the guidance for the selection of intervention method.

In the present study, the PUMCH classification was selected, which considers both the location and the proximal artery morphology of the aneurysm. The higher the location of the aneurysm, the greater the difficulty of open surgery. Similarly,

the greater the angle of the proximal artery of the ECAA, the greater the difficulty of endovascular repair. Therefore, according to the PUMCH classification, type Ia aneurysms that were below the line of Blaisdell in the absence of kinking were readily treated either by open surgery and/or endovascular repair. Patients with type Ib aneurysm below the line of Blaisdell in the presence of kinking were most likely to undergo open surgery. Patients with type IIa aneurysms higher than the line of Blaisdell in the absence of kinking were most likely to undergo endovascular repair. A type IIb aneurysm higher than the line of Blaisdell in the presence of kinking, which is complicated for treatment and hybrid operation, may be available. In the present study, the data indicated that the PUMCH classification may be helpful for the selection of intervention methods of ECAA. Therefore, the combination of the structure classification with the PUMCH classification may be useful for selection of management strategy of extracranial carotid artery aneurysms (Figure 3). However, further studies are required to support this new classification.

Selection of a suitable intervention method

Open surgery

Treatment of ECAAs using open surgery can be technically demanding owing to the vicinity of carotid vessels and cranial nerves. Previous reports [14,15] estimated the nerve deficit rate was 44%, whereas the early stroke rate was 5.16% and the early mortality rate was 1.91%. In the present study, 16 patients underwent open repair surgery and the total incidence of nerve deficit was 43.8% (7/16), whereas the stroke rate was 6.25% (1/16). No mortalities were noted, which is in agreement with previous studies. Nordanstig et al. reported that local complications are higher in cases with types I/II and IV aneurysms according to the Attigah classification [16]. In the present study, all 3 (100%) type Ib patients suffered from complications, including cervix hematoma, nerve palsy, and cervix hematoma and stroke, as classified by the PUMCH. However, only 4 (30.7%) type Ia aneurysm patients experienced nerve palsy. Long-term results indicated neurological stability with a low stroke risk and satisfactory patency. Currently, open surgery is considered the main treatment strategy for accessible ECAAs.

Endovascular repair

Selection of endovascular technique depends primarily on the arterial anatomy and specific characteristics of the lesion [17]. Both covered and bare-metal stents have been used to treat ECAAs. A total of 8 out of 12 (66.6%) patients in group 2 were treated with a covered stent and 2 patients further received coils to embolize the external carotid artery that originated from the aneurysm. Bare-metal stents can be used alone and/or in combination with aneurysm sac coiling. In the present study,

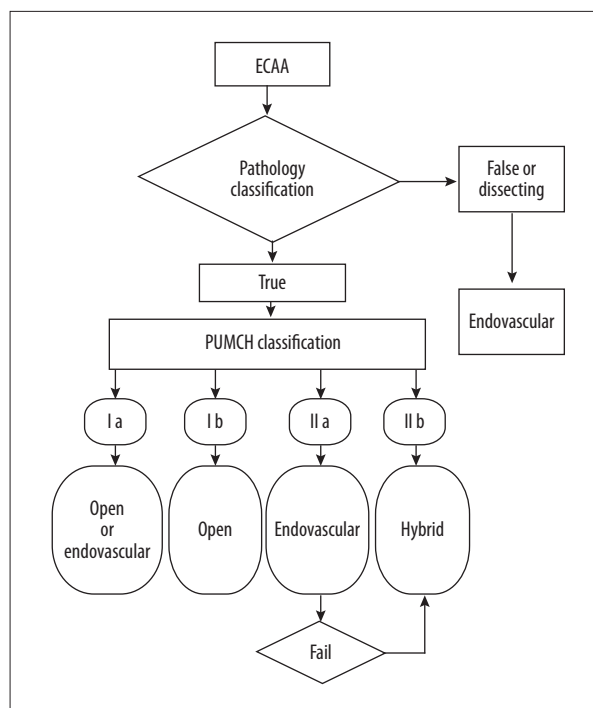


Figure 3. The management strategy for the treatment of ECAAs.

1 patient was treated with BMS and 1 patient was treated by BMS and coiling. A total of 2 patients underwent internal carotid artery coil embolization owing to the poor prognosis and the adequate blood supply of the compensatory circulation, which was confirmed by the temporary internal carotid balloon occlusion test. No coil migration was noted during follow-up. The flow-diverting stent was used in 1 high type I aneurysm at a region close to the skull base, which was designed to change the inflow and outflow of the blood in the aneurysm and aimed to promote optimal thrombosis compared with the bare-metal stent [18]. Endovascular treatment serves as an additional optimal method of surgical intervention for aneurysms [19]. Li et al. reported a stroke rate of 1.8%, a cranial nerve injury rate of 0.5%, and an in-hospital mortality rate of 4.1% [13]. The patients in the present study who underwent endovascular treatment had a stent graft patency rate of 93.3%. No neurological events and no mortalities were recorded. The data of this study are promising and suggest a potential benefit from the development of novel endovascular devices and techniques.

Hybrid operation

Hybrid techniques have further been described in cases of high internal carotid artery (ICA) aneurysms with a proximal ICA kink and/or loop. Open surgery can expose the carotid artery and the anatomic variation can be removed before or after endovascular repair [20]. A total of 3 out of 4 hybrid operation patients were classified as type IIb, whereas the remaining

1 was classified as type IIa according to PUMCH classification. We individually designed the hybrid operation plan according to the patients' conditions. The first patient experienced a cut of the proximal loop of the aneurysm, followed by direct arterial anastomosis, and then the endovascular stenting was conducted to circumvent it. The second patient initially underwent endovascular stenting, followed by straightening of the loop of the internal carotid artery, and subsequent anastomosis to the common carotid artery. The third patient underwent endovascular stenting via the carotid artery in the absence of the handling loop. The fourth patient was diagnosed with a type IIa aneurysm and underwent a hybrid operation owing to the different diameters of the proximal and distal parts of the aneurysms. Consequently, a hybrid operation is an available choice of treatment for complicated cases.

Strengths and limitations

The present study includes data analysis from a fully defined population with regard to clinical and pathological features,

which potentially reflects current clinical practice. In addition, a new classification system of aneurysms was developed. In contrast to the aforementioned advantages, the main limitation of this study is its retrospective nature, which includes a limited number of patients and events, in the absence of a control group. Nevertheless, the present study provides insight into contemporary management of this uncommon disease.

Conclusions

Open surgery was more frequently feasible in true aneurysms, and endovascular surgery the first choice for false and dissecting aneurysms. Hybrid operations were considered for use in complicated cases. The PUMCH classification may be helpful for selection of management strategy for ECAAs.

Conflict of interests

None.

References:

1. Szopinski P, Ciostek P, Kielar M et al: A series of 15 patients with extracranial carotid artery aneurysms: Surgical and endovascular treatment. *Eur J Vasc Endovasc Surg*, 2005; 29: 256–61
2. Pulli R, Dorigo W, Alessi Innocenti A et al: A 20-year experience with surgical management of true and false internal carotid artery aneurysms. *Eur J Vasc Endovasc Surg*, 2013; 45: 1–6
3. Radak D, Davidovic L, Vukobratov V et al: Carotid artery aneurysms: Serbian multicentric study. *Ann Vasc Surg*, 2007; 21: 23–29
4. Attigah N, Kulkens S, Zausig N et al: Surgical therapy of extracranial carotid artery aneurysms: Long-term results over a 24-year period. *Eur J Vasc Endovasc Surg*, 2009; 37: 127–33
5. Donas KP, Schulte S, Pitoulas GA et al: Surgical outcome of degenerative versus postreconstructive extracranial carotid artery aneurysms. *J Vasc Surg*, 2009; 49: 93–98
6. Welleweerd JC, den Ruijter HM, Nelissen BG et al: Management of extracranial carotid artery aneurysm. *Eur J Vasc Endovasc Surg*, 2015; 50: 141–47
7. Welleweerd JC, Moll FL, de Borst GJ: Technical options for the treatment of extracranial carotid aneurysms. *Expert Rev Cardiovasc Ther*, 2012; 10: 925–31
8. Zhang Q, Duan ZQ, Xin SJ et al: Management of extracranial carotid artery aneurysms: 17 years' experience. *Eur J Vasc Endovasc Surg*, 1999; 18: 162–65
9. El-Sabrouy R, Cooley DA: Extracranial carotid artery aneurysms: Texas Heart Institute experience. *J Vasc Surg*, 2000; 31: 702–12
10. Srivastava SD, Eagleton MJ, O'Hara P et al: Surgical repair of carotid artery aneurysms: A 10-year, single-center experience. *Ann Vasc Surg*, 2010; 24: 100–5
11. Fankhauser GT, Stone WM, Fowl RJ et al: Surgical and medical management of extracranial carotid artery aneurysms. *J Vasc Surg*, 2015; 61: 389–93
12. Angiletta D, Pulli R, Marinazzo D et al: Surgical and endovascular treatment of extracranial carotid artery aneurysms: Early and long-term results of a single center. *Ann Vasc Surg*, 2014; 28: 659–64
13. Li Z, Chang G, Yao C et al: Endovascular stenting of extracranial carotid artery aneurysm: A systematic review. *Eur J Vasc Endovasc Surg*, 2011; 42: 419–26
14. Rosset E, Albertini JN, Magnan PE et al: Surgical treatment of extracranial internal carotid artery aneurysms. *J Vasc Surg*, 2000; 31: 713–23
15. Song G, Jiao L, Chen Y et al: Management of extracranial carotid artery aneurysm: A report of four cases. *Exp Ther Med*, 2015; 10: 1029–32
16. Nordanstig J, Gelin J, Jensen N et al: National experience with extracranial carotid artery aneurysms: Epidemiology, surgical treatment strategy, and treatment outcome. *Ann Vasc Surg*, 2014; 28: 882–86
17. Malikov S, Thomassin JM, Magnan PE et al: Open surgical reconstruction of the internal carotid artery aneurysm at the base of the skull. *J Vasc Surg*, 2010; 51: 323–29
18. Fischer S, Vajda Z, Aguilar Perez M et al: Pipeline embolization device (PED) for neurovascular reconstruction: Initial experience in the treatment of 101 intracranial aneurysms and dissections. *Neuroradiology*, 2011; 54: 369–82
19. Wan J, Gu W, Zhang X, Geng D et al: Endovascular coil embolization of aneurysm neck for the treatment of ruptured intracranial aneurysm with bleb formation. *Med Sci Monit*, 2014; 20: 1121–28
20. Trinidad-Hernández M, Introcaso JH, White JV: Combined open and endovascular treatment of a saccular aneurysm and redundant loop of the internal carotid artery. *J Vasc Surg*, 2006; 44: 642–46