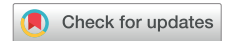

# Wandering Thrombi in the Right Atrium: A Fatal Journey From the Heart to Lungs



Yavuzer Koza, MD, Ednan Bayram, MD, Hakan Taş, MD, and Selim Aydemir, MD, *Erzurum, Turkey*

## INTRODUCTION

Right heart thrombi (RHT) in transit are a serious condition that usually represent a clot dislodged from deep venous thrombosis that has mobilized and become lodged in the right heart en route to the pulmonary arteries (PAs), with the potential to migrate and lead to additional embolic complications. RHT are often found in the setting of severe bilateral pulmonary embolisms (PEs).<sup>1</sup> Patients with RHT in transit often have higher heart rates and lower blood pressures and exhibit more right ventricular dysfunction compared with patients who present with PE without RHT in transit.<sup>1,2</sup> We describe two cases of right atrial thrombi in transit diagnosed using echocardiography. Despite intravenous thrombolysis and inotropic support, the patients developed cardiopulmonary collapse and died.

## CASE PRESENTATIONS

### Case 1

A 63-year-old female patient was admitted with hypotension and sudden loss of consciousness. She was on adjuvant chemotherapy for a recently detected metastatic breast cancer, including multiple lymph nodes and pelvic bone metastases. Bedside transthoracic echocardiography (TTE) revealed large, free-floating thrombi in the right atrium (Figure 1, Video 1) protruding into the right ventricle during diastole and severely decreased right ventricular systolic function. The right ventricle and right atrium were severely dilated. Systolic PA pressure was measured at 69 mm Hg. Recombinant tissue plasminogen activator was started with a regimen of 100 mg over 2 hours with concomitant use of intravenous heparin infusion. Shortly after administration of recombinant tissue plasminogen activator, the patient became hypotensive and bradycardic, with visible RHT (Video 2). Resuscitative measures were undertaken; unfortunately, she did not respond and died.

### Case 2

A 76-year-old man presented with dyspnea, chest pain, and syncope. He had recently been treated for pneumonia at another hospital. On admission, he was hypotensive and bradycardic. TTE was performed and showed a highly mobile thrombus in the right atrium and severely depressed right ventricular function, with systolic pulmonary artery

pressure of 55 mm Hg (Figure 2, Video 3). The right ventricle and right atrium were severely dilated, with a D-shaped left ventricle. Thrombolytic treatment was started as described in case 1. Immediately after thrombolysis, the patient developed hypotension and bradycardia related to the sudden decrease in pulmonary venous return. There was no visible thrombus in the right atrium (Video 4). Despite fluid replacement and inotropic support, the patient died 3 hours later.

## DISCUSSION

RHT usually originate from the deep leg veins, with a high potential to embolize.<sup>3</sup> Thrombi in the right heart can be detected using echocardiography in approximately 4%–18% of patients with acute PE, and the presence of RHT is associated with a high mortality rate.<sup>4,5</sup>

In the largest study reported on symptomatic free-floating RHT, 79% of RHT were in the right atrium, 16% were in the right ventricle, and 5% were in both right heart chambers.<sup>4</sup> It is still unclear whether RHT are a direct cause or just an indicator of adverse outcomes. In the Right Heart Thrombi European Registry, short-term prognosis was associated with clinical and hemodynamic consequences of PE and not RHT characteristics such as size, morphology, or mobility.<sup>5</sup> Pelaez *et al.*<sup>6</sup> reported that a migratory thrombosis in the right heart became a PE within 24 hours, resulting in massive PE in 40% of cases, which eventually resulted in a 45% mortality rate. Thrombi that are attached in the right atrium or right ventricle usually have a benign prognosis. However, free-floating, “snakelike” thrombi are usually associated with massive unstable PE.<sup>1,2</sup> These mobile RHT have often been referred to as emboli in transit.<sup>7</sup>

The diagnosis of RHT in transit is usually made by echocardiography or computed tomographic angiography. Bedside TTE, as in our cases, can lead to a more prompt diagnosis. Because all deaths occur within the first 24 hours, a right heart thrombus in transit requires a more aggressive and emergent management approach.<sup>3</sup>

In case 2, the right atrial thrombus probably migrated to the lungs after thrombolytic treatment. However, it was unclear whether the disappearance of RHT following thrombolysis was due to dissolution by the thrombolytic agent or migration to the PAs. Such fragmentation and migration have been reported when thrombolytic therapy is administered to treat extensive deep venous thrombosis.<sup>8,9</sup>

Anticoagulation, systemic or catheter-directed thrombolysis, and surgical embolectomy are the recommended management options for patients with PE and RHT.<sup>10</sup> As another option, there have been case reports documenting the use of percutaneous catheterization to retrieve RHT in transit. In three reports,<sup>11–13</sup> there was one successful removal of RHT<sup>13</sup> in four attempts. However, it should be noted that percutaneous extraction carries an unquantified risk for completely or partially dislodging or fragmenting the thrombus, causing fatal PE. We think that this procedure may represent a potential therapeutic alternative, particularly in patients with contraindications to thrombolysis and surgery.

From the Department of Cardiology, Ataturk University Faculty of Medicine, Erzurum, Turkey.

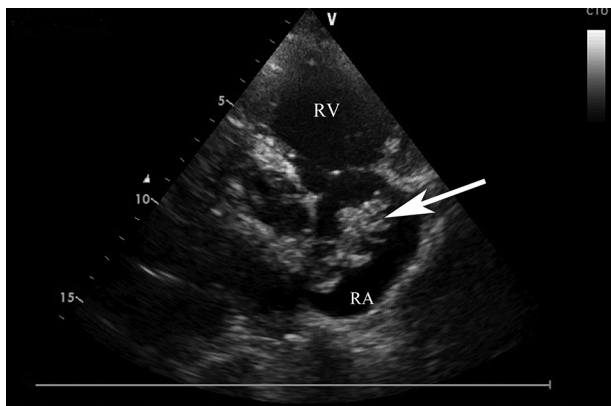
Keywords: Thrombus, Right atrium, Mortality, Echocardiography

Conflicts of interest: The authors report no actual or potential conflicts of relative to this document.

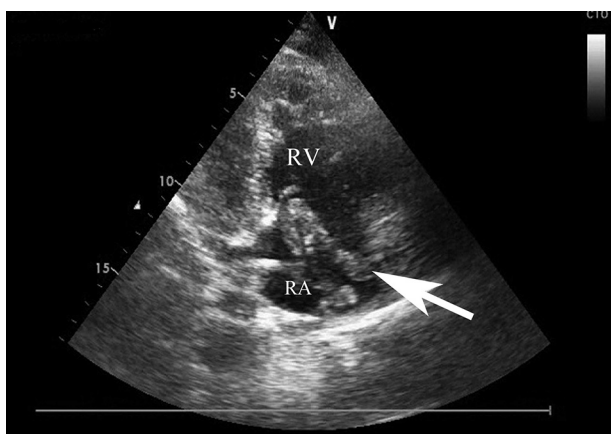
Copyright 2018 by the American Society of Echocardiography. Published by Elsevier Inc. This is an open access article under the CC BY-NC-ND license (<http://creativecommons.org/licenses/by-nc-nd/4.0/>).

2468-6441

<https://doi.org/10.1016/j.case.2018.09.002>



**Figure 1** Echocardiogram, right ventricular inflow view, showing right atrial thrombi (arrow). RA, Right atrium; RV, right ventricle.



**Figure 2** Echocardiogram, right ventricular inflow view, showing right atrial thrombi (arrow). RA, Right atrium; RV, right ventricle.

Although RHT in transit are usually associated with PE, the optimal therapy has not been defined, and treatment selection is still a subject of debate. Thrombolysis is a better treatment modality, especially in hemodynamically unstable patients, as it treats RHT, PE, and associated deep venous thrombosis simultaneously.<sup>14</sup> However, intravenous thrombolysis may dissolve clots in several locations at the same time, with the potential risk for migration of fragments into the PA and occlusion of some of the remaining branches, as suspected in case 2. There is also a time delay from the start of thrombolysis to its maximal effect. Furthermore, in patients with hemodynamic impairment, there is not always enough time to dissolve the thrombus before cardiopulmonary arrest occurs, as in case 1. Therefore, it may be speculated that thrombolytic therapy may be relatively risky for patients with massive PE who have few remaining branches of the PAs.

In a meta-analysis<sup>7</sup> that included 177 cases, the overall mortality rate was 27%. The mortality rates associated with no therapy, anticoagulation therapy, embolectomy, and thrombolysis were 100%, 29%, 24%, and 11%, respectively. These findings suggest that anticoagulation by itself appears insufficient to treat patients with mobile RHT. Those investigators further suggested that thrombolysis is the preferred option in the absence of contraindications over embolectomy. However, the results of that study should be interpreted cautiously given the various limitations of a meta-analysis. Barrios *et al.*<sup>15</sup> compared anticoagulation with thrombolytic therapy in 325

patients with PE and RHT. Seventy received thrombolytics, and 255 received anticoagulation. Therapy was not randomized; propensity scores were used to adjust for the likelihood of receiving thrombolytic therapy. They reported no significant difference between reperfusion therapy and anticoagulant therapy for mortality and bleeding. This result may be explained by the fact that the RHT included an unknown number of attached thrombi that have a lower mortality than free-floating thrombi. Interestingly, reperfusion therapy was associated with a higher risk for recurrent venous thromboembolism than sole anticoagulation therapy. They concluded that reperfusion therapies might be reserved for patients who have acute symptomatic PE and associated hypotension or shock, irrespective of the presence or absence of coexisting RHT. As a main limitation of that study, the retrospective analysis of observational data may lack some clinical details that may be important determinants of patient selection and outcomes. Although successful treatment of RHT with anticoagulation alone has been reported, it should be noted that heparin alone might not be adequate treatment for patients with RHT, even among those who appear clinically stable.<sup>1,7</sup>

On the other hand, the unpredictable systemic embolism risk during thrombolysis or anticoagulation is considered too high, and some authors recommend surgical thrombectomy. Surgical treatment may be considered for very large RHT, tricuspid occlusion, paradoxical embolism via patent foramen ovale transit, thrombolytic failure, or contraindications to thrombolytic therapy.<sup>7</sup> In the present cases, surgical embolectomy might have been the best strategy given the findings, such as mobile large thrombus and massive PE with subsequently relapsed embolism. However, the patients' poor general condition did not allow surgical thrombectomy, which requires general anesthesia and cardiopulmonary bypass. Furthermore, in routine practice, such emergency surgery is not always available, even in a tertiary hospital such as ours.

In case 2, we think that the death of the patient was probably due to thrombus migration to pulmonary circulation, as TTE during and after thrombolysis showed no visible thrombi in the right atrium. In case 1, because the patient developed cardiopulmonary collapse during thrombolysis and RHT appeared unchanged, embolization of RHT into the PAs on admission may have caused death. However, an alternative explanation cannot be excluded, as postmortem examinations were not permitted. Although we did not perform emergency multidetector computed tomography, because of the hemodynamic instability of the patients, the diagnosis of RHT by TTE allows immediate treatment, and additional investigations (e.g., computed tomography) may be performed after treatment.

## CONCLUSION

RHT should be considered a therapeutic emergency because of the risk for sudden death. The presence of a right heart thrombus is rare, and it is unlikely that a randomized trial with two or three different treatment arms would be performed in the near future. There are no evidence-based guidelines for treatment of PE complicated by snakelike RHT. The optimal treatment strategy for this critical condition remains controversial. It seems that in hemodynamically stable patients with PE with RHT, routine reperfusion therapy is not warranted, and standard anticoagulation should be preferred, whereas thrombolysis should be limited to unstable patients or those developing hemodynamic instability. More important, before the implementation of any therapeutic regimen, the potential immediate and long-term side effects must be weighed against alternative strategies and against the risks of no treatment.

## SUPPLEMENTARY DATA

---

Supplementary data related to this article can be found at <https://doi.org/10.1016/j.case.2018.09.002>.

## REFERENCES

---

1. Torbicki A, Galie N, Covezzoli A, Rossi E, De Rosa M, Goldhaber SZ, ICOPER Study Group. Right heart thrombi in pulmonary embolism. *J Am Coll Cardiol* 2003;41:2245-51.
2. Casazza F, Becattini C, Guglielmelli E, Floriani I, Morrone V, Caponi C, et al. Prognostic significance of free-floating right heart thromboemboli in acute pulmonary embolism: results from the Italian Pulmonary Embolism Registry. *Thromb Haemost* 2014;111:53-7.
3. Chapoutot L, Nazeyrollas P, Metz D, Maes D, Maillier B, Jennessaux C, et al. Floating right heart thrombi and pulmonary embolism: diagnosis, outcome, and therapeutic management. *Cardiology* 1996;87:169-74.
4. Chartier L, Bera J, Delomez M, Asseman P, Beregi JP, Bauchart JJ, et al. Free-floating thrombi in the right heart: diagnosis, management, and prognostic indexes in 38 consecutive patients. *Circulation* 1999;99:2779-83.
5. Koc M, Kostrubiec M, Elikowski W, Meneveau N, Lankeit M, Grifoni S, et al. RiHTER Investigators. Outcome of patients with right heart thrombi: The Right Heart Thrombi European Registry. *Eur Respir J* 2016;47:869-75.
6. Pelaez JB, de Miguel EM, Moreno RS, Gómez LR, Etxebeste J, Martín RG, et al. Right-atrial floating thrombus attached to the interatrial septum with massive pulmonary embolism diagnosed by echocardiography. *Int J Cardiol* 2008;131:125-7.
7. Rose PS, Punjabi NM, Pearse DB. Treatment of right heart thromboemboli. *Chest* 2002;12:806-14.
8. Thery C, Bauchard JJ, Lesenne M, Asseman P, Flajollet JG, Legghe R, et al. Predictive factors of effectiveness of streptokinase in deep venous thrombosis. *Am J Cardiol* 1992;69:117-22.
9. Goldsmith JC, Lollar P, Hoak JC. Massive fatal pulmonary emboli with fibrinolytic therapy. *Circulation* 1990;64:1068-81.
10. Kinney EL, Wright RJ. Efficacy of treatment of patients with echocardiographically detected right-sided heart thrombi: a meta-analysis. *Am Heart J* 1989;118:569-73.
11. Malloy PC, Gore JM, Rippe JM, Paraskos JA, Benotti JR, Ockene IS, et al. Transient right atrial thrombus resulting in pulmonary embolism. *Am Heart J* 1984;108:1047-9.
12. Beregi JP, Aumegeat V, Loubeyre C, Couillet JM, Asseman P, Debacker-Steckelorum C, et al. Right atrial thrombi: percutaneous mechanical thrombectomy. *Cardiovasc Intervent Radiol* 1997;20:142-5.
13. Davies RP, Harding J, Hassam R. Percutaneous retrieval of a right atrioventricular embolus. *Cardiovasc Intervent Radiol* 1998;21:433-5.
14. Mahajan K, Negi P, Asotra S, Dev M. Right atrial free-floating thrombus in a patient with acute pulmonary embolism. *BMJ Case Rep* 2016;2016.
15. Barrios D, Chavant J, Jiménez D, Bertoletti L, Rosa-Salazar V, Muriel A, et al. Registro Informatizado de la Enfermedad TromboEmbólica Investigadores. Treatment of right heart thrombi associated with acute pulmonary embolism. *Am J Med* 2017;130:588-95.