

A retrospective multicenter study of quantitative bone SPECT/CT to predict the surgical removal of the accessory navicular bone

Ji-Young Kim^a, Ji Young Kim^b, Soo Bin Park^c, Chulhan Kim^d and Won Woo Lee^{a,e}

Objective The maximum standardized uptake value (SUVmax) in single-photon emission computed tomography/computed tomography (SPECT/CT) can help quantify disease activity of the accessory navicular bone (ANB). In this multicenter quantitative bone SPECT/CT study, we investigated whether SUVmax was correlated with ANB severity, thereby allowing prediction of surgical resection for ANB treatment.

Methods Two-hundred forty-six patients (men:women = 135:111, mean age = 39.3 years), who had undergone quantitative Tc-99m diphosphonate SPECT/CT of the feet, were recruited from four hospitals. SUVmax was measured using vendor-provided quantitation software. The SUVmax values were compared in relation to ANB type (type 1 = 62, type 2 = 136 and type 3 = 14), presence of pain and surgical treatment.

Results SUVmax (mean \pm SD) was the highest in type 2 ANB (4.41 \pm 5.2; $P = 0.0101$). The 17 resected ANBs showed greater SUVmax (8.27 \pm 5.23; $P < 0.0001$) than the 141 asymptomatic ANBs (2.30 \pm 1.68) or the 54 symptomatic ANBs without surgery (6.15 \pm 4.40). Since surgery is exclusively indicated for ANB type 2, surgical resection was investigated only in these cases. In univariate analysis, young age and SUVmax were significantly associated with surgical treatment, but

only SUVmax was a significant predictor of surgery in multivariate analysis ($P < 0.0001$). Type 2 ANBs were treated by surgery in 32.5% (13/40) of the cases when SUVmax was ≥ 5 , and in only 1.35% (1/74) of the cases when SUVmax was < 5 ($P < 0.0001$).

Conclusion ANB disease activity and excision were strongly associated with the SUVmax derived from quantitative bone SPECT/CT. Our study suggests an absolute SUVmax cutoff for ultimate ANB surgical treatment, but additional prospective studies are required to validate this finding. *Nucl Med Commun* 42: 998–1004 Copyright © 2021 The Author(s). Published by Wolters Kluwer Health, Inc.

Nuclear Medicine Communications 2021, 42:998–1004

Keywords: accessory navicular bone, single-photon emission computed tomography, computed tomography, standardized uptake value

^aDepartment of Nuclear Medicine, Seoul National University Bundang Hospital, Seongnam-si, ^bDepartment of Nuclear Medicine, Hanyang University Guri Hospital, Guri-si, Gyeonggi-do, ^cDepartment of Nuclear Medicine, Soonchunhyang University Seoul Hospital, Seoul, ^dDepartment of Nuclear Medicine, Korea University Ansan Hospital, Ansan and ^eInstitute of Radiation Medicine, Medical Research Center, Seoul National University, Seoul, Republic of Korea

Correspondence to Won Woo Lee, MD, PhD, Department of Nuclear Medicine, Seoul National University Bundang Hospital, Seoul National University College of Medicine 82, Gumi-ro 173 Beon-gil, Bundang-gu, Seongnam-si, Gyeonggi-do 13620, Republic of Korea
Tel: +82 31 787 7672; fax: +82 31 787 4018; e-mail: wwlee@snu.ac.kr

Received 7 January 2021 Accepted 23 March 2021

Introduction

Accessory navicular bone (ANB) is one of the most common variants of accessory ossicles involving the foot [1]. A developmental anomaly, an ANB, is often incidental, but it can cause medial foot pain requiring treatment. Despite the availability of conservative treatments such as medication or physiotherapy, some painful ANBs ultimately need surgical resection of the ossicle with or without posterior tibialis tendon repair [2,3].

ANB classification is highly related to symptomatology. Type 1 ANB is mostly asymptomatic and appears as a sesamoid bone within the tibialis posterior tendon.

Type 2 refers to symptomatic ANB with an unstable cartilaginous connection (synchondrosis) with a navicular tuberosity. However, not all type 2 ANBs are symptomatic. Exercise or trauma may produce symptomatic type 2 ANB that leads to foot pain at some point. In contrast, type 3 ANB is rarely symptomatic and is thought to result from the fusion of a type 2 ANB with a navicular tuberosity, generating a cornuate navicular [1,4–7].

Imaging studies for ANB evaluation span from simple radiologic studies to nuclear scintigraphy and MRI assessments [8–11]. Among nuclear imaging studies, single-photon emission computed tomography/computed tomography (SPECT/CT) is of particular importance because radionuclide uptake and ANB type can be evaluated together by SPECT and CT, respectively [12–16]. Besides, novel quantitative SPECT/CT technologies

This is an open-access article distributed under the terms of the Creative Commons Attribution-Non Commercial-No Derivatives License 4.0 (CCBY-NC-ND), where it is permissible to download and share the work provided it is properly cited. The work cannot be changed in any way or used commercially without permission from the journal.

like PET can quantify the degree of radionuclide uptake [17–27]. A recent single-center study used the maximum standardized uptake value (SUVmax) derived from quantitative bone SPECT/CT to stratify the risk of ANB [28].

Although an objective criterion informing ANB surgery would improve patient management, such a criterion has not been proposed to date. In the current multicenter study, we attempted to prove that the SUVmax from quantitative bone SPECT/CT is a useful biomarker for ANB disease severity and that a higher SUVmax value is associated with a greater chance of surgical resection, thereby suggesting that SUVmax is a potential eligibility criterion for ANB surgery.

Materials and methods

Participants

This retrospective multicenter trial involving four South Korean hospitals was supported in part by the Korean Society of Nuclear Medicine Clinical Trial Network (KSNM-CTN) working group funded by the Korean Society of Nuclear Medicine (KSNM-CTN-2017-01-01), while the nuclear medicine physicians of the participant hospitals were members of the ‘Korean Research Council of Hybrid SPECT, K-SPECT’. Since 2014, all four participating hospitals have installed state-of-the-art SPECT/CT scanners (2 GE in hospital A and B and 2 Siemens in hospital C and D) capable of radioactivity quantitation. Scanner sensitivities were calculated by imaging known Tc-99m activities measured by dose calibrators in each hospital. More details on the SPECT/CT acquisition and reconstruction parameters are shown in Table 1. This study was approved by the institutional review boards (IRBs) of the participating hospitals. The requirement for obtaining informed consent from the patients

was waived by the respective IRBs. All procedures performed in studies involving human participants were in accordance with the ethical standards of the institutional research committee and with the Helsinki Declaration as revised in 2013.

Patients

From all four hospitals, we recruited a total of 246 patients (age, 39.3 ± 19.7 years, mean \pm SD; sex ratio, men: women = 135:111) who had undergone bone SPECT/CT on their feet between October 2016 to November 2019. Patients were referred from orthopedic, rehabilitation or internal medicine clinics for evaluation of pain, sprain, fracture, trauma, arthropathy, flat foot, diabetic foot, gout, prehallux syndrome or known ANB. Patient characteristics differed among the four hospitals (Table 2). In three hospitals (A–C), approximately 40–53% of the patients with foot SPECT/CT were confirmed to have an ANB in either or both feet, whereas in hospital D, the only cause of bone SPECT/CT referral was the evaluation of known ANB. Thus, all patients (100%) from hospital D had unilateral or bilateral ANBs. Hospitals B and C, on the other hand, did not receive any bone SPECT/CT referrals with known ANB or previous prehallux syndrome. Thus, all ANBs diagnosed in these two hospitals were asymptomatic.

Accessory navicular bone feet

ANB types were determined by nuclear medicine physicians using the CT scans from foot SPECT/CT images. The distinction between symptomatic or asymptomatic ANBs was made by the referring physicians. ANB type (type 1, sesamoid type within tibialis posterior tendon; type 2, ossification center type with synchondrosis; and type 3, cornuate type with navicular tuberosity) and presence of pain were recorded for each individual foot.

Table 1 SPECT/CT scanners and acquisition/reconstruction parameters

		Hospital A	Hospital B	Hospital C	Hospital D
Scanner model (vendor)		NMCT670 (GE)	NMCT670DR (GE)	Symbia Intevo (Siemens)	Symbia Intevo (Siemens)
CT slice number		16	32	16	6
Radiopharmaceutical		Tc-99m-HDP	Tc-99m-MDP	Tc-99m-MDP	Tc-99m-DPD
Radioactivity		20 mCi	25 mCi	25 mCi	30 mCi
Time to imaging		2–3 h	3–4 h	2–3 h	3–4 h
Collimator		LEHR	LEHR	LEHR	LEHR
SPECT	Mode of acquisition	Step-and-shoot	Step-and-shoot	Step-and-shoot	Step-and-shoot
	Acquisition angle	3°	3°	4°	6°
	Acquisition time per step	10 s	20 s	22 s	30 s
	Peak energy	140 \pm 10 KeV (126–154 KeV)	140 \pm 10 KeV (126–154 KeV)	140 \pm 15 KeV (129.2–150.2 KeV)	140 \pm 15 KeV (129.2–150.2 KeV)
	Scatter energy	120 \pm 5 KeV (115–125 KeV)	120 \pm 5 KeV (115–125 KeV)	120 \pm 10 KeV (108–132 KeV)	120 \pm 10 KeV (108–132 KeV)
	Zoom	1.14	1	1	1
CT	Tube potential	120 kVp	120 kVp	110 kVp	110 kVp
	Tube current	60–210 mA	100–150 mA	80 mAs	150 mAs
	CT dose reduction	AutoMA	AutoMA	CareDose	CareDose
SPECT/CT reconstruction	Software	Q.Metrix	Q.Metrix	xSPECT Quant	xSPECT Quant
	AC/SC/RR	All yes	All yes	All yes	All yes
	Iteration (number, subset)	OSEM (2,10)	OSEM (4,10)	OSCGM (24,1)	OSCGM (24,2)
	System sensitivity	151.8 counts per min/ μ Ci	143.1 counts per min/ μ Ci	189.8 counts per min/ μ Ci	197.8 counts per min/ μ Ci

AC/SC/RR, attenuation correction/scatter correction/resolution recovery; CT, computed tomography; DPD, dicarboxypropane diphosphonate; HDP, hydroxymethylene diphosphonate; LEHR, low energy high resolution collimator; MDP, methylene diphosphonate; OSEM, ordered subset expectation maximization; OSCGM, ordered subset conjugate gradient maximization; SPECT, single-photon emission computed tomography.

Table 2 Patients' characteristics

		Hospital A	Hospital B	Hospital C	Hospital D	<i>P</i> value
Patients	Number of patients (total 246)	106	33	94	13	
	Age, years (mean ± STD)	31.3 ± 18.2	61.2 ± 11.7	42.2 ± 17.6	28.5 ± 15.2	<0.000001
	Men:women	46:60	23:10	56:38	10:3	0.0075
	With ANB (%)	52.8% (=56/106)	54.5% (=18/33)	40.4% (=38/94)	100% (=13/13)	0.0004
	Unilateral: bilateral	16:40	1:17	14:24	7:6	0.0237
Foot	Number of foot with ANB (total 212)	96	35	62	19	
	Type 1	19	14	21	8	0.0308
	Type 2	68	17	40	11	
	Type 3	9	4	1	0	

ANB, accessory navicular bone; SPECT/CT, single-photon emission computed tomography/computed tomography.

Maximum standardized uptake value measurement

Injected radioactivity measured by dose calibrators (CRC-15R; CAPINTEC for hospitals A, B and D; and CRC-25R, CAPINTEC for hospital C) and time of injection were recorded and employed for SUVmax calculation. Remnant radioactivity after injection and the corresponding measurement time was also recorded. All dose calibrators were calibrated using a national institute of standards and technology traceable Co-57 point source of their own and as a part of a quality control program of the Korean Society of Nuclear Medicine. Dedicated quantitative software (Q.Metrix for GE and xSPECT Quant for Siemens) was employed for SUVmax measurement. ANBs were identified using the CT image of SPECT/CT, and a spherical volume-of-interest (VOI) was drawn over the ANB and navicular tuberosity (Fig. 1). The VOI volume was $3.86 \pm 2.14 \text{ cm}^3$. The equation for the SUVmax calculation was as follows:

$$\text{SUV}_{\text{max}} = \frac{\text{Decay-corrected radioactivity} / \text{voxel volume}}{\text{Injected radioactivity} / \text{body weight}}$$

Statistical analysis

If the assumption of equal variance was not satisfied by Levene's test, group comparisons were performed using the Kruskal-Wallis test. Post hoc (Conover) analysis was performed if the Kruskal-Wallis test showed statistical significance. A chi-square test was employed for comparison of proportions. A Cox proportional-hazard regression analysis was performed for the variables of age and SUVmax in relation to the prediction of surgical resection. A receiver operating characteristic (ROC) curve and Kaplan-Meier survival analysis was used for the demonstration of the optimal SUVmax cutoff for surgery. All analyses were performed with the statistical software MedCalc Version 19.2.1 (MedCalc Software Ltd, Ostend, Belgium). A *P* value <0.05 was considered statistically significant.

Results

Maximum standardized uptake value by hospitals

We analyzed the SUVmax and ANB type for each foot with ANB (*n* = 212). The SUVmax data of the 212 ANBs from the four hospitals are displayed in Fig. 2. Surgical resection was performed in only two hospitals,

as indicated by the arrows pointing at the resected ANBs (Fig. 2). Type 2 was the only surgically treated ANB type.

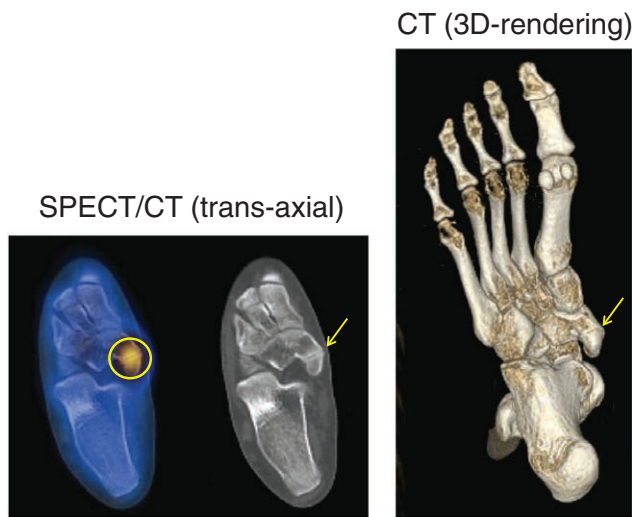
Maximum standardized uptake value by accessory navicular bone type and symptoms

All SUVmax data from the four hospitals were summed up. Type 2 ANBs showed the highest SUVmax values (*P* = 0.0101 by the Kruskal-Wallis test), with a statistically significant difference between types 1 and 2 (*P* < 0.05) and no significant difference between types 2 and 3 (*P* > 0.05) in post hoc analysis (Fig. 3a). Next, all 212 ANBs were analyzed according to the presence of pain and surgical treatment. One-hundred and forty-one ANBs were asymptomatic and were not resected. Seventy-one ANBs were symptomatic, and surgery was performed on 17 ANBs (23.9%, 17/71). We found that asymptomatic ANBs had significantly lower SUVmax values (2.30 ± 1.68 , *n* = 141) than the symptomatic ANBs that did not require surgery (6.15 ± 4.40 , *n* = 54) and those that were ultimately resected (8.27 ± 5.23 , *n* = 17) (*P* < 0.05). However, the SUVmax values for the symptomatic ANBs that did not require resection (*n* = 54) and those that did (*n* = 17) were not significantly different (*P* > 0.05). Thus, the SUVmax gradually increased from asymptomatic to symptomatic cases, reaching its highest levels for surgically resected ANBs (*P* < 0.0001 by the Kruskal-Wallis test) (Fig. 3b).

Maximum standardized uptake value and surgical resection

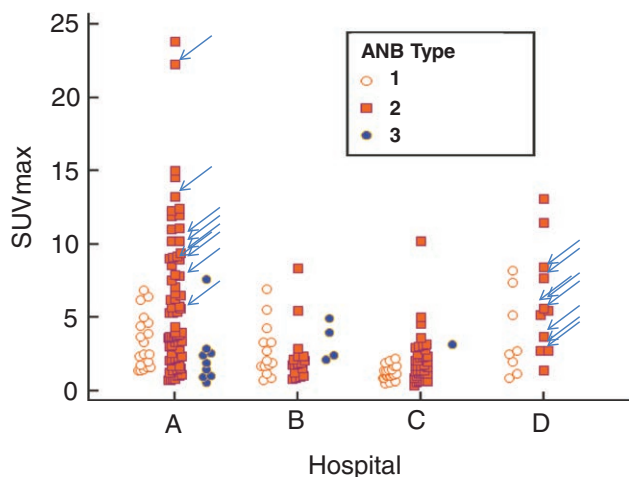
The presence of pain was the reason for surgical treatment in all cases that underwent resection of ANB. However, the decision to perform surgery was made by the physicians without referring to the SUVmax values. Thus, we investigated whether SUVmax values could serve as an objective criterion for ANB resection. The time from bone SPECT/CT to surgery or last follow-up was analyzed using Cox regression analysis, and ANB cases without follow-up information after bone SPECT/CT (*n* = 39) were excluded. We also excluded cases of type 1 or 3 ANBs (*n* = 59) because only type 2 ANB was a surgical target. Thus, 114 cases of type 2 ANB were investigated, of which 14 involved surgical resection. In a univariate analysis, age [*P* = 0.0267, exp (β) = 0.9560, 95% confidence interval (CI) of exp (β) = 0.9188–0.9948] and

Fig. 1



Measurement of SUVmax. A spherical volume-of-interest (yellow circle) was placed over the ANB and the navicular tuberosity. The arrows indicate the synchondrosis, the cartilage connection between the ANB and navicular tuberosity in type 2 ANB. ANB, accessory navicular bone; SUVmax, maximum standardized uptake value.

Fig. 2



SUVmax categorized by hospitals. Arrows indicate ANBs with surgical resection. ANB, accessory navicular bone; SUVmax, maximum standardized uptake value.

SUVmax ($P < 0.0001$, $\exp(\beta) = 1.1671$, 95% CI of $\exp(\beta) = 1.0878-1.2521$) were predictors of surgical resection. However, in a stepwise multivariate analysis using age and SUVmax, age dropped out and only SUVmax remained as an independent predictor of surgical resection ($P = 0.0002$ for overall model fit, and $P < 0.0001$ as a covariate with $\exp(\beta) = 1.1671$, 95% CI of $\exp(\beta) = 1.0878-1.2521$).

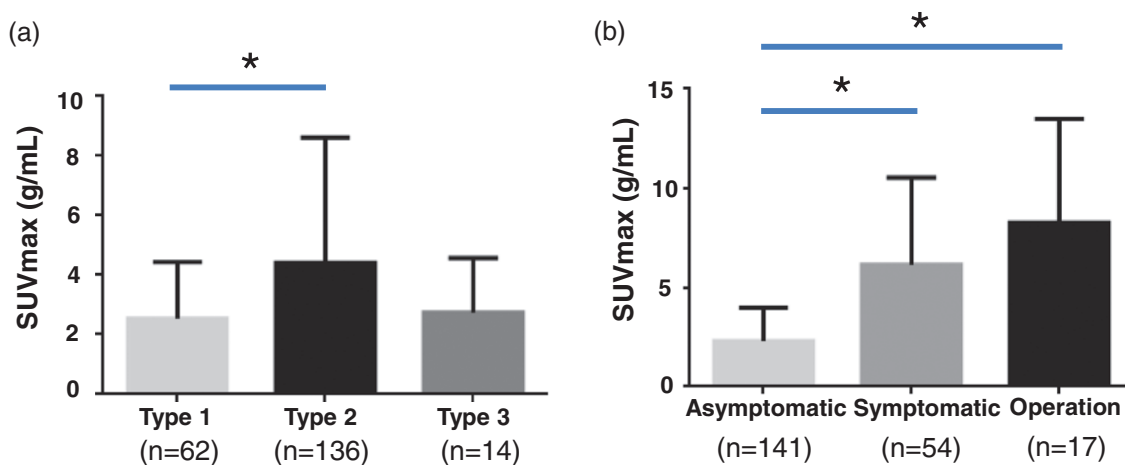
In the ROC curve and Kaplan–Meier analysis, a SUVmax value of 5 was the optimal cutoff value for discrimination between surgical and nonsurgical treatment, with the highest chi-square (23.18) and the lowest P value (< 0.0001) among various SUVmax values. The area under the curve for the SUVmax value was 0.847, with a 95% CI of 0.791–0.893, sensitivity of 82.35% and specificity of 80.51% (Fig. 4a). Among the 40 type 2 ANBs with SUVmax values ≥ 5 , 13 (32.5%) ultimately underwent surgical resection, whereas among the 74 type 2 ANBs with SUVmax values < 5 , only one (1.35%) underwent surgery ($P < 0.0001$ by the log-rank test) (Fig. 4b).

Discussion

In a previous single-center study, ANBs were investigated using Tc-99m hydroxymethylene diphosphonate (HDP) SPECT/CT, and a high SUVmax was closely related with ultimate surgical resection [28]. In the current multi-center study, we recruited ANB cases from four hospitals with state-of-the-art SPECT/CT scanners. Although the four hospitals employed different software and hardware, the obtained SUVmax values did not differ significantly with regard to the order of scale. The SUVmax distribution in relation to ANB type (i.e. the highest SUVmax of type 2 ANB) and the association between SUVmax with surgical treatment in our study suggested that disease activity evaluation and prognosis prediction of ANB can be realized using quantitative bone SPECT/CT.

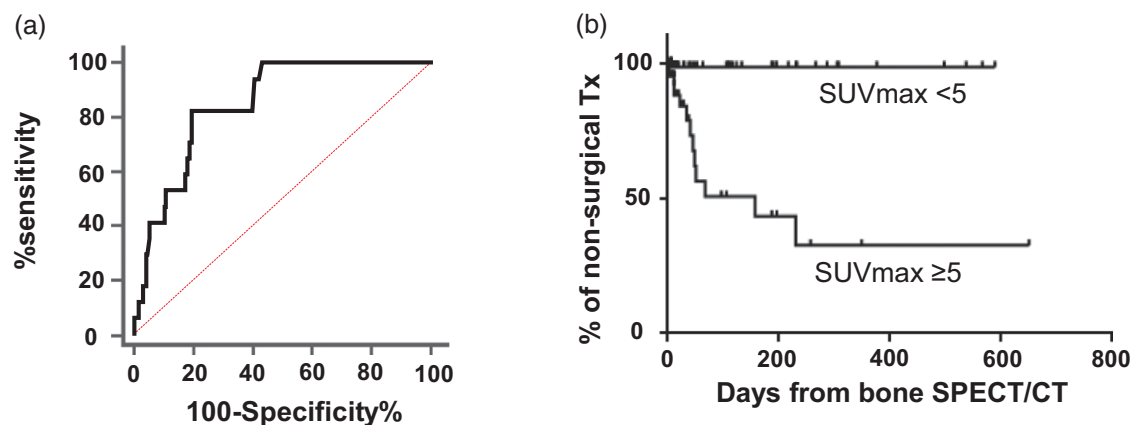
PET has allowed the evaluation of disease activity and prognosis prediction in a variety of malignant diseases [29–31]. This can be attributed to the fact that PET allows absolute quantification of radioactivity and the use of radiopharmaceuticals such as F-18 fluorodeoxyglucose (FDG), which readily reflect the biological aggressiveness of cancer. Quantitative SPECT/CT has recently emerged as a truly quantitative imaging modality like PET, and its influence on patient management has been investigated [26]. For example, Tc-99m pertechnetate thyroid uptake measured using quantitative SPECT/CT was shown to be associated with treatment response, allowing identification of poor responders before the initiation of medication [19]. Our results suggest that ANB management may be improved by using an objective parameter that reflects ANB disease severity. The decision to perform ANB surgery is based on the surgeons' discretion and is occasionally made without objective evidence of improved patient outcomes [32–34]. Unlike subjective methods such as grading of bone scan agent uptake (e.g. grades 0–2, with grade 0 indicating no uptake and grade 2 with intense uptake) or all-or-none approaches (positive or negative uptake) [10,11], the SUVmax offers a more objective and accurate evaluation because the injected amounts of bone scan agents are normalized to the patient's weight, and lesion radioactivity is corrected for attenuation, scattering and variations in the distance between patients and detectors [35,36].

Fig. 3



SUVmax categorized by ANB type and symptom. (a) SUVmax based on ANB type. Type 2 ANB showed the highest SUVmax. SUVmax (g/mL, mean \pm SD) was 2.55 ± 1.90 ($n = 62$), 4.41 ± 5.21 ($n = 136$) and 2.74 ± 1.84 ($n = 14$) for types 1, 2 and 3, respectively. (b) SUVmax based on symptoms and surgical treatment. SUVmax was 2.30 ± 1.68 ($n = 141$), 6.15 ± 4.40 ($n = 54$) and 8.27 ± 5.23 ($n = 17$) for asymptomatic, symptomatic (no surgery), and resected symptomatic ANB, respectively. ANB, accessory navicular bone; SUVmax, maximum standardized uptake value. * $P < 0.05$ by post hoc analysis of Kruskal–Wallis test.

Fig. 4



(a) ROC curve analysis for ANB patients without surgery from resected symptomatic ANB. The SUVmax showed an area under the curve value of 0.847 with 95% CI of 0.791–0.893. (b) Kaplan–Meier analysis for the optimal SUVmax cutoff in relation to surgical treatment of type 2 ANB ($n = 114$). A SUVmax cutoff of 5 was the optimal discriminator of surgical ANB treatment. ROC, receiver operating characteristic; ANB, accessory navicular bone; SUVmax, maximum standardized uptake value; CI, confidence interval.

Most of the limitations of this study can be attributed to its multicentric and retrospective nature. The scanner harmonization issue is the primary limitation that needs to be addressed. We did not perform a comparison analysis of SPECT/CT scanner performance. Furthermore, the acquisition and reconstruction protocols differed even for scanners from the same vendor. Therefore, this study can be considered to be preliminary in nature. However, we think that the currently available SPECT/CT scanners can generate clinically useful SUV data that may be applied to patient management without further validation, at least within each hospital. Second, SUVmax-guided operations

should justify the extra cost of SPECT/CT since not all patient outcomes may be determined by the uptake of bone scan agents. In this regard, the surgeons' technique may have a greater influence on the outcome than the disease activity reflected by the SUVmax. Moreover, for such nonfatal diseases, planar scintigraphy without SPECT may be sufficient for the evaluation of disease activity. However, a head-to-head comparison between conventional planar scans and quantitative SPECT/CT was not performed in our study. Third, clinical parameters other than SUVmax may influence the decision to perform surgery, although young age did not persist as an influencing factor in

multivariate analysis in our study. However, daily activity or exercise may be decisive factors influencing ANB injuries and a subsequently high SUVmax, and these compounding factors were not evaluated in our study. Therefore, additional well-controlled prospective studies are warranted to validate our findings.

Finally, the incidental high uptake of bone tracer uptake on other accessory ossicles, such as os trigonum, has not been thoroughly investigated in the current study. We focused only on ANB, whether symptomatic or asymptomatic. Further studies are warranted for these variants of accessory ossicles.

Conclusion

Quantitative bone SPECT/CT is a useful imaging modality for evaluation of ANB disease severity, and the SPECT/CT quantitative parameter SUVmax may facilitate surgical decision-making. The current retrospective multicenter study warrants further prospective studies.

Acknowledgements

We would like to thank Editage for English language editing.

This work was supported in part by the Basic Science Research Program through the National Research Foundation of Korea funded by the Ministry of Education (2018R1D1A1A09081961) and by the Korean Society of Nuclear Medicine Clinical Trial Network (KSNM-CTN) working group funded by the Korean Society of Nuclear Medicine (KSNM-CTN-2017-01-01).

Conflicts of interest

There are no conflicts of interest.

References

- Keles-Celik N, Kose O, Sekerci R, Aytac G, Turan A, Güler F. Accessory ossicles of the foot and ankle: disorders and a review of the literature. *Cureus* 2017; **9**:e1881.
- Ugolini PA, Raikin SM. The accessory navicular. *Foot Ankle Clin* 2004; **9**:165–180.
- Kim JR, Park CI, Moon YJ, Wang SI, Kwon KS. Concomitant calcaneo-cuboid-cuneiform osteotomies and the modified Kidner procedure for severe flatfoot associated with symptomatic accessory navicular in children and adolescents. *J Orthop Surg Res* 2014; **9**:131.
- Malicky ES, Levine DS, Sangeorzan BJ. Modification of the Kidner procedure with fusion of the primary and accessory navicular bones. *Foot Ankle Int* 1999; **20**:53–54.
- Kopp FJ, Marcus RE. Clinical outcome of surgical treatment of the symptomatic accessory navicular. *Foot Ankle Int* 2004; **25**:27–30.
- Nakayama S, Sugimoto K, Takakura Y, Tanaka Y, Kasanami R. Percutaneous drilling of symptomatic accessory navicular in young athletes. *Am J Sports Med* 2005; **33**:531–535.
- Scott AT, Sabesan VJ, Saluta JR, Wilson MA, Easley ME. Fusion versus excision of the symptomatic Type II accessory navicular: a prospective study. *Foot Ankle Int* 2009; **30**:10–15.
- Romanowski CA, Barrington NA. The accessory navicular—an important cause of medial foot pain. *Clin Radiol* 1992; **46**:261–264.
- Miller TT, Staron RB, Feldman F, Parisien M, Glucksman WJ, Gandolfo LH. The symptomatic accessory tarsal navicular bone: assessment with MR imaging. *Radiology* 1995; **195**:849–853.
- Chiu NT, Jou IM, Lee BF, Yao WJ, Tu DG, Wu PS. Symptomatic and asymptomatic accessory navicular bones: findings of Tc-99m MDP bone scintigraphy. *Clin Radiol* 2000; **55**:353–355.
- Chong A, Ha JM, Lee JY. Clinical meaning of hot uptake on bone scan in symptomatic accessory navicular bones. *Nucl Med Mol Imaging* 2016; **50**:322–328.
- Mohan HK, Gnanasegaran G, Vijayanathan S, Fogelman I. SPECT/CT in imaging foot and ankle pathology—the demise of other coregistration techniques. *Semin Nucl Med* 2010; **40**:41–51.
- Saha S, Burke C, Desai A, Vijayanathan S, Gnanasegaran G. SPECT-CT: applications in musculoskeletal radiology. *Br J Radiol* 2013; **86**:20120519.
- Upadhyay B, Mo J, Beadsmoore C, Marshall T, Toms A, Buscombe J. Technetium-99m methylene diphosphonate single-photon emission computed tomography/computed tomography of the foot and ankle. *World J Nucl Med* 2017; **16**:88–100.
- Mohan HK, Strobel K, van der Bruggen W, Gnanasegaran G, Kampen WU, Kuwert T, et al. The role of hybrid bone SPECT/CT imaging in the work-up of the limping patient: a symptom-based and joint-oriented review. *Eur J Hybrid Imaging* 2018; **2**:8.
- Yoo IR. Bone SPECT/CT of the foot and ankle: potential clinical application for chronic foot pain. *Nucl Med Mol Imaging* 2020; **54**:1–8.
- Suh MS, Lee WW, Kim YK, Yun PY, Kim SE. Maximum standardized uptake value of (99m)Tc hydroxymethylene diphosphonate SPECT/CT for the evaluation of temporomandibular joint disorder. *Radiology* 2016; **280**:890–896.
- Lee H, Kim JH, Kang YK, Moon JH, So Y, Lee WW. Quantitative single-photon emission computed tomography/computed tomography for technetium pertechnetate thyroid uptake measurement. *Medicine (Baltimore)* 2016; **95**:e4170.
- Kim HJ, Bang JI, Kim JY, Moon JH, So Y, Lee WW. Novel application of quantitative single-photon emission computed tomography/computed tomography to predict early response to methimazole in Graves' Disease. *Korean J Radiol* 2017; **18**:543–550.
- Kim J, Lee HH, Kang Y, Kim TK, Lee SW, So Y, Lee WW. Maximum standardised uptake value of quantitative bone SPECT/CT in patients with medial compartment osteoarthritis of the knee. *Clin Radiol* 2017; **72**:580–589.
- Kang YK, Park S, Suh MS, Byun SS, Chae DW, Lee WW. Quantitative single-photon emission computed tomography/computed tomography for glomerular filtration rate measurement. *Nucl Med Mol Imaging* 2017; **51**:338–346.
- Kim JY, Kim JH, Moon JH, Kim KM, Oh TJ, Lee DH, et al. Utility of quantitative parameters from single-photon emission computed tomography/computed tomography in patients with destructive thyroiditis. *Korean J Radiol* 2018; **19**:470–480.
- Kim J, Lee H, Lee H, Bang JI, Kang YK, Bae S, et al. Quantitative single-photon emission computed tomography/computed tomography for evaluation of salivary gland dysfunction in sjögren's syndrome patients. *Nucl Med Mol Imaging* 2018; **52**:368–376.
- Lee R, So Y, Song YS, Lee WW. Evaluation of hot nodules of thyroid gland using Tc-99m pertechnetate: a novel approach using quantitative single-photon emission computed tomography/computed tomography. *Nucl Med Mol Imaging* 2018; **52**:468–472.
- Park J, Bae S, Seo S, Park S, Bang JI, Han JH, et al. Measurement of glomerular filtration rate using quantitative SPECT/CT and deep-learning-based kidney segmentation. *Sci Rep* 2019; **9**:4223.
- Lee WW; K-SPECT Group. Clinical applications of technetium-99m quantitative single-photon emission computed tomography/computed tomography. *Nucl Med Mol Imaging* 2019; **53**:172–181.
- Ryoo HG, Lee WW, Kim JY, Kong E, Choi WH, Yoon JK; K-SPECT Group. Minimum standardized uptake value from quantitative bone single-photon emission computed tomography/computed tomography for evaluation of femoral head viability in patients with femoral neck fracture. *Nucl Med Mol Imaging* 2019; **53**:287–295.
- Bae S, Kang Y, Song YS, Lee WW; K-SPECT Group. Maximum standardized uptake value of foot SPECT/CT using Tc-99m HDP in patients with accessory navicular bone as a predictor of surgical treatment. *Medicine (Baltimore)* 2019; **98**:e14022.
- Song YS, Lee WW, Lee JS, Kim SE. Prediction of central nervous system relapse of diffuse large B-cell lymphoma using pretherapeutic [18F]2-Fluoro-2-Deoxyglucose (FDG) positron emission tomography/computed tomography. *Medicine (Baltimore)* 2015; **94**:e1978.
- Chang H, Lee SJ, Lim J, Lee JS, Kim YJ, Lee WW. Prognostic significance of metabolic parameters measured by 18F-FDG PET/CT in limited-stage small-cell lung carcinoma. *J Cancer Res Clin Oncol* 2019; **145**:1361–1367.

- 31 Wang J, Kim D, Kang WJ, Cho H. Prognostic value of bone marrow F-18 FDG uptake in patients with advanced-stage diffuse large B-cell lymphoma. *Nucl Med Mol Imaging* 2020; **54**:28–34.
- 32 Chung JW, Chu IT. Outcome of fusion of a painful accessory navicular to the primary navicular. *Foot Ankle Int* 2009; **30**:106–109.
- 33 Kiter E, Günel I, Turgut A, Köse N. Evaluation of simple excision in the treatment of symptomatic accessory navicular associated with flat feet. *J Orthop Sci* 2000; **5**:333–335.
- 34 Choi HJ, Lee WC. Revision surgery for recurrent pain after excision of the accessory navicular and relocation of the tibialis posterior tendon. *Clin Orthop Surg* 2017; **9**:232–238.
- 35 Ritt P, Vija H, Hornegger J, Kuwert T. Absolute quantification in SPECT. *Eur J Nucl Med Mol Imaging* 2011; **38**:S69–S77.
- 36 Bailey DL, Willowson KP. An evidence-based review of quantitative SPECT imaging and potential clinical applications. *J Nucl Med* 2013; **54**: 83–89.