

Successful treatment of brain radiation necrosis resulting from triple-negative breast cancer with Endostar and short-term hyperbaric oxygen therapy: a case report

This article was published in the following Dove Press journal:
OncoTargets and Therapy

Shiyun Xing^{1,*}
Zhenhai Fan^{2,*}
Lei Shi¹
Ze Yang¹
Yuju Bai¹

¹Department of Oncology, Affiliated Hospital of Zunyi Medical University, Zunyi, People's Republic of China; ²Key Laboratory of Cell Engineering of Guizhou, Affiliated Hospital of Zunyi Medical University, Zunyi, People's Republic of China

*These authors contributed equally to this work

Abstract: Radiation necrosis (RN) is one of the complications of radiotherapy. Angiogenesis is a key factor underlying the development of RN, and Endostar, a safe and well-tolerated recombinant human endostatin, has been used to treat a variety of tumors. Thus far, however, no definitive reports on the use of Endostar for RN treatment have been reported. Here, we report the successful treatment of one patient with symptomatic brain radiation necrosis (BRN) using Endostar in combination with short-term hyperbaric oxygen therapy (HBO). One triple-negative breast cancer patient with recurrent brain metastatic lesions after standard chemoradiotherapy was referred to a specialty center outside our hospital for stereotaxic radiotherapy. Two months later, the patient showed deteriorating clinical symptoms, and magnetic resonance imaging (MRI) showed radiation necrosis with significant surrounding edema. The patient had a poor response to mannitol and steroids. After diagnosing this patient with BRN, we began short-term HBO therapy and intravenously administered Endostar for 4 cycles. The patient responded well to this strategy, showing rapidly and dramatically improved MRI findings and clinical symptoms. No tumor progression was observed at 10 months after treatment. Endostar in combination with short-term HBO therapy had marked effects on symptomatic BRN. However, additional large-scale, double-blinded, controlled trials are necessary to confirm the clinical effect of Endostar in combination with a short-term HBO therapy regimen on BRN.

Keywords: brain radiation necrosis, triple-negative breast cancer, Endostar, hyperbaric oxygen therapy

Introduction

Research indicates that triple-negative breast cancer (TNBC) has a propensity for visceral metastasis to the brain and lung.^{1,2} The incidence of brain metastasis has been steadily increasing in recent years.³ Therapeutic irradiation is an important modality for locally controlling disease associated with metastatic brain tumors.⁴⁻⁷ Recently, high-dose radiotherapies, such as intensity-modulated radiation therapy, proton beam radiotherapy, and boron neutron capture therapy, have been used for the treatment of brain tumors and have led to better expected outcomes than those achieved with conventional radiotherapy. Although the central nervous system (CNS) was first thought to be highly radioresistant, studies have shown that the CNS, particularly the white matter in the deep part of the brain, is more

Correspondence: Yuju Bai
Department of Oncology, Affiliated Hospital of Zunyi Medical University, No. 149, Da Lian Road, Huichuan district, Zunyi, Guizhou 563000, People's Republic of China
Tel +86 851 2860 9038
Email BYJ6618@163.com

radioresponsive than previously believed.^{8–10} Local radiation injuries can occur from as early as a few months to 10 or more years after radiotherapy.¹¹ Brain radiation necrosis (BRN) is an adverse event widely known to be associated with therapeutic irradiation to the CNS and focal injuries resulting from late radiation effects, causing focal neurological abnormalities.

Diagnosis and treatment of BRN remain challenging because it is not easily distinguishable from tumor recurrence without pathological examination of a resected sample,¹² and the therapeutic strategies for tumor progression and treatment-related RN are completely different. RN initially responds to corticosteroids, but progressive RN is refractory to medical treatment. Vascular endothelial growth factor (VEGF) has been reported to play an important role in the development of RN, and blocking the function of VEGF has been reported to be effective at treating RN and reducing perilesional edema.^{13–15}

Endostar is a modified and recombinant human endostatin that was first used for the treatment of nonsmall-cell lung cancer (NSCLC), and similar to endostatin, Endostar blocks the VEGF signaling pathway. The use of Endostar to treat radiation encephalopathy has not been indicated in the literature. Herein, we report the successful treatment of one patient with BRN after radiotherapy using Endostar in combination with a single course of hyperbaric oxygen (HBO) therapy.

Case report

A 45-year-old female patient was diagnosed with clinical stage breast cancer (IIIC, pT2N3M0) in her right breast. Pathological results revealed that the tumor was invasive ductal carcinoma, ER(-), PgR(-), and HER2(-). After treatment via a modified radical right mastectomy, the patient received six cycles of adjuvant chemotherapy with a docetaxel (Taxotere), doxorubicin (Adriamycin), and cyclophosphamide (TAC) regimen; capecitabine as a single-drug treatment for three cycles; and adjuvant radiation (DT 50 Gy). Ten months after surgery, the patient complained of headache and dizziness. Magnetic resonance imaging (MRI) revealed an enhanced solitary mass (19×22×25 mm) with a surrounding area of low intensity in the right basal ganglia, associated with left frontal lobe metastases (Figure 1A), and the patient was consequentially diagnosed with brain metastasis. Contrast-enhancement T1-weighted images showed that the enhanced mass was surrounded by a hypointense area, a finding consistent with edema; no other metastases were observed. The patient received whole-brain

radiotherapy (3,860 cGy) and increased doses of radiotherapy to the metastatic carcinoma sites (2,000 cGy). After radiotherapy, the patient was treated with temozolomide for two cycles.

Two months after brain radiotherapy, a follow-up MRI revealed that the cerebral metastatic tumor volumes in the right basal ganglia and left frontal lobe were significantly reduced, and the therapeutic effect was evaluated as a complete response (CR) (Figure 1B). Seven courses of autologous dendritic cell/cytokine-induced killer cell (DC-CIK) therapy were administered, and temozolomide therapy was continued for four cycles. The patient showed stable disease for nineteen months.

However, thirty-three months after the first brain radiotherapy, the patient once again complained of headache and dizziness, and a cranial MRI reexamination revealed metastatic brain tumor recurrence and progression (Figure 2A). Once again, the patient was administered four cycles of temozolomide. Two months later, an MRI scan revealed slow progression of the brain tumor metastases (Figure 2B), and the patient then underwent stereotaxic radiotherapy for brain tumor metastases at the Nanfang Hospital of Nanfang Medical University (dosage not stated). A few days later, the patient developed headache, dizziness and muscle strength degeneration; these symptoms were progressively exacerbated. The MRI results showed brain metastases and radiation encephalopathy. An enhanced solitary mass (53×28×20 mm) with a surrounding area of low intensity was observed in the bilateral frontal lobe and genu of the corpus callosum (Figure 3A). We treated the patient with mannitol and steroids to reduce the intracranial pressure and further limit the damage caused by cerebral edema. The patient's condition was wavering and lingered, and her quality of life deteriorated. Next, the patient was treated with tamoxifen to prevent tumor recurrence and progression. Three months later, an MRI reexamination showed radiation encephalopathy that could not exclude brain metastases; the lesion area was not decreased after treatment (Figure 3B).

Considering that radiation encephalopathy could have occurred, we attempted to adapt HBO therapy. After only one treatment, the patient felt much better; her headache and dizziness disappeared, and her muscle strength was obviously restored. We continued to administer HBO therapy once a day for ten days, and the patient subsequently received four cycles of the Endostar regimen (30 mg of a continuous infusion, D1~7). Two and six months after Endostar treatment, MRI analysis showed that the areas of BRN and edema had decreased significantly (Figure 4A and B).

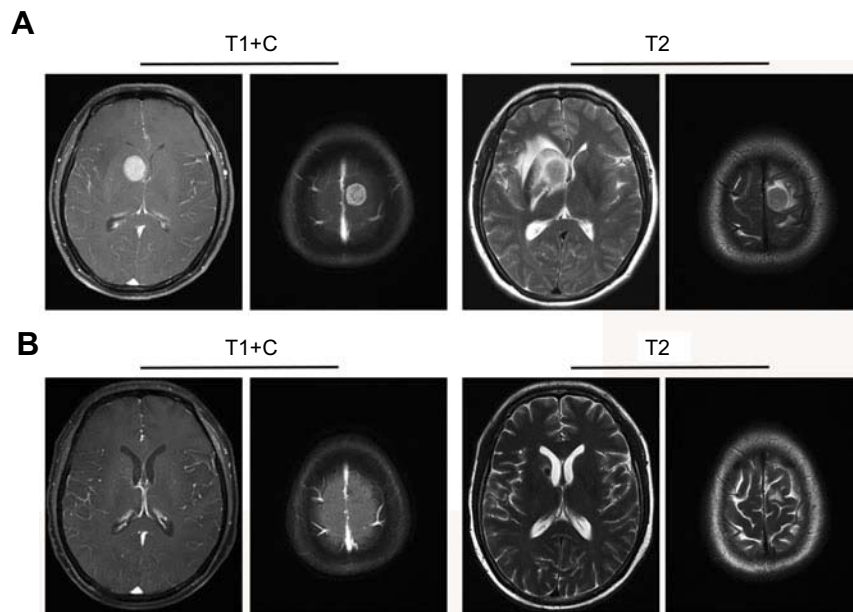


Figure 1 MRI detection of brain metastasis and an MRI scan after curative radiotherapy. **(A)** Contrast-enhancement T1-weighted images revealed an enhanced solitary mass 19×22×25 mm in size with a surrounding area of low intensity in the right basal ganglia, associated with left frontal lobe metastases. **(B)** One month after curative radiotherapy, the MRI scan showed that the brain metastatic tumoral volume was significantly reduced and had disappeared.

Abbreviations: MRI, magnetic resonance imaging; T1+C, contrast-enhancement T1-weighted images; T2, T2-weighted images.

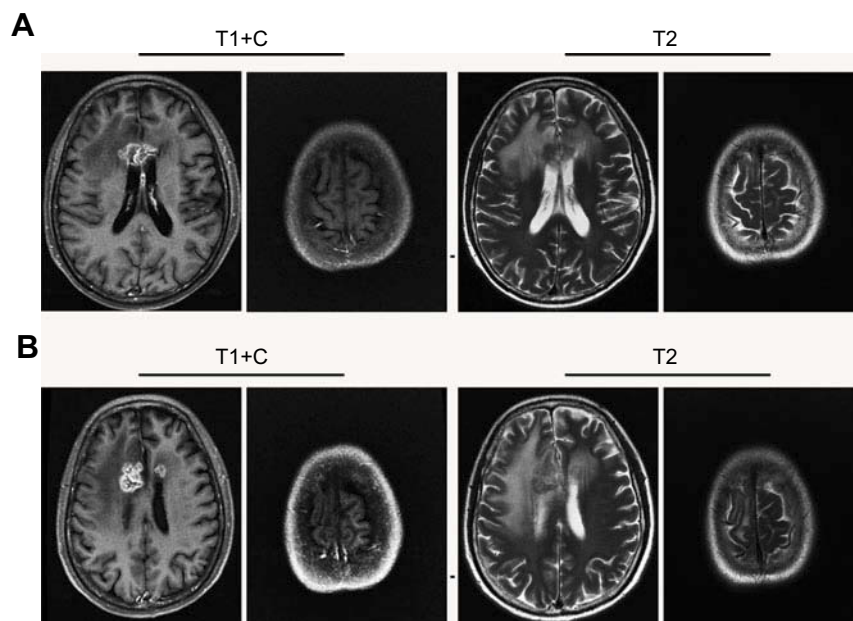


Figure 2 MRI detection of brain metastasis recurrence and MRI scanning after administration of the temozolomide regimen. **(A)** An MRI scan revealed an irregularly strengthened signal in the anterior corpus callosum and peripheral edema of the lesions. **(B)** One year after administration of the temozolomide regimen for four cycles, an MRI scan revealed that the lesions in the anterior corpus callosum had decreased, but the size of the lesions in the right lateral ventricle had significantly increased.

Abbreviations: MRI, magnetic resonance imaging; T1+C, contrast-enhancement T1-weighted images; T2, T2-weighted images.

Discussion

The incidence of CNS metastases among patients with advanced TNBC is as high as 46%,¹⁶ and the median survival time from the point of a CNS metastasis diagnosis

is only 4.9 months.¹⁷ Thus far, no breast cancer-specific modalities have been approved for the treatment of brain metastases, and the main standard of care is local radiotherapy. In this case, radiotherapy therapy was effective at

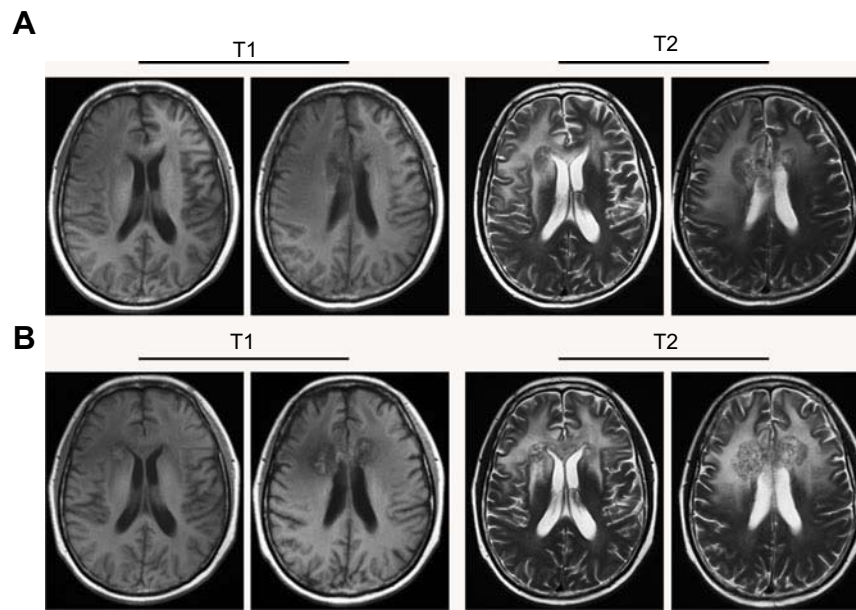


Figure 3 MRI scan after stereotactic radiotherapy. **(A and B)** After treating with mannitol and steroids to reduce intracranial pressure and to limit further damage caused by cerebral edema, an MRI scan revealed an enhanced solitary mass (53×28×20 mm) with a surrounding area of low intensity in the bilateral frontal lobe and genu of the corpus callosum. **Abbreviations:** MRI, magnetic resonance imaging; T1, T1-weighted images; T2, T2-weighted images.

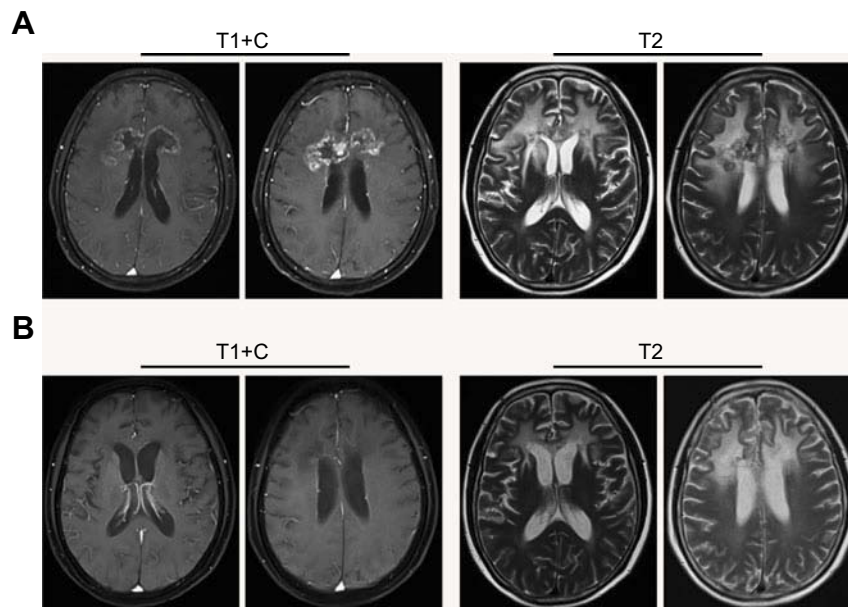


Figure 4 MRI scan after treating with a vascular endostatin and short-term HBO therapy. **(A and B)** After treating with a vascular endostatin and short-term HBO therapy, an MRI scan revealed that the clumps of matter in the bilateral frontal lobes and the genu of the corpus callosum were smaller than those on the MRI scan from 2017–07 and especially smaller than those shown on the MRI scan from 2018–06; however, the edema in the surrounding tissue was still present. **Abbreviations:** MRI, magnetic resonance imaging; HBO therapy, hyperbaric oxygen therapy; T1+C, contrast-enhancement T1-weighted images; T2, T2-weighted images.

reducing the brain metastatic tumor volume and maintaining a nonrecurrent status. High incidence rates of RN and symptomatic changes have been associated with high-dose radiotherapies.^{18,19} Therefore, developing high-dose radiotherapies and successfully treating BRN are also important.

Several studies have reported that HBO therapy could both decrease intracranial pressure and reduce the incidence and severity of BRN symptoms, including headaches, new seizure onset, general cognitive decline, and focal neurological deficits.^{20–22} However, most of these studies were small and retrospective, and most patients received steroids

concurrently; thus, determining whether the symptoms of RN are improved with longer durations of steroid treatment or HBO is difficult.²³ Furthermore, the dose of radiation administered by the outside specialty center was not clear, and metastatic lesion progression or deterioration could not be ruled out when relying solely on the MRI results. Decisions regarding therapy for BRN are often affected by whether the patient has received a definitive diagnosis. Therefore, rather than adopting HBO therapy, we initially treated this patient with mannitol and steroids to reduce the intracranial pressure and to limit further damage caused by cerebral edema. However, the curative effect of this strategy was extremely poor. Considering that BRN could have occurred, we attempted to adapt HBO therapy, and interestingly, the clinical symptoms of intracranial hypertension were significantly reduced. This finding suggests that when radiation encephalopathy is highly suspected, disease progression should not be ruled out, and applying short-term HBO therapy might be a good treatment choice.

The pathophysiological mechanisms underlying BRN are thought to mainly consist of endothelial abnormalities and elevated levels of cytokines, eg VEGF, resulting in increased vascular permeability, extracellular edema and, ultimately, hypoxia and necrosis.²⁴ Research indicates that VEGF knockout mice are resistant to radiation injury,²⁵ and VEGF-producing astrocytes could concentrate in perinecrotic areas and be a universal cause of pathological angiogenesis in RN and subsequent perilesional edema.^{13,26} These results indicate that VEGF is responsible for factors related to deep RN growth. As a selective inhibitor of VEGF biological effects, the monoclonal antibody bevacizumab offers symptomatic relief, a reduction in steroid requirements, and a dramatic radiographic response and appears to be a promising agent for the treatment of BRN.^{15,27–29} However, most patients experience recurrence after bevacizumab is discontinued, and some patients even become resistant to the drug and experience retreatment failure, followed by cancer progression.^{30,31} Endostar, a new recombinant human endostatin expressed and purified in *Escherichia coli*, was approved by China's State Food and Drug Administration (SFDA) for the treatment of NSCLC in 2005. The anti-angiogenic activity of endostatin is not the result of a single molecular action but is very complex. Endostatin activity reportedly leads to the induction of endothelial cell apoptosis, cell cycle arrest and suppression of endothelial cell proliferation and migration via a complex signaling system,^{32–36} thereby powerfully

suppressing neovascularization. Research has indicated that endostatin alone or in combination with radiotherapy and chemotherapy could inhibit the progression of multiple cerebral metastases in various types of tumors.^{37–41} To the best of our knowledge, this is the first report to evaluate the role of Endostar for the treatment of BRN resulting from any tumor type. In this case, Endostar effectively improved the symptoms of intracranial hypertension, significantly reduced the area of BRN and maintained the nonrecurrent status in the brain. It is also worth noting that the patient resumed a normal life and worked after treatment, and no recurrence was observed during a follow-up period of 10 months.

This case report provides a useful reference for the clinical management of patients with BRN. However, additional research is required to verify the effectiveness of Endostar in combination with a short-term HBO therapy regimen on BRN.

Conclusion

Endostar in combination with short-term HBO therapy had marked effects on symptomatic BRN, significantly reducing the area of BRN and maintaining the nonrecurrent status. Additional large-scale, double-blinded, controlled trials are necessary to confirm the clinical effect of this therapeutic regimen on BRN.

Ethical approval and consent to participate

This study was approved by the Institutional Ethics Review Board of the Affiliated Hospital of Zunyi Medical University. The patient agreed to participate in this study and submitted written informed consent, including publication of the case details, at the the Affiliated Hospital of Zunyi Medical University.

Acknowledgments

This work was supported by the National Natural Science Foundation of China (grant number: 81760548), the International Cooperation Project of Science and Technology Foundation of Guizhou Province (Qian Ke He Wai G [2014] 7015) and the Master's Initial Fund of Zunyi Medical College 2011(09). The authors thank Na Tan from the Pathology department and Junli Shi from the Medical Imaging Department of the Affiliated Hospital of Zunyi Medical College for providing the photographic materials related to this patient.

Disclosure

The authors report no conflicts of interest in this work.

References

- Buonomo OC, Caredda E, Portarena I, et al. New insights into the metastatic behavior after breast cancer surgery, according to well-established clinicopathological variables and molecular subtypes. *PLoS One*. 2017;12(9):e0184680. doi:10.1371/journal.pone.0184680
- Fulford LG, Easton DF, Reis-Filho JS, et al. Specific morphological features predictive for the basal phenotype in grade 3 invasive ductal carcinoma of breast. *Histopathology*. 2006;49(1):22–34. doi:10.1111/j.1365-2559.2006.02453.x
- Rostami R, Mittal S, Rostami P, Tavassoli F, Jabbari B. Brain metastasis in breast cancer: a comprehensive literature review. *J Neurooncol*. 2016;127(3):407–414. doi:10.1007/s11060-016-2075-3
- Soliman H, Das S, Larson DA, Sahgal A. Stereotactic radiosurgery (SRS) in the modern management of patients with brain metastases. *Oncotarget*. 2016;7(11):12318–12330. doi:10.18632/oncotarget.7131
- Kondziolka D, Shin SM, Brunswick A, Kim I, Silverman JS. The biology of radiosurgery and its clinical applications for brain tumors. *Neuro Oncol*. 2015;17(1):29–44. doi:10.1093/neuonc/nou284
- Halasz LM, Uno H, Hughes M, et al. Comparative effectiveness of stereotactic radiosurgery versus whole-brain radiation therapy for patients with brain metastases from breast or non-small cell lung cancer. *Cancer*. 2016;122(13):2091–2100. doi:10.1002/cncr.30009
- Rades D, Veninga T, Hornung D, Wittkugel O, Schild SE, Gliemroth J. Single brain metastasis: whole-brain irradiation plus either radiosurgery or neurosurgical resection. *Cancer*. 2012;118(4):1138–1144. doi:10.1002/cncr.26379
- Connor M, Karunamuni R, McDonald C, et al. Regional susceptibility to dose-dependent white matter damage after brain radiotherapy. *Radiother Oncol*. 2017;123(2):209–217. doi:10.1016/j.radonc.2017.04.006
- Connor M, Karunamuni R, McDonald C, et al. Dose-dependent white matter damage after brain radiotherapy. *Radiother Oncol*. 2016;121(2):209–216. doi:10.1016/j.radonc.2016.10.003
- Stokes TB, Niranjana A, Kano H, et al. White matter changes in breast cancer brain metastases patients who undergo radiosurgery alone compared to whole brain radiation therapy plus radiosurgery. *J Neurooncol*. 2015;121(3):583–590. doi:10.1007/s11060-014-1670-4
- Schultheiss TE, Kun LE, Ang KK, Stephens LC. Radiation response of the central nervous system. *Int J Radiat Oncol Biol Phys*. 1995;31(5):1093–1112. doi:10.1016/0360-3016(94)00655-5
- Ou S, Klempner S, Azada M, Rauser-Mills V, Duma C. Radiation necrosis presenting as pseudoprogression (PSP) during alectinib treatment of previously radiated brain metastases in ALK-positive NSCLC: implications for disease assessment and management. *Lung Cancer*. 2015;88(3):355–359. doi:10.1016/j.lungcan.2015.03.022
- Nonoguchi N, Miyatake S, Fukumoto M, et al. The distribution of vascular endothelial growth factor-producing cells in clinical radiation necrosis of the brain: pathological consideration of their potential roles. *J Neurooncol*. 2011;105(2):423–431. doi:10.1007/s11060-011-0610-9
- Perez-Torres CJ, Yuan L, Schmidt RE, et al. Specificity of vascular endothelial growth factor treatment for radiation necrosis. *Radiother Oncol*. 2015;117(2):382–385. doi:10.1016/j.radonc.2015.09.004
- Miyatake S, Furuse M, Kawabata S, et al. Bevacizumab treatment of symptomatic pseudoprogression after boron neutron capture therapy for recurrent malignant gliomas. Report of 2 cases. *Neuro Oncol*. 2013;15(6):650–655. doi:10.1093/neuonc/not020
- Lin NU, Claus E, Soh J, Razzak AR, Arnaout A, Winer EP. Sites of distant recurrence and clinical outcomes in patients with metastatic triple-negative breast cancer: high incidence of central nervous system metastases. *Cancer*. 2008;113(10):2638–2645. doi:10.1002/cncr.23930
- Niikura N, Hayashi N, Masuda N, et al. Treatment outcomes and prognostic factors for patients with brain metastases from breast cancer of each subtype: a multicenter retrospective analysis. *Breast Cancer Res Treat*. 2014;147(1):103–112. doi:10.1007/s10549-014-3090-8
- Iuchi T, Hatano K, Narita Y, Kodama T, Yamaki T, Osato K. Hypofractionated high-dose irradiation for the treatment of malignant astrocytomas using simultaneous integrated boost technique by IMRT. *Int J Radiat Oncol Biol Phys*. 2006;64(5):1317–1324. doi:10.1016/j.ijrobp.2005.12.005
- Mizumoto M, Tsuboi K, Igaki H, et al. Phase I/II trial of hyperfractionated concomitant boost proton radiotherapy for supratentorial glioblastoma multiforme. *Int J Radiat Oncol Biol Phys*. 2010;77(1):98–105. doi:10.1016/j.ijrobp.2009.04.054
- Ohguri T, Imada H, Kohshi K, et al. Effect of prophylactic hyperbaric oxygen treatment for radiation-induced brain injury after stereotactic radiosurgery of brain metastases. *Int J Radiat Oncol Biol Phys*. 2007;67(1):248–255. doi:10.1016/j.ijrobp.2006.08.009
- Valadão J, Pearl J, Verma S, Helms A, Whelan H. Hyperbaric oxygen treatment for post-radiation central nervous system injury: a retrospective case series. *Undersea Hyperb Med*. 2014;41(2):87–96.
- Kohshi K, Imada H, Nomoto S, Yamaguchi R, Abe H, Yamamoto H. Successful treatment of radiation-induced brain necrosis by hyperbaric oxygen therapy. *J Neurol Sci*. 2003;209(1–2):115–117.
- Pasquier D, Hoelscher T, Schmutz J, et al. Hyperbaric oxygen therapy in the treatment of radio-induced lesions in normal tissues: a literature review. *Radiother Oncol*. 2004;72(1):1–13. doi:10.1016/j.radonc.2004.04.005
- Furuse M, Nonoguchi N, Kawabata S, Miyatake S, Kuroiwa T. Delayed brain radiation necrosis: pathological review and new molecular targets for treatment. *Med Mol Morphol*. 2015;48(4):183–190. doi:10.1007/s00795-015-0123-2
- Nordal RA, Nagy A, Pintilie M, Wong CS. Hypoxia and hypoxia-inducible factor-1 target genes in central nervous system radiation injury: a role for vascular endothelial growth factor. *Clin Cancer Res*. 2004;10(10):3342–3353. doi:10.1158/1078-0432.CCR-03-0426
- Rahmathulla G, Marko N, Weil R. Cerebral radiation necrosis: a review of the pathobiology, diagnosis and management considerations. *J Clin Neurosci*. 2013;20(4):485–502. doi:10.1016/j.jocn.2012.09.011
- Zhuang H, Yuan X, Zheng Y, et al. A study on the evaluation method and recent clinical efficacy of bevacizumab on the treatment of radiation cerebral necrosis. *Sci Rep*. 2016;6:24364. doi:10.1038/srep24364
- Boothe D, Young R, Yamada Y, Prager A, Chan T, Beal K. Bevacizumab as a treatment for radiation necrosis of brain metastases post stereotactic radiosurgery. *Neuro Oncol*. 2013;15(9):1257–1263. doi:10.1093/neuonc/not085
- Ma Y, Zheng C, Feng Y, Xu Q. Bevacizumab for the treatment of gammaknife radiosurgery-induced brain radiation necrosis. *J Craniofac Surg*. 2017;28(6):e569–e571. doi:10.1097/SCS.00000-00000003874
- Zhuang H, Yuan X, Sun D, et al. Acquired-resistance of bevacizumab treatment for radiation brain necrosis: a case report. *Oncotarget*. 2016;7(11):13265–13268. doi:10.18632/oncotarget.7724
- Zhuang H, Yuan X, Chang JY, et al. Exploration of the recurrence in radiation brain necrosis after bevacizumab discontinuation. *Oncotarget*. 2016;7(30):48842–48849. doi:10.18632/oncotarget.7768
- Mohajeri A, Sanaei S, Kiafar F, Fattahi A, Khalili M, Zarghami N. The challenges of recombinant endostatin in clinical application: focus on the different expression systems and molecular bioengineering. *Adv Pharm Bull*. 2017;7(1):21–34. doi:10.15171/apb.2017.004

33. Xu X, Mao W, Chen Q, et al. Endostar, a modified recombinant human endostatin, suppresses angiogenesis through inhibition of Wnt/beta-catenin signaling pathway. *PLoS One*. 2014;9(9):e107463. doi:10.1371/journal.pone.0107463
34. Ma X, Yao Y, Yuan D, et al. Recombinant human endostatin endostar suppresses angiogenesis and lymphangiogenesis of malignant pleural effusion in mice. *PLoS One*. 2012;7(12):e53449. doi:10.1371/journal.pone.0053449
35. Xu X, Mao W, Chai Y, et al. Angiogenesis inhibitor, Endostar, prevents vasa vasorum neovascularization in a swine atherosclerosis model. *J Atheroscler Thromb*. 2015;22(10):1100–1112. doi:10.5551/jat.26906
36. Liu J, Ye P, Su Z, Lin K, He F, Xu W. Suppression of choroidal neovascularization by Endostar in rats. *Mol Med Rep*. 2015;11(5):3621–3625. doi:10.3892/mmr.2014.3132
37. Ge J-J, Li C, Zhang J-P. Long-term remission of recurrent brainstem pilocytic astrocytoma with neuraxis dissemination using recombinant human endostatin after failure of vincristine and carboplatin. *World Neurosurg*. 2018;110:397–402. doi:10.1016/j.wneu.2017.11.150
38. Jiang X, Ding M, Qiao Y, Liu Y, Liu L. Recombinant human endostatin combined with radiotherapy in the treatment of brain metastases of non-small cell lung cancer. *Clin Transl Oncol*. 2014;16(7):630–636. doi:10.1007/s12094-013-1129-7
39. Jiang X-D, Qiao Y. Updating advances on recombinant human endostatin combined with radiotherapy for non-small cell lung cancer with brain metastasis. *Transl Lung Cancer Res*. 2012;1(1):84–88. doi:10.3978/j.issn.2218-6751.2011.12.06
40. Kirsch M, Weigel P, Pinzer T, et al. Therapy of hematogenous melanoma brain metastases with endostatin. *Clin Cancer Res*. 2005;11(3):1259–1267.
41. Lin H, Luo S, Li L, et al. Efficacy and safety of antitumor agents plus radiotherapy compared with radiotherapy alone for brain metastases from lung cancer. *Mol Clin Oncol*. 2017;6(3):296–306. doi:10.3892/mco.2017.1152

OncoTargets and Therapy

Dovepress

Publish your work in this journal

OncoTargets and Therapy is an international, peer-reviewed, open access journal focusing on the pathological basis of all cancers, potential targets for therapy and treatment protocols employed to improve the management of cancer patients. The journal also focuses on the impact of management programs and new therapeutic

agents and protocols on patient perspectives such as quality of life, adherence and satisfaction. The manuscript management system is completely online and includes a very quick and fair peer-review system, which is all easy to use. Visit <http://www.dovepress.com/testimonials.php> to read real quotes from published authors.

Submit your manuscript here: <https://www.dovepress.com/oncotargets-and-therapy-journal>