

[CASE REPORT]

Pulmonary *Scedosporium apiospermum* Infection with Pulmonary Tumorlet in an Immunocompetent Patient

Nana Motokawa^{1,2}, Taiga Miyazaki^{1,3}, Atsuko Hara¹, Yuichi Fukuda¹, Shigeyuki Morino⁴, Hiroaki Nakamura⁴, Keisuke Iwasaki⁵, Hiroshi Soda¹, Koichi Izumikawa³, Katsunori Yanagihara⁶, Hideaki Ohno⁷, Yoshitsugu Miyazaki⁷, Shigeru Kohno² and Hiroshi Mukae²

Abstract:

Scedosporium apiospermum is an opportunistic fungus that can cause various types of infections, including localized infections and life-threatening disseminated infections, particularly in immunocompromised patients. Treatment is especially challenging due to its multidrug resistance. We herein report the case of a 73-year-old woman who was non-immunocompromised but developed *S. apiospermum* lung infection and a pulmonary tumorlet. To our knowledge, this is the first report of the coexistence of pulmonary *S. apiospermum* infection and tumorlet. The lung lesion was successfully treated by surgical excision without any antifungal agents, and no recurrence of the tumorlet or *S. apiospermum* infection has occurred.

Key words: *Scedosporium apiospermum*, *Pseudallescheria boydii*, pulmonary tumorlet, fungus ball

(Intern Med 57: 3485-3490, 2018)

(DOI: 10.2169/internalmedicine.1239-18)

Introduction

Scedosporium apiospermum species complex are saprophytic fungi widespread in soil and polluted water sources. *S. apiospermum* was previously reported as an anamorph form of *Pseudallescheria boydii* but has recently been defined as a distinct species (1, 2). *S. apiospermum* is an opportunistic fungus causing life-threatening infections in immunocompromised patients (3-5). Chronic pulmonary infections develop mainly in patients with underlying lung disorders, such as tuberculosis, sarcoidosis and cystic fibrosis (6-8). Similar to chronic pulmonary aspergillosis, lung involvement due to *S. apiospermum* falls into several categories: transient local colonization, bronchopulmonary saprobic involvement, fungus ball formation (scedosporioma), and in-

vasive infection (pneumonia) (3). However, due to the absence of a standard diagnostic assay for *S. apiospermum* infection, its incidence rate and clinical significance are likely to be underestimated (6, 7).

A pulmonary tumorlet is a nodular proliferation of neuroendocrine cells that is <5 mm in diameter. It is associated with underlying lung disorders, such as chronic bronchitis and other inflammatory diseases, and has rarely been reported with normal lungs (9, 10). To our knowledge, the co-occurrence of pulmonary tumorlet and pulmonary scedosporioma has never been reported, although there have been a few papers reporting the simultaneous existence of a tumorlet with pulmonary tuberculosis or pulmonary aspergillosis (11, 12). We herein report the first case of scedosporioma with pulmonary tumorlet in an immunocompetent host.

¹Division of Respiratory Medicine, Sasebo City General Hospital, Japan, ²Department of Respiratory Medicine, Nagasaki University Graduate School of Biomedical Sciences, Japan, ³Department of Infectious Diseases, Nagasaki University Graduate School of Biomedical Sciences, Japan, ⁴Division of Thoracic Surgery, Sasebo City General Hospital, Japan, ⁵Division of Pathology, Sasebo City General Hospital, Japan, ⁶Department of Laboratory Medicine, Nagasaki University Graduate School of Biomedical Sciences, Japan and ⁷Department of Chemotherapy and Mycoses, National Institute of Infectious Diseases, Japan

Received: March 25, 2018; Accepted: April 22, 2018; Advance Publication by J-STAGE: August 10, 2018

Correspondence to Dr. Taiga Miyazaki, taiga-m@nagasaki-u.ac.jp

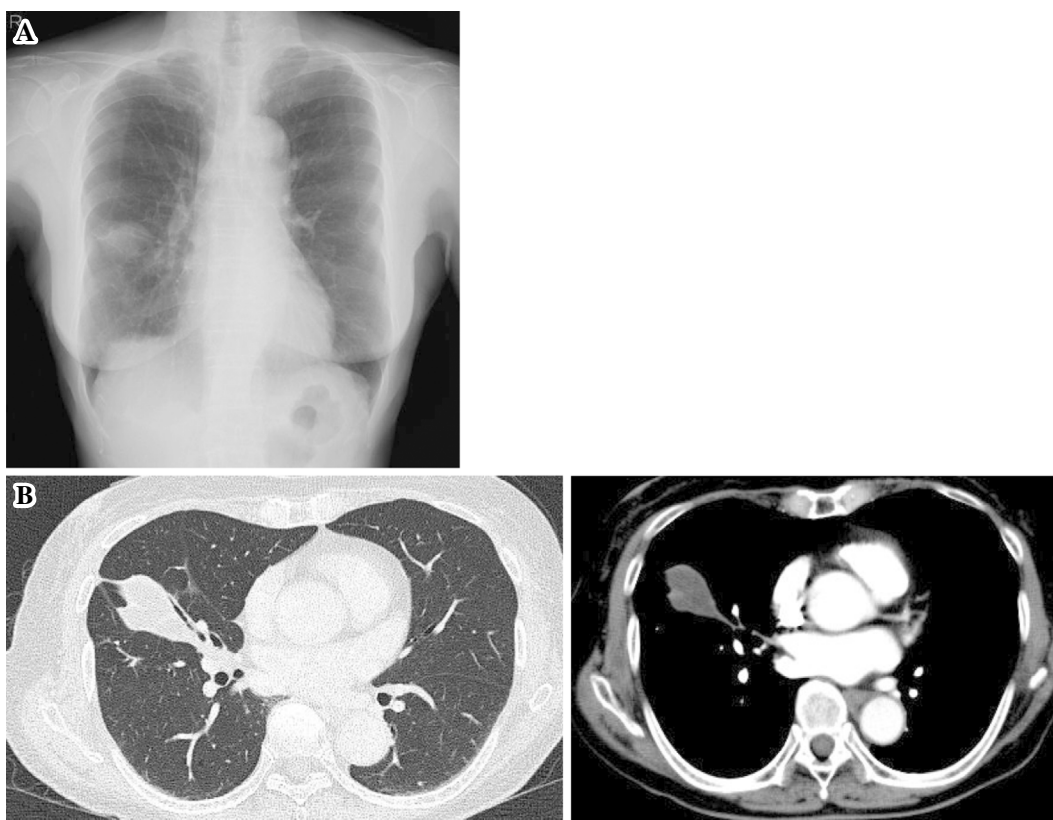

Figure 1. Chest X-ray (A) and contrast-enhanced computed tomography (B) on admission.

Case Report

A 73-year-old Japanese woman visited our hospital for the further evaluation of abnormal chest imaging findings noted at a medical checkup. She had previously worked in the publishing industry where she had undergone regular medical checkups, but no chest X-rays had been taken for decades. She had no pulmonary symptoms and no history of a fever, anorexia or loss of weight. She had never smoked.

A physical examination and vital signs were unremarkable except for hypertension. Her hematological and biochemical examinations were within normal limits. The *Aspergillus* galactomannan (GM) antigen value was 0.2 (Plateletia *Aspergillus* ELISA; Bio-Rad Laboratories, Marnes-la-Coquette, France), and the 1,3-beta-D-glucan value was <11 pg/nL (B-D-glucan Test Wako, Wako Pure Chemical, Osaka, Japan). Elevated values of serum ProGRP (93.6 pg/mL) and CYFRA (3.9 mg/dL) were observed, while CEA (1.9 ng/mL) and SCC (0.6 ng/mL) were within normal limits. Chest X-ray showed a mass in the right middle lung field (Fig. 1A) and contrast-enhanced computed tomography showed a solitary mass lesion (40×35×21 mm) that was heterogeneously rim-enhanced with small cystic bronchiectasis in the right middle lobe (Fig. 1B).

A sputum smear examination by Gram staining and acid-fast bacillus (AFB) testing and sputum culture were negative. Bronchoscopy was performed, and a histopathological examination of transbronchial lung biopsy (TBLB) speci-

mens showed an atypical epithelium lesion stained for TTF-1 and slightly stained for cytokeratin with hyphal elements in fibrous stroma. AFB and Gram staining of the bronchoalveolar lavage fluid (BALF) were negative. Culture of the BALF and TBLB specimens revealed colonies with a white cottony texture grown on potato dextrose agar after incubation at 30°C for 20 days (Fig. 2A). It did not show typical characteristics of a *Scedosporium* spp. colony, which showed a white to grayish front surface and with a brownish back surface due to a lack of pigments and the production of brown conidia (3). The microscopic appearance of the mycelia was a single conidia borne on a short conidiophore attached to the mycelium, which was a typical feature of *Scedosporium* spp. (Fig. 2B). Finally, the isolate was identified as *S. apiospermum*/*P. boydii* complex by sequencing the internal transcribed spacer region and the D1/D2 region of the ribosomal DNA gene, as described previously (13). The antifungal susceptibilities of the isolated *S. apiospermum* were assessed using the broth microdilution method according to the Clinical and Laboratory Standard Institute (CLSI) M38, third edition (14). The data are shown in Table.

Right middle lobectomy was carried out to remove the lesion at which cancer and a fungus ball were suspected. An examination of an apical segment revealed a cavity filled with fungus ball-like tissue (Fig. 3A). Furthermore, marked increases in collagenous tissues were noted on the surface of the fungus ball (Fig. 3B). The fungus ball was composed of conidia and hyphal elements of *S. apiospermum* (Fig. 3C). In addition, the small nodule near the fungus ball was com-

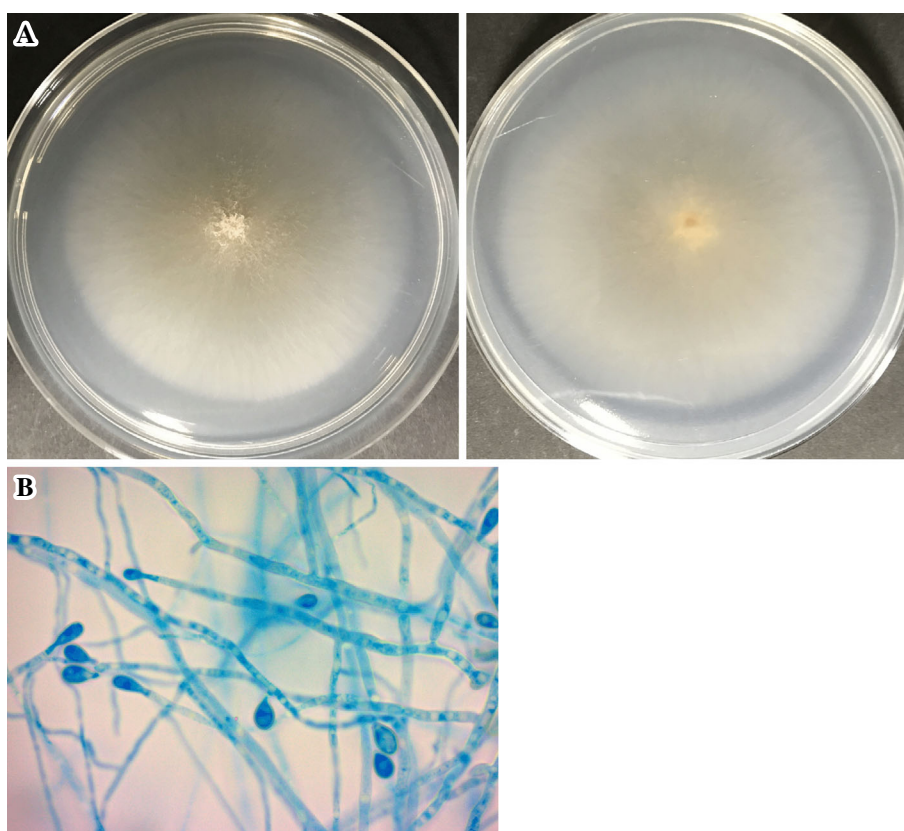


Figure 2. (A) Colony appearance of *Scedosporium apiospermum* on a PDA plate. After incubation at 30°C for 20 days, the front surface (left panel) and back surface (right panel) of the plate were photographed. (B) A microscopic examination of the slide culture stained with lactophenol cotton blue. Branching septated hyphae and single oval sessile conidia at the top of conidiophores ($\times 1,000$).

Table. Comparison of Antifungal Susceptibility of *Scedosporium Apiospermum* and *Aspergillus Fumigatus*.

	MIC ($\mu\text{g/mL}$)*				Reference
	AMB	MCFG	ITC	VRC	
<i>A. fumigatus</i> (ATCC 204305)	0.5-2	<0.007	0.25-1	0.25-1	23, 24
<i>S. apiospermum</i>	>16	0.12	>8	>8	23, 25
<i>S. apiospermum</i> complex isolate in the present case	>16	0.25	1	0.25	this study

*Micafungin susceptibility was determined by minimum effective concentration.

AMB: amphotericin B, MCFG: micafungin, ITC: itraconazole, VRC: voriconazole

posed of a uniform rosette population of cells with oval or spindle nuclei (Fig. 4A). The small tumor was stained strongly for neuroendocrine markers, including Chromogranin A, Synaptophysin and CD 56 (Fig. 4B, C and D), and was therefore diagnosed as a carcinoid tumorlet. On a histopathological examination, a fungus ball was found in the cystic bronchiectasis, and its surrounding bronchial mucosa remained largely intact. No metastasis was found in the mediastinal lymph nodes.

We diagnosed the patient with pulmonary *S. apiospermum* infection (fungus ball) and the coexistence of a tumorlet. No antifungal agent was administered before or after surgery. The tumor marker values returned to normal after the opera-

tion. No recurrence of the tumorlet or *S. apiospermum* infection has occurred in the five years since surgical resection.

Discussion

The lung and upper respiratory tract are the most commonly encountered sites of non-opportunistic involvement by *S. apiospermum*. The imaging of pulmonary *S. apiospermum* infection and histological examination findings are nonspecific and closely resemble the manifestations of more common *Aspergillus* species infections. However, the antifungal susceptibilities of *Aspergillus* spp. and *S. apiosper-*

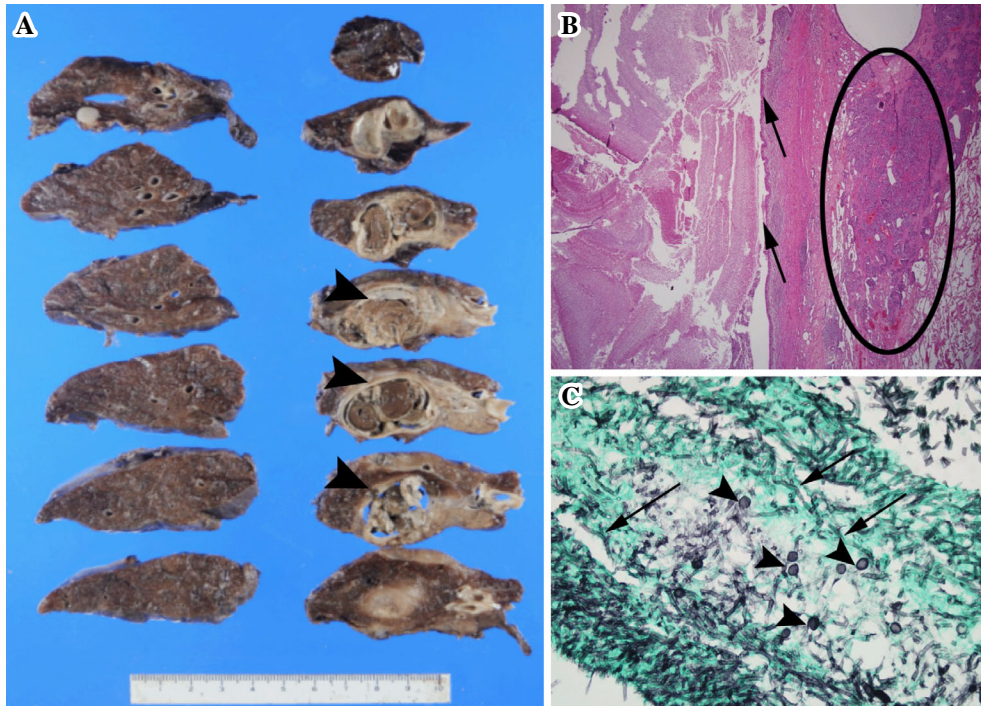


Figure 3. (A) Gross pathology of the right middle lobe. The arrowheads indicate fungus ball-like tissue filling cystic bronchiectasis. (B) The fungus ball was composed of hyphal elements on the left side of the arrows. The arrows indicate bronchial epithelium. No fungal invasion exceeded the bronchial walls. The tumorlet nests are on the right side of the bronchial epithelium (circle), (Hematoxylin and Eosin staining, $\times 25$). (C) Branching and septate hyphae (arrows) and conidia (arrowheads), (Gomori's methenamic silver, $\times 400$).

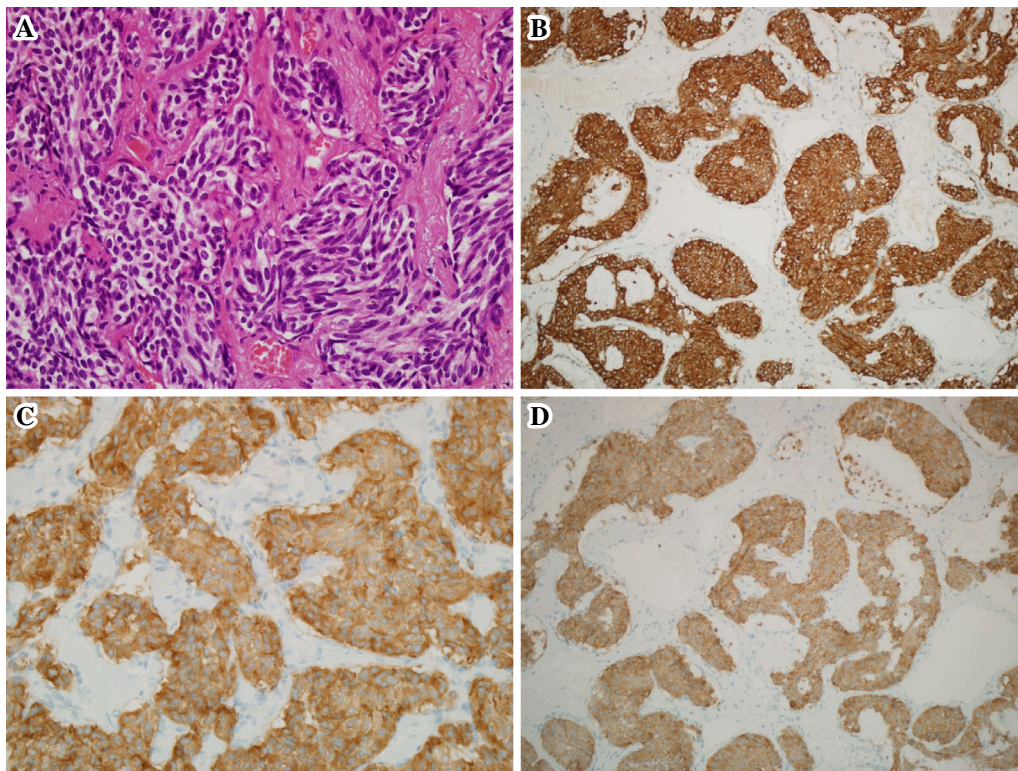


Figure 4. The nodule consists of a uniform population of cells with oval or spindle nuclei. Rosette formation is evident (A, Hematoxylin and Eosin staining, $\times 200$). Strongly positive immunostaining for Chromogranin A (B, $\times 100$), Synaptophysin (C, $\times 200$) and CD 56 (D, $\times 100$) was observed in the carcinoid tumorlet.

mum are different (15, 16). As observed for the isolate in this case, *S. apiospermum* is highly resistant to amphotericin B and less susceptible to echinocandins than most *Aspergillus* spp. including *A. fumigatus* (Table), suggesting the epidemiological and clinical importance of these species' identification.

Although voriconazole is recommended as the first-line treatment (17, 18), the appropriate treatment for *S. apiospermum* infection is unknown, and the mortality is very high despite antifungal treatment. In our case, treatment with voriconazole may have been a therapeutic option based on the susceptibility results of the isolate, but because of the possibility of malignancy, the patient underwent surgical resection. The elevated ProGRP value returned to normal after the operation. Although immunostaining for ProGRP was not performed in this case, the elevated level of ProGRP was likely derived from the tumorlet, in agreement with the findings of a previous report (19). To our knowledge, there have been no reports describing the relationship between *S. apiospermum* infection and tumor markers, including ProGRP.

The etiopathogenic relationship between tumorlet and *S. apiospermum* infection is difficult to define. Pulmonary tumorlets often develop in the context of bronchiectasis, fibrosis and chronic inflammation of the lung tissues that can be caused by chronic mold infections. However, the tumorlet itself also causes pulmonary fibrosis and chronic lung tissue scarring by producing fibrosis-inducing factors, such as vascular endothelial growth factor and bombesin (20-22). This secondary induced lung tissue injury may also predispose the lung to the development of subsequent mold infections. In our pathological examination, the tumorlet and *S. apiospermum* infection lesions were located closely but separately; however, we were unable to differentiate the tumorlet lesion on chest X-ray/computed tomography before surgery. The limitation of this case report is that we were unable to assess the time course of the development of both diseases.

Similar to pulmonary aspergillosis, *S. apiospermum* infection develops as a localized lesion in patients who are not severely immunocompromised. In addition, *S. apiospermum* infection is often refractory to treatment with antifungal agents alone due at least in part to its intrinsically reduced susceptibility to multi-antifungals; therefore, if feasible, surgical resection may be an effective therapeutic option, as shown in the present case. However, the need for adjunctive antifungal therapy should be considered on a case-by-case basis.

The authors state that they have no Conflict of Interest (COI).

References

- Gilgado F, Cano J, Gene J, Sutton DA, Guarro J. Molecular and phenotypic data supporting distinct species statuses for *Scedosporium apiospermum* and *Pseudallescheria boydii* and the proposed new species *Scedosporium dehoogii*. *J Clin Microbiol* **46**: 766-771, 2008.
- Ishii S, Hiruma M, Hayakawa Y, et al. Cutaneous *Pseudallescheria boydii/Scedosporium apiospermum* complex (Molecular type: *Scedosporium apiospermum* [Clade 4]) infection: a case report and literature review of cases from Japan. *Med Mycol J* **56**: E25-E30, 2015.
- Cortez KJ, Roilides E, Quiroz-Telles F, et al. Infections caused by *Scedosporium* spp. *Clin Microbiol Rev* **21**: 157-197, 2008.
- Guarro J, Kantarcioglu AS, Horre R, et al. *Scedosporium apiospermum*: changing clinical spectrum of a therapy-refractory opportunist. *Med Mycol* **44**: 295-327, 2006.
- Toth EJ, Nagy GR, Homa M, et al. Recurrent *Scedosporium apiospermum* mycetoma successfully treated by surgical excision and terbinafine treatment: a case report and review of the literature. *Ann Clin Microbiol Antimicrob* **16**: 31, 2017.
- Pihet M, Carrere J, Cimon B, et al. Occurrence and relevance of filamentous fungi in respiratory secretions of patients with cystic fibrosis—a review. *Med Mycol* **47**: 387-397, 2009.
- Sedlacek L, Graf B, Schwarz C, et al. Prevalence of *Scedosporium* species and *Lomentospora prolificans* in patients with cystic fibrosis in a multicenter trial by use of a selective medium. *J Cyst Fibros* **14**: 237-241, 2015.
- Noni M, Katelari A, Dimopoulos G, Alexandrou H, Kaditis A, Doudounakis S. *Scedosporium apiospermum* complex in cystic fibrosis; should we treat? *Mycoses* **60**: 594-599, 2017.
- Churg A, Warnock ML. Pulmonary tumorlet: a form of peripheral carcinoid. *Cancer* **37**: 1469-1477, 1976.
- Aubry MC, Thomas CF Jr, Jett JR, Swensen SJ, Myers JL. Significance of multiple carcinoid tumors and tumorlets in surgical lung specimens: analysis of 28 patients. *Chest* **131**: 1635-1643, 2007.
- Dixit R, Gupta R, Yadav A, Paramez AR, Sen G, Sharma S. A case of pulmonary carcinoid tumor with concomitant tuberculosis. *Lung India* **26**: 133-135, 2009.
- Kim KJ, Yu JH, Kim NH, Kim YH, Kim YS, Seo JA. A case of pulmonary carcinoid tumor with a superimposed aspergilloma presenting as a covert ectopic adrenocorticotropic hormone syndrome. *Front Endocrinol (Lausanne)* **8**: 123, 2017.
- Kimura M, Araoka H, Uchida N, et al. *Cunninghamella bertholletiae* pneumonia showing a reversed halo sign on chest computed tomography scan following cord blood transplantation. *Med Mycol* **50**: 412-416, 2012.
- Clinical and Laboratory Standards Institute. Reference method for broth dilution antifungal susceptibility testing of filamentous fungi. In: CLSI standard M38. 3rd ed. Clinical and Laboratory Standards Institute, Wayne, PA, USA, 2017.
- Lass-Flori C, Mayr A, Perkhofor S, et al. Activities of antifungal agents against yeasts and filamentous fungi: assessment according to the methodology of the European Committee on Antimicrobial Susceptibility Testing. *Antimicrob Agents Chemother* **52**: 3637-3641, 2008.
- Cuenca-Estrella M, Gomez-Lopez A, Mellado E, Buitrago MJ, Monzon A, Rodriguez-Tudela JL. Head-to-head comparison of the activities of currently available antifungal agents against 3,378 Spanish clinical isolates of yeasts and filamentous fungi. *Antimicrob Agents Chemother* **50**: 917-921, 2006.
- Lackner M, de Hoog GS, Verweij PE, et al. Species-specific antifungal susceptibility patterns of *Scedosporium* and *Pseudallescheria* species. *Antimicrob Agents Chemother* **56**: 2635-2642, 2012.
- Lackner M, Hagen F, Meis JF, et al. Susceptibility and diversity in the therapy-refractory genus *scedosporium*. *Antimicrob Agents Chemother* **58**: 5877-5885, 2014.
- Masuko H, Satoh H, Miyazaki K, et al. Pulmonary sequestration with elevated serum level of progastrin-releasing peptide. *Intern Med* **47**: 157-160, 2008.
- Aguayo SM, Miller YE, Waldron JA Jr, et al. Brief report: idi-

- opathic diffuse hyperplasia of pulmonary neuroendocrine cells and airways disease. *N Engl J Med* **327**: 1285-1288, 1992.
21. He P, Gu X, Wu Q, Lin Y, Gu Y, He J. Pulmonary carcinoid tumorlet without underlying lung disease: analysis of its relationship to fibrosis. *J Thorac Dis* **4**: 655-658, 2012.
22. Sartelet H, Decaussin M, Devouassoux G, et al. Expression of vascular endothelial growth factor (VEGF) and its receptors (VEGF-R 1 [Flt-1] and VEGF-R2 [KDR/Flk-1]) in tumorlets and in neuroendocrine cell hyperplasia of the lung. *Hum Pathol* **35**: 1210-1217, 2004.
23. Cuenca-Estrella M, Gomez-Lopez A, Mellado E, Garcia-Effron G, Monzon A, Rodriguez-Tudela JL. *In vitro* activity of ravuconazole against 923 clinical isolates of nondermatophyte filamentous fungi. *Antimicrob Agents Chemother* **49**: 5136-5138, 2005.
24. van de Sande WW, Fahal AH, Bakker-Woudenberg IA, van Belkum A. *Madurella mycetomatis* is not susceptible to the echinocandin class of antifungal agents. *Antimicrob Agents Chemother* **54**: 2738-2740, 2010.
25. Cuenca-Estrella M, Alastruey-Izquierdo A, Alcazar-Fuoli L, et al. *In vitro* activities of 35 double combinations of antifungal agents against *Scedosporium apiospermum* and *Scedosporium prolificans*. *Antimicrob Agents Chemother* **52**: 1136-1139, 2008.

The Internal Medicine is an Open Access journal distributed under the Creative Commons Attribution-NonCommercial-NoDerivatives 4.0 International License. To view the details of this license, please visit (<https://creativecommons.org/licenses/by-nc-nd/4.0/>).