




Contents lists available at ScienceDirect

Clinical and Translational Radiation Oncology

journal homepage: www.elsevier.com/locate/ctro

Case Report

Uptake of Prostate-Specific Membrane Antigen (PSMA) in adenoid cystic carcinoma – Is PSMA-PET-CT a helpful tool in radiation oncology?



Laila König^{a,b,*}, Henrik Hauswald^{a,b}, Christa Flechtenmacher^c, Martina Heller^d, Jürgen Debus^{a,b}, Uwe Haberkorn^e, Clemens Kratochwil^e, Frederik Giesel^e

^a Department of Radiation Oncology, Heidelberg University Hospital, INF 400, 69120 Heidelberg, Germany

^b Heidelberg Institute for Radiation Oncology (HIRO), Heidelberg, Germany

^c Institute of Pathology, Heidelberg University Hospital, INF 224, 69120 Heidelberg, Germany

^d Section of Molecular Urooncology, Department of Urology, Heidelberg University Hospital, INF 517, 69120 Heidelberg, Germany

^e Department of Nuclear Medicine, Heidelberg University Hospital, INF 400, 69120 Heidelberg, Germany

ARTICLE INFO

Article history:

Received 21 July 2017

Revised 2 October 2017

Accepted 7 October 2017

Available online 14 November 2017

ABSTRACT

This case report shows the high PSMA-uptake in a patient with an adenoid cystic carcinoma of the maxillary sinus. Due to the intense ligand-uptake additional information for target volume delineation was obtained and the Treatment plan for bimodal radiotherapy with carbon ions was adapted accordingly.

© 2017 The Authors. Published by Elsevier Ireland Ltd on behalf of European Society for Radiotherapy and Oncology. This is an open access article under the CC BY-NC-ND license (<http://creativecommons.org/licenses/by-nc-nd/4.0/>).

Background

Adenoid cystic carcinoma (ACC) is a rare tumor entity with a yearly incidence of 3–5 cases per million [1]. Nevertheless, ACCs account for 1% of all head and neck malignancies and 10% of all salivary gland tumors [2,3]. Histopathologically, ACC display a cribriform arrangement of tumor cells and invasion of surrounding tissue. One of the main characteristics is an invasive growth pattern with spread along nerves in this relentlessly growing tumor [4], which is an unfavorable prognostic factor, associated with distant metastases and an adverse outcome. The clinical course is characterized by slow tumor growth and often results in local recurrences, even after long intervals from previous radical treatment [5].

Due to this rather indolent behavior, with frequent local relapses, treatment of choice is radical surgical resection followed

by postoperative radiotherapy [6]. Chemotherapy only plays an inferior role in treatment of ACC and is recommended as a palliative treatment option in patients with progressive, symptomatic disease, mainly in more aggressive subtypes [7].

Furthermore, ACC belongs to a group of rather radioresistant tumors. Due to the infiltrative growth along the neural tracts in the skull base, applying high doses of radiotherapy remains challenging in view of close proximity to critical structures (e.g. optical nerve, brainstem). Therefore, in the last two decades, bimodal radiotherapy with particle therapy and photon irradiation has been used in our institution in patients with ACC. Carbon ions in particular offer several favorable features: due to the Bragg peak, they show a sharp increase of dose in depth followed by a rapid dose fall-off beyond this maximum, which allows to apply high doses in close proximity of organs at risk [8,9].

With the addition of a carbon ion boost, bimodal radiotherapy resulted in superior local control, progression free survival and overall survival compared to photon radiotherapy alone [10,11]. Furthermore, there was no difference between patients who had been subtotally resected or treated with definitive radiotherapy due to inoperability [10].

PSMA (Prostate-specific membrane antigen) is a cell surface protein with transmembrane location and a large extracellular domain. Owing to the enzymatic activity, PSMA allows for development of specific inhibitors and their internalization after ligand binding [12]. As described recently, ⁶⁸Ga-labelled PSMA-ligands have been developed to detect relapses and metastases of prostate carcinoma [13,14]. PSMA is highly expressed in prostate carcinoma cells, but

Abbreviations: ACC, Adenoid cystic carcinoma; CTCAE, Common terminology criteria of adverse events; IMRT, intensity modulated radiotherapy; HIT, Heidelberg Ion Beam Therapy Center; IHC, Immunohistochemistry; PET-CT, Positron emission tomography-computed tomography; PSMA, Prostate-Specific Membrane Antigen; RBE, Relative Biological Effectiveness; RECIST, Response Evaluation Criteria In Solid Tumors; RT, radiotherapy.

* Corresponding author at: Department of Radiation Oncology, Heidelberg University Hospital, INF 400, 69120 Heidelberg, Germany.

E-mail addresses: laila.koenig@med.uni-heidelberg.de (L. König), henrik.hauswald@med.uni-heidelberg.de (H. Hauswald), christa.flechtenmacher@med.uni-heidelberg.de (C. Flechtenmacher), martina.heller@me.com (M. Heller), juergen.debus@med.uni-heidelberg.de (J. Debus), uwe.haberkorn@med.uni-heidelberg.de (U. Haberkorn), clemens.kratochwil@med.uni-heidelberg.de (C. Kratochwil), frederik.giesel@med.uni-heidelberg.de (F. Giesel).

<https://doi.org/10.1016/j.ctro.2017.10.003>

2405-6308/© 2017 The Authors. Published by Elsevier Ireland Ltd on behalf of European Society for Radiotherapy and Oncology.

This is an open access article under the CC BY-NC-ND license (<http://creativecommons.org/licenses/by-nc-nd/4.0/>).

also non-malignant tissues like kidney tubules or salivary glands [15], resulting in an additional intense tracer uptake in these organs in PET (positron emission tomography)-imaging [13]. Additionally, recent observations revealed that PSMA-expression is found in the neo-vasculature of non-prostatic solid tumors like squamous cell carcinoma, glioma, lung or breast cancer [16–18]. Physiologic tracer uptake into the salivary glands – even exceeding the uptake of healthy prostate tissue – was one of the most pronounced observations during evaluation of PSMA-ligands normal biodistribution. The knowledge of organ specific uptake (either driven by PSMA-expression or small molecule transporters) provides a strong rationale to ameliorate soft tissue delineation of tumors with origin in the salivary glands by PSMA-PET/CT.

Case presentation

In 2013, a 58-years old male patient presented with nasal airway obstruction, a visual deficit on the left eye and mild hypoesthesia of the left maxillary nerve. In a rhinoscopic examination a mass in the left nasal cavity with origin in the left maxillary sinus was detected. A biopsy was taken and histologically confirmed the diagnosis of an adenoid cystic carcinoma. Magnetic resonance imaging showed a large tumor mass with infiltration of the left maxillary sinus, pterygoid muscle, oral cavity and maxillary bone as well as a penetration to the cavernous sinus and left orbit. Additionally, growth into the anterior cranial fossa with resulting compression of the left temporal lobe was seen (Fig. 2a, dashed arrows). MRI and histological examinations both showed perineural growth and invasion, typical for ACCs. Chest CT-scan, abdominal sonography and bone scintigraphy did not show any signs of metastatic disease. Initial staging consequently was: cT4b cN0 cM0.

An operation was refused by the patient due to the mutilating extent and he was referred to our institution for a definitive bimodal radiotherapy.

Due to the observation of physiologic PSMA tracer-uptake in salivary glands we decided to additionally perform a ^{68}Ga -PSMA-PET-CT in this patient to see, if malign tumors of the salivary glands show these characteristics.

Treatment planning was based on all available diagnostic procedures, contrast enhanced CT and MR images as well as ^{68}Ga -PSMA-PET-CT.

The patient was treated with a carbon ion boost to the macroscopic tumor disease of 18.0 Gy(RBE) in 6 fractions (single dose 3.0 Gy(RBE)) and a comprehensive photon plan of 54.0 Gy in 27 fractions (2.0 Gy single dose) with helical intensity modulated radiotherapy (IMRT). Carbon ion radiotherapy was applied at

Heidelberg Ion Beam Therapy Center (HIT) with 3 beams in active raster scanning technique (Fig. 2e and f), whereas photon IMRT was applied via helical Tomotherapy® (Fig. 2g and h).

Radiotherapy was tolerated with mild toxicity. By the end of the treatment the patient was suffering from mucositis CTCAE grade II, mild dysphagia as well as a radiation dermatitis CTCAE grade I. In the follow up scans, 3, 6 and 9 months after treatment, partial remission (RECIST criteria) was detected (Fig. 2c and d), the previous radiogenic side effects were declining with only mild xerostomia, CTCAE grade I persisting.

For treatment planning, MRI and a ^{68}Ga -PSMA-PET-CT-scan (Fig. 1a-c) were performed. Additional ^{68}Ga -PSMA-PET-CT was performed for research purposes and showed an intense tracer uptake inside the tumor in the left maxillary sinus with a SUV_{max} of 23.25 (Figs. 1 and 2). The infiltrative tumor growth along the nerves in the skull base was detected well in the ^{68}Ga -PSMA-PET images and also showed contact to the temporal lobe (Fig. 2a, dashed arrows). Furthermore, ^{68}Ga -PSMA-PET-CT showed a significantly increased uptake in the right maxillary sinus (Fig. 1a-c dashed white arrows), so that it seemed likely that the tumor had already spread to the contralateral side. In the MRI scan, contrast enhancement in the right maxillary sinus was interpreted as mucosal swelling and not as tumor infiltration.

Therefore, this finding changed the concept of target volume delineation, since this area of higher uptake was also included to the gross tumor volume (GTV) and the final clinical target volume (CTV) encompassed the complete right maxillary sinus.

PSMA-positivity in ACC was shown in previous reports and was used for diagnostic visualization of local recurrent but also distant metastatic disease [19,20].

As far as we know, this is the first report describing a potential use of ^{68}Ga -PSMA-PET-CT for radiooncological purposes regarding target volume delineation. Nevertheless, due to the retrospective nature of this report, validation of quantitative segmentation and SUV thresholds for target volume delineation is lacking and should be investigated in future studies.

For secondary confirmation of PSMA-positivity we performed an immunohistochemistry (IHC)-staining for PSMA which showed low cytoplasmatic positivity in approximately 5% of ACC cells, similar to a recently published report [20]. Although, PSMA-expression in IHC was low, ^{68}Ga -PSMA-PET-CT revealed high SUV_{max} values (see Fig. 1).

Discussion and conclusion

Especially in ACC of the paranasal sinuses, target volume delineation remains challenging due to the frequent infiltration of the

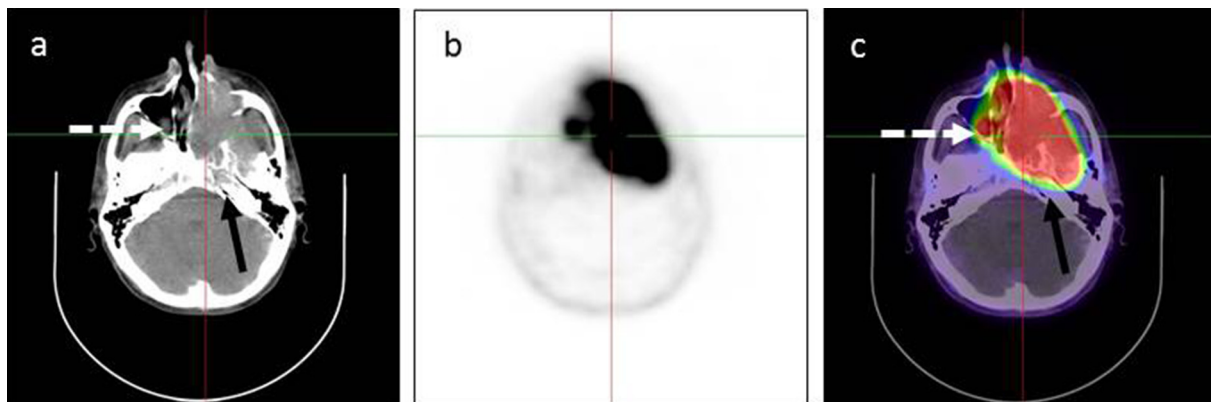


Fig. 1. ^{68}Ga -PSMA-ligand PET CT. (a) non-contrast enhanced CT-scan shows a tumor of the left maxillary sinus with ipsilateral infiltration of skull base (black arrows) (b) intense ^{68}Ga -PSMA-ligand uptake in the tumor with a SUV_{max} of 23.25 (c) fused images confirm infiltration of the contralateral maxillary sinus (dashed white arrows).

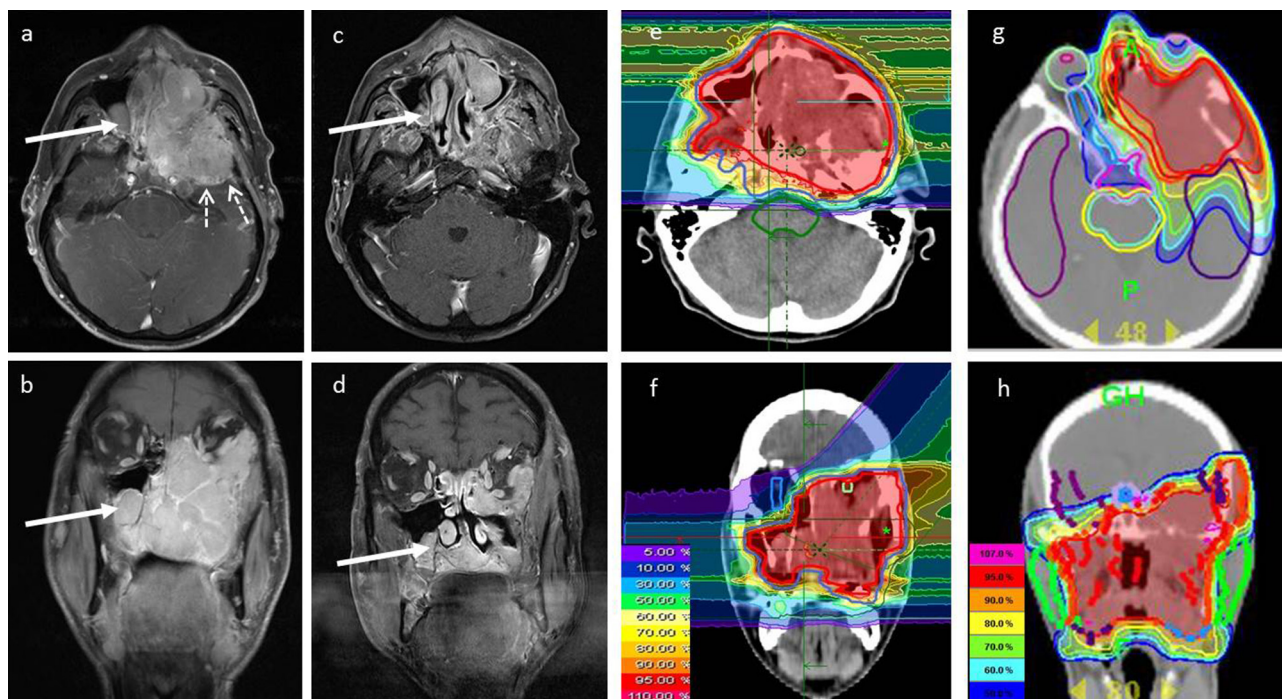


Fig. 2. MRI scans before and after bimodal radiotherapy, dose distribution of radiotherapy plans. (a) and (b) show the transversal and coronal contrast enhanced MRI-scan before bimodal radiotherapy. After radiotherapy a partial response (RECIST criteria) was detected with residual tumor in the left maxillary sinus and anterior cranial fossa (c) and (d); Broad arrows show infiltration of contralateral maxillary sinus, dashed arrows indicate contact of tumor to left temporal lobe. (e) and (f) show the carbon ion therapy boostplan, (g) and (h) show the helical IMRT comprehensive plan with different isodose definitions in %.

skull base along the cranial nerves and due to the close proximity of organs at risk in this area. Contrast-enhanced MR-imaging does not always differentiate between inflammatory changes, mucosal swelling or tumor infiltration. Due to the intense PSMA-ligand uptake of ACC cells, additional information from ^{68}Ga -PSMA-PET-CT may be helpful in optimizing target selection and treatment planning. The potential therapeutic implication of a radionuclide-PSMA targeted treatment in a disease with limited treatment options such as ACC should be evaluated in the future.

Furthermore, these results show that ^{68}Ga -PSMA-PET-CT might be useful as a noninvasive staging tool in patients with ACC.

Ethics approval and consent to participate

All procedures performed in studies involving human participants were in accordance with the ethical standards of the institutional and/or national research committee and with the 1964 Helsinki declaration and its later amendments or comparable ethical standards. Ethical approval was obtained from the local Ethics Committee of Heidelberg University (S-321).

Availability of data and material

Data sharing not applicable to this article as no datasets were generated or analyzed during the current study.

Funding

This work was supported by the Medical Faculty providing a research grant for LK.

Author's contributions

LK carried out data collection and analysis, drafted and finalized the manuscript. HH performed radiotherapy planning and assisted

with figure and table preparation. FG conceived of the study. CK, JD and UH participated in data interpretation. CF and MH performed the immunohistochemistry-staining. All authors read and approved the manuscript.

Competing interests

All authors declare that they have no competing interests.

Appendix A. Supplementary data

Supplementary data associated with this article can be found, in the online version, at <https://doi.org/10.1016/j.ctro.2017.10.003>.

References

- [1] Bjørndal K et al. Salivary gland carcinoma in Denmark 1990–2005: a national study of incidence, site and histology. Results of the Danish Head and Neck Cancer Group (DAHANCA). *Oral Oncol* 2011;47(7):677–82.
- [2] Bradley PJ. Adenoid cystic carcinoma of the head and neck: a review. *Curr Opin Otolaryngol Head Neck Surg* 2004;12(2):127–32.
- [3] Dodd RL, Slevin NJ. Salivary gland adenoid cystic carcinoma: a review of chemotherapy and molecular therapies. *Oral Oncol* 2006;42(8):759–69.
- [4] Coca-Pelaz A et al. Adenoid cystic carcinoma of the head and neck—An update. *Oral Oncol* 2015;51(7):652–61.
- [5] Huang M et al. Factors influencing survival rate in adenoid cystic carcinoma of the salivary glands. *Int J Oral Maxillofac Surg* 1997;26(6):435–9.
- [6] Vander Poorten V et al. Diagnosis and management of parotid carcinoma with a special focus on recent advances in molecular biology. *Head Neck* 2012;34(3):429–40.
- [7] Laurie SA et al. Systemic therapy in the management of metastatic or locally recurrent adenoid cystic carcinoma of the salivary glands: a systematic review. *Lancet Oncol* 2011;12(8):815–24.
- [8] Jakel O, Smith AR, Orton CG. The more important heavy charged particle radiotherapy of the future is more likely to be with heavy ions rather than protons. *Med Phys* 2013;40(9):090601.
- [9] Suit H et al. Proton vs carbon ion beams in the definitive radiation treatment of cancer patients. *Radiother Oncol* 2010;95(1):3–22.
- [10] Jensen AD et al. Combined intensity-modulated radiotherapy plus raster-scanned carbon ion boost for advanced adenoid cystic carcinoma of the head and neck results in superior locoregional control and overall survival. *Cancer* 2015;121(17):3001–9.

- [11] Jensen AD et al. High-LET radiotherapy for adenoid cystic carcinoma of the head and neck: 15 years' experience with raster-scanned carbon ion therapy. *Radiother Oncol* 2016;118(2):272–80.
- [12] Ghosh A, Heston WD. Tumor target prostate specific membrane antigen (PSMA) and its regulation in prostate cancer. *J Cell Biochem* 2004;91(3):528–39.
- [13] Afshar-Oromieh A et al. PET imaging with a [68Ga]gallium-labelled PSMA ligand for the diagnosis of prostate cancer: biodistribution in humans and first evaluation of tumour lesions. *Eur J Nucl Med Mol Imaging* 2013;40(4):486–95.
- [14] Afshar-Oromieh A et al. [68Ga]Gallium-labelled PSMA ligand as superior PET tracer for the diagnosis of prostate cancer: comparison with 18F-FeCh. *Eur J Nucl Med Mol Imaging* 2012;39(6):1085–6.
- [15] Mhawech-Fauceglia P et al. Prostate-specific membrane antigen (PSMA) protein expression in normal and neoplastic tissues and its sensitivity and specificity in prostate adenocarcinoma: an immunohistochemical study using multiple tumour tissue microarray technique. *Histopathology* 2007;50(4):472–83.
- [16] Haffner MC et al. High expression of prostate-specific membrane antigen in the tumor-associated neo-vasculature is associated with worse prognosis in squamous cell carcinoma of the oral cavity. *Mod Pathol* 2012;25(8):1079–85.
- [17] Nomura N et al. Prostate specific membrane antigen (PSMA) expression in primary gliomas and breast cancer brain metastases. *Cancer Cell Int* 2014;14(1):26.
- [18] Wang HL et al. Expression of prostate-specific membrane antigen in lung cancer cells and tumor neovasculature endothelial cells and its clinical significance. *PLoS ONE* 2015;10(5):e0125924.
- [19] Lutje S et al. In Vivo visualization of prostate-specific membrane antigen in adenoid cystic carcinoma of the salivary gland. *Clin Nucl Med* 2016;41(6):476–7.
- [20] Klein-Nulent TJW. Prostate-specific membrane antigen PET imaging and immunohistochemistry in adenoid cystic carcinoma—a preliminary analysis. *Eur J Nucl Med Mol Imaging* 2017;44(10):1614–21.