

Virtual Surgical Planning: The Pearls and Pitfalls

Johnny I. Efanov, MD
 Andr ee-Anne Roy, MD
 Ke N. Huang, MD
 Daniel E. Borsuk, MD, MBA

Objective: Over the past few years, virtual surgical planning (VSP) has evolved into a useful tool for the craniofacial surgeon. Virtual planning and computer-aided design and manufacturing (CAD/CAM) may assist in orthognathic, cranio-orbital, traumatic, and microsurgery of the craniofacial skeleton. Despite its increasing popularity, little emphasis has been placed on the learning curve.

Methods: A retrospective analysis of consecutive virtual surgeries was done from July 2012 to October 2016 at the University of Montreal Teaching Hospitals. Orthognathic surgeries and free vascularized bone flap surgeries were included in the analysis.

Results: Fifty-four virtual surgeries were done in the time period analyzed. Forty-six orthognathic surgeries and 8 free bone transfers were done. An analysis of errors was done. Eighty-five percentage of the orthognathic virtual plans were adhered to completely, 4% of the plans were abandoned, and 11% were partially adhered to. Seventy-five percentage of the virtual surgeries for free tissue transfers were adhered to, whereas 25% were partially adhered to. The reasons for abandoning the plans were (1) poor communication between surgeon and engineer, (2) poor appreciation for condyle placement on preoperative scans, (3) soft-tissue impedance to bony movement, (4) rapid tumor progression, (5) poor preoperative assessment of anatomy.

Conclusion: Virtual surgical planning is a useful tool for craniofacial surgery but has inherent issues that the surgeon must be aware of. With time and experience, these surgical plans can be used as powerful adjuvants to good clinical judgement. (*Plast Reconstr Surg Glob Open* 2018;5:e1443; doi: 10.1097/GOX.0000000000001443; Published online 17 January 2018.)

INTRODUCTION

Over the past 15 years, the advent of virtual surgical planning (VSP) and computer-aided design and manufacturing, CAD/CAM, of 3D stereolithographic models and osteotomy guides have contributed to a significant evolution of craniomaxillofacial surgery. The usefulness of the technique has been widely published in the plastic surgery and maxillofacial surgical literature.¹⁻⁶

The VSP has been used for numerous types of orthognathic procedures including Le Fort I, II, III osteotomies, bilateral sagittal split osteotomies, distraction procedures

of the upper and mid face, and genioplasties. Moreover, several reports have elucidated the benefits of the technique in cranioorbital procedures, perhaps the biggest change in the field since Tessier and Del Monasterio's initial drawings of the techniques. The VSP has been used in traumatic cases, where its use has been limited, and in free osteocutaneous procedures of the craniofacial skeleton, where its use has been widely adopted by oncologic reconstruction surgeons.

Despite all the potential uses for the virtual plans, its potential benefits of reducing operative times and the possibility of a more precise control of the final outcome, there exists a paucity of information regarding the inherent difficulties associated with the technique. This study aims to discuss the potential pitfalls encountered during the learning curve when VSP is incorporated in a craniofacial practice and to propose algorithms to help avoid these pitfalls.

METHODS

We conducted a retrospective review of virtual surgical plans done in our institutions between July 2012 and

From the Plastic and Reconstructive Surgery Service, Centre Hospitalier Universitaire Sainte-Justine, University of Montreal, Montreal, Canada.

Presented at the Annual meeting of the Canadian Society of Plastic Surgeons, June 2016, Ottawa, Canada.

Received for publication May 31, 2017; accepted June 20, 2017.

Copyright  2018 The Authors. Published by Wolters Kluwer Health, Inc. on behalf of The American Society of Plastic Surgeons. This is an open-access article distributed under the terms of the Creative Commons Attribution-Non Commercial-No Derivatives License 4.0 (CCBY-NC-ND), where it is permissible to download and share the work provided it is properly cited. The work cannot be changed in any way or used commercially without permission from the journal.

DOI: 10.1097/GOX.0000000000001443

Disclosure: *The authors have no financial interest to declare in relation to the content of this article. The Article Processing Charge was paid for by the authors.*

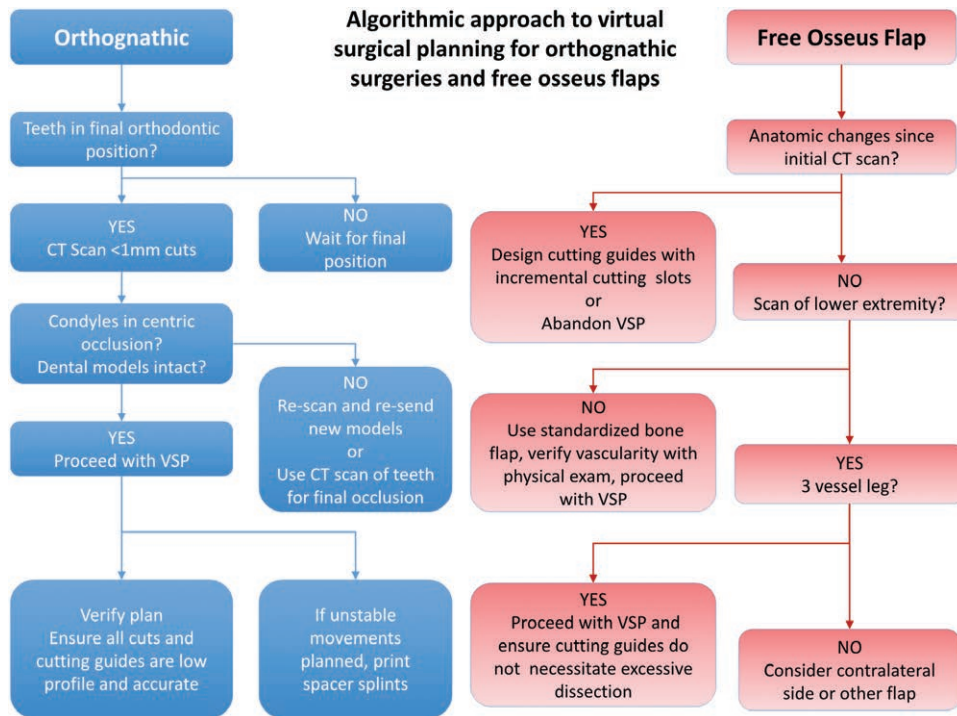


Fig. 1. Algorithmic approach to virtual surgical planning. A, Step-by-step approach for the planning of orthognathic cases. B, Approach to free osseous flaps performed with virtual surgery planning.

Adherence to initial virtual surgical plan peri-operatively

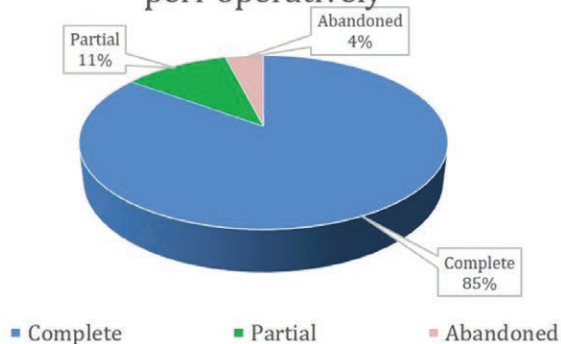


Fig. 2. Representation of adherence to initial virtual surgical plans, divided as complete, partial, or abandoned.

October 2016. Patients were treated in academic centers of University of Montreal, Hôpital Sainte-Justine for children and Hôpital Maisonneuve-Rosemont for adults. All virtual plans were performed by 1 surgeon (senior author) and 1 senior computer engineer. An analysis of the utility of the virtual plans was done pre-, peri-, and postoperatively and documented in the patient’s chart.

We obtained approval from our institution’s ethics review board to perform a retrospective chart review on all the patients. Inclusion criteria included patients of all ages operated for a craniofacial reconstruction or orthognathic surgery with the use of VSP. Target endpoints recorded from each chart included complete adherence to VSP, complete adherence with minor difficulties,

Reasons for incomplete adherence or abandonment of VSP

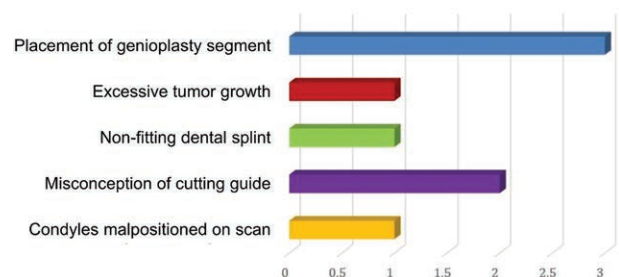


Fig. 3. List of reasons explaining incomplete adherence or abandonment of initial virtual surgical plans.

incomplete adherence, or complete abandonment of virtual surgical plan.

Technique

A step-by-step algorithmic approach is depicted in Figure 1. To perform VSP, one must acquire precise imaging of the craniofacial skeleton with a minimum of 1 mm cuts on a computed tomography (CT) scan. For cases where osteocutaneous fibular free flaps were necessary, we performed computed tomographic angiography as well to evaluate the vascularization and presence of a peroneus magnus when available. The CT scan data were then uploaded and shipped to the engineers (Materialise, Leuven, Belgium) using the Digital Imaging and Communications in Medicine format, and dental occlusal casts in final occlusion were included for the orthognathic cases. Online



CHECKLIST FOR VIRTUAL SURGICAL PLANNING

MINIMIZING COMMUNICATION ERRORS WITH THE ENGINEER IN ORTHOGNATHIC PROCEDURES

Cross each checkmark:

- CT Scan performed following final orthodontic movements
- DICOM images from scan <1mm cuts
- Verify condyle positions
- Examine dental cast impressions for chipped teeth
- Verify cephalometric points on the scan
- Plan osteotomies according to pre-operative clinical assessment and radiographic data
- Ensure that the osteotomy guides are planned on pre-operative skeleton
- Verify that unstable movements, such as down-fracture of maxilla or chin, is maintained with spacer splints
- Ensure final plan is accurate in terms of:
 - Dental occlusion
 - Facial heights
 - Midline position
 - Condyle positions
 - Bony contact
- Ensure timely manufacturing of splints and models to avoid surgical delay

*Johnny I. Efanov; Andrée-Anne Roy; Ke N. Huang; Daniel E. Borsuk
Plastic and Reconstructive Surgery®*

Fig. 4. Checklist to aid in minimizing communication errors between the surgeon and the engineer during virtual online planning. DICOM, Digital Imaging and Communications in Medicine.

meetings were performed with the surgeon and engineers to incorporate clinical findings with skeletal movements in all cases. The virtual plan was accepted by the surgeon before 3-dimensional printing of the occlusal splints and cutting guides. The surgical oncologist was included in all online meetings before printing guides for the free tissue transfer cases.

RESULTS

In total, there were 54 patients who required VSP for craniofacial cases. Indications for virtual surgical plan included 85% (n = 46) for orthognathic correction of dento-skeletal malocclusion and 15% (n = 8) for free vascularized

bone flaps for reconstruction of the facial skeleton. Within the orthognathic group, 39% (n = 18) were for patients with cleft lip and palate deformities, 26% (n = 12) were patients with hemifacial macrosomia, 4% (n = 2) had syndromic craniosynostosis, and 4% (n = 2) had cleido-cranial dysostosis. Twenty-two percentage of patients (n = 10) had other congenital dento-skeletal deformities, whereas the remaining 4% (n = 2) had acquired deformities. Eighty-five percentage of patients (n = 39) had double jaw surgery, whereas the remaining only had 1 jaw surgery.

Within the patients requiring free tissue transfers to the facial skeleton, 75% (n = 6) had mandibular reconstruction with free osteocutaneous fibula flaps, 12.5% (n = 1) had a mandibular reconstruction with a free osteocutaneous

radial forearm flap, and 12.5% (n = 1) had zygomatic-maxillary reconstruction for chronic osteomyelitis with a deep circumflex iliac artery iliac crest osseous flap.

Adherence to the initial virtual surgical plan is illustrated in Figure 2. Eighty-five percentage (n = 46) of all plans were adhered to completely, with 9% (n = 4) orthognathic and 25% (n = 2) free tissue transfers being partially adhered to and 4% (n = 2) orthognathic virtual plans being completely abandoned.

The reasons for incomplete adherence or abandonment of virtual surgical plan are listed in Figure 3. Among free flap operations necessitating VSP, complete adherence to the initial plan was made difficult by rapid tumor growth (n = 1) and altered patient extremity anatomy (n = 1). The patient with rapid tumor growth had mandibular resections outside the planned cutting guide and therefore required intraoperative alterations. Partial adherence occurred in another patient who had had polio induced atrophy of her fibula and therefore required adjustments when the standardized fibula cutting guide was applied in vivo. In a third patient, the large cutting guides caused excessive tissue dissection and skin necrosis of her native skin flaps, whereas in another case, a peroneus magnus was found during leg dissection. In both of these cases, the virtual surgery was adhered to, however, with difficulty.

Among the orthognathic cases, abandonment of the VSP could be explained by condyles out of centric relation on initial scan (n = 1) and soft tissue redraping that precluded the need for genioplasty (n = 1). Incomplete adherence was caused by restricted mandibular movement by soft tissues with difficulty placing the genioplasty (n = 1), difficulty in positioning chin with downfracture (n = 1), inadequate cutting guides due to engineering error (n = 1), and chipped tooth on occlusal splint model (n = 1).

DISCUSSION

The scientific literature reveals that VSP constitutes a valid and reliable method to assist the surgeon in various procedures, ranging from mandibular reconstruction with osteocutaneous free flaps,^{1,6-13} orthognathic procedures,^{3,14-18} midface and Le Fort I advancements,¹⁹⁻²¹ craniosynostosis correction,²² distraction osteogenesis,²³⁻²⁶

and even facial allotransplantation.²⁷ The initial goal of computed virtual planning was to produce stereolithographic models that would assist surgeons for the reconstruction of craniofacial defects and orthognathic surgery. With refinements of design and manufacturing of cutting guides, precontoured plates, and occlusive splints, the technology has now contributed to the wide adoption of these technologies in craniomaxillofacial surgery.

In orthognathic surgery, there are numerous benefits obtained by integrating VSP technology. First, obtaining an accurate and detailed representation of facial asymmetries and precise cephalometric data represents a valuable diagnostic tool facilitated by the tridimensional models.²⁸⁻³⁰ Second, the technique allows for adjustments in simulating different operative techniques, which translates into customized treatment plans and better outcomes.² Third, VSP provides an accurate assessment of centric relation in the temporomandibular joint,³¹ which can be corrected if discrepancies occur.

For mandibular reconstruction, VSP has also offered valuable advantages. Perhaps the most important aspect of using VSP is the improvement in operative efficiency and the decrease in duration of operations with the use of prefabricated cutting guides and plates.¹ Ultimately, the previous reticence with regard to costs of virtual planning and manufacturing is slowly disappearing with studies demonstrating that VSP produces significant savings in operative times and consequently cost.^{9,32-34} The availability of “in-office” tridimensional printing further improves the cost-effectiveness of this technique.³⁵ Interestingly, the literature does not report any increase in complications with the use of VSP.^{1,9} Furthermore, stereolithographic models constructed from virtual planning represent a valuable tool for educating patients, family members, and trainees alike, and have been supported in the literature.^{36,37}

Among factors that influence virtual planning substantially, communication with the manufacturing engineer is critical. To minimize potential sources of errors due to communication, we have developed a checklist to ensure that all aspects of planning are covered (Fig. 4). For pre-

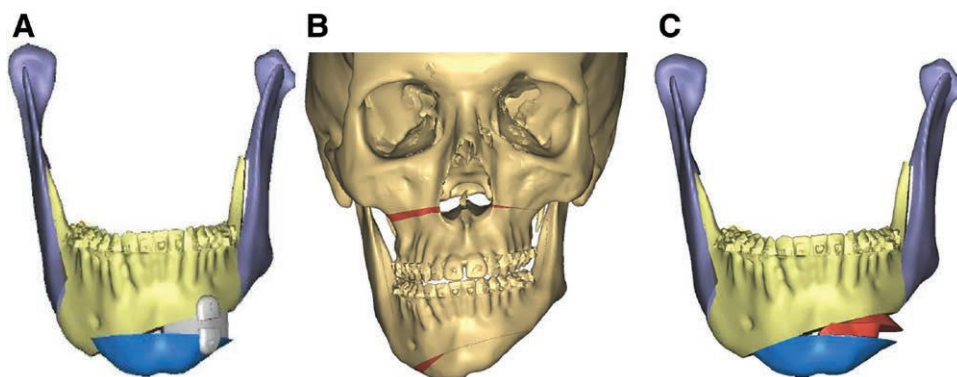


Fig. 5. 3D planning for genioplasty. Positioning of spacer guide with temporary fixation for genioplasty (A). Osteotomies and bone to be resected for Lefort I in red (B). Bone graft from right genioplasty and Lefort I (C).

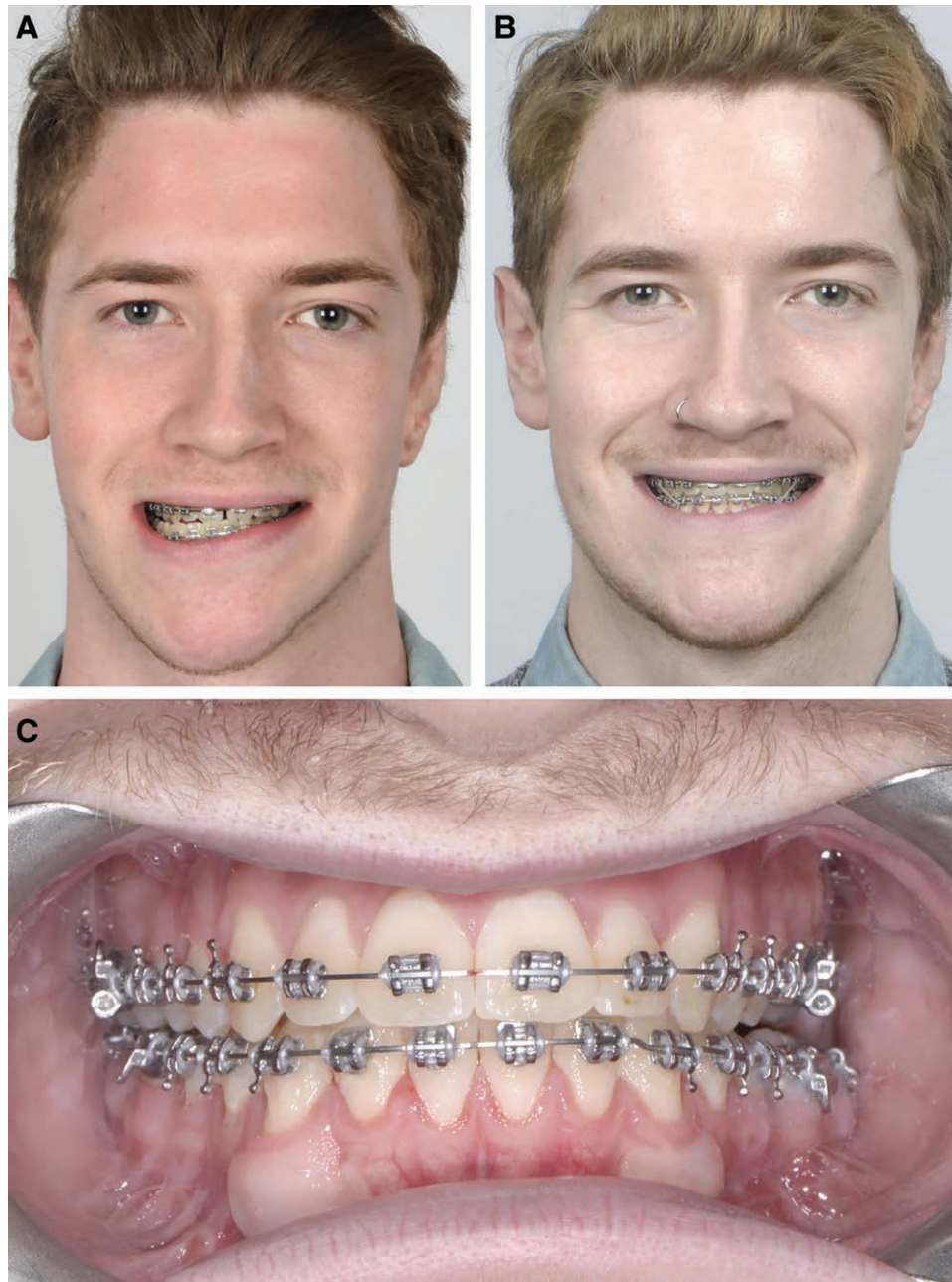


Fig. 6. Preoperative photograph of patient from Figure 4 with hemifacial microsomia (A). Postoperative results at 1 month (B) and at 6 months (C) after virtual surgical planning. Symmetric facial morphology and a natural smile.

cise construction of splints and tridimensional positioning of cranial structures in orthognathic and mandibular reconstruction, an entire understanding of what the surgeon wishes to accomplish is required by the engineer. Previous studies have stated that communication with the manufacturers constitutes a demanding challenge, and perhaps practical protocols applied via online meetings can be developed to diminish engineering errors.³⁸ Standardizing virtual designs according to cephalometric data cannot replace the essential discussion required between the engineer and the surgeon because everyone functions

differently. Moreover, clinical judgement and examination cannot be overlooked and will ultimately guide the narrative of the virtual plans.

Occlusal casts can sometimes present a challenge with VSP when chipped teeth affect the splint's intraoperative fit. The canine tip represents one of the key anatomical landmarks for virtual splint planning; therefore, any modification produced by a chipped tooth will affect final occlusive fitting of the splint.¹⁴ When we encountered this problem in a patient with lower incisors that were chipped, the final splints were modified perioperatively by drilling the occlusal

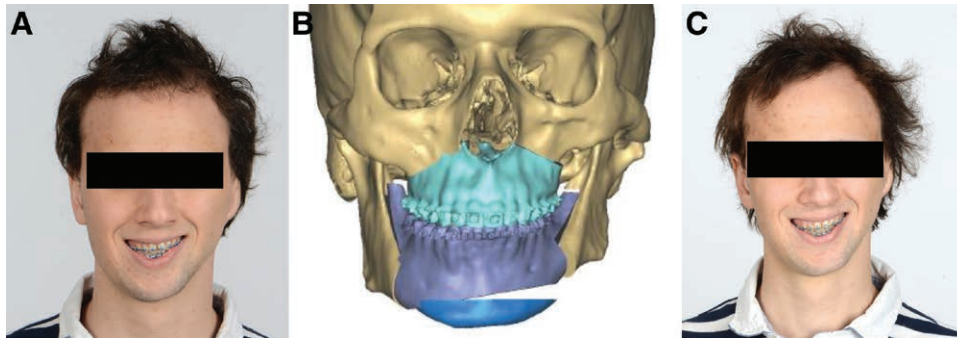


Fig. 7. Patient with hemifacial microsomia smiling (A). Virtual surgical planning illustrates bony segments' positions after Lefort I osteotomies, bilateral sagittal split osteotomies, and genioplasty (B). Results at 4-month follow-up demonstrates an improved symmetry and smile (C).

cast over the unbroken teeth, which allowed it to insert properly.

Ensuring adequate final occlusion represents one of the most challenging aspects of VSP. If the condyles are not in centric occlusion and the cutting guides are built according to VSP where they are, then the condyles will have a natural tendency to displace postoperatively. The final result produces another malocclusive position. In this context, the pitfall of VSP is to build the plans according to the natural position of the condyle rather than where it is supposed to be. Another aspect to consider in orthognathic virtual planning is the temporal relationship between when the imaging is performed and when the final orthodontic movements occur. When the scans are done before the final movements, errors will occur with relation to the exact position of the cuts and the final occlusion.¹⁵ It becomes critical to conduct the VSP only after the final orthodontic position has developed. Finally, VSP requires multiple checkpoints to verify for inaccuracies. For example, if the splints are constructed based on the placement after postoperative rather than preoperative Lefort osteotomy, the cutting guide becomes backward. Mistakes in planning can occur and should be discovered before manufacturing when possible.

Another important pitfall of VSP can occur during correction of severe asymmetry for syndromic craniofacial patients. Occasionally, the virtual plan does not translate to the clinical setting with down-fractures of the maxilla and genioplasty and movement of the mandible. Soft-tissue behavior cannot be estimated on virtual plans and can severely alter the intraoperative plan. These hurdles were encountered in 2 of our patients and are demonstrated in Figures 5–7. Previous studies have described the challenges encountered with planning for severely asymmetric patients, where VSP can assist with tridimensional osseous planning but where it cannot replace the intraoperative clinical judgment of soft-tissue manipulation and placement.^{16,39} In our experience, the liberal use of spacer splints palliated this pitfall.

Mandibular reconstruction with fibular free flaps present other challenges related to VSP. Shaping of the osseous component can contain errors if a standardized fibula

is used. Indeed, dimensions of the fibular component can vary from patient to patient and standardization of fibulas used in the VSP are rendered unusable when transposed to the mandible. This was experienced in one of our patients with an atrophic fibula due to polio where the discrepancy with the standard VSP fibula was significant. Systematic imaging of lower extremities may be warranted when medical comorbidities of patients raise suspicions. Furthermore, imaging with CT angiography can minimize the underappreciation of peroneus magnus in harvests of free fibular flaps.^{40,41} When a dominant peroneal artery supplies the distal portion, it is warranted to use the contralateral leg.

When constructing cutting guides for mandibular reconstruction, their relative size should not be designed too large wherein unnecessary stripping of the native mandible can cause decreased healing potential and soft-tissue necrosis.⁴² In our study, excessive tissue dissection, due to design of cutting guides, accounted for necrosis of native skin flaps of the chin and cheeks over a free tissue flap. Very few studies have investigated the impact of surgical cutting guide size on osseous healing during soft-tissue dissection, but standard techniques describing placement of cutting guides emphasize the need to minimize tissue stripping and maintain as much periosteum as possible around the mandible.^{43,44} The same problem can occur in orthognathic surgery as well, when cutting guides are too large for use. To avoid this complication, virtual markings are made on the maxilla during planning and are translated onto the bone in vivo precluding the use of cutting guides.

For oncologic cases, designs of virtual surgical planning should not overlook the possibility that resection margins protrude further than initially expected.⁴⁵ This is particularly true when CT scans are performed too early in the sequence of treatment planning. Between the initial imaging, the virtual planning, the manufacturing, and the operative day, tumors may grow and oncologic margins are necessarily affected (Fig. 8). Mandibular guides become obsolete in consequence, and the virtual plan is abandoned.⁴⁶ Some authors have suggested to obtain 2 additional cutting guides (1 proximal and 1 distal) to perform a second osteotomy for wider resections.⁴⁵ Another solution to this problem relies in designing cutting guides

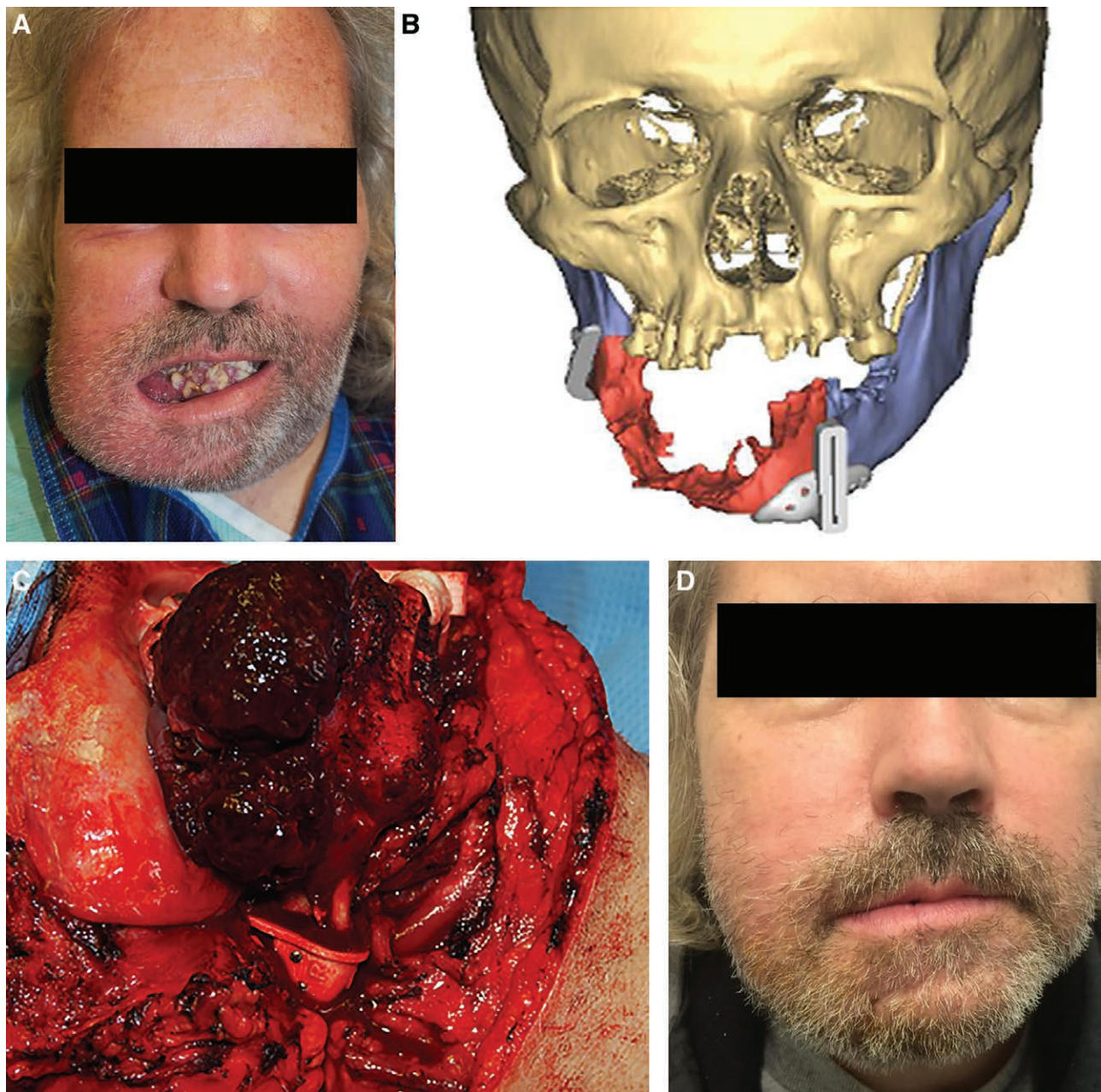

Fig. 8. Patient with squamous cell carcinoma of the oral cavity invading into the right mandible (A). Virtual surgical planning for mandible resection guides with slot widths of 1 mm and 2.2 mm holes for temporary fixation (B). Significant tumor growth between the initial scan on which virtual planning was performed and the time of surgery, rendering the preconceived mandible cutting guides unusable (C). Results at 6 months of follow-up (D).

with interval slots, generally 1 cm, to accommodate any tumor growth. We have experienced this pitfall in 1 patient and the use of incremental slots on the mandibular guides allowed to correct the wider than expected oncologic margins (Fig. 9).

There are potential sources of error with VSP that this article wanted to demonstrate. Although we believe that there are significant advantages reported in the literature, including savings in operative times and patient education with stereolithographic models, having a better understanding of potential pitfalls could

decrease the rate of partial adherence or abandonment that was reported in this review. We continue to recommend planning orthognathic and free flap procedures with this technology considering that only a minimal 4% of cases were completely abandoned and 11% demonstrated partial adherence while retaining certain levels of usefulness intraoperatively. Also, we concede that an adequate evaluation of VSP's efficacy should focus on long-term outcomes of orthognathic and free flap operations. Although this article does not aim to compare final functional or esthetic results, it provides nonetheless

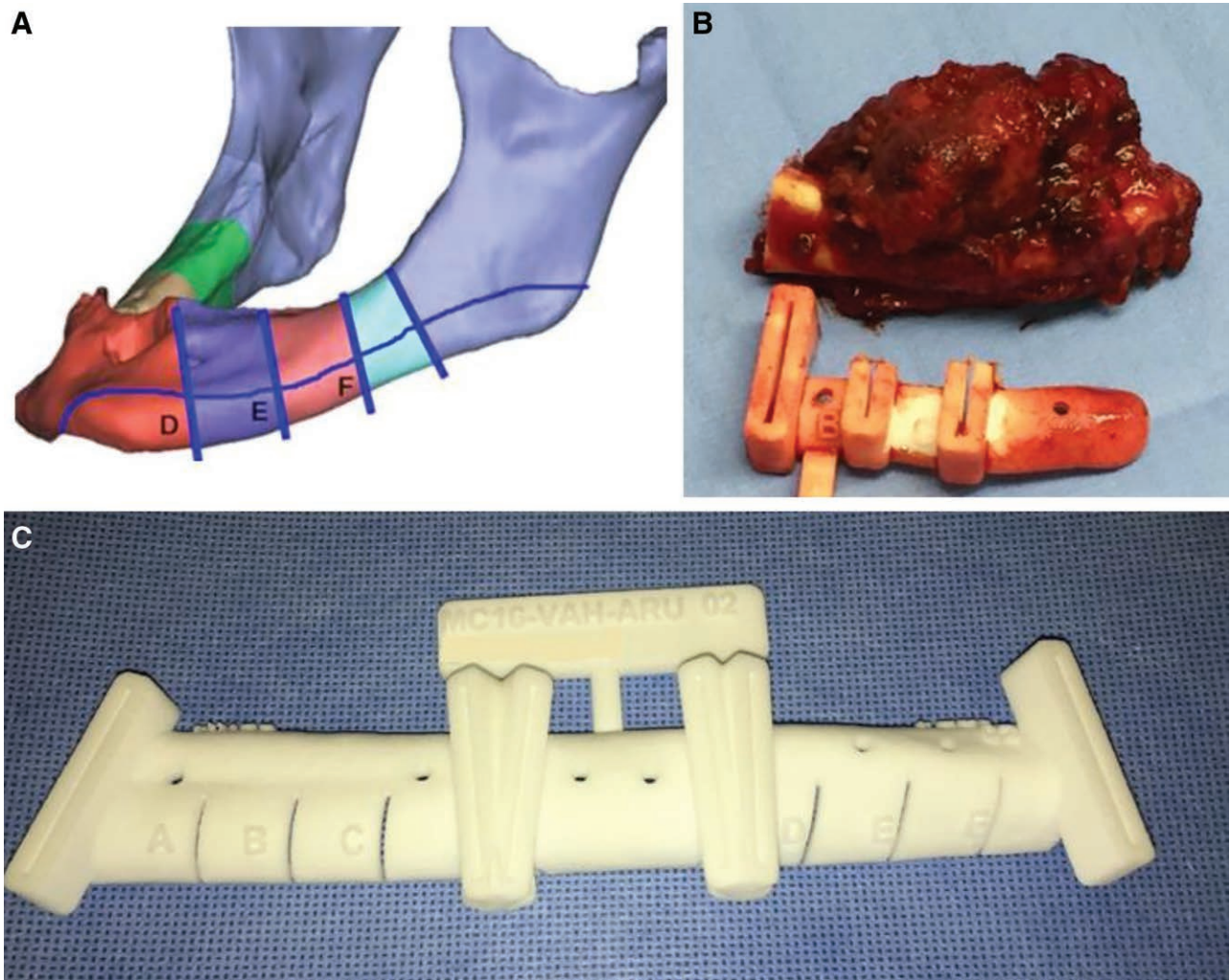


Fig. 9. Solution to problem encountered in Figure 7. Preoperative planning on virtual models of different cutting slots depending on tumor growth and resection margins (A). Intraoperative tumor resection with selection of the appropriate slot on the mandibular cutting guide (B). Example of fibular cutting guide with incremental slots to accommodate for tumor resection margins (C).

valuable intraoperative lessons to surgeons who begin to incorporate this technology into practice.

CONCLUSIONS

VSP is a useful tool for craniofacial surgery that demonstrated benefits in decreasing operative times and improving surgical outcomes. However, there are inherent issues that the surgeon must be aware of. With time and experience, these surgical plans can be used as powerful adjuncts to good clinical judgement.

Daniel Borsuk, MD, MBA, FRCSC, FACS
 Plastic and Reconstructive Surgery Service
 Centre Hospitalier Universitaire Sainte-Justine
 3175 Ch. Cote-Ste-Catherine
 Montreal
 Quebec
 Canada
 H3T1C5
 E-mail: info@drborsuk.com

ACKNOWLEDGMENTS

We gratefully thank Natasha Caminsky for her contribution with data collection.

REFERENCES

1. Chang EI, Jenkins MP, Patel SA, et al. Long-term operative outcomes of preoperative computed tomography-guided virtual surgical planning for osteocutaneous free flap mandible reconstruction. *Plast Reconstr Surg.* 2016;137:619–623.
2. Stokbro K, Aagaard E, Torkov P, et al. Virtual planning in orthognathic surgery. *Int J Oral Maxillofac Surg.* 2014;43:957–965.
3. Farrell BB, Franco PB, Tucker MR. Virtual surgical planning in orthognathic surgery. *Oral Maxillofac Surg Clin North Am.* 2014;26:459–473.
4. Pipalia H, Ganesh P, Shetty S, et al. Virtual surgery planning in orthomorphic correction of mandibular dysmorphology. *J Craniofac Surg.* 2016;27:2156–2158.
5. Weitz J, Bauer FJ, Hapfelmeier A, et al. Accuracy of mandibular reconstruction by three-dimensional guided vascularised fibular free flap after segmental mandibulectomy. *Br J Oral Maxillofac Surg.* 2016;54:506–510.

6. Avraham T, Franco P, Brecht LE, et al. Functional outcomes of virtually planned free fibula flap reconstruction of the mandible. *Plast Reconstr Surg*. 2014;134:628e–634e.
7. Eckardt A, Swennen GR. Virtual planning of composite mandibular reconstruction with free fibula bone graft. *J Craniofac Surg*. 2005;16:1137–1140.
8. Hirsch DL, Garfein ES, Christensen AM, et al. Use of computer-aided design and computer-aided manufacturing to produce orthognathically ideal surgical outcomes: a paradigm shift in head and neck reconstruction. *J Oral Maxillofac Surg*. 2009;67:2115–2122.
9. Toto JM, Chang EI, Agag R, et al. Improved operative efficiency of free fibula flap mandible reconstruction with patient-specific, computer-guided preoperative planning. *Head Neck*. 2015;37:1660–1664.
10. Antony AK, Chen WF, Kolokythas A, et al. Use of virtual surgery and stereolithography-guided osteotomy for mandibular reconstruction with the free fibula. *Plast Reconstr Surg*. 2011;128:1080–1084.
11. Liu XJ, Gui L, Mao C, et al. Applying computer techniques in maxillofacial reconstruction using a fibula flap: a messenger and an evaluation method. *J Craniofac Surg*. 2009;20:372–377.
12. Marchetti C, Bianchi A, Mazzoni S, et al. Oromandibular reconstruction using a fibula osteocutaneous free flap: four different “preplating” techniques. *Plast Reconstr Surg*. 2006;118:643–651.
13. Valentini V, Agrillo A, Battisti A, et al. Surgical planning in reconstruction of mandibular defect with fibula free flap: 15 patients. *J Craniofac Surg*. 2005;16:601–607.
14. Hammoudeh JA, Howell LK, Boutros S, et al. Current status of surgical planning for orthognathic surgery: traditional methods versus 3D surgical planning. *Plast Reconstr Surg Glob Open*. 2015;3:e307.
15. Janakiraman N, Feinberg M, Vishwanath M, et al. Integration of 3-dimensional surgical and orthodontic technologies with orthognathic “surgery-first” approach in the management of unilateral condylar hyperplasia. *Am J Orthod Dentofacial Orthop*. 2015;148:1054–1066.
16. Scolozzi P. Computer-aided design and computer-aided modeling (CAD/CAM) generated surgical splints, cutting guides and custom-made implants: which indications in orthognathic surgery? *Rev Stomatol Chir Maxillofac Chir Orale*. 2015;116:343–349.
17. Shaheen E, Sun Y, Jacobs R, et al. Three-dimensional printed final occlusal splint for orthognathic surgery: design and validation. *Int J Oral Maxillofac Surg*. 2017;46:67–71.
18. Swennen GR. Timing of three-dimensional virtual treatment planning of orthognathic surgery: a prospective single-surgeon evaluation on 350 consecutive cases. *Oral Maxillofac Surg Clin North Am*. 2014;26:475–485.
19. Kracima J, Jansma J, Schepers RH. Splintless surgery: does patient-specific CAD-CAM osteosynthesis improve accuracy of Le Fort I osteotomy? *Br J Oral Maxillofac Surg*. 2016;54:1085–1089.
20. Metzler P, Geiger EJ, Chang CC, et al. Assessment of three-dimensional nasolabial response to Le Fort I advancement. *J Plast Reconstr Aesthet Surg*. 2014;67:756–763.
21. Steinbacher DM. Three-dimensional analysis and surgical planning in craniomaxillofacial surgery. *J Oral Maxillofac Surg*. 2015;73:S40–S56.
22. Chim H, Wetjen N, Mardini S. Virtual surgical planning in craniofacial surgery. *Semin Plast Surg*. 2014;28:150–158.
23. Benateau H, Chatellier A, Caillot A, et al. Computer-assisted planning of distraction osteogenesis for lower face reconstruction in gunshot traumas. *J Craniomaxillofac Surg*. 2016;44:1583–1591.
24. Yu H, Wang B, Wang M, et al. Computer-assisted distraction osteogenesis in the treatment of Hemifacial Microsomia. *J Craniofac Surg*. 2016;27:1539–1542.
25. Doscher ME, Garfein ES, Bent J, et al. Neonatal mandibular distraction osteogenesis: converting virtual surgical planning into an operative reality. *Int J Pediatr Otorhinolaryngol*. 2014;78:381–384.
26. Varol A, Basa S. The role of computer-aided 3D surgery and stereolithographic modelling for vector orientation in premaxillary and trans-sinusoidal maxillary distraction osteogenesis. *Int J Med Robot*. 2009;5:198–206.
27. Sosin M, Ceradini DJ, Hazen A, et al. Total face, eyelids, ears, scalp, and skeletal subunit transplant cadaver simulation: the culmination of aesthetic, craniofacial, and microsurgery principles. *Plast Reconstr Surg*. 2016;137:1569–1581.
28. Swennen GR, Mollemans W, Schutysen F. Three-dimensional treatment planning of orthognathic surgery in the era of virtual imaging. *J Oral Maxillofac Surg*. 2009;67:2080–2092.
29. Baker SB, Goldstein JA, Seruya M. Outcomes in computer-assisted surgical simulation for orthognathic surgery. *J Craniofac Surg*. 2012;23:509–513.
30. Edwards SP. Computer-assisted craniomaxillofacial surgery. *Oral Maxillofac Surg Clin North Am*. 2010;22:117–134.
31. Hsu SS, Gateno J, Bell RB, et al. Accuracy of a computer-aided surgical simulation protocol for orthognathic surgery: a prospective multicenter study. *J Oral Maxillofac Surg*. 2013;71:128–142.
32. Resnick CM, Inverso G, Wrzosek M, et al. Is there a difference in cost between standard and virtual surgical planning for orthognathic surgery? *J Oral Maxillofac Surg*. 2016;74:1827–1833.
33. Rodby KA, Turin S, Jacobs RJ, et al. Advances in oncologic head and neck reconstruction: systematic review and future considerations of virtual surgical planning and computer aided design/computer aided modeling. *J Plast Reconstr Aesthet Surg*. 2014;67:1171–1185.
34. Zielinski E. Virtual surgical planning in craniomaxillofacial reconstruction. In: Motamedi MHK, ed. *A Textbook of Advanced Oral and Maxillofacial Surgery*; InTech, Iran, 2015.
35. Mendez BM, Chiodo MV, Patel PA. Customized “in-office” three-dimensional printing for virtual surgical planning in craniofacial surgery. *J Craniofac Surg*. 2015;26:1584–1586.
36. Chopra K, Manson PN, Gastman BR. Stereolithographic modeling in reconstructive surgery of the craniofacial skeleton after tumor resection. *Plast Reconstr Surg*. 2012;129:743e–745e.
37. Emmez H, Küküködük I, Börcek AO, et al. Effectiveness of skull models and surgical simulation: comparison of outcome between different surgical techniques in patients with isolated brachycephaly. *Childs Nerv Syst*. 2009;25:1605–1612.
38. Zhao L, Patel PK, Cohen M. Application of virtual surgical planning with computer assisted design and manufacturing technology to cranio-maxillofacial surgery. *Arch Plast Surg*. 2012;39:309–316.
39. Seres L, Varga E, Jr, Kocsis A, et al. Correction of a severe facial asymmetry with computerized planning and with the use of a rapid prototyped surgical template: a case report/technique article. *Head Face Med*. 2014;10:27.
40. Young DM, Trabulsy PP, Anthony JP. The need for preoperative leg angiography in fibula free flaps. *J Reconstr Microsurg*. 1994;10:283–7; discussion 287.
41. Garvey PB, Chang EI, Selber JC, et al. A prospective study of preoperative computed tomographic angiographic mapping of free fibula osteocutaneous flaps for head and neck reconstruction. *Plastic and reconstructive surgery*. 2012;130:541e–9e.
42. Utvåg SE, Grundnes O, Reikeraos O. Effects of periosteal stripping on healing of segmental fractures in rats. *J Orthop Trauma*. 1996;10:279–284.
43. Succo G, Berrone M, Battiston B, et al. Step-by-step surgical technique for mandibular reconstruction with fibular free flap: application of digital technology in virtual surgical planning. *Eur Arch Otorhinolaryngol*. 2015;272:1491–1501.

44. Nakao M, Aso S, Imai Y, et al. Statistical analysis of interactive surgical planning using shape descriptors in mandibular reconstruction with fibular segments. *PLoS One*. 2016;11: e0161524.
45. Roser SM, Ramachandra S, Blair H, et al. The accuracy of virtual surgical planning in free fibula mandibular reconstruction: comparison of planned and final results. *J Oral Maxillofac Surg*. 2010;68:2824–2832.
46. Kraeima J, Schepers RH, van Ooijen PM, et al. Integration of oncologic margins in three-dimensional virtual planning for head and neck surgery, including a validation of the software pathway. *J Craniomaxillofac Surg*. 2015;43:1374–1379.