

# Next-generation sequencing to solve complex inherited retinal dystrophy: A case series of multiple genes contributing to disease in extended families

Kaylie D. Jones,<sup>1</sup> Dianna K. Wheaton,<sup>1,4</sup> Sara J. Bowne,<sup>2</sup> Lori S. Sullivan,<sup>2</sup> David G. Birch,<sup>1,4</sup> Rui Chen,<sup>3</sup> Stephen P. Daiger<sup>2,5</sup>

(The first two authors contributed equally to this study.)

<sup>1</sup>Retina Foundation of the Southwest, Dallas, TX; <sup>2</sup>Human Genetics Center, School of Public Health, The University of Texas Health Science Center (UTHealth), Houston, TX; <sup>3</sup>Baylor College of Medicine, Houston, TX; <sup>4</sup>Ophthalmology, University of Texas Southwestern Medical Center, Dallas, TX; <sup>5</sup>Ruiz Department of Ophthalmology and Visual Science, McGovern Medical School, University of Texas Health Science Center Houston (UTHealth), Houston, TX

**Purpose:** With recent availability of next-generation sequencing (NGS), it is becoming more common to pursue disease-targeted panel testing rather than traditional sequential gene-by-gene dideoxy sequencing. In this report, we describe using NGS to identify multiple disease-causing mutations that contribute concurrently or independently to retinal dystrophy in three relatively small families.

**Methods:** Family members underwent comprehensive visual function evaluations, and genetic counseling including a detailed family history. A preliminary genetic inheritance pattern was assigned and updated as additional family members were tested. Family 1 (FAM1) and Family 2 (FAM2) were clinically diagnosed with retinitis pigmentosa (RP) and had a suspected autosomal dominant pedigree with non-penetrance (n.p.). Family 3 (FAM3) consisted of a large family with a diagnosis of RP and an overall dominant pedigree, but the proband had phenotypically cone-rod dystrophy. Initial genetic analysis was performed on one family member with traditional Sanger single gene sequencing and/or panel-based testing, and ultimately, retinal gene-targeted NGS was required to identify the underlying cause of disease for individuals within the three families. Results obtained in these families necessitated further genetic and clinical testing of additional family members to determine the complex genetic and phenotypic etiology of each family.

**Results:** Genetic testing of FAM1 (n = 4 affected; 1 n.p.) identified a dominant mutation in *RPI* (p.Arg677Ter) that was present for two of the four affected individuals but absent in the proband and the presumed non-penetrant individual. Retinal gene-targeted NGS in the fourth affected family member revealed compound heterozygous mutations in *USH2A* (p. Cys419Phe, p.Glu767Serfs\*21). Genetic testing of FAM2 (n = 3 affected; 1 n.p.) identified three retinal dystrophy genes (*PRPH2*, *PRPF8*, and *USH2A*) with disease-causing mutations in varying combinations among the affected family members. Genetic testing of FAM3 (n = 7 affected) identified a mutation in *PRPH2* (p.Pro216Leu) tracking with disease in six of the seven affected individuals. Additional retinal gene-targeted NGS testing determined that the proband also harbored a multiple exon deletion in the *CRX* gene likely accounting for her cone-rod phenotype; her son harbored only the mutation in *CRX*, not the familial mutation in *PRPH2*.

**Conclusions:** Multiple genes contributing to the retinal dystrophy genotypes within a family were discovered using retinal gene-targeted NGS. Families with noted examples of phenotypic variation or apparent non-penetrant individuals may offer a clue to suspect complex inheritance. Furthermore, this finding underscores that caution should be taken when attributing a single gene disease-causing mutation (or inheritance pattern) to a family as a whole. Identification of a disease-causing mutation in a proband, even with a clear inheritance pattern in hand, may not be sufficient for targeted, known mutation analysis in other family members.

Retinal dystrophies are a genetically and phenotypically heterogeneous collection of eye diseases disturbing the function of photoreceptor cells and subsequently leading to loss of vision. To date, 256 genes listed in [RetNet](#) have been associated with syndromic and non-syndromic retinal dystrophies,

which can be inherited as an autosomal-recessive, autosomal-dominant, or X-linked trait ([RetNet](#)). Retinitis pigmentosa (RP) is the most common form of hereditary retinal degeneration with a worldwide prevalence of about 1 in 3,500–5,000 and affects more than 1.5 million individuals worldwide [1-5]. RP can be divided into two groups: non-syndromic where RP manifests only in the eyes and syndromic RP where other non-ocular diseases are concomitant. The most common form of syndromic RP is Usher syndrome, which involves RP with

Correspondence to: Kaylie Jones, Retina Foundation of the Southwest, Suite 200, 9600 North Central Expressway, Dallas, TX 75231; Phone: (214) 363-3911; FAX: (214) 363-4538; email: [kwebb@retinafoundation.org](mailto:kwebb@retinafoundation.org)

sensory-neural hearing impairment and frequently, vestibular dysfunction [6].

Current evidence suggests that the majority of inherited retinal dystrophies are monogenic (single gene) in an individual, and a reasonable assumption is that the same gene is involved in affected members of a single family, following standard Mendelian inheritance, i.e., autosomal dominant, autosomal recessive, or X-linked. However, rare digenic, triallelic, and mitochondrial forms have been observed [7-10], and multiple, independent mutations are possible in large families. Correctly identifying the disease-causing gene within a family is vital to providing guidance to the onset, progression, and severity of disease and for enrolling patients in clinical trials. Genotype data are also used to infer phenotype and to calculate inheritance risk to offspring [11].

Genetic testing in retinal diseases historically began with the proband as proxy for the family and targeted genes analyzed in a known disease-causing sequential manner until a probable disease-causing variant was identified. With the emerging availability of next-generation sequencing (NGS), it is becoming routine to parallel gene testing for large panels of genes rather than sequential gene-by-gene testing [12-16]. Few would disagree that NGS is a powerful, cost-effective, and efficient genetic testing tool, but comprehensive testing can also yield incidental and unexpected findings. In this report, we describe the identification of multiple gene mutations associated with retinal dystrophy occurring independently or concurrently in three relatively small families.

## METHODS

The study was performed in accordance with the Declaration of Helsinki, and informed consent was obtained from all participants. The research was approved by the Committee for Protection of Human Subjects, University of Texas Southwestern Medical Center and at the University of Texas Health Science Center.

Members from three families with an initial diagnosis of RP from referring ophthalmologists underwent comprehensive visual function evaluations as part of the Retina Foundation of the Southwest's ongoing research into the etiology and pathophysiology of inherited retinal disease. Clinical examinations included Electronic Early Treatment of Diabetic Retinopathy Study (E-ETDRS) visual acuity, dark-adapted visual thresholds (Goldmann-Weekers adaptometer; Haag-Streit, Bern, Switzerland), kinetic and static visual field perimetry (Octopus; Haag-Streit, Koeniz, Switzerland), and in most cases, spectral domain optical coherence tomography (SD-OCT; Heidelberg Spectralis, Heidelberg, Germany) and

full-field electroretinography (ffERG; Espion E3, Diagnosys, Lowell, MA).

Pedigrees were constructed based on patient interviews, and a preliminary genetic inheritance pattern was assigned and updated as additional family members were willing to participate. Comprehensive visual function exams and genetic testing were offered to immediate and extended family members to ascertain affectation status of all available individuals. If family members were unable to attend an in-person testing appointment, a biologic sample was sought for genetic testing along with a brief phone interview to collect vision and family history information, as well as obtain informed consent.

Blood or saliva samples were obtained from each individual. Genomic DNA was extracted from whole blood as reported previously [17]. Saliva was collected with Oragene collection kits (DNA Genotek, Inc., Kanata, Canada) and extracted according to the manufacturer's recommended protocol.

Genetic analysis was initially performed on one family member with traditional Sanger sequencing via sequential analysis of an autosomal dominant retinitis pigmentosa (adRP) gene panel to identify the underlying cause of disease in that family. Additional family members were clinically and genetically tested to refine the emerging complex genetic and phenotypic etiology. Retinal gene-targeted NGS analysis was used to resolve disparate genetic testing findings.

Sanger single gene and adRP panel-based sequencing was performed in the Clinical Laboratory Improvement Amendments (CLIA)-certified DNA diagnostic Laboratory for Molecular Diagnosis of Inherited Eye Diseases (LMDIED) at the University of Texas-Houston. Retinal gene-targeted NGS was performed in the University of Texas-Houston Health Science Center laboratory or in the Department of Molecular and Human Genetics, Baylor College of Medicine, Houston [18,19]. All likely pathogenic mutations identified using retinal gene-targeted NGS were confirmed using Sanger sequencing.

Pathogenicity analyses included variant assessment (PolyPhen-2; SIFT; Mutation Taster), sequencing of multiple family members, and segregation analysis. The observed genotype was compared to the reported diagnosis and ophthalmic characterization for each individual and subsequently assessed for consistency with reported literature. Additional Sanger single gene sequencing and further rounds of retinal gene-targeted NGS were performed as needed until the genetic cause of disease was determined for each available family member.

**RESULTS**

Pedigrees for the three families are shown in Figure 1. Family 1 (FAM1) and Family 2 (FAM2) were clinically diagnosed initially with RP with suspected dominant inheritance with non-penetrance (n.p.). Family 3 (FAM3) comprised a dominant pedigree with multiple generations diagnosed with RP, but the proband was phenotypically consistent with a cone-rod dystrophy phenotype.

**FAM1:** The proband of FAM1 (#2334) was diagnosed with RP at age 33 years. She reported bilateral, sensorineural mild-to-moderate hearing loss from age 10 that was thought to be due to childhood measles. The family history revealed other cases of RP but no hearing loss. At age 46 years, her

phenotype was consistent with a typical adult onset, rod-driven case of RP. Her visual acuity was reduced to 20/50 oculus dexter (OD) and 20/60 oculus sinister (OS), rod ERG responses (Figure 2) were non-detectable, while cone ERG responses were minimally reduced from normal although her central visual field was reduced to less than 10 degrees. Her final dark-adapted threshold was elevated by 3.9 log units with an 11 degree test centrally fixated. The OCT scans for the proband showed limited retention of the photoreceptor layer in the fovea OS and only discontinuous remnants in the fovea OD (Figure 3). Fundus photography (Figure 3) showed notable bone spicule-like pigmentation, vessel attenuation, and disc pallor in the proband. Full-field ERG responses

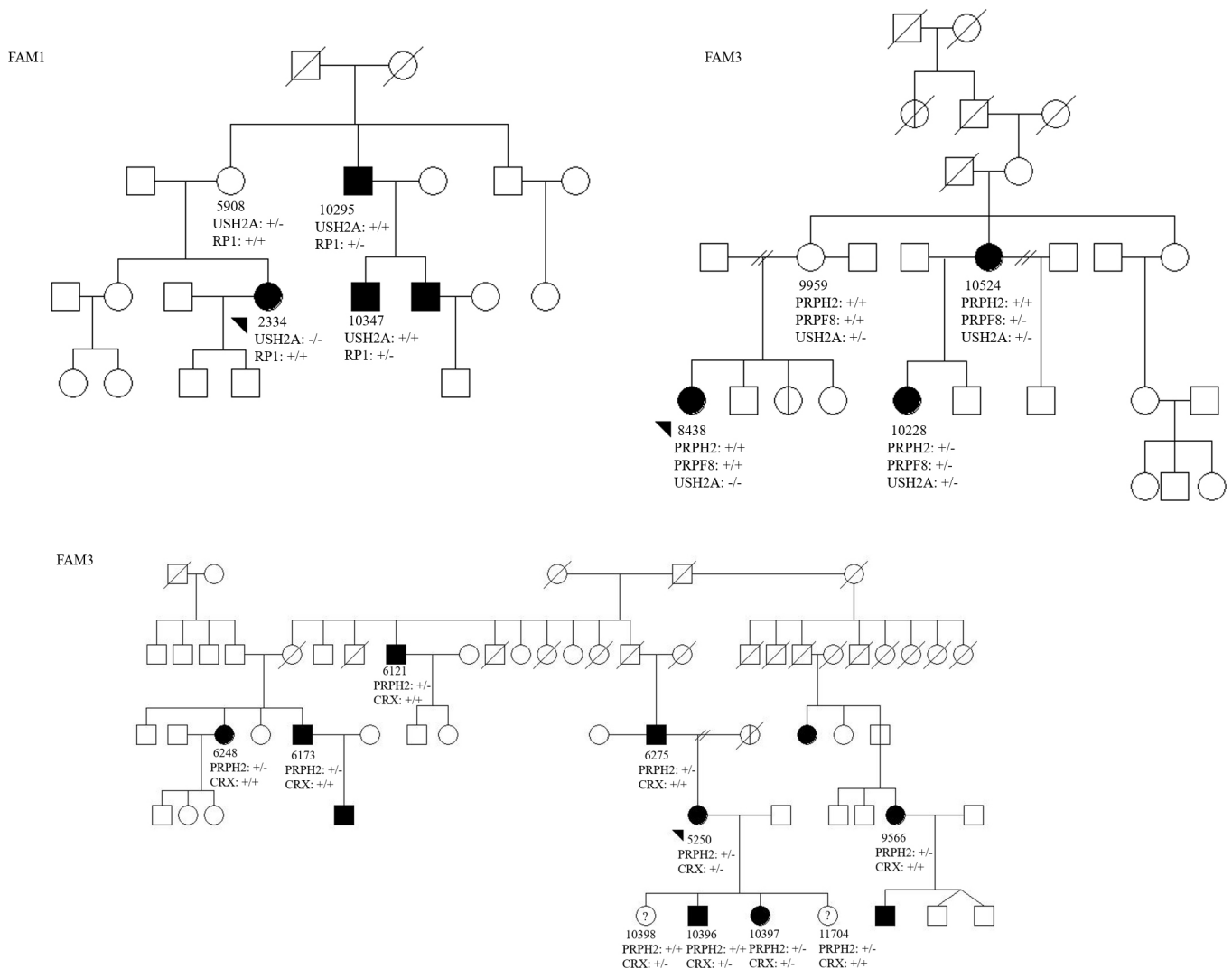


Figure 1. Pedigrees of families clinically diagnosed with autosomal dominant retinitis pigmentosa (adRP) with suspected non-penetrance (FAM1, FAM2) and dominant pedigree (FAM3). Filled symbols indicate diagnosis of RP. Individuals for whom DNA samples were available are indicated with identification (ID) numbers; probands are marked with arrows. ‘-’ indicates the presence of a mutation, and ‘+’ indicates the presence of a wild-type allele, detailed in Table 1.

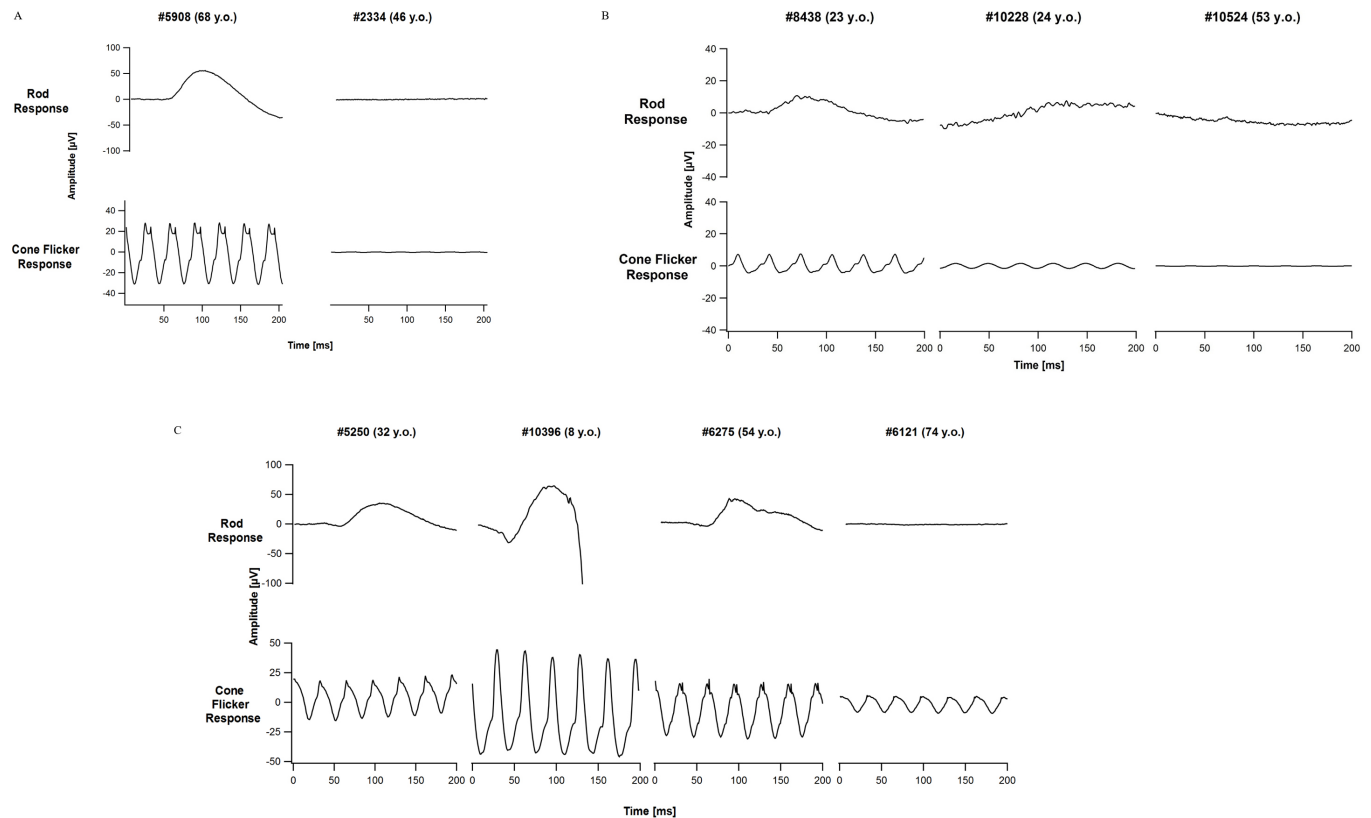


Figure 2. ffERG panels for FAM1, FAM2, and FAM3. **A:** FAM1 unaffected full-field electroretinography (ffERG) cone and rod responses for patient #5908, heterozygous carrier of a mutation in *USH2A*. Non-detectable ffERG rod response and minimally reduced from normal cone response for patient #2334, compound heterozygous for two mutations in *USH2A*. **B:** Three members of FAM2 with reduced-to-minimal rod and cone ERG function. Patient #8438 was found to have two compound heterozygous mutations in *USH2A*, and patient #10228 had mutations in two autosomal dominant retinitis pigmentosa (adRP) genes, *PRPH2* and *PRPF8*, as well as a single, heterozygous mutation in *USH2A*. Patient #10524 had a mutation in one adRP gene, *PRPF8*, as well as a single, heterozygous mutation in *USH2A*. **C:** Four members of FAM3 with varying degrees of ffERG dysfunction. Proband #5250 shows moderately reduced rod and cone responses and was found to harbor mutations in two autosomal dominant genes, *PRPH2* and *CRX*. The proband's son, #10396, had minor ffERG changes at age 8 years and was found to carry the mutation in *CRX*. Two additional family members, #6275 and #6121, carry only a single mutation in *PRPH2* and show reduced-to-minimal ffERG responses.

for the proband's unaffected mother (#5908) are shown for comparison (Figure 2).

Initial sequential Sanger analysis of the FAM1 proband did not identify a disease-causing mutation in an autosomal dominant panel of RP genes. However, testing of additional known affected family members identified a previously reported dominant mutation in *RPI* (Gene ID: 19888, OMIM: 603937) p.Arg677Ter [20,21] that was confirmed in two (#10295 and #10347; vision data not available) of the four affected individuals but absent in the proband and the unaffected, suspected non-penetrant individual (#5908). The fourth affected family member was unavailable for testing. Subsequent retinal gene-targeted NGS testing revealed the proband was a compound heterozygote for two previously reported mutations in *USH2A* (Gene ID: 7399, OMIM:

608400), p.Cys419Phe and p.Glu767Serfs\*21 [13,14,22,23], and her mother, who was believed to be non-penetrant, was a heterozygous carrier of the mutation in *USH2A* p.Cys419Phe. Segregation of the identified mutations is detailed in Table 1.

**FAM2:** Patient #8438 was diagnosed with RP at age 20 years and denied any known or suspected hearing loss. Family history detailed other cases of RP but no hearing loss. Visual function testing of patient #8438 at age 23 years revealed visual acuity of 20/25 in each eye with reduced-to-minimal rod and cone ERG function (Figure 2). Visual field diameter was reduced to less than 15 degrees. Her final dark-adapted threshold was elevated by 1.9 log units with an 11 degree test centrally fixated. The OCT scans showed retention of the photoreceptor layer in the fovea and midperiphery, although midperiphery granularity was notable (Figure 3). Fundus



photography (Figure 3) showed a relatively preserved fundus appearance with sparse bone spicule-like pigment deposits limited to the far periphery. Two additional family members presented with signs consistent with a diagnosis of RP. The proband's aunt, patient #10524, at age 53 years of age showed symptoms consistent with an advanced stage of RP, including non-detectable ffERG responses (Figure 2). OCT images showed thinning of the retina with only remnants of the photoreceptor layer remaining, and fundus photography showed dense mid-periphery bone spicule-like pigment and thinning of the retina (Figure 3). Her daughter, patient #10228, at age 24 years exhibited severe symptoms of RP, including markedly reduced ffERG rod and cone responses, OCT images indicated the photoreceptor layer limited to the fovea and parafovea, and moderate mid-periphery bone spicule-like pigment could be seen on fundus photography.

Initial sequential Sanger sequencing analysis for patient #8438 did not detect a disease-causing mutation in a panel of autosomal dominant RP genes. Subsequent retinal

gene-targeted NGS was initiated in patient #10228 due to sample availability. This testing revealed likely disease-causing mutations in three retinal dystrophy genes (*PRPH2*- Gene ID: 5961 OMIM: 179605, *PRPF8*- Gene ID: 10594 OMIM: 607300, and *USH2A*) within this family. Affected FAM2 individuals each were determined to have a different genotype responsible for their retinal disease.

Patient #10228 was determined to harbor a novel mutation in *PRPF8* and a novel autosomal dominant mutation in *PRPH2*, and additionally carried a heterozygous known mutation in *USH2A* (p.Glu767Serfs\*21). Targeted Sanger sequencing analysis for each of the identified gene mutations was undertaken in the available family members to determine segregation of the mutations. The novel *PRPF8* missense mutation (c.5792C>T, p.Thr1931Met) results in an amino acid substitution that has not been reported in patients or normal control databases. Computational analysis predicts this variant to be pathogenic (PolyPhen = 1.0, SIFT = 0.0, MutationTaster = 0.99, disease causing plus possible splicing

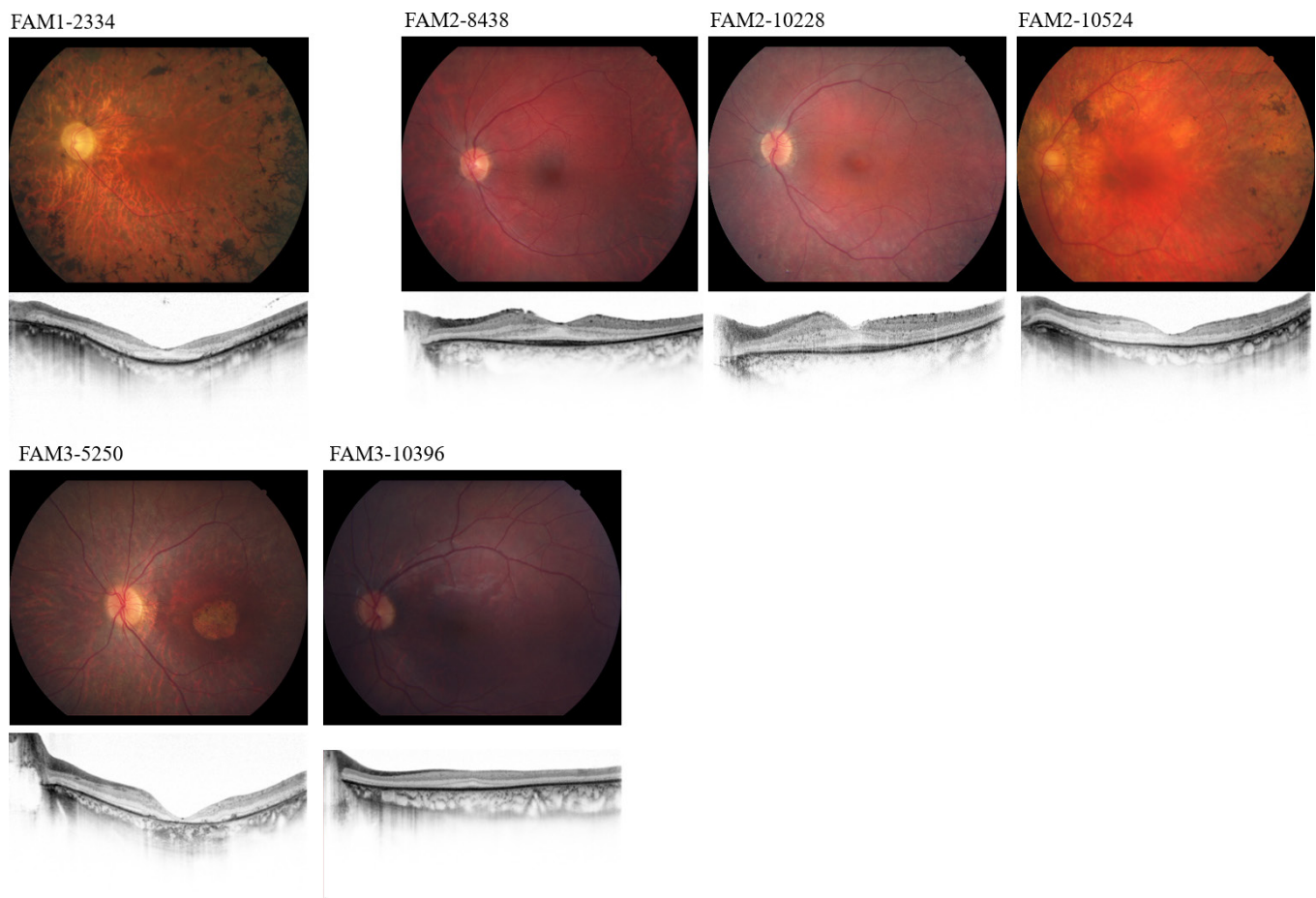


Figure 3. Fundus and SD-OCT images from individuals in three families diagnosed with inherited retinal disease. Representative central views of the left eye and the corresponding spectral domain optical coherence tomography (SD-OCT) image are shown.

TABLE 1. CLINICAL CHARACTERISTICS AND GENOTYPES OF 3 FAMILIES WITH MULTI-ALLELIC INHERITED RETINAL DYSTROPHY.

Subject ID	Age	Sex	Acuity	Gene	mRNA ID, Protein ID	Allele 1	Allele 2	Phenotype
<b>FAM1-2334</b>	33	F	20/50 OD	<i>USH2A</i>	NM_206933.2,	c.2029C>T, p.Cys419Phe Wild-type	c.2299delG, p.Glu767Serifs*21 Wild-type	RP with sensori- neural hearing loss
			20/60 OS	<i>RPI</i>	NP_996816.2, NM_006269.1, NP_006260.1			
FAM1-5908	68	F	20/20 OU	<i>USH2A</i>	NM_206933.2,	c.2029C>T, p.Cys419Phe Wild-type	Wild-type Wild-type	Unaffected
				<i>RPI</i>	NP_996816.2, NM_006269.1, NP_006260.1			
FAM1-10295	80	M	NA	<i>USH2A</i>	NM_206933.2,	Wild-type c.2029C>T, p.Arg677Ter	Wild-type Wild-type	RP
				<i>RPI</i>	NP_996816.2, NM_006269.1, NP_006260.1			
FAM1-10347	54	M	NA	<i>USH2A</i>	NM_206933.2,	Wild-type c.2029C>T, p.Arg677Ter	Wild-type Wild-type	RP
				<i>RPI</i>	NP_996816.2, NM_006269.1, NP_006260.1			
<b>FAM2-8438</b>	23	F	20/25 OU	<i>PRPF2</i>	NM_000322.4,	Wild-type Wild-type c.2299delG, p.Glu767Serifs*21	Wild-type Wild-type c.10342G>A, p.Glu3448Lys	RP
				<i>PRPF8</i>	NP_00313.2			
				<i>USH2A</i>	NM_006445.3, NP_006436.3			
					NM_206933.2, NP_996816.2			
FAM2-10228	24	F	20/32 OD	<i>PRPF2</i>	NM_000322.4,	c.610T>C, p.Tyr204His c.5792C>T, p.Thr1931Met c.2299delG, p.Glu767Serifs*21	Wild-type Wild-type Wild-type	RP
			20/40 OS	<i>PRPF8</i>	NP_00313.2			
				<i>USH2A</i>	NM_006445.3, NP_006436.3			
					NM_206933.2, NP_996816.2			
FAM2-10524	53	F	20/20 OD	<i>PRPF2</i>	NM_000322.4,	Wild-type c.5792C>T, p.Thr1931Met c.2299delG, p.Glu767Serifs*21	Wild-type Wild-type Wild-type	RP
			20/40 OS	<i>PRPF8</i>	NP_00313.2			
				<i>USH2A</i>	NM_006445.3, NP_006436.3			
					NM_206933.2, NP_996816.22			
FAM2-9959	48	F	20/20 OD	<i>PRPF2</i>	NM_000322.4,	Wild-type Wild-type c.2299delG, p.Glu767Serifs*21	Wild-type Wild-type Wild-type	Unaffected
			20/25 OS	<i>PRPF8</i>	NP_00313.2			
				<i>USH2A</i>	NM_006445.3, NP_006436.3			
					NM_206933.2, NP_996816.2			

Subject ID	Age	Sex	Acuity	Gene	mRNA ID, Protein ID	Allele 1	Allele 2	Phenotype
FAM3-5250	32	F	20/50 OU	<i>PRPH2</i> <i>CRX</i>	NM_000322.4, NP_00313.2 NM_000554.5, NP_000545.1	c.647C>T, p.Pro216Leu del exons 3-4	Wild-type Wild-type	Cone-rod dystrophy
FAM3-11704	4	F	20/20 OD 20/20 OS	<i>PRPH2</i> <i>CRX</i>	NM_000322.4, NP_00313.2 NM_000554.5, NP_000545.1	c.647C>T, p.Pro216Leu Wild-type	Wild-type Wild-type	Asymptomatic at ophthalmic exam
FAM3-10396	8	M	20/60 OD 20/25 OS	<i>PRPH2</i> <i>CRX</i>	NM_000322.4, NP_00313.2 NM_000554.5, NP_000545.1	Wild-type del exons 3-4	Wild-type Wild-type	Cone-rod dystrophy
FAM3-10397	3	F	20/32 OD 20/32 OS	<i>PRPH2</i> <i>CRX</i>	NM_000322.4, NP_00313.2 NM_000554.5, NP_000545.1	c.647C>T, p.Pro216Leu del exons 3-4	Wild-type Wild-type	Cone-rod dystrophy
FAM3-10398	6	F	NA	<i>PRPH2</i> <i>CRX</i>	NM_000322.4, NP_00313.2 NM_000554.5, NP_000545.1	Wild-type del exons 3-4	Wild-type Wild-type	No vision evaluation
FAM3-6275	54	M	20/20 OU	<i>PRPH2</i> <i>CRX</i>	NM_000322.4, NP_00313.2 NM_000554.5, NP_000545.1	c.647C>T, p.Pro216Leu Wild-type	Wild-type Wild-type	RP
FAM3-9566	59	F	20/32 OD 20/50 OS	<i>PRPH2</i> <i>CRX</i>	NM_000322.4, NP_00313.2 NM_000554.5, NP_000545.1	c.647C>T, p.Pro216Leu Wild-type	Wild-type Wild-type	RP
FAM3-6121	76	M	20/25 OD 20/40 OS	<i>PRPH2</i> <i>CRX</i>	NM_000322.4, NP_00313.2 NM_000554.5, NP_000545.1	c.647C>T, p.Pro216Leu Wild-type	Wild-type Wild-type	RP
FAM3-6173	50	M	20/20 OD 20/20 OS	<i>PRPH2</i> <i>CRX</i>	NM_000322.4, NP_00313.2 NM_000554.5, NP_000545.1	c.647C>T, p.Pro216Leu Wild-type	Wild-type Wild-type	RP
FAM3-6248	53	F	20/20 OD 20/32 OS	<i>PRPH2</i> <i>CRX</i>	NM_000322.4, NP_00313.2 NM_000554.5, NP_000545.1	c.647C>T, p.Pro216Leu Wild-type	Wild-type Wild-type	RP

RP, retinitis pigmentosa; OD, right eye; OS, left eye; OU, both eyes.

defect) based on its location in a highly conserved functional domain and the prediction that the nucleotide substitution may alter the donor splice site. The novel missense mutation in *PRPH2* (c.610T>C, p.Tyr204His) results in an amino acid change that has not been reported in a patient or normal control databases; this mutation was identified once in the LMDIED laboratory in a patient with dominant retinal disease. The mutation is located at a highly conserved residue in an established functional domain. Computation analysis predicts this to be a pathogenic mutation (PolyPhen = 0.99, SIFT = 0.01, MutationTaster = 0.99, disease-causing). Her affected mother, patient #10524, was found to harbor the novel, autosomal dominant mutation in *PRPF8*. The family denied that the father of #10228 has any symptoms of retinal disease, but to date, he has been unavailable for clinical or genetic testing due to an occupation outside the United States.

Patient #8438 was negative for the identified autosomal dominant RP mutations in *PRPH2* and *PRPF8* but was found to harbor the identified p.Glu767Serfs\*21 mutation in *USH2A*. A subsequent round of retinal gene-targeted NGS confirmed that patient #8438 was a compound heterozygote for previously reported pathogenic mutations in *USH2A*, p.Glu767Serfs\*21 and p.Glu3448Lys [14,22,24,25]. Segregation analysis of the identified mutations in *USH2A* among the three additional family members tested showed that each individual was a heterozygous carrier for one of the mutations in *USH2A*, including patient #8438's mother (#9959) who was formerly believed to be non-penetrant for adRP. Segregation of the identified mutations is detailed in Table 1 and Figure 1.

**FAM3:** The proband (#5250; Figure 1) was diagnosed with cone-rod dystrophy at age 18 years with a family history of RP spanning multiple generations consistent with dominant inheritance. Patient #5250, her son, and two additional family members diagnosed with RP exhibited varying levels of rod and cone ERG dysfunction (Figure 2). Unlike the proband's RP diagnosed family members who demonstrated primarily loss of peripheral rod function followed by cone degeneration as disease progressed, the proband exhibited early onset, primary loss of cone photoreceptors followed by loss of rod function that was widespread across the entire retina. At age 33, patient #5250 had visual acuity of 20/500 OU, and her final dark-adapted threshold was elevated by 5.4 log units with an 11 degree test centrally fixated. OCT scans showed sparse remnants of the photoreceptor layer in the fovea and midperiphery with infrared imaging highlighting an atrophic macular lesion (Figure 3). Fundus photography (Figure 3) illustrated a pronounced macular lesion, granular appearance, and sparse bone spicule-like pigment deposits. RP-affected family members had imaging typically associated with

peripheral retinopathy due to RP. The proband's son (#10396) presented at age 8 years with suspected reduced acuity and visual fields constricted to less than 10 degrees with reduced macular sensitivity, and a multifocal ERG from his referring ophthalmologist noted marked deficits in central retina responses that were consistent with a cone-rod dystrophy phenotype.

Traditional sequential single gene sequencing identified a previously reported heterozygous mutation in *PRPH2* (p.Pro216Leu) [26] tracking with disease in six of the seven affected individuals who were genetically tested. The proband's son, patient #10396, was notably mutation negative for the mutation in *PRPH2*. Subsequent retinal gene-targeted NGS analysis for the FAM3 proband and her son determined that she harbored a novel, heterozygous partial deletion in the *CRX* gene (Gene ID: 1406 OMIM: 602225) that includes at least exons 3 and 4 along with the dominant *PRPH2* mutation, whereas her son harbored only the deletion in the *CRX* gene. The *CRX* deletion was confirmed independently by a commercial laboratory. Although this exact deletion has not been previously reported in literature, multiple missense and nonsense mutations in the *CRX* gene have been reported in the Human Gene Mutation Database as associated with cone-rod dystrophy [27], and a single gross deletion in the *CRX* gene has been previously published in association with Leber congenital amaurosis [28]. The proband's other three children (#10397, #10398, and #11,704) were genetically and clinically tested as available (#10398 was unable to undergo clinical testing due to illness), and each child was found to harbor one or both of the identified mutations. Segregation of the identified mutations is detailed in Table 1 and Figure 1.

## DISCUSSION

Using targeted capture NGS, we are discovering multiple genes contributing to the retinal dystrophy genotypes within a family [19,29,30]. Individuals from FAM1, FAM2, and FAM3 each had the initial provisional diagnosis of RP associated with a likely autosomal dominant pattern of inheritance. Two of the three families contained a potential non-penetrant individual, and the third family had documented phenotypic variability

Traditional Sanger-based sequential, single gene testing of the index case failed to reveal the underlying cause of retinal disease for these families. For FAM1, two different genes accounted for retinal disease in a non-overlapping manner in this relatively small family. The proband in FAM1 presented with typical RP symptoms, including night blindness, reduced visual fields, and bone spicule-like pigmentary deposits, all of which are plausibly consistent with previously



reported phenotypes caused by mutations in *RPI* in dominant RP with and without reduced penetrance [20,31]. The proband's phenotype, which included sensorineural hearing loss from an initially uncertain cause, was ultimately explained, through the use of targeted capture NGS, by mutations in the *USH2A* gene which is associated with syndromic and non-syndromic RP [32-34].

FAM2 and FAM3 presented a far more complex genetic puzzle with disease-causing mutations identified in multiple genes that in some individuals likely contributed concurrently to their retinal dystrophy phenotype. It is not entirely clear what impact having two autosomal dominant gene mutations may have on phenotypic severity or the progression of disease. In FAM2, we observed dominant mutations in *PRPH2* and *PRPF8* in a single individual. The *PRPH2* and *PRPF8* genes have been widely reported to result in intrafamilial phenotype variability, including incomplete penetrance [35-40]. FAM3 was found to have two individuals with dominant mutations in *PRPH2* and *CRX*. The identification of only the dominant *PRPH2* gene was initially determined to be the cause of RP for the family because mutations in the *PRPH2* gene can result in a broad spectrum of phenotypes ranging from RP to adult vitelliform macular dystrophy and even cone-rod dystrophy [35,41].

Inherited retinal diseases are exceptionally heterogeneous with more than 3,500 mutations in more than 80 genes known to cause various forms of non-syndromic retinitis pigmentosa [5]. Autosomal dominant retinitis pigmentosa alone can be caused by mutations in at least 27 genes (<https://sph.uth.edu/retnet/>). Precise clinical diagnosis and detailed pedigree information are the first keys to correct identification of disease-causing mutations. Even with meticulous characterization of the phenotype, considerable variability and overlap of disease presentation in patients with inherited retinal disease can lead to challenges in correctly identifying the disease-causing mutation in individuals. The implementation of NGS platforms in the field of inherited retinal diseases has led to the identification of cases with inconsistencies between initial clinical findings and actual genetic result that required a revision of diagnosis for individuals [41-45]. Intrafamilial variability is not uncommon in families with inherited retinal disease. Even family members with the same causative mutation can show different phenotypes, which can further complicate molecular diagnosis.

In practice, evaluation of a patient or family with an inherited retinal disease can be divided into three overlapping stages: clinical characterization of the patient and available family members, family history including pedigree, and molecular testing. Because of the complexity of inherited

retinal diseases, it is often necessary to reconcile the clinical diagnosis, family diagnosis, and molecular diagnosis. This can best be done in a team approach, ideally in centers that include retinal specialists, genetic counselors, molecular biologists, and other experts.

Families with considerable phenotypic variation or apparent non-penetrant individuals raise the possibility of complex inheritance. Furthermore, these findings underscore that caution should be taken when attributing a single gene disease-causing mutation (or inheritance pattern) to a family as a whole and has implications for directing appropriate genetic testing and genetic counseling. Multiple family members should always undergo independent genetic testing whenever possible. Targeted single gene genetic testing may not be a sufficient prescreening for gene-directed therapies. Until we have a much better understanding of the complexity of RP and related diseases, diagnosis and treatment must be approached with caution and an open mind.

#### ACKNOWLEDGMENTS

Funding for this work was provided by the Foundation Fighting Blindness (DGB, SPD, and RC), The National Eye Institute R01EY009076 (DGB), R01EY007142, (SPD), R01EY022356 (RC), R01EY018571 (RC), The William Stamps Farish Fund (SPD), The Max and Minnie Tomerlin Voelcker Fund, The Herman Eye Fund (SPD), Retinal Research Foundation (RC), and sequencing effort is also supported by the NEI vision core grant P30EY002520 (RC). We thank the family members for their participation in this study. Kaylie Jones and Dianna Wheaton are co-corresponding authors and can be reached at [kwebb@retinafoundation.org](mailto:kwebb@retinafoundation.org) and [dwheaton@retinafoundation.org](mailto:dwheaton@retinafoundation.org), respectively.

#### REFERENCES

1. Haim M. Epidemiology of retinitis pigmentosa in Denmark. *Acta Ophthalmol Scand Suppl* 2002; 233:1-34. [PMID: 11921605].
2. Chang S, Vaccarella L, Olatunji S, Cebulla C, Christoforidis J. Diagnostic challenges in retinitis pigmentosa: Genotypic multiplicity and phenotypic variability. *Curr Genomics* 2011; 12:267-75. [PMID: 22131872].
3. Chizzolini M, Galan A, Milan E, Sebastiani A, Costagliola C, Parmeggiani F. Good epidemiologic practice in retinitis pigmentosa: From phenotyping to biobanking. *Curr Genomics* 2011; 12:260-6. [PMID: 22131871].
4. Collin RW, Safieh C, Littink KW, Shalev SA, Garzosi HJ, Rizel L, Abbasi AH, Cremers FPM, den Hollander AI, Klevering BJ, Ben-Yosef T. Mutations in C2ORF71 cause autosomal-recessive retinitis pigmentosa. *Am J Hum Genet* 2010; 86:783-8. [PMID: 20398884].

5. Daiger SP, Sullivan LS, Bowne SJ. Genes and mutations causing retinitis pigmentosa. *Clin Genet* 2013; 84:132-41. [PMID: 23701314].
6. Williams DS. Usher syndrome: Animal models, retinal function of Usher proteins, and prospects for gene therapy *Vision Res* 2008; 48:433-41. [PMID: 17936325].
7. Hamel C. Retinitis Pigmentosa. *Orphanet J Rare Dis* 2006; 1:40-[PMID: 17032466].
8. Kajiwara K, Berson EL, Dryja TP. Digenic retinitis pigmentosa due to mutations at the unlinked peripherin/RDS and ROM1 loci. *Science* 1994; 264:1604-8. [PMID: 8202715].
9. Dryja TP, Hahn LB, Kajiwara K, Berson EL. Dominant and digenic mutations in the peripherin/RDS and ROM1 genes in retinitis pigmentosa. *Invest Ophthalmol Vis Sci* 1997; 38:1972-82. [PMID: 9331261].
10. Mansergh FC, Millington-Ward S, Kennan A, Kiang AS, Humphries M, Farrar GJ, Humphries P, Kenna PF. Retinitis pigmentosa and progressive sensorineural hearing loss caused by a C12258A mutation in the mitochondrial MTT2 gene. *Am J Hum Genet* 1999; 64:971-85. [PMID: 10090882].
11. Fahim AT, Daiger SP, Weleber RG. Nonsyndromic Retinitis Pigmentosa Overview. 2000 Aug 4 [Updated 2013 Mar 21]. In: Pagon RA, Adam MP, Ardinger HH, editors. *GeneReviews*® [Internet]. Seattle (WA): University of Washington, Seattle; 1993–2016. Available from: <https://www.ncbi.nlm.nih.gov/books/NBK1417/>
12. Simpson DA, Clark GR, Alexander S, Silvestri G, Willoughby CE. Molecular diagnosis for heterogeneous genetic diseases with targeted high-throughput DNA sequencing applied to retinitis pigmentosa. *J Med Genet* 2011; 48:145-51. [PMID: 21147909].
13. Neveling K, Collin RW, Gilissen C, van Huet RA, Visser L, Kwint MP. Next-generation genetic testing for retinitis pigmentosa. *Hum Mutat* 2012; 33:963-72. [PMID: 22334370].
14. O'Sullivan JI, Mullaney BG, Bhaskar SS, Dickerson JE, Hall G, O'Grady A, Webster A, Ramsden SC, Black GC. A paradigm shift in the delivery of services for diagnosis of inherited retinal disease. *J Med Genet* 2012; 49:322-6. [PMID: 22581970].
15. Glöckle N, Kohl S, Mohr J, Scheurenbrand T, Sprecher A, Weisschuh N, Bernd A, Rudolph G, Schubach M, Poloschek C, Zrenner E, Biskup S, Berger W, Wissinger B, Neidhardt J. Panel-based next generation sequencing as a reliable and efficient technique to detect mutations in unselected patients with retinal dystrophies. *Eur J Hum Genet* 2014; 22:99-104. [PMID: 23591405].
16. Wang F, Wang H, Tuan HF, Nguyen DH, Sun V, Keser V, Bowne SJ, Sullivan LS, Luo H, Zhao L, Wang X, Zaneveld JE, Salvo JS, Siddiqui S, Mao L, Wheaton DK, Birch DG, Branham KE, Heckenlively JR, Wen C, Flagg K, Freyreya H, Pei J, Khan A, Ren H, Wang K, Lopez I, Qamar R, Zenteno JC, Ayala-Ramirez R, Buentello-Volante B, Fu Q, Simpson DA, Li Y, Sui R, Silvestri G, Daiger SP, Koenekoop RK, Zhang K, Chen R. Next generation sequencing-based molecular diagnosis of retinitis pigmentosa: identification of a novel genotype-phenotype correlation and clinical refinements. *Hum Genet* 2014; 133:331-45. [PMID: 24154662].
17. Sullivan LS, Bowne SJ, Birch DG, Hughbanks-Wheaton D, Heckenlively JR, Lewis RA, Garcia CA, Ruiz RS, Blanton SH, Northup H, Gire AI, Seaman R, Duzkale H, Spellicy CJ, Zhu J, Shankar SP, Daiger SP. Prevalence of disease causing mutations in families with autosomal dominant retinitis pigmentosa: a screen of known genes in 200 families. *Invest Ophthalmol Vis Sci* 2006; 47:3052-64. [PMID: 16799052].
18. Wang X, Wang H, Sun V, Tuan HF, Keser V, Wang K, Ren H, Lopez I, Zaneveld JE, Siddiqui S, Bowles S, Khan A, Salvo J, Jacobson SG, Iannaccone A, Wang F, Birch D, Heckenlively JR, Fishman GA, Traboulsi EI, Li Y, Wheaton D, Koenekoop RK, Chen R. Comprehensive molecular diagnosis of 179 Leber congenital amaurosis and juvenile retinitis pigmentosa patients by targeted next generation sequencing. *J Med Genet* 2013; 50:674-88. [PMID: 23847139].
19. Daiger SP, Bowne SJ, Sullivan LS, Webb-Jones KD, Birch DG, Avery CE, Wang F, Chen R, Wheaton DK. Retinal targeted-capture next generation sequencing and CLIA confirmation in a representative range of patients with inherited retinal degeneration. ARVO Annual Meeting, May 1-5, 2016, Seattle, WA
20. Sullivan LS, Heckenlively JR, Bowne SJ, Zuo J, Hide WA, Gal A, Denton M, Ingleheam CF, Blanton SH, Daiger SP. Mutations in a novel retina-specific gene cause autosomal dominant retinitis pigmentosa. *Nat Genet* 1999; 22:255-9. [PMID: 10391212].
21. Gamundi MJ, Hernan I, Martinez-gimeno M, Maseras M, Garcia-sandoval B, Ayuso C, Antiñolo G, Baiget M, Carballo M. Three novel and the common Arg677Ter RPI protein truncating mutations causing autosomal dominant retinitis pigmentosa in a Spanish population. *BMC Med Genet* 2006; 7:35-[PMID: 16597330].
22. Eudy JD, Weston MD, Yao S, Hoover DM, Rehm HL, Ma-Edmonds M, Yan D, Ahmad I, Cheng JJ, Ayuso C, Cremers C, Davenport S, Moller C, Talmadge CB, Beisel KW, Tamayo M, Morton CC, Swaroop A, Kimberling WJ, Sumegi J. Mutation of a gene encoding a protein with extracellular matrix motifs in Usher syndrome type IIa. *Science* 1998; 280:1753-7. [PMID: 9624053].
23. Weston MD, Eudy JD, Fujita S, Yao S, Usami S, Cremers C, Greenberg J, Ramesar R, Martini A, Moller C, Smith RJ, Sumegi J, Kimberling WJ. Genomic structure and identification of novel mutations in usherin, the gene responsible for Usher syndrome type IIa. *Am J Hum Genet* 2000; 66:1199-210. [PMID: 10729113].
24. Maranhao B, Biswas P, Duncan JL, Branham KE, Silva GA, Naeem MA, Khan SN, Riazuddin S, Hejtmancik JF, Heckenlively JR, Riazuddin SA, Lee PL1, Ayyagari R. exomeSuite: Whole exome sequence variant filtering tool for rapid identification of putative disease causing SNVs/indels. *Genomics* 2014; 103:169-76. [PMID: 24603341].
25. McGee TL, Seyedahmadi BJ, Sweeney MO, Dryja TP, Berson EL. Novel mutations in the long isoform of the USH2A gene

- in patients with Usher syndrome type II or non-syndromic retinitis pigmentosa. *J Med Genet* 2010; 47:499-506. [PMID: 20507924].
26. Kajiwara K, Han LB, Mukai S, Travis GH, Berson EL, Dryja TP. Mutations in the human retinal degeneration slow gene in autosomal dominant retinitis pigmentosa. *Nature* 1991; 354:480-3. [PMID: 1684223].
  27. Stenson PD, Mort M, Ball EV, Shaw K, Phillips AD, Cooper DN. The Human Gene Mutation Database: building a comprehensive mutation repository for clinical and molecular genetics, diagnostic testing and personalized genomic medicine. *Hum Genet* 2014; 133:1-9. [PMID: 24077912].
  28. Eisenberger T, Neuhaus C, Khan AO, Decker C, Preising MN, Friedburg C, Bieg A, Gliem M, Charbel Issa P, Holz FG, Baig SM, Hellenbroich Y, Galvez A, Platzer K, Wollnik B, Laddach N, Ghaffari SR, Rafati M, Botzenhart E, Tinschert S, Börger D, Bohring A, Schreml J, Körtge-Jung S, Schell- Apacik C, Bakur K, Al-Aama JY, Neuhann T, Herkenrath P, Nürnberg G, Nürnberg P, Davis JS, Gal A, Bergmann C, Lorenz B, Bolz HJ. Increasing the yield in targeted next-generation sequencing by implicating CNV analysis, non-coding exons and the overall variant load: the example of retinal dystrophies. *PLoS One* 2013; 8:e78496-[PMID: 24265693].
  29. Dianna KH. Wheaton, Kaylie D Webb-Jones, Sara J Bowne, Lori S Sullivan, Rui Chen, Stephen P Daiger, David G Birch; Complex Multi-Allelic Inherited Retinal Dystrophy: Multiple Genes Contributing Independently and Concurrently in Extended Families. *Invest Ophthalmol Vis Sci* 2016; 57:3135-.
  30. Kaylie Webb-Jones. Sara J Bowne, Lori S Sullivan, Stephen P Daiger, Feng Wang, Rui Chen, David G Birch, Dianna K H Wheaton; Identification of mutations in three retinal dystrophy genes within a single family: PRPF8, PRPH2 and USH2A. *Invest Ophthalmol Vis Sci* 2015; 56:2887-.
  31. Dietrich K, Jacobi FK, Tippmann S, Schmid R, Zrenner E, Wissinger B, Apfelstedt-Sylla E. A novel mutation of the RPI gene (Lys778Ter) associated with autosomal dominant retinitis pigmentosa. *Br J Ophthalmol* 2002; 86:328-32. [PMID: 11864893].
  32. Seyedahmadi BJ, Rivolta C, Keene JA, Berson EL, Dryja TP. Comprehensive screening of the USH2A gene in Usher syndrome type II and non-syndromic recessive retinitis pigmentosa. *Exp Eye Res* 2004; 79:167-73. [PMID: 15325563].
  33. Ebermann I, Scholl HP, Charbel Issa P, Becirovic E, Lamprecht J, Jurklics B, Millán JM, Aller E, Mitter D, Bolz H. A novel gene for Usher syndrome type 2: mutations in the long isoform of whirlin are associated with retinitis pigmentosa and sensorineural hearing loss. *Hum Genet* 2007; 121:203-11. [PMID: 17171570].
  34. Pierrottet CO, Zuntini M, Digiuni M, Bazzanella I, Ferri P, Paderni R, Rossetti LM, Cecchin S, Orzalesi N, Bertelli M. Syndromic and non-syndromic forms of retinitis pigmentosa: a comprehensive Italian clinical and molecular study reveals new mutations. *Genet Mol Res* 2014; 13:8815-33. [PMID: 25366773].
  35. Renner AB, Fiebig BS, Weber BH, Wissinger B, Andreasson S, Gal A, Cropp E, Kohl S, Kellner U. Phenotypic variability and long term follow-up of patients with known and novel PRPH2/RDS gene mutations. *Am J Ophthalmol* 2009; 147:518-30. [PMID: 19038374].
  36. Martinez-Gimeno M, Gamundi MJ, Hernan I. Mutations in the pre-mRNA splicing-factor genes PRPF3, PRPF8, and PRPF31 in Spanish families with autosomal dominant retinitis pigmentosa. *Invest Ophthalmol Vis Sci* 2003; 44:2171-7. [PMID: 12714658].
  37. van Lith-Verhoeven JJ, van der Velde-Visser SD, Sohocki MM. Clinical characterization, linkage analysis, and PRPC8 mutation analysis of a family with autosomal dominant retinitis pigmentosa type 13 (RP13). *Ophthalmic Genet* 2002; 23:1-12. [PMID: 11910553].
  38. Testa F, Ziviello C, Rinaldi M. Clinical phenotype of an Italian family with a new mutation in the PRPF8 gene. *Eur J Ophthalmol* 2006; 16:779-81. [PMID: 17061239].
  39. Walia S, Fishman GA, Zernant-Rajang J, Raime K, Allikmets R. Phenotypic expression of a PRPF8 gene mutation in a large African American family. *Arch Ophthalmol* 2008; 126:1127-32. [PMID: 18695108].
  40. Maubaret G, Vaclavik V, Mukhopadhyay R, Waseem NH, Churchill A, Holder GE, Webster AR. (2017). Autosomal Dominant Retinitis Pigmentosa with Intrafamilial Variability and Incomplete Penetrance in Two Families Carrying Mutations in PRPF8 AND, 52(13), 9304–9309. <https://doi.org/10.1167/iov.11-8372>.
  41. Huang L, Li S, Xiao X, Jia X, Wang P, Guo X, Zhang Q. Screening for variants in 20 genes in 130 unrelated patients with cone-rod dystrophy. *Mol Med Rep* 2013; 7:1779-85. [PMID: 23563732].
  42. Chiang JP, Lamey T, McLaren T, Thompson JA, Montgomery H, De Roach J. Progress and prospects of next-generation sequencing testing for inherited retinal dystrophy. *Expert Rev Mol Diagn* 2015; 15:1269-75. [PMID: 26394700].
  43. Weisschuh N, Mayer AK, Strom TM, Kohl S, Glockle N, Schubach M, Andreasson S, Bernd A, Birch DG, Hamel CP, Heckenlively JR, Jacobson SG, Kamme C, Kellner U, Kunstmann E, Maffei P, Reiff CM, Rohrschneider K, Rosenberg T, Rudolph G, Vámos R, Varsányi B, Weleber RG, Wissinger B. Mutation Detection in Patient with Retinal Dystrophies Using Targeted Next Generation Sequencing. *PLoS One* 2016; 11:[PMID: 26766544].
  44. Wang X, Feng Y, Li J, Zhang W, Wang J, Lewis R, Wong LJ. Retinal Diseases Caused by Mutations in Genes Not Specifically Associated with the Clinical Diagnosis. *PLoS One* 2016; 11:[PMID: 27788217].
  45. Bravo-Gil N, Méndez-Vidal C, Romero-Pérez L, González-del Pozo M, Rodríguez-de la Rúa E, Dopazo J, Borrego S, Antiñolo G. Improving the management of Inherited Retinal Dystrophies by targeted sequencing of a population-specific gene panel. *Sci Rep* 2016; 6:[PMID: 27032803].

Articles are provided courtesy of Emory University and the Zhongshan Ophthalmic Center, Sun Yat-sen University, P.R. China. The print version of this article was created on 20 July 2017. This reflects all typographical corrections and errata to the article through that date. Details of any changes may be found in the online version of the article.