

Case Report

Fatal convexity and interhemispheric acute subdural hematoma from a falx meningioma: A case report

Tatsuya Tanaka¹, May Pyae Kyaw², Satoshi Anai², Yukinori Takase², Yukari Takase³, Tatsuya Abe⁴, Akira Matsuno¹

¹Department of Neurosurgery, International University of Health and Welfare, School of Medicine, Narita City, Departments of ²Neurosurgery and ³Pathology, Kouhoukai Takagi Hospital, Okawa, ⁴Department of Neurosurgery, Faculty of Medicine, Saga University, Saga, Japan.

E-mail: Tatsuya Tanaka - s96047@hotmail.com; May Pyae Kyaw - maypyaekyaw23@gmail.com; Satoshi Anai - exsatoshi24@gmail.com; Yukinori Takase - takase@kouhoukai.org; Yukari Takase - takasey@kouhoukai.org; Tatsuya Abe - abet@cc.saga-u.ac.jp; Akira Matsuno - akira.dr.ruby@gmail.com



*Corresponding author:

Tatsuya Tanaka,
Department of Neurosurgery,
International University of
Health and Welfare, School of
Medicine, Narita City, Japan.
s96047@hotmail.com

Received: 22 January 2024

Accepted: 22 February 2024

Published: 05 April 2024

DOI

10.25259/SNI_54_2024

Quick Response Code:



ABSTRACT

Background: Hemorrhagic meningiomas are rare. We report a rare case of nontraumatic convexity and interhemispheric acute subdural hematoma (ASDH) caused by a falx meningioma.

Case Description: An 84-year-old woman with a history of atrial fibrillation and hypertension who was taking warfarin presented to our emergency department with a sudden disorder of consciousness. The patient had no traumatic events associated with her symptoms. Computed tomography (CT) revealed right convexity and interhemispheric ASDH, mass lesions in the left frontal lobes, and brain herniation. Contrast-enhanced CT revealed vascular structures within the mass lesion. CT angiography (CTA) revealed no aneurysm or arteriovenous malformation, and the venous phase revealed occlusion in the anterior portion of the superior sagittal sinus. The patient had her right convexity and interhemispheric ASDH removed endoscopically. A mass lesion located on the falx, which was easily bleeding, soft, and suctionable, was immediately detected. Histopathological examination revealed fibrous meningioma, a benign meningioma of the World Health Organization grade 1. Despite undergoing aggressive treatment, the patient's general condition deteriorated.

Conclusion: Hemorrhagic meningiomas can easily be missed with plain CT, and the enhancement effect of CTA and tumor shadow on digital subtraction angiography may not be observed during the acute phase. Surgery for nontraumatic ASDH should be performed considering the possibility that a meningioma causes it.

Keywords: Falx meningioma, Grade 1 meningioma, Interhemispheric acute subdural hematoma, Intratumoral hemorrhage, Nontraumatic acute subdural hematoma

INTRODUCTION

Meningiomas are benign tumors that frequently occur in the central nervous system of adults. The World Health Organization (WHO) classifies roughly 80–90% of meningioma cases as grade 1, implying that these lesions are histologically benign.^[11,17]

Even though these tumors are benign, they might bleed due to radiation therapy, embolization before surgery, or spontaneous events, although the incidence rate of bleeding (1.3–2.4%) is lower than that in malignant tumors.^[13,25]

The most prevalent types of bleeding related to meningiomas are subarachnoid hemorrhage and intracerebral hemorrhage.^[4,21] Notably, the occurrence of subdural hematoma (SDH) is lower,

This is an open-access article distributed under the terms of the Creative Commons Attribution-Non Commercial-Share Alike 4.0 License, which allows others to remix, transform, and build upon the work non-commercially, as long as the author is credited and the new creations are licensed under the identical terms.

©2024 Published by Scientific Scholar on behalf of Surgical Neurology International

with reported rates less than one-fourth of the rates of intracranial hemorrhage in patients with meningioma.^[9] For patients who were found unconscious at onset, the mortality rate was 74.1%.^[26]

In this report, we present a case of falx meningioma that manifested with acute subdural hemorrhage on the convexity and interhemispheric region in a comatose patient with a review of the literature.

CASE DESCRIPTION

An 84-year-old woman with a history of atrial fibrillation and hypertension who was taking warfarin and antihypertensive medications presented to our emergency department with a sudden disorder of consciousness. The patient had no traumatic events associated with her symptoms. On initial assessment, the patient had a Glasgow Coma Scale (GCS) score of 3, with bilateral pupil diameters of 4 mm and a dull light reflex. Computed tomography (CT) revealed right convexity and interhemispheric acute subdural hematoma (ASDH), mass lesions in the left frontal lobes, and brain

herniation [Figure 1]. Contrast-enhanced CT revealed vascular structures within the mass lesion [Figure 2a]. CT angiography (CTA) revealed no aneurysm or arteriovenous malformation [Figure 2b], and the venous phase exhibited occlusion in the anterior portion of the superior sagittal sinus [Figure 2c]. The initial differential diagnosis based on imaging and clinical presentation included traumatic intracranial hemorrhage, hemorrhagic metastatic lesion, primary intra-axial tumor, and hemorrhagic meningioma.

The patient was intubated for airway protection. Tranexamic acid, menatetrenone, and 4-factor prothrombin complex concentrate were intravenously administered. During emergency surgery, a right frontal minicraniotomy and dural incision were performed. The patient had her right convexity and interhemispheric ASDH removed endoscopically. A mass lesion located on the falx, which was easily bleeding, soft, and suctionable, was immediately detected. After the removal of the lesion, bleeding from the falx was stopped through cauterization and packing with gelatin sponge and BioGlue. No other active bleeding points, such as cortical arteries or bridging veins, were observed in the subdural space. Brain

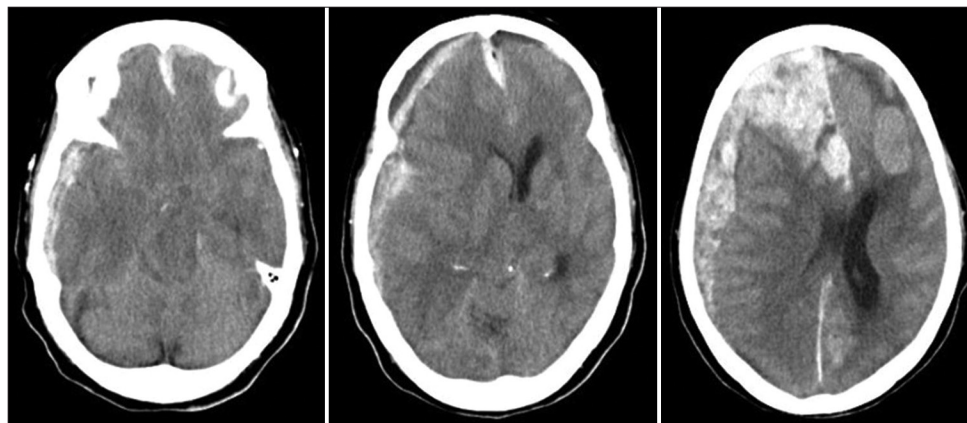


Figure 1: (a-c) Initial head computed tomography reveals right convexity and interhemispheric acute subdural hematoma, (c) mass lesions in the left frontal lobes, and brain herniation.

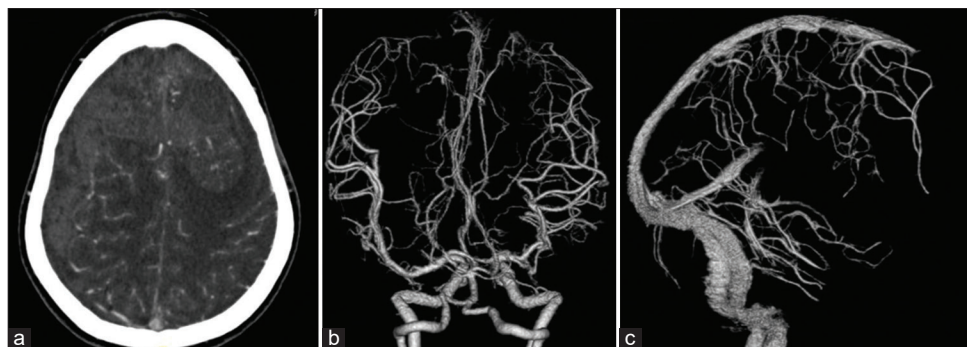


Figure 2: (a) Contrast-enhanced computed tomography (CT) reveals vascular structures within the mass lesion. (b) CT angiography reveals no aneurysm or arteriovenous malformation, and (c) the venous phase reveals occlusion in the anterior portion of the superior sagittal sinus.

Table 1: Reported cases of meningioma presenting with nontraumatic interhemispheric acute subdural hematoma.

Case Year	Author, Age/Sex	Manifesting symptoms	Clinical presentation at the time of bleeding	Type of hematoma	Period from onset to diagnosis, diagnostic method	Location of tumor	Treatment (removal of)	Associated bleeding	Suspected bleeding mechanism	Pathological diagnosis of meningioma	Outcome
1	Sunada, 1998 48/Female	Hemorrhage	Headache and left hemiparesis	ASDH	3 days, MRI→DSA	Parasagittal	Hematoma and tumor	Intratumoral hemorrhage	Rupture of the fragile tumor vessel	Fibrous	Mild disability
2	Okuno, 1999 78/Female	Hemorrhage	Vomiting and disorder of consciousness	ASDH	Not Available, CT→DSA	Falx	Hematoma and tumor	Intratumoral hemorrhage	Vessel rupture caused by vascular stress	Transitional	Mild disability
3	Goyal, 2003 66/Female	Hemorrhage	Headache	ASDH	4 days, CT	Falx	Hematoma and tumor	Not Available	Rupture of the abnormal tumor vessel	Transitional	Good recovery
4	Dalocchio, 2003 73/Female	Hemorrhage	Left hemiparesis and disorder of consciousness	ICH/ASDH	Not Available, CT→MRI	Falx	Hematoma and tumor	Not Available	Not Available	Meningothelial	Mild disability
5	Krishnan, 2015 62/Male	Hemorrhage	Headache and right hemiparesis	ICH/ASDH	2 days, operative finding	Falx	Hematoma and tumor	Not Available	Not Available	Fibrous	Good recovery
6	Suzuki, 2018 61/Female	Hemorrhage	Headache and right hemiparesis	ASDH	21 days, DSA→MRI	Falx	Tumor	Intratumoral hemorrhage	Rupture of the abnormal tumor vessel	Angiomatous	Good recovery
7	Matsuoka, 2019 61/Female	Hemorrhage	Headache	ASDH	33 months, MRI→DSA	Falx	Tumor	Not Available	Rupture of the fragile tumor vessel	Transitional	Good recovery
8	Sato, 2019 68/Male	Hemorrhage	Headache	ICH/ASDH	14 days, DSA→MRI	Falx	Tumor	Intratumoral hemorrhage	Venous hypertension	Transitional	Good recovery
9	Oyamada, 2022 77/Female	Incidental	Right hemiparesis and disorder of consciousness	ICH/ASDH	Diagnosis incidental before onset, MRI	Falx	Hematoma and tumor	Intratumoral hemorrhage	Vessel stretching and rupture	Meningothelial	Severe disability
10	Present case, 2023 84/Female	Hemorrhage	Disorder of consciousness	ASDH	1 day, operative finding	Falx	Hematoma and tumor	Intratumoral hemorrhage	Rupture of the abnormal tumor vessel	Transitional	Dead

swelling was insignificant. Histopathological examination revealed that spindle-shaped tumor cells proliferated in fascicular or storiform patterns with collagenous stroma. The tumor tissue revealed no mitosis, nuclear atypia, and tumor necrosis [Figure 3a]. Furthermore, immunostaining revealed that the tumor cells were positive for epithelial membrane antigen [Figure 3b] and had a Ki-67 labeling index of <3%. These findings suggested a histopathological diagnosis of fibrous meningioma, which is a benign meningioma of the WHO grade 1. Postoperative CT confirmed the successful removal of the right frontal tumor and ASDH [Figure 4]. Despite undergoing aggressive treatment, the patient's general condition deteriorated. The patient ultimately died with a postoperative GCS score of 3.

DISCUSSION

The overall intratumoral hemorrhage rate for brain tumors is 14.6%, with a significant difference in the hemorrhage rate among different histological tumor types.^[8] In addition, recent studies report that anticoagulant therapy is associated with hemorrhage rates. Hemorrhage rates in glioblastoma and metastatic disease are 2.5% and 37%, respectively, with the rates being 14.7% and 44% with anticoagulant use, respectively.^[5,12] Intracranial hemorrhage associated with meningioma is rare. Among them, meningioma accompanied by interhemispheric acute SDH is exceedingly

rare; to date, only ten cases, including this case, have been reported [Table 1].^[3,6,9,14,16,19,22-24] Among these cases, 80% involved female patients, with a mean age of 68 years (range: 48–84 years). Bleeding usually occurs when the tumor is initially detected. Most symptoms during bleeding were headaches, which ranged in severity from mild to severe. In five of the ten cases, the cause was bleeding due to suspected disruption of the tumor vessels. Patient prognosis is related to the clinical presentation during bleeding. If the initial symptom is consciousness disturbance, the prognosis is poor.

Several hypotheses have been proposed to explain the mechanism of meningioma growth accompanied by massive ASDH. They include the following: (1) disruption of tumor vessels due to tumor growth; (2) disruption of bridging veins due to tumor growth; (3) direct invasion of tumor cells into blood vessels; (4) release of vasoactive substances by tumor cells; (5) disruption of bridging veins due to local venous hypertension caused by a secondary condition, such as Valsalva maneuver or cough; and (6) anticoagulant or antiplatelet medications, blood dyscrasias, or hypertension.^[6,14,18,19,20,22,23]

In our case, the tumor was not identified as a pathologically malignant meningioma and lacked an obvious traumatic mechanism. Furthermore, in this case, the occlusion of the venous sinuses and deep veins due to the meningioma may have increased intratumoral venous pressure. Furthermore, the use of anticoagulant drugs and hypertension may have led to significant bleeding due to the delicate nature of the tumor vessels. Diagnosing meningiomas is typically straightforward based on clinical presentation and conventional radiological findings.^[10,15] However, hemorrhagic meningiomas can be misdiagnosed or completely missed in clinical practice. According to a recent review, the primary misdiagnoses included subdural hematoma (27.3%) and traumatic hematoma (13.6%).^[7] Multiple factors may contribute to the difficulty in making a correct diagnosis. A large, sudden blood clot (appearing bright on CT and T1-weighted imaging) may hide a small underlying tumor or appear too bright on noncontrasted

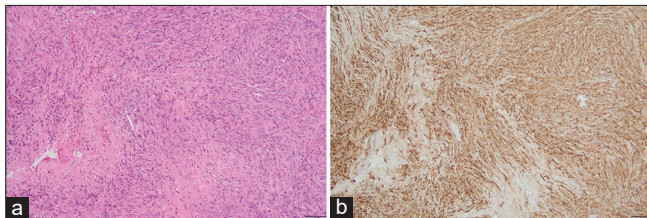


Figure 3: (a) Hematoxylin and eosin stains revealing spindle-shaped tumor cell proliferation in fascicular or storiform pattern with collagenous stroma. (b) Immunostaining revealing tumor cells positive for epithelial membrane antigen.

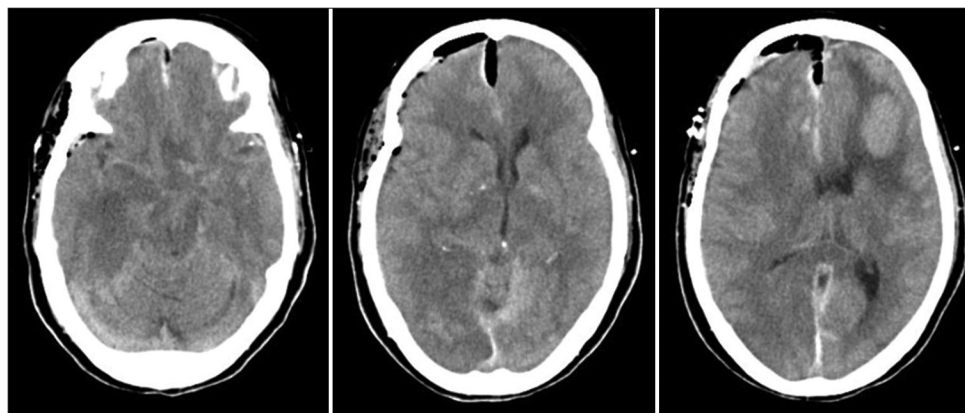


Figure 4: Postoperative computed tomography reveals removal of acute subdural hematoma.

imaging to detect any contrast enhancement. Moreover, tumor staining may not be visible on CTA or digital subtraction angiography (DSA) due to direct vessel compression caused by the hematoma or local intracranial pressure elevation.^[1,2]

Our case started with clinical findings and was systematically approached with CT and then CTA; however, magnetic resonance imaging (MRI) was not possible due to emergency surgery. Due to the possibility of the presence of nontraumatic intracranial hemorrhage, the surgical field was carefully observed, and ASDH due to meningioma was diagnosed during surgery. Imaging findings that are not typical of a simple traumatic hematoma may indicate meningioma hemorrhage, and neurosurgeons should be alert to these signs, particularly in patients requiring emergency surgery where preoperative MRI is not possible. For patients with intracranial hemorrhage who do not require urgent workup or treatment, contrast-enhanced MRI should be performed for further investigation.

CONCLUSION

We report a rare case of falx meningioma caused by nontraumatic convexity and interhemispheric ASDH. Hemorrhagic meningiomas can be easily missed with plain CT, and the enhancement effect of CTA and tumor shadow on DSA may not be observed during the acute phase. Surgery for nontraumatic ASDH should be performed considering the possibility that a meningioma causes it.

Ethical approval

The Institutional Review Board approval is not required.

Declaration of patient consent

The authors certify that they have obtained all appropriate patient consent.

Financial support and sponsorship

Nil.

Conflicts of interest

There are no conflicts of interest.

Use of artificial intelligence (AI)-assisted technology for manuscript preparation

The authors confirm that there was no use of artificial intelligence (AI)-assisted technology for assisting in the writing or editing of the manuscript and no images were manipulated using AI.

REFERENCES

1. Alghabban FA, Alhamss YJ, Farag AA, Alfahmi JA, Al-Saiari SA, Alghamdi F, *et al.* Incidental intraoperative finding of meningioma in spontaneous acute subdural hematoma: A case report from Saudi Arabia and review of literature. *Int J Surg Case Rep* 2020;77:314-7.
2. Basil G, Urakov T, Knudsen MG, Morcos J. Jugular tubercle meningioma with hemorrhagic conversion mimicking a ruptured thrombosed giant vertebrobasilar aneurysm. *World Neurosurg* 2018;119:108-12.
3. Dallochio C, Borutti G, Frascaroli G, Camana C, Magrotti E. A sudden bleeding meningioma. *Neurol Sci* 2003;23:327-8.
4. Di Rocco F, Mannino S, Puca A, Lauriola L, Pompucci A. Intracranial meningiomas associated with non-traumatic chronic subdural hematoma. *Acta Neurochir (Wien)* 2006;148:1097-102.
5. Donato J, Campigotto F, Uhlmann EJ, Coletti E, Neuberger D, Weber GM, *et al.* Intracranial hemorrhage in patients with brain metastases treated with therapeutic enoxaparin: A matched cohort study. *Blood* 2015;126:494-9.
6. Goyal A, Singh AK, Kumar S, Gupta V, Singh D. Subdural hemorrhage associated with falcine meningioma. *Neurol India* 2003;51:419-21.
7. Huang RB, Chen LJ, Su SY, Wu X, Zheng YG, Wang HP, *et al.* Misdiagnosis and delay of diagnosis in hemorrhagic meningioma: A case series and review of the literature. *World Neurosurg* 2021;155:e836-46.
8. Kondziolka D, Bernstein M, Resch L, Tator CH, Fleming JF, Vanderlinden RG, *et al.* Significance of hemorrhage into brain tumors: Clinicopathological study. *J Neurosurg* 1987;67:852-7.
9. Krishnan P, Jena M, Kartikueyan R. Occult falcine meningioma unmasked following nearly complete hemorrhagic transformation with resultant spontaneous acute interhemispheric subdural hematoma. *J Neurosci Rural Pract* 2015;6:91-3.
10. Krishnan V, Mittal MK, Sinha M, Thukral BB. Imaging spectrum of meningiomas: A review of uncommon imaging appearances and their histopathological and prognostic significance. *Pol J Radiol* 2019;84:e630-53.
11. Louis DN, Ohgaki H, Wiestler OD, Cavenee WK, Burger PC, Jouvet A, *et al.* The 2007 WHO classification of tumours of the central nervous system. *Acta Neuropathol* 2007;114:97-109.
12. Mantia C, Uhlmann EJ, Puligandla M, Weber GM, Neuberger D, Zwicker JJ. Predicting the higher rate of intracranial hemorrhage in glioma patients receiving therapeutic enoxaparin. *Blood* 2017;129:3379-85.
13. Martinez-Lage JF, Poza M, Martinez M, Esteban JA, Antunez MC, Sola J. Meningiomas with haemorrhagic onset. *Acta Neurochir (Wien)* 1991;110:129-32.
14. Matsuoka G, Eguchi S, Ryu B, Tominaga T, Ishikawa T, Yamaguchi K, *et al.* Treatment strategy for recurrent hemorrhage from meningioma: Case report and literature review. *World Neurosurg* 2019;124:75-80.
15. Miki K, Kai Y, Hiraki Y, Kamano H, Oka K, Natori Y. Malignant meningioma mimicking chronic subdural hematoma. *World Neurosurg* 2019;124:71-4.
16. Okuno S, Touho H, Ohnishi H, Karasawa J. Falx meningioma presenting as acute subdural hematoma: Case report. *Surg Neurol* 1999;52:180-4.

17. Ostrom QT, Cioffi G, Gittleman H, Patil N, Waite K, Kruchko C, *et al.* CBTRUS statistical report: Primary brain and other central nervous system tumors diagnosed in the United States in 2012-2016. *Neuro Oncol* 2019;21:v1-100.
18. Omar AT 2nd, Starreveld YP. Meningiomas associated with subdural hematoma: A systematic review of clinical features and outcomes. *World Neurosurg* 2022;158:e465-75.
19. Oyamada K, Ohbuchi H, Nishiyama K, Imazato D, Inazuka M, Hagiwara S, *et al.* Acute subdural hematoma associated with disruption of tumor vessels due to rapid growth of falx meningioma: A case report and literature review. *Surg Neurol Int* 2022;13:495.
20. Pressman E, Penn D, Patel NJ. Intracranial hemorrhage from meningioma: 2 novel risk factors. *World Neurosurg* 2020;135:217-21.
21. Pelz D, Levine AB, MacDougall KW. Subdural hematoma: A rare presentation of a convexity meningioma. *Can J Neurol Sci* 2014;41:506-7.
22. Sato K, Matsuo A, Hiu T, Kurohama H, Miura S, Ito K, *et al.* Falx meningioma presenting with intratumoral hemorrhage and interhemispheric acute subdural hematoma: A case of report. *No Shinkei Geka* 2020;48:413-22.
23. Suzuki Y, Fujimoto M, Kawakita F, Asakura F, Murata H, Morooka Y, *et al.* Tiny falx meningioma causing massive interhemispheric subdural hematoma: A case report. *NMC Case Rep J* 2018;5:51-5.
24. Sunada I, Nakabayashi H, Matsusaka Y, Yamamoto S. Meningioma associated with acute subdural hematoma--case report. *Radiat Med* 1998;16:483-6.
25. Wakai S, Yamakawa K, Manaka S, Takakura K. Spontaneous intracranial hemorrhage caused by brain tumor: Its incidence and clinical significance. *Neurosurgery* 1982;10:437-44.
26. Whittle IR, Smith C, Navoo P, Collie D. Meningiomas. *Lancet* 2004;363:1535-43.

How to cite this article: Tanaka T, Kyaw MP, Anai S, Takase Y, Takase Y, Abe T, *et al.* Fatal convexity and interhemispheric acute subdural hematoma from a falx meningioma: A case report. *Surg Neurol Int.* 2024;15:115. doi: 10.25259/SNI_54_2024

Disclaimer

The views and opinions expressed in this article are those of the authors and do not necessarily reflect the official policy or position of the Journal or its management. The information contained in this article should not be considered to be medical advice; patients should consult their own physicians for advice as to their specific medical needs.