

[ CASE REPORT ]

## Correction of Hypercortisolemia with an Improved Cognitive Function and Muscle Mass after Transsphenoidal Surgery in an Older Patient with Cushing's Disease

Ryo Terayama<sup>1</sup>, Takahiro Ishikawa<sup>1,3</sup>, Kazuki Ishiwata<sup>1</sup>, Ai Sato<sup>1</sup>, Takuya Minamizuka<sup>1</sup>, Tomohiro Ohno<sup>1</sup>, Satomi Kono<sup>1</sup>, Masashi Yamamoto<sup>1</sup>, Hidetaka Yokoh<sup>1</sup>, Hidekazu Nagano<sup>4</sup>, Masaya Koshizaka<sup>1</sup>, Sawako Suzuki<sup>1</sup>, Hisashi Koide<sup>1</sup>, Yoshiro Maezawa<sup>1</sup> and Koutaro Yokote<sup>1</sup>

### Abstract:

Cushing's disease causes numerous metabolic disorders, cognitive decline, and sarcopenia, leading to deterioration of the general health in older individuals. Cushing's disease can be treated with transsphenoidal surgery, but thus far, surgery has often been avoided in older patients. We herein report an older woman with Cushing's disease whose cognitive impairment and sarcopenia improved after transsphenoidal surgery. Although cognitive impairment and sarcopenia in most older patients show resistance to treatment, our case indicates that normalization of the cortisol level by transsphenoidal surgery can be effective in improving the cognitive impairment and muscle mass loss caused by Cushing's disease.

**Key words:** Cushing's disease, older people, cognitive impairment, sarcopenia, transsphenoidal surgery

(Intern Med 61: 3391-3399, 2022)

(DOI: 10.2169/internalmedicine.8326-21)

### Introduction

Cushing's disease is a rare disorder with an incidence of 1.2-1.7 per million population per year (1). The pathological increase in circulating cortisol levels due to excessive secretion of adrenocorticotropic hormone (ACTH) leads to serious comorbidities, such as hypertension, abnormal glucose metabolism, lipid abnormalities, and bone mineral density loss. Cushing's disease also leads to various neurocognitive deficits, such as memory loss, impaired reasoning, compromised visual and spatial information processing, and verbal intellectual abilities (2, 3). Furthermore, catabolic hormones, such as cortisol, are involved in muscle degeneration, thus accelerating age-related muscle atrophy (4). In addition, elevated levels of cortisol are the secondary cause of sarcopenia. In summary, Cushing's disease has a high potential to

cause deterioration of the general health status, leading to a decreased quality of life, especially in older individuals.

The treatment for Cushing's disease is transsphenoidal surgery (TSS). However, performing TSS in older patients is often avoided due to the increased risk of mortality and other factors (5).

We herein report an older woman with Cushing's disease who showed improvement in cognitive dysfunction and muscle mass after TSS.

### Case Report

A 67-year-old woman was hospitalized for heart failure at another hospital. On the 28th hospital day, she developed emphysematous cystitis and was transferred to the Department of Urology in our hospital. Computed tomography showed incidental bilateral enlargement of the adrenal

<sup>1</sup>Department of Endocrinology, Hematology, and Gerontology, Chiba University Graduate School of Medicine, Japan, <sup>2</sup>Department of General Medical Science, Chiba University Graduate School of Medicine, Japan, <sup>3</sup>Geriatric Medical Center, Chiba University Hospital, Japan and <sup>4</sup>Department of Molecular Diagnosis, Graduate School of Medicine, Chiba University, Japan

Received: July 12, 2021; Accepted: March 21, 2022; Advance Publication by J-STAGE: April 30, 2022

Correspondence to Dr. Takahiro Ishikawa, tak.ishikawa.vla@chiba-u.jp

**Table 1. Laboratory Data before Surgery.**

	Preoperative
White blood cell count (/ $\mu$ L)	4,500
Segmented (%)	73.8
Eosinophil (%)	0.9
Basophil (%)	0.2
Monocyte (%)	8.6
Lymphocyte (%)	16.5
Hemoglobin (g/dL)	8.7
Platelet count ( $10^4/\mu$ L)	33.9
Total protein (g/dL)	5.8
Albumin (g/dL)	3.3
Aspartate aminotransferase (U/L)	18
Alanine aminotransferase (U/L)	26
Blood urea nitrogen (mg/dL)	16
Creatinine (mg/dL)	0.40
Na (mEq/L)	143
K (mEq/L)	3.9
Cl (mEq/L)	107
Triglyceride (mg/dL)	68
High-density lipoprotein cholesterol (mg/dL)	45
Low-density lipoprotein cholesterol (mg/dL)	80
Glucose (mg/dL)	124
HbA1c (%)	8.7
C-peptide immunoreactivity (ng/mL)	0.63

glands. She exhibited elevated ACTH (49.6 pg/mL) and cortisol levels (23.3  $\mu$ g/dL). After treatment of emphysematous cystitis, she was transferred to our department under suspicion of Cushing's disease.

Her medical history was significant and included 40 years of hypertension, 27 years of diabetes mellitus, and thoracolumbar compression fracture at 65 years old. She had taken medication for hypertension, diabetes mellitus, osteoporosis, dyslipidemia, and paroxysmal atrial fibrillation. About a year ago, her cognitive function began to decline rapidly, and her diabetes control worsened. The medication for diabetes mellitus included multiple daily insulin injections (insulin aspart, 6 units before breakfast, 5 units before lunch, and 4 units before supper, and 14 units of insulin degludec before bedtime) and sitagliptin 50 mg. Her family history was remarkable for hypertension in her father and younger brother and diabetes mellitus for her mother and elder sister.

A physical examination revealed that her height was 145 cm, body weight was 48.8 kg, temperature was 36.2°C, blood pressure was 134/67 mmHg, and heart rate was 62 beats/min. She had moon face and skin thinning. No central obesity, buffalo hump, or stretch marks were present.

Her routine laboratory data is shown in Table 1. Her hemoglobin A1c (HbA1c) level was high (8.7%). Her C-peptide index (C-peptide/plasma glucose) was 0.51. Her endocrinological data are shown in Table 2. Her plasma ACTH levels in the morning (56.9 pg/mL) and at midnight (34.7 pg/mL) were elevated. Her prolactin level was elevated (59.89 ng/mL). Her levels of other pituitary hormones were

normal. Her plasma cortisol levels in the morning (19.0  $\mu$ g/dL) and at midnight (16.8  $\mu$ g/dL) were elevated. Her dehydroepiandrosterone-sulfate (DHEA-S) levels were elevated (280  $\mu$ g/dL). Her urinary free cortisol concentration was elevated (127  $\mu$ g/day).

The overnight low-dose (0.5 mg) dexamethasone suppression test (DST) revealed non-suppressed cortisol levels (10.2  $\mu$ g/dL), although the overnight high-dose (8 mg) DST revealed suppressed cortisol levels (2.7  $\mu$ g/dL). The corticotropin-releasing hormone (CRH) load test revealed that ACTH responded to CRH: plasma ACTH levels were 46.4 pg/mL at baseline and peaked at 126 pg/mL at 60 minutes (Table 3). Magnetic resonance imaging (MRI) showed a 6-mm tumor in the left lobe of the pituitary (Fig. 1).

We performed inferior petrosal sinus sampling (Table 4). The left petrosal/peripheral ratio at baseline (2.33) was  $\geq 2$ , and the ratio at 3 minutes after CRH loading (27.3) was  $\geq 3$ . These findings indicated Cushing's disease.

TSS was performed, and an ACTH-producing adenoma was confirmed pathologically (Fig. 2). The tumor cells with nuclear enlargement and pale eosinophilic cytoplasm were distributed in an alveolar pattern, bordered by thin interstitium with intervening blood vessels. She required supplementation with hydrocortisone 30 mg daily after the operation.

Before the operation, her Mini-Mental State Examination (MMSE) score was 17 points (Table 5). MRI showed extensive atrophy of the cerebrum (Fig. 3). Using N-isopropyl-p-[ $^{123}$ I]-iodoamphetamine single-photon emission computed tomography ( $^{123}$ I-IMP SPECT), mild blood flow reduction was observed in a wide area of the cerebrum, in addition to the posterior cingulate gyrus and the parietal lobe - areas often affected in Alzheimer's disease (Fig. 4). Her grip strength was 10 kg on both sides, and the skeletal muscle mass index (SMI) measured with a bioelectrical impedance analysis was 5.175 kg/m<sup>2</sup>. Therefore, she was diagnosed with cognitive impairment and sarcopenia.

Six months post-surgery, she was hospitalized for a post-operative evaluation. The dose of hydrocortisone was gradually reduced in the outpatient department and was 10 mg at admission. No moon face or skin thinning was present. No residual tumor or recurrence was observed on MRI (Fig. 1). The post-operative endocrinologic examination results were markedly improved compared with the preoperative results (Table 2, 3). These results indicated remission of Cushing's disease.

Interestingly, several changes related to cognitive impairment and sarcopenia were observed. The MMSE score improved by 21 points (Table 5), while "Orientation to time," "Registration," "Recall," and "Repetition" improved, and "Reading and obey" deteriorated. MRI-determined brain atrophy did not improve, and no morphological changes in the hippocampus were observed (Fig. 3). However,  $^{123}$ I-IMP SPECT (Fig. 4) and a three-dimensional stereotactic surface projections (3D-SSP) analysis using  $^{123}$ I-IMP SPECT (Fig. 5) showed an improved blood flow in the frontal, parietal, and

**Table 2. Endocrinological Data.**

Hormone replacement therapy	Preoperative	6 months after operation
	None	Hydrocortisone 10 mg
GH (ng/mL)	0.85	1.89
IGF-1 (ng/mL)	53	92
LH (mIU/mL)	10.02	14.93
FSH (mIU/mL)	42.37	39.49
PRL (ng/mL)	59.89	49.27
TSH ( $\mu$ IU/mL)	1.296	3.534
Free T3 (pg/mL)	1.76	3.07
Free T4 (ng/dL)	0.93	0.94
ACTH (pg/mL)	56.9	13.2
Cortisol ( $\mu$ g/dL)	19.0	4.6
DHEA-S ( $\mu$ g/dL)	280	16
Urinary free cortisol ( $\mu$ g/day)	127	6.9
Midnight plasma ACTH (pg/mL)	34.7	<5.0
Midnight plasma cortisol ( $\mu$ g/dL)	16.8	<1.0
Overnight low-dose DST		
ACTH (pg/mL)	22.1	<5.0
Cortisol ( $\mu$ g/dL)	10.2	<1.0
Overnight high-dose DST		
ACTH (pg/mL)	12.5	<5.0
Cortisol ( $\mu$ g/dL)	2.7	<1.0

DST: dexamethasone suppression test

**Table 3. Corticotropin Releasing Hormone (CRH) Load Test.**

	Time (minutes)					
	0	15	30	60	90	120
Preoperative						
ACTH (pg/mL)	46.4	84.3	112	126	89	65.2
Cortisol ( $\mu$ g/dL)	17.6	25	30.9	33.6	30.8	28.3
6 months after operation						
ACTH (pg/mL)	12.9	28.4	33.3	25.8	21.8	24.6
Cortisol ( $\mu$ g/dL)	3.9	10.2	11.7	11.2	9.8	10.3

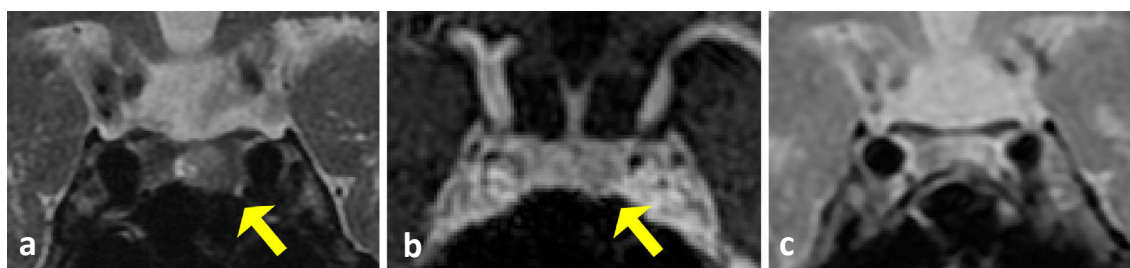hippocampal lobes. The grip strength did not change significantly, but the SMI measured by a bioelectrical impedance analysis increased to 5.432 kg/m<sup>2</sup>. The total muscle mass of both lower limbs increased from 8.19 to 8.60 kg. The Functional Independence Measure (FIM) improved from 63 to 82 points. She was able to walk with a walker after the surgery, whereas she had been using a wheelchair before the surgery, and her exercise tolerance improved. Complications also showed changes, especially with regard to improvement in HbA1c from 8.7% to 7.4% (Table 6).

## Discussion

In this study, we encountered an older patient with Cushing's disease who underwent surgical treatment and experienced improvement in the cognitive function and sarcopenia after TSS. To our knowledge, this is the first report of improvement in both the cognitive and physical function in an

older patient with Cushing's disease.

Only a few reports have evaluated the effects of surgical treatment on cognitive dysfunction caused by Cushing's disease, and they were all limited to patients under 65 years old. Among the cognitive functions, the immediate memory, delayed replay, and repetition are particularly impaired in patients with Cushing's disease (6). Notably, the present patient showed improvement in these three parameters post-operatively, suggesting that Cushing's disease affects a specific part of the cognitive function and may be reversible. Furthermore, the cerebral blood flow improved after surgery. It has been reported that brain glucose consumption is decreased in Cushing's disease, and plasma cortisol levels are negatively correlated with fluorodeoxyglucose positron emission tomography (FDG-PET) signals in the frontal lobe, parietal lobe, and limbic system (7, 8). Therefore, these cerebral regions may be susceptible to cortisol-mediated damage. In addition, the blood flow measured by <sup>123</sup>I-IMP



**Figure 1.** Pituitary magnetic resonance imaging (MRI) in T2-weighted coronal images (a) and gadolinium-enhanced T1-weighted coronal images (b) revealing a 6-mm tumor (arrows). Six months after operation, pituitary MRI in T2-weighted coronal images (c) showed no residual tumor.

**Table 4.** Inferior Petrosal Sinus Sampling.

Time (minutes)	ACTH (pg/mL)				
	Right petrosal	R/P	Left petrosal	L/P	Peripheral
0	33.2	1.14	67.5	2.33	29
3	171	2.94	1,591	27.3	58.2
5	170	2.53	834	12.4	67.2
10	183	2.28	484	6.03	80.2
15	206	2.12	496	5.10	97.3

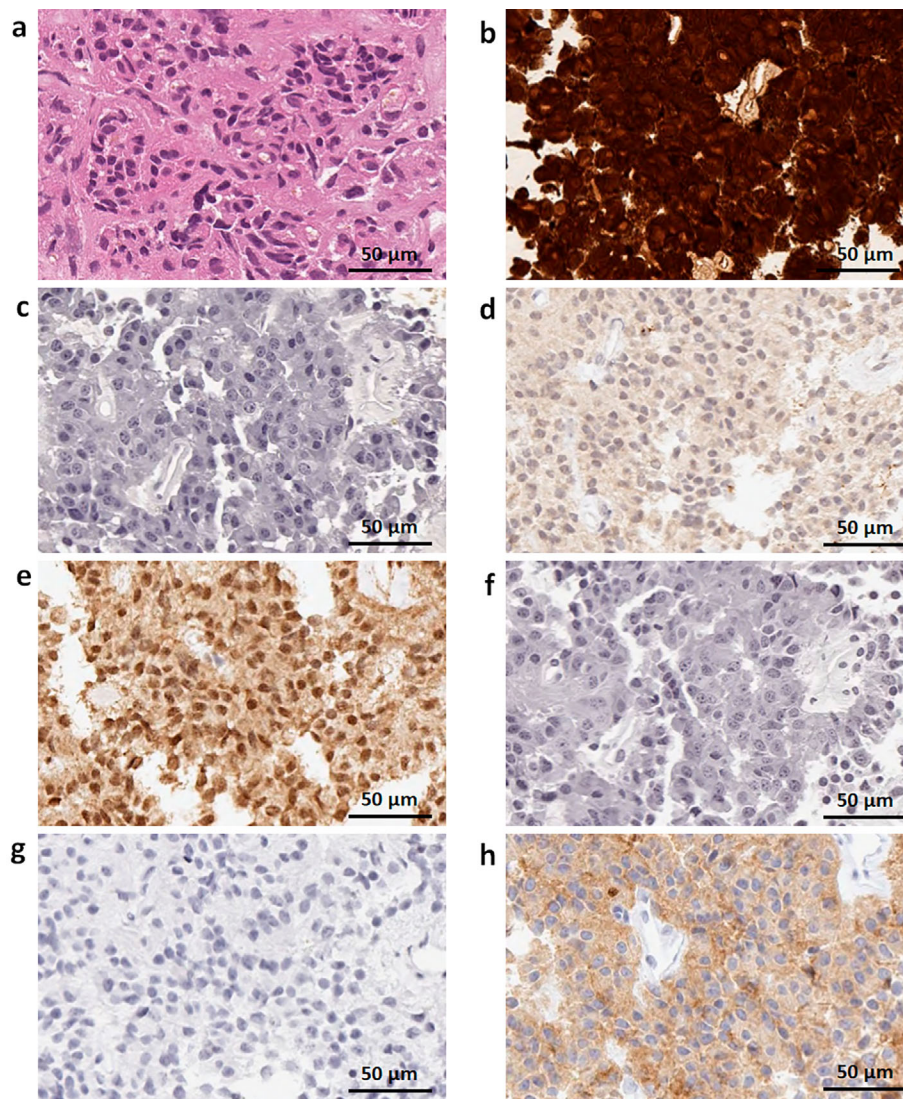
SPECT improved in the frontal and parietal lobes after surgery on our patient. In a study that evaluated the cerebral blood flow using the 3D pseudo-continuous arterial spin labeling method in patients before and after treatment, the cerebral blood flow was found to be significantly reduced in cortical regions, such as the occipital and parietal lobes, in patients before treatment compared to controls (9). Furthermore, the cerebral blood flow was restored after surgery to the same level as in the control group, and the amount of change in blood flow restoration after surgery correlated with the amount of change in 24-h urinary free cortisol after surgery. This result reinforces our findings. Taken together, these results suggest that the restoration of the blood flow and glucose consumption in the areas strongly affected by steroids after surgery may have contributed to the improvement of the cognitive function.

The detailed mechanism by which glucocorticoid excess leads to the decreased cerebral blood flow is not fully understood, but it has been speculated that glucocorticoid receptors are involved. Glucocorticoid receptors are widely distributed throughout the brain (10), and it is thought that patients with Cushing's disease are exposed to excessive glucocorticoids via glucocorticoid receptors, resulting in metabolic abnormalities and a decreased blood flow throughout the brain. The fact that the amount of change in blood flow recovery before and after surgery correlates with the amount of change in 24-h urinary free cortisol before and after surgery also reinforces this speculation. Recently, it has also been reported that changes in the cerebral blood flow in response to increases or decreases in metabolic demand are regulated by the neurovascular unit, which is composed of neurons, glial cells, and vascular endothelial

cells (11). Hypercortisolemia affects the shape of dendrites of neurons via glucocorticoid receptors, resulting in the loss of synapses (12). The proliferation of astrocytes, a type of glial cell, is also severely inhibited by prolonged excessive glucocorticoid action via glucocorticoid receptors (13). Furthermore, it has been shown that excess cortisol induces superoxide production in vascular endothelial cells, resulting in vascular endothelial dysfunction (14). These mechanisms are thought to interact in a complex manner, causing hypercortisolism to reduce the cerebral blood flow in a wide area (15).

The involvement of the hippocampus in cognitive decline and hippocampal atrophy has been reported in patients with Cushing's disease. Cognitive decline and hippocampal atrophy have also been observed in patients with Cushing's syndrome (16). Correction of hypercortisolism has been shown to improve the cognitive function in patients with Cushing's syndrome (17). Taken together, these findings suggest that hypercortisolemia is directly involved in hippocampal atrophy and cognitive decline. The hippocampus contains an abundance of glucocorticoid receptors (18), which are likely to be strongly affected by hyperglucocorticoidemia. Therefore, it is thought that the cerebral blood flow is reduced in the hippocampus through glucocorticoid receptors. In the present case, as shown in the 3D-SSP analysis of SPECT, there was a decrease in the blood flow in the hippocampal region preoperatively; however, no decrease in the blood flow was observed postoperatively. In contrast, no marked change in the size of the hippocampus was observed in our patient, possibly because this case was discovered shortly after the onset of Cushing's disease, before any organic changes in the hippocampus had occurred. Although a re-





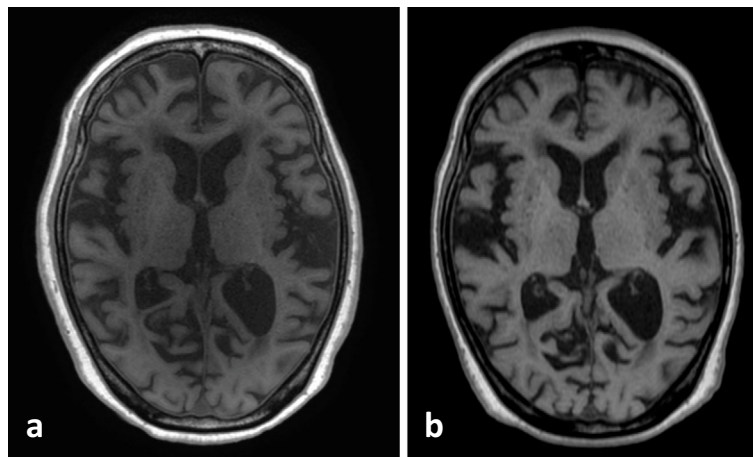
**Figure 2.** Hematoxylin and Eosin staining (a) and immunohistochemistry of pituitary adenoma. Immunohistochemistry showed positive immunostaining for ACTH (b) and negative findings for GH (c), PRL (d), LH (e), FSH (f), and TSH (g). The Ki-67 index was <1% (h). ACTH: adrenocorticotropic hormone, GH: growth hormone, PRL: prolactin, LH: luteinizing hormone, FSH: follicle-stimulating hormone, TSH: thyroid-stimulating hormone

**Table 5.** Mini Mental State Examination.

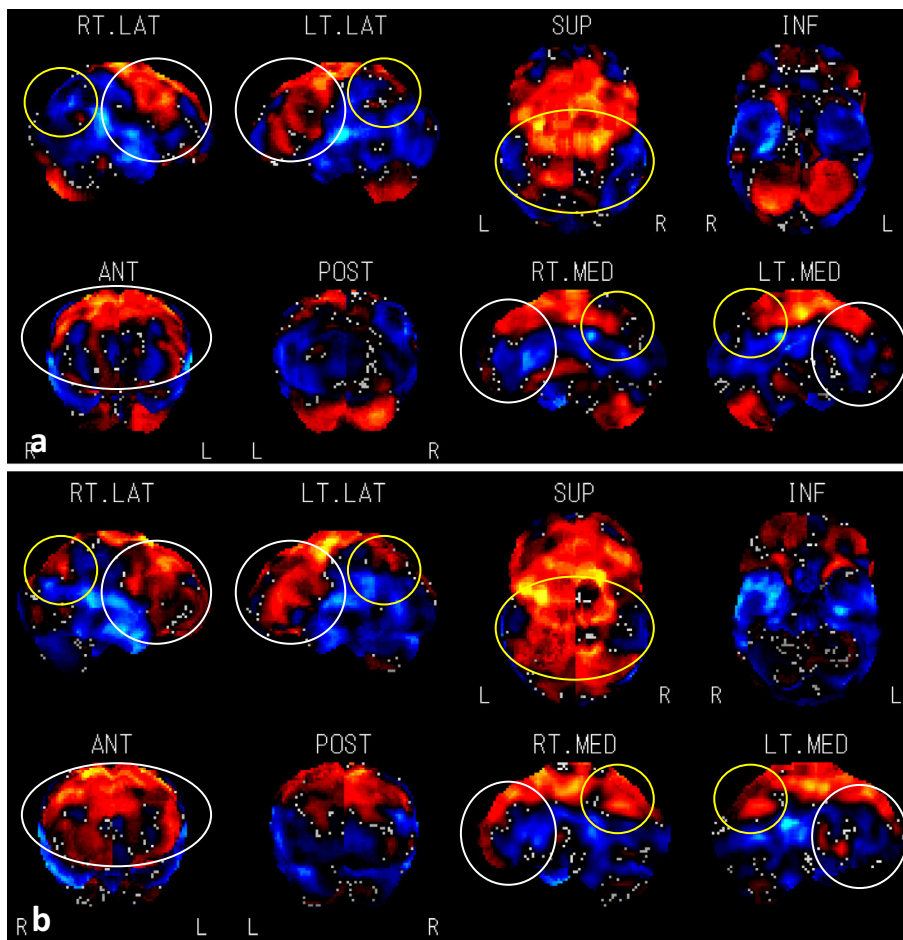
	Preoperative	6 months after operation
Orientation to time	4	5
Orientation to place	3	3
Registration	2	3
Attention and calculation	0	0
Recall	1	3
Naming	2	2
Repetition	0	1
Stage command	3	3
Reading and obey	1	0
Writing	0	0
Copying	1	1
Total score	17	21

duction in the hippocampal volume is often observed in patients with Cushing's disease, some reports indicate that volume reduction does not necessarily occur in all cases. A 27% reduction in hippocampal volume has been observed compared to healthy subjects (19). In addition, in a report on Cushing's syndrome, the cognitive function improved after surgery, but the hippocampal size did not change (16). These results suggest that correction of hypercortisolism may not lead to the recovery of the hippocampal size, although the correction of hypercortisolism is significant enough to improve the cognitive decline.

In the present case, temporal disorientation and delayed regeneration improved after surgery. Both of these findings are consistent with results reflecting the recovery of the hippocampal function. In patients with Cushing's disease, immediate memory, delayed replay, and repetition are particularly impaired among cognitive functions (6), and in the pre-



**Figure 3.** Head magnetic resonance imaging (MRI) in T1-weighted transverse images before operation (a) and six months after the operation (b) showing extensive atrophy of the cerebrum.

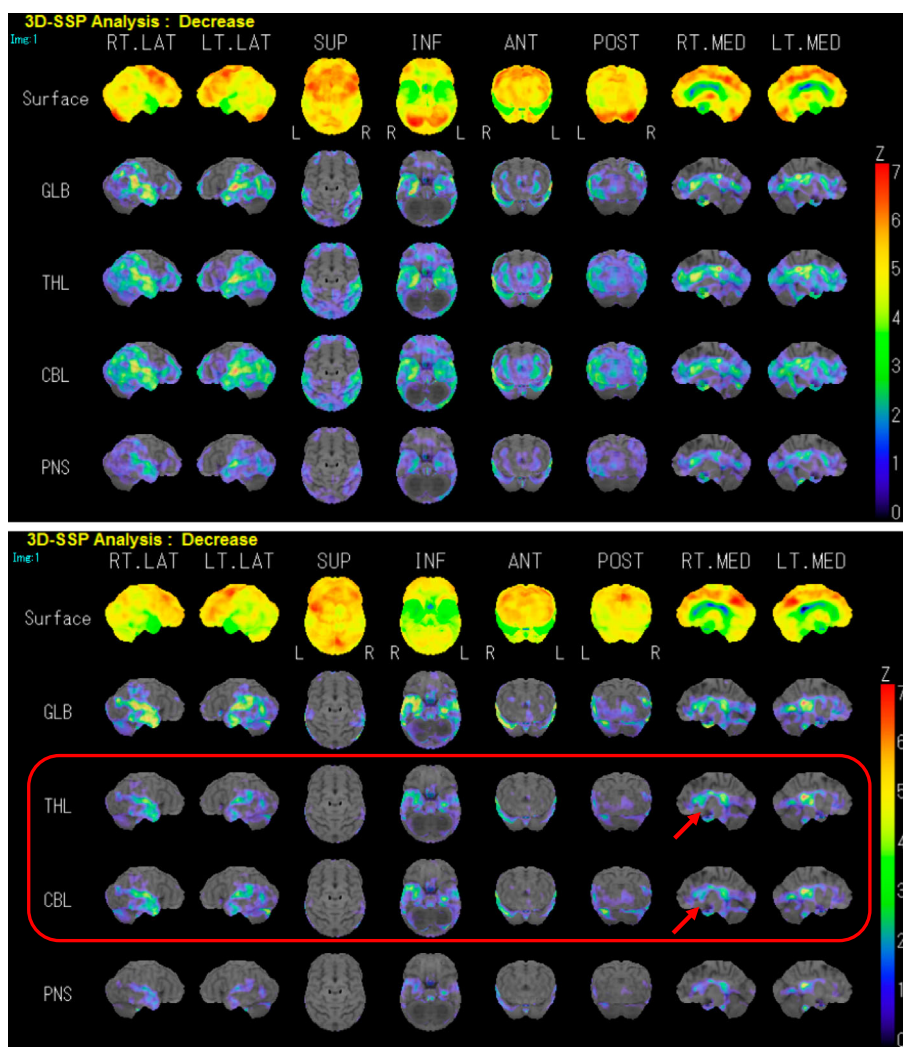


**Figure 4.** N-isopropyl-p<sup>123</sup>I-iodoamphetamine single-photon emission computed tomography (<sup>123</sup>I-IMP SPECT) before the operation showing a decline in the blood flow in all lobes (a), <sup>123</sup>I-IMP SPECT six months after the operation (b) showing an improvement in the blood flow in the frontal (white circles) and parietal lobes (yellow circles). The blue area shows decreased blood flow. The red area indicates that blood flow is maintained. RT.LAT: right lateral, LT.LAT: left lateral, SUP: superior, INF: inferior, ANT: anterior, POST: posterior, RT.MED: right medial, LT.MED: left medial

sent case, these three parameters improved after surgery. In addition, all of these parameters are known to be areas that strongly reflect the function of the hippocampus. Therefore,

it is highly likely that the improvement in the cognitive decline in this case was due to functional recovery achieved by improving the blood flow to the hippocampal area.





**Figure 5.** Results of a three-dimensional stereotactic surface projections (3D-SSP) analysis using  $^{123}\text{I}$ -IMP SPECT before the operation showing a decline in the blood flow in the frontal, parietal, and hippocampal lobes (a).  $^{123}\text{I}$ -IMP SPECT six months after the operation (b) showing an improvement in the blood flow in these lobes. Red squares indicate areas where blood flow has improved after surgery, and red arrows indicate areas of the hippocampus. RT.LAT: right lateral, LT.LAT: left lateral, SUP: superior, INF: inferior, ANT: anterior, POST: posterior, RT.MED: right medial, LT.MED: left medial, GLB: global whole brain, THL: thalamus, CBL: cerebellum, PNS: pons

We will next discuss the relationship between Cushing's disease and sarcopenia. In the current literature, there have been no reports of post-operative improvements in sarcopenia in Cushing's disease. Glucocorticoids act on glucocorticoid receptors in skeletal muscles, causing muscle atrophy by simultaneously promoting catabolism and inhibiting anabolism and leading to the development of sarcopenia in patients with Cushing's disease (20). The 24-h urinary cortisol concentration in patients is significantly negatively correlated with the psoas muscle density (21). Recently, correlations between the cortisol level in the blood and the severity of Cushing's disease (22) as well as between subclinical hypercortisolism and decreased skeletal muscle mass in women have been reported (23). Furthermore, salivary cortisol levels have been reported to correlate with blood and urine cortisol and are involved in the development of sarcopenia in menopausal women (24). In summary, there is a strong cor-

relation between blood and urinary cortisol levels and muscle mass in older women. In our case, rehabilitation was continuously performed before and after surgery. Rehabilitation is important and effective in improving muscle mass in older patients. However, in the present case, the patient's SMI improved following the significant decrease in urinary cortisol levels after TSS. This result suggests that the decrease in urinary cortisol level may have enhanced the effect of rehabilitation and contributed to the recovery of the muscle mass.

Currently, the first-line treatment for Cushing's disease is resection of the pituitary adenoma by TSS. However, if the patient is unable to undergo surgery, there are several options for drug therapy. There have been reports comparing the efficacy of medications that inhibit ACTH secretion by the pituitary gland (cabergoline and pasireotide) and those that target steroidogenesis in the adrenal gland (metyrapone,

**Table 6. Complication Data.**

	Preoperative	6 months after operation
Blood pressure (mmHg)	130-140/70-80 (4 agents)	100-130/50-80 (same agents as preoperative)
HbA1c (%)	8.7 (MDI and OHA)	7.4 (OHA)
Triglyceride (mg/dL)	68	169
HDL cholesterol (mg/dL)	45	35
LDL cholesterol (mg/dL)	80 (1 agent)	86 (same agent as preoperative)
Grip strength (kg) Right/Left	10/10	12/11
SMI (kg/m <sup>2</sup> )	5.175	5.432
Muscle mass in both lower limbs (kg)	8.19	8.60
FIM	63	82
Young adult mean of femoral neck BMD (%)	55	51

MDI: multiple daily insulin injection, OHA: oral hypoglycemic agent, HDL: high-density lipoprotein, LDL: low-density lipoprotein, SMI: Skeletal Muscle mass Index, FIM: Functional Independence Measure, BMD: bone mineral density

oshiodrostat, ketoconazole, and mitotane). The efficacy of cabergoline was low (about 50%), although no major adverse effects were reported, and that of pasireotide was high (76%), but adverse drug events, including a relatively high incidence of hyperglycemia, were present (87%). Regarding metyrapone, evidence of its long-term efficacy is lacking. Regarding the recently developed oshiodrostat, the results of a phase III trial were reported in 2020 (25). A complete response at 48 weeks was achieved in 66.4% [95% confidence interval (CI): 57.9, 74.3] of the treated group, while nausea (42%), headache (34%), fatigue (28%), and adrenal insufficiency (28%) were reported as adverse events. In addition, many patients fail to achieve disease remission. The efficacy of ketoconazole is reportedly inconsistent, ranging from 45% to 85%. Mitotane has been shown to be effective in 72% to 81% of subjects, but the frequency of side effects, especially gastrointestinal symptoms (47%) and neurological symptoms (30%), prevents its continued use, and discontinuation results in the recurrence of hypercortisolism (26). In summary, TSS is the current first-line treatment for Cushing's disease.

In general, invasive treatments such as surgery are often avoided in older patients because they lead to a loss of the cognitive function and muscle mass. Indeed, a backward-looking analysis based on a U.S. database from 1998 to 2005 reported a higher mortality rate among older patients in the perioperative period than among younger patients (5). However, in recent studies, TSS was shown to have relatively low invasiveness, and no increased surgical risk was observed in older patients compared to younger patients (27). In fact, our patient showed no obvious complications during surgery. Furthermore, six months after surgery, the cognitive function and muscle mass had improved. These findings suggest that surgical correction of excessive cortisol secretion by performing surgery is highly effective for older patients.

In conclusion, we encountered an older patient with Cushing's disease who underwent surgical treatment and experienced improvement in the cognitive function and muscle mass after TSS. TSS should therefore be considered as an option to treat Cushing's disease whenever possible.

Written informed consent for the publication of the clinical details was obtained from the patient.

**The authors state that they have no Conflict of Interest (COI).**

## References

- Lindholm J, Juul S, Jorgensen JO, et al. Incidence and late prognosis of Cushing's syndrome: a population-based study. *J Clin Endocrinol Metab* **86**: 117-123, 2001.
- Starkman MN. Neuropsychiatric findings in Cushing syndrome and exogenous glucocorticoid administration. *Endocrinol Metab Clin N Am* **42**: 477-488, 2013.
- Chen YF, Li YF, Chen X, Sun QF. Neuropsychiatric disorders and cognitive dysfunction in patients with Cushing's disease. *CMJ* **26**: 3156-3160, 2013.
- Priego T, Martín AI, González-Hedström D, Granado M, López-Calderón A. Role of hormones in sarcopenia. *Vitam Horm* **115**: 535-570, 2021.
- Grossman R, Mukherjee D, Chaichana KL, et al. Complications and death among elderly patients undergoing pituitary tumour surgery. *Clin Endocrinol* **73**: 361-368, 2010.
- Tiemensma J, Kokshoom NE, Biermasz NR, et al. Subtle cognitive impairments in patients with long-term cure of Cushing's disease. *J Clin Endocrinol Metab* **95**: 2699-2714, 2010.
- Brunetti A, Fulham MJ, Aloj L, et al. Decreased brain glucose utilization in patients with Cushing's disease. *J Nucl Med* **39**: 786-790, 1998.
- Liu S, Wang Y, Xu K, et al. Brain glucose metabolism is associated with hormone level in Cushing's disease: a voxel-based study using FDG-PET. *NeuroImage Clin* **12**: 415-419, 2016.
- Cheng H, Gao L, Hou B, et al. Reversibility of the cerebral blood flow in patients with Cushing's disease after surgery treatment. *Metabolism* **104**: 154050, 2020.



10. Forget H, Lacroix A, Somma M, Cohen H. Cognitive decline in patients with Cushing's syndrome. *J Int Neuropsychol Soc* **6**: 20-29, 2000.
11. Kim KJ, Filosa JA. Advanced *in vitro* approach to study neurovascular coupling mechanisms in the brain microcirculation. *J Physiol* **590**: 1757-1770, 2012.
12. McEwen BS, Bowles NP, Gray JD, et al. Mechanisms of stress in the brain. *Nat Neurosci* **18**: 1353-1363, 2015.
13. Rajkowska G, Miguel-Hidalgo JJ. Gliogenesis and glial pathology in depression. *CNS Neurol Disord Drug Targets* **6**: 219-233, 2007.
14. Iuchi T, Akaike M, Mitsui T, et al. Glucocorticoid excess induces superoxide production in vascular endothelial cells and elicits vascular endothelial dysfunction. *Circ Res* **92**: 81-87, 2003.
15. Cheng H, Gao L, Hou B, et al. Reversibility of the cerebral blood flow in patients with Cushing's disease after surgery treatment. *Metabolism* **104**: 154050, 2020.
16. Frimodt-Møller KE, Møllegaard Jepsen JR, Feldt-Rasmussen U, et al. Hippocampal volume, cognitive functions, depression, anxiety, and quality of life in patients with Cushing syndrome. *J Clin Endocrinol Metab* **104**: 4563-4577, 2019.
17. Siegel S, Kirstein CF, Grzywotz A, et al. Neuropsychological functioning in patients with Cushing's disease and Cushing's syndrome. *Exp Clin Endocrinol Diabetes* **129**: 194-202, 2021.
18. Chow Y, Masiak J, Mikołajewska E, et al. Limbic brain structures and burnout - a systematic review. *Adv Med Sci* **63**: 192-198, 2018.
19. Starkman MN, Gebarski SS, Berent S, Scheingart DE. Hippocampal formation volume, memory dysfunction, and cortisol levels in patients with Cushing's syndrome. *Biol Psychiatry* **32**: 756-765, 1992.
20. Goldberg AL, Tischler M, Demartina G, Griffin G. Hormonal regulation of protein degradation and synthesis in skeletal muscle. *Fed Proc* **39**: 31-36, 1980.
21. Miller BS, Ignatoski KM, Daignault S, et al. A quantitative tool to assess degree of sarcopenia objectively in patients with hypercortisolism. *Surgery* **150**: 1178-1185, 2011.
22. Delivanis D, Iñiguez-Ariza N, Zeb M, et al. Impact of hypercortisolism on skeletal muscle mass and adipose tissue mass in patients with adrenal adenomas. *Clin Endocrinol* **88**: 209-216, 2018.
23. Kim JH, Kwak MK, Ahn SH, et al. Alteration in skeletal muscle mass in women with subclinical hypercortisolism. *Endocrine* **61**: 134-143, 2018.
24. Gonzalez Rodriguez E, Marques-Vidal P, Aubry-Rozier B, et al. Diurnal salivary cortisol in sarcopenic postmenopausal women: the OsteoLaus Cohort. *Calcif Tissue Int* **109**: 499-509, 2021.
25. Pivonello R, Fleseriu M, Newell-Price J, et al. Efficacy and safety of osilodrostat in patients with Cushing's disease (LINC 3): a multicentre phase III study with a double-blind, randomised withdrawal phase. *Lancet Diabetes Endocrinol* **8**: 748-761, 2020.
26. Lau D, Rutledge C, Aghi MK. Cushing's disease: current medical therapies and molecular insights guiding future therapies. *Neurosurg Focus* **38**: E11, 2015.
27. Villar-Taibo R, Díaz-Ortega C, Sifontes-Dubo M, et al. Pituitary surgery in elderly patients: a safe and effective procedure. *Endocrine* **2**: 814-822, 2021.

The Internal Medicine is an Open Access journal distributed under the Creative Commons Attribution-NonCommercial-NoDerivatives 4.0 International License. To view the details of this license, please visit (<https://creativecommons.org/licenses/by-nc-nd/4.0/>).