

Case report

Erythema nodosum leads to the diagnosis of pulmonary tuberculosis

Theocharis Koufakis^{1,&}, Ioannis Gabranis¹

¹Department of Internal Medicine, General Hospital of Larissa, Larissa, Greece

[&]Corresponding author: Theocharis Koufakis, 49 Ioustinianoustr. P.C. 41223 Larissa, Greece

Key words: Erythema nodosum, Tuberculosis, Hilar lymphadenopathy

Received: 01/08/2014 - Accepted: 10/08/2014 - Published: 14/08/2014

Abstract

Erythema nodosum is a panniculitis which may have various causes, such as drugs, infections, sarcoidosis, inflammatory bowel disease, tuberculosis or can be idiopathic. We here report a case of a woman diagnosed with pulmonary tuberculosis whose first symptom was erythema nodosum. A thorough clinical and laboratory investigation of the patient presenting with erythema nodosum is always required, in order to assess a possible systemic, underlying condition.

Pan African Medical Journal. 2014; 18:291 doi:10.11604/pamj.2014.18.291.5170

This article is available online at: <http://www.panafrican-med-journal.com/content//article/18/291/full/>

© Theocharis Koufakis et al. The Pan African Medical Journal - ISSN 1937-8688. This is an Open Access article distributed under the terms of the Creative Commons Attribution License (<http://creativecommons.org/licenses/by/2.0>), which permits unrestricted use, distribution, and reproduction in any medium, provided the original work is properly cited.

Introduction

Erythema nodosum is a panniculitis, characterized by red, tender nodules usually located on the extensor surfaces of the legs. It may have various causes, such as drugs, infections, sarcoidosis, inflammatory bowel disease, tuberculosis or can be idiopathic [1]. In up to 50% of cases, the underlying etiology remains unclear [2].

Patient and observation

We here report a case of a 78 year old woman, with free medical history, who presented to the Emergency Department of our Hospital with erythema nodosum on her both shins (Figure 1A). She also mentioned low grade fever since 15 days and a positive family history of tuberculosis (daughter). Her chest X-Ray revealed bilateral hilar lymphadenopathy, mainly at the right side (Figure 1C). Further evaluation with High Resolution chest Computed Tomography confirmed the lymphadenopathy and demonstrated ground-glass opacities. The Mantoux skin test was strongly positive (22 mm) (Figure 1B). Anti-TB treatment was started, based on the positive Mantoux test, the compatible imaging findings and mainly, the history of close and direct exposure. Sputum cultures proved to be positive for *Mycobacterium tuberculosis*. Patient's response to treatment was impressive and in her follow up visits, she remained free of symptoms and a definite improvement of her imaging findings was observed.

Discussion

The commonest causes of erythema nodosum reported in the literature, are streptococcal infection in children and streptococcal infection and sarcoidosis in adults [3]. Its course is, in most cases, benign and self-limited. However, therapeutic options include, among others, NSAIDs, corticosteroids antimicrobial agents and colchicine.

Conclusion

In conclusion, a thorough clinical and laboratory investigation of the patient presenting with erythema nodosum is always required, in order to assess a possible systemic, underlying condition.

Competing interests

The authors declare that they have no competing interests

Authors' contributions

Koufakis T: Patient's management and writing of the manuscript. Gabranis I: Patient's management and review of the literature. All the authors have read and approved the final version of the manuscript.

Figures

Figure 1: A) Erythema nodosum on the patient's left shin; B) Positive Mantoux test; C) Chest X-Ray demonstrating hilar lymphadenopathy, mainly at the right side

References

1. Passarini B, Infusino SD. Erythema nodosum. *G Ital Dermatol Venereol.* 2013 Aug;148(4):413-7. **PubMed | Google Scholar**
2. Acosta KA, Haver MC, Kelly B. Etiology and therapeutic management of erythema nodosum during pregnancy: an update. *Am J Clin Dermatol.* 2013; 14(3):215-2. **PubMed | Google Scholar**
3. Hassink RI, Pasquinelli-Egli CE, Jacomella V, Laux-End R, Bianchetti MG. Conditions currently associated with erythema nodosum in Swiss children. *Eur J Pediatr.* Nov 1997; 156(11):851-3. **PubMed | Google Scholar**

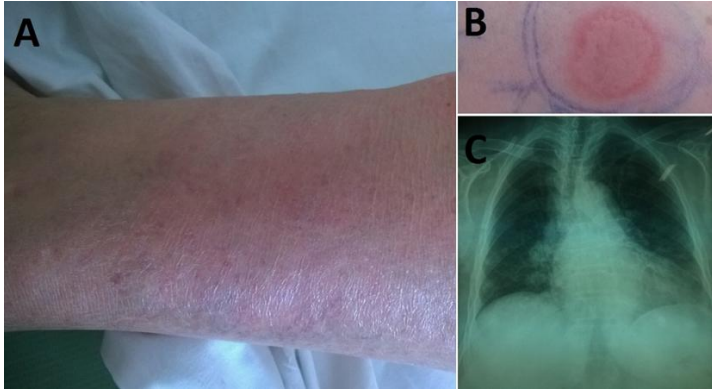


Figure 1: A) Erythema nodosum on the patient's left shin; B) Positive Mantoux test; C) Chest X-Ray demonstrating hilar lymphadenopathy, mainly at the right side