

Received: 2015.12.01  
Accepted: 2016.02.05  
Published: 2016.04.29

ISSN 1941-5923  
© Am J Case Rep, 2016; 17: 295-300  
DOI: 10.12659/AJCR.896946

# Long QT Syndrome Leading to Multiple Cardiac Arrests After Posaconazole Administration in an Immune-Compromised Patient with Sepsis: An Unusual Case Report

Authors' Contribution:  
Study Design A  
Data Collection B  
Statistical Analysis C  
Data Interpretation D  
Manuscript Preparation E  
Literature Search F  
Funds Collection G

E 1,2 **George Panos**  
E 1 **Dimitrios Velissaris**  
E 1 **Vasilios Karamouzou**  
B 3 **Charalampos Matzaroglou**  
D 3 **Minos Tyllianakis**

1 Department of Internal Medicine, University Hospital of Patras, Patras, Greece  
2 Department of Infectious Diseases, University Hospital of Patras, Patras, Greece  
3 Department of Orthopedic Surgery, University Hospital of Patras, Patras, Greece

**Corresponding Author:** George Panos, e-mail: [panmedix@otenet.gr](mailto:panmedix@otenet.gr); [george.panos@upatras.gr](mailto:george.panos@upatras.gr)  
**Conflict of interest:** None declared

**Patient:** Female, 26  
**Final Diagnosis:** Sepsis • drug induced long QT syndrome  
**Symptoms:** Cardiac arrest • cardiac arrhythmia • fever • Qt prolongation  
**Medication:** Posaconazole  
**Clinical Procedure:** Pacemaker insertion  
**Specialty:** Infectious Diseases

**Objective:** Rare disease  
**Background:** We present the case of a septic patient with severe immunodeficiency, who developed QT interval prolongation followed by episodes of lethal cardiac arrhythmia. Cardiac events occurred after posaconazole administration, incriminating posaconazole use, alone or in combination with voriconazole, as the culpable agent.

**Case Report:** A 26-year-old female patient underwent orthopedic surgery to remove ectopic calcifications in her left hip joint. On the first post-operative day she became septic due to a surgical wound infection. Despite being treated according to the therapeutic protocols for sepsis, no clinical improvement was noticed and further assessment revealed an underlying immunodeficiency. Considering the underlying immunodeficiency and to that point poor clinical response, an antifungal agent was added to the antibiotic regimen. Following discontinuation of multiple antifungal agents due to adverse effects, posaconazole was administered. Posaconazole oral intake was followed by episodes of bradycardia and QT interval prolongation. The patient suffered continuous incidents of cardiac arrest due to polymorphic ventricular tachycardia (torsades des pointes) that degenerated to lethal ventricular fibrillation. Posaconazole was immediately discontinued and a temporary pacemaker was installed. The patient finally recovered without any neurological deficit, and was discharged in a good clinical status.

**Conclusions:** Close cardiac monitoring is recommended in cases where posaconazole administration is combined with co-existing risk factors, as they may lead to severe ECG abnormalities and cardiac arrhythmias such as long QT interval syndrome and torsades de pointes. Posaconazole interactions with medications metabolized via the CYP3A4 pathway should be considered an additional risk factor for lethal cardiac incidents.

**MeSH Keywords:** Drug Interactions • Long QT Syndrome • Torsades de Pointes

**Full-text PDF:** <http://www.amjcaserep.com/abstract/index/idArt/896946>

 2087

 1

 4

 17



## Background

Posaconazole is the newest orally administered triazole antifungal agent with an extended spectrum of activity [1]. It is indicated for the prophylaxis of invasive *Aspergillus* and *Candida* infections in severely immunocompromised patients, for the treatment of oral candidiasis (mainly in HIV+ patients), including cases refractory to itraconazole and fluconazole. It also seems to be a promising antifungal agent for the treatment and prophylaxis of invasive fungal infections (IFIs) [1–3]. Finally, it has favorable clinical outcomes against fungal infections of the central nervous system (CNS) [4]. The drug inhibits lanosterol 14 $\alpha$ -demethylase enzyme and ergosterol production, it is well absorbed, and demonstrates dose-proportional pharmacokinetics following oral administration, which are not related to age, sex, or race/ethnicity [5]. Its half-life fluctuates between 20 and 35 h [6,7], and it also has prolonged and extensive peripheral tissue distribution [7]. Posaconazole inhibits the hepatic CYP3A4 enzyme, but compared to other azoles has less interactions with the P450 system, as its only significant interaction is the inhibition of CYP3A4 and it has no effect on the other CYP isoenzymes (1A2, 2C8, 2C9, 2D6, and 2E1), in contrast to voriconazole, which is both a substrate and inhibitor of the CYP3A4, CYP2C9, and CYP2C19 enzymes [1,3,7]. Elimination occurs primarily through fecal excretion (77%) and to a lesser degree through urinary excretion (14%) [3,7]. Studies of long-term posaconazole administration (6–12 months) showed that it is a well-tolerated and safe drug, with minimal adverse effects [6–8]. Adverse effects like nausea (8%) and vomiting (6%) are the most frequently reported, long QT syndrome occurred in 1%, and elevated hepatic enzymes in 2% [1].

Torsades de pointes (TdP) is a potentially fatal polymorphic ventricular tachyarrhythmia, related to QT interval prolongation and it may present with palpitations, seizures, syncope, and sudden death, or may be asymptomatic if the duration is relatively short and terminates spontaneously.

Electrocardiographic long QT interval syndrome (normal men QTc  $\leq$ 0.44 s, women QTc  $\leq$ 0.45 to 0.46 s) is categorized as either congenital or acquired. Congenital long QT syndrome is defined as occurrence of genetic mutations affecting Na<sup>+</sup>, K<sup>+</sup>, and Ca<sup>2+</sup> channels. The following related syndromes are described in the literature: Romano-Ward syndrome, Anderson syndrome, Timothy syndrome, and the Jervell and Lange Nielsen syndrome. Acquired long QT syndrome is most commonly drug-related [9]. Numerous drugs (antiarrhythmic, antimicrobials, antifungals, antipsychotics, antidepressants, serotonin agonists of triptan class, and antihistamines) have an effect on I<sub>Kr</sub>, an important K<sup>+</sup> channel subtype that participates in ventricular repolarization, causing prolongation of QT interval [9,10] (Table 1).

We report the case of an immunocompromised female patient with sepsis, whose treatment with posaconazole was complicated with severe cardiac events.

## Case Report

A 26-year-old woman of Albanian origin was admitted to the Orthopedic Department of our hospital for a scheduled surgical removal of ectopic calcifications in the left hip joint. Her past medical history consisted of a caesarean section at the age of 23 followed by a prolonged hospitalization due to abdominal sepsis and multiple plastic surgeries to reconstruct the abdominal wall. No significant cardiac history was reported, and a recent cardiac echocardiography report, as well as the ECG report on admission, were normal.

She had an uneventful operation; however, on postoperative day 2 she developed sepsis due to surgical wound infection. Intra- and post-operative administration of cefamandole was replaced by meropenem and daptomycin, taking into consideration local susceptibility patterns, but the clinical response was poor.

At that point, the persistent high temperature, the previous medical history of continuous multiple infections, and the inadequate response to antibiotics raised the suspicion of a possible immunodeficiency, which was confirmed by low levels of gamma globulins in electrophoresis and low proportion of B and T lymphocytes in flux cytometry.

Daptomycin was replaced by linezolid, and colistin and amikacin were added to the antibiotic regimen. Furthermore, considering the immunocompromised status, liposomal amphotericin B was added to cover possible fungal infection despite negative cultures, resulting in clinical improvement. Nine days later, due to refractory hypokalemia (K<sup>+</sup>=2.6mEq/L) resistant to external K<sup>+</sup> administration, a decision was made to replace liposomal amphotericin B with voriconazole.

After discontinuation of amphotericin B, plasma potassium levels were restored but the patient relapsed due to a new septic episode. Results from blood cultures at that time were positive for multi-resistant *Acinetobacter baumannii* and modifications were made according to the antibiogram. Tigecycline, doripenem, colistin, and oral posaconazole were administered combined with intravenous immune globulin (IVIG) every 5 days. Moreover, the patient underwent through debridement of the surgical wound daily, and finally the infection begun to recede after 3 days.

Voriconazole was administered for a total of 9 days and was then replaced with oral posaconazole. Thirty-six hours after

**Table 1.** Acquired long QT syndrome etiology.

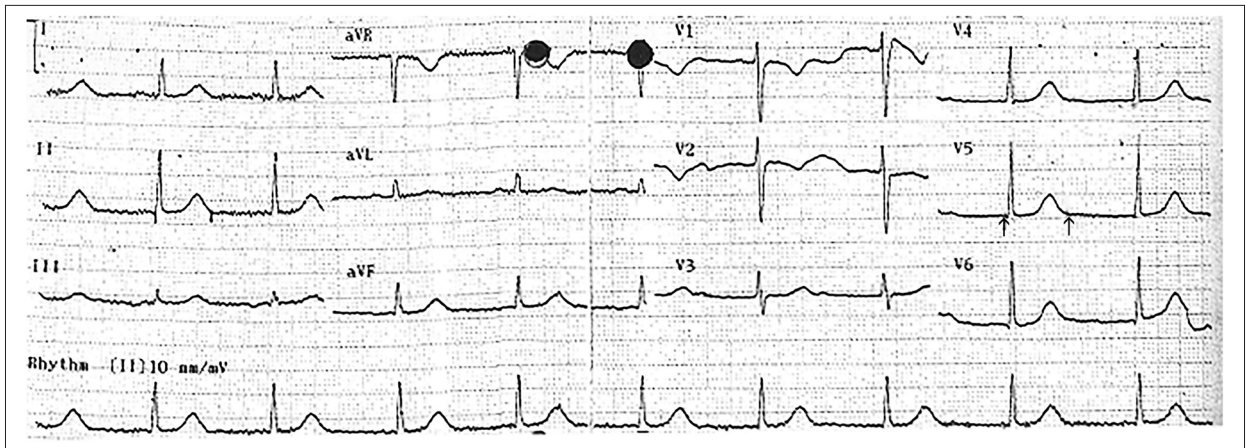
Acquired long QT syndrome etiology	
<b>Metabolic disorders</b>	<b>Antiarrhythmic Drugs</b>
Hypokalemia, Hypomagnesemia, Hypocalcemia	Quinidine, Procainamide, Disopyramide, Sotalol, Amiodarone, Mexiletine, Propafenone, Flecainide
Anorexia nervosa	
Hypothyroidism	<b>Antimicrobial drugs</b>
	Erythromycin, clarithromycin, azithromycin, Metronidazole
<b>Cardiac disorders</b>	Pentamidine, Voriconazole, Posaconazole
Sinus node dysfunction, 2nd and 3rd degree AV Block	Gatifloxacin, Levofloxacin, Moxifloxacin
Severe Bradycardia	Spiramycin, Chloroquine, Mefloquine
Heart failure, Myocarditis, Ischemia	<b>Antihistamines</b>
<b>Other factors</b>	Terfenadine, Astemizole, Ebastine, Terfenadine, Hydroxyzine
Stroke, Subarachnoid hemorrhage	<b>Psychotropic drugs</b>
Hypothermia	Thioridazine, Phenothiazines, Tricyclic antidepressants, Haloperidol, Risperidone
HIV infection	<b>Antineoplastic agents</b>
Connective tissue disease	Crizotinib, Dasatinib, Nilotinib, Romidepsin, Sorafenib, Vandetanib, Vorinostat
	<b>Other drugs</b>
	<ul style="list-style-type: none"> <li>• Migraine medication – Naratriptan, sumatriptan, zolmitriptan</li> <li>• Opioids – methadone, oxycodone</li> <li>• Vasodilators – prenylamine, bepridil, mibefradil</li> <li>• Diuretics – Indapamide, thiazide, furosemide</li> <li>• Gastrointestinal – ondansetron, dolasetron, Metoclopramide</li> <li>• HIV protease inhibitors</li> <li>• Immunosuppressive Drugs – Tacrolimus</li> <li>• Other – Arsenic trioxide, Cocaine, Organophosphorus Compounds</li> </ul>

posaconazole intake, the patient had episodes of bradycardia accompanied by QT prolongation in ECG (Figure 1), while plasma electrolyte levels were normal. Finally, she had an episode of cardiac arrest resolved with cardiopulmonary resuscitation and defibrillation. She was transferred to the cardiology ICU for monitoring and at that time she had continuous incidents of cardiac arrest due to polymorphic ventricular tachycardia (torsade des pointes) (Figure 2) that degenerated to lethal ventricular fibrillation (VF). Posaconazole was immediately halted and a temporary pacemaker was placed due to the continuous VF incidents (Figure 3). The patient was treated in our cardiology ICU for 4 days (Figure 4) and finally was transferred to the orthopedic clinic to resume therapy. She was discharged clinically well and planned for further investigation in the hematology outpatient clinic.

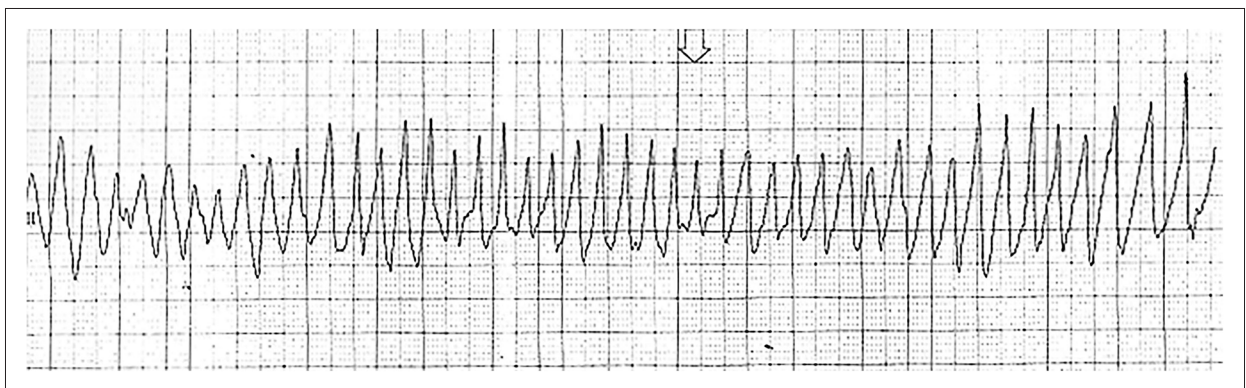
## Discussion

Only a few cases of antifungal azole-induced long QT interval syndrome followed by TdP have been reported in the literature, but the responsible drug in all of them was voriconazole.

The first one, published by Alkan et al. in 2004, referred to a 15-year-old girl with acute lymphoblastic leukemia and *Fusarium* infection, treated with voriconazole. The first episode of QTc interval prolongation followed by TdP was noted 3 weeks after voriconazole initiation. At that time, the patient had a combination of severe risk factors (mild hypokalemia  $K^+$ : 3.2mEq/Lt) and potentially arrhythmogenic co-medication. In that case, QT prolongation was concentration-independent and recurred upon re-challenge with a very small voriconazole dose in the absence of other known pro-arrhythmogenic factors, a fact that strongly suggests a causal relationship between long QT syndrome and voriconazole exposure. Moreover, during the first cardiac event, voriconazole plasma concentrations were in the normal range, and during the re-challenge were very low [11]. The second case was reported by Elbey in 2012 and involved a female patient with a past medical history of nephrotic syndrome and rheumatic mitral valve disease, who was hospitalized and treated for fever. She developed sinus tachycardia and a prolonged QT interval of 580 ms when amphotericin-B was changed to voriconazole [12]. The third case, published in 2007 by Eiden et al., involved a 14-year-old Tahitian girl with acute myeloid leukemia



**Figure 1.** ECG depicting long QT interval. QTc=540 ms measured with the Bazett's formula (arrows).



**Figure 2.** ECG showing polymorphic ventricular tachycardia (torsades des pointes).

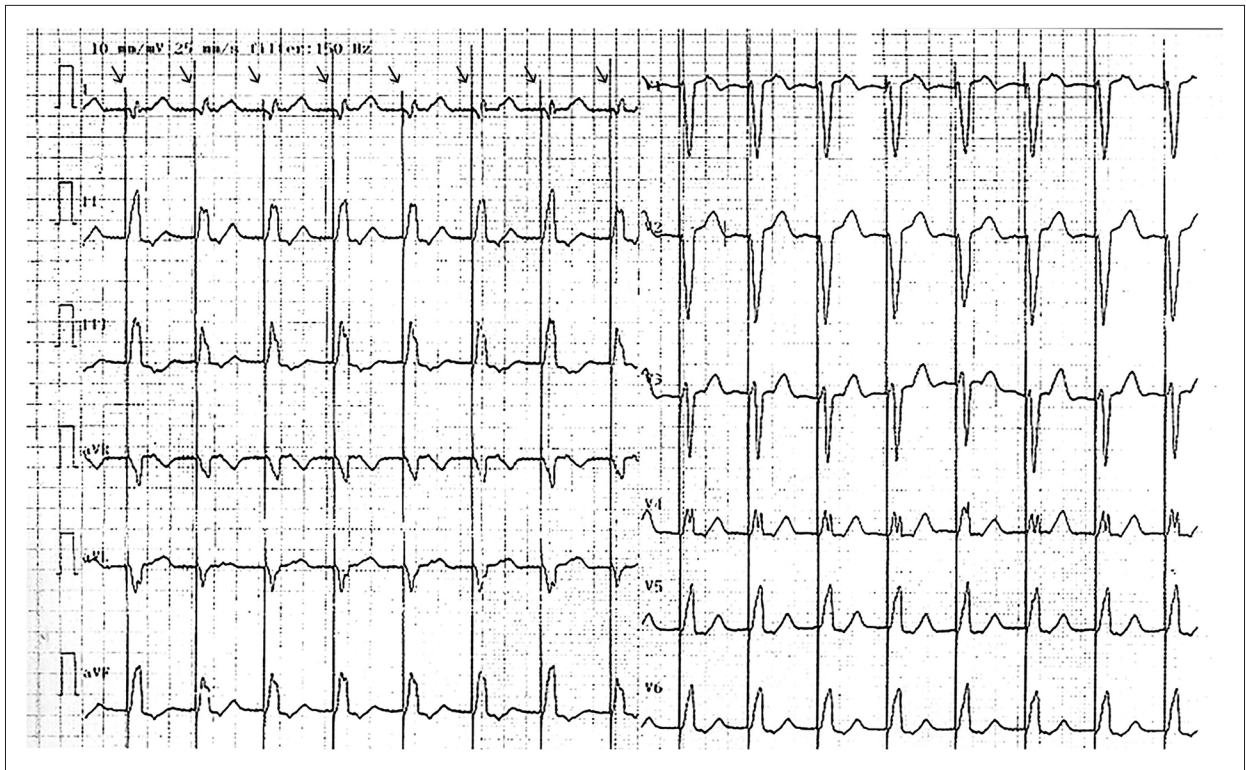
and a suspected mucormycosis, who was treated first with voriconazole and caspofungin and later was changed to posaconazole due to the worsening fungal infection. Immediately after the switch to posaconazole, the patient developed bradycardia and long QT interval. The preceding TdP episode was attributed primarily to voriconazole, not posaconazole, because: 1) voriconazole plasma levels were measured 15 h after the last administration and reached levels of 7 mg/Lt, instead of the normal rate of 0.6–1.5 mg/Lt; and 2) the patient vomited 30 min after the oral posaconazole administration, thus it was assumed that little of the drug had been absorbed [13].

In our case, the causative factor that probably was responsible for the QT interval prolongation and episodes of TdP seems to be posaconazole, either by itself or combined with voriconazole administration. We tend to believe so, despite the fact that the patient had been treated with voriconazole for 9 days, because bradycardia and cardiac arrest occurred 36 h after the first dose of posaconazole and approximately 48 h after the last voriconazole dose. Given the fact that posaconazole half-life reaches 20–35 h [7], whereas voriconazole has an estimated half-life of 9 h, presumably, after 48 h the voriconazole plasma levels would be minimal or insignificant; therefore,

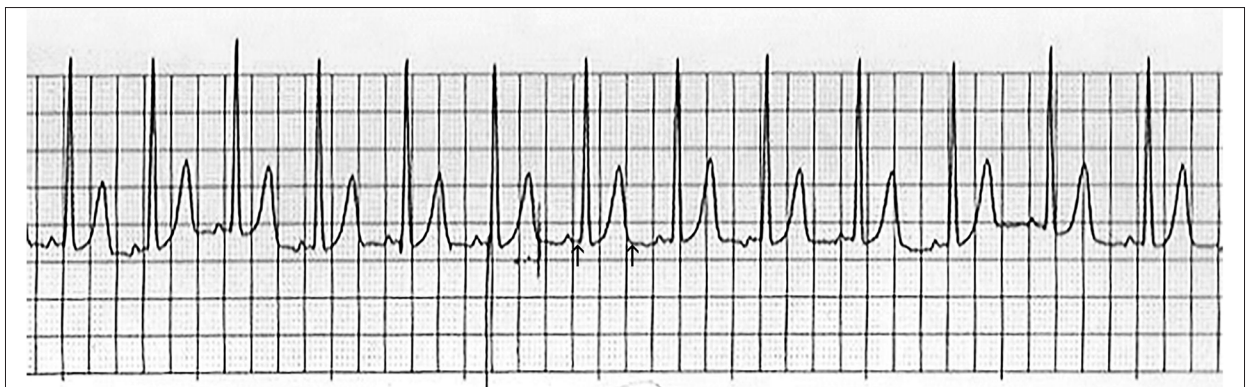
posaconazole seems more likely to be responsible for the QT interval prolongation. The patient also kept having continuous incidents of cardiac arrest due to polymorphic ventricular tachycardia (TdP) that degenerated to ventricular fibrillation even when she entered the Cardiology ICU, and these stopped immediately after posaconazole was removed from the regimen.

Risk factors for long QT interval syndrome are well described [10,14–16]. Predisposing risk factors identified in our patient were: female sex, antifungal azoles (voriconazole and posaconazole), drug interactions, and arrhythmogenic drugs (metoclopramide and antifungals). Female sex has a predominance in the development of QT interval prolongation and associated arrhythmias, which is attributed to differences in specific cardiac ion densities [12]. Studies show that posaconazole is a well-tolerated drug [6,8,14], and even after a 6-month to 1-year administration, long QT syndrome prevalence is 1% [8]. In cases of congenital long QT syndrome, posaconazole acts synergistically, leading to a higher incidence of long QT interval and TdP.

Furthermore, all known azoles (fluconazole, ketoconazole, itraconazole, voriconazole, and posaconazole) may prolong QT interval directly by blocking  $I_{Kr}$  channels, as well as by delaying



**Figure 3.** ECG after the temporary pacemaker placement. The pacemaker's spikes are clearly visible (arrows).



**Figure 4.** ECG when discharged from cardiac ICU. QTc=436 ms measured with the Bazett's formula (arrows).

CYP450-dependent metabolism of other drugs that prolong QT interval [17]. The possible interaction between voriconazole and posaconazole must also be taken into account, as both the Tahitian girl with leukemia [13] and our patient had episodes of bradycardia and finally cardiac arrest after shifting from voriconazole to posaconazole. This suggests an unknown interaction between these 2 antifungal drugs that enhances the incidence of long QT prolongation and TdP. A drug-drug interaction cannot be excluded according to the mechanisms of the hepatic metabolism of both drugs. Serious interactions may occur in cases when drugs like posaconazole and voriconazole, whose metabolism is related to the cytochrome P450 enzymic system, are concomitantly administered. The enzyme CYP3A4

is polymorphically expressed, and its allelic variants have less functional phenotypic implications compared to the alleles of the CYP2C9 and CYP2C19 enzymes, indicating a clinical polymorphism [9]. There is diminished clearance, increased concentration, and prolonged exposure of the poorly metabolized medications via the CYP2C9 and CYP2C19 enzymes. Therefore, patients who express the phenotype of poor metabolism of drugs via the CYP pathway are more likely to develop higher incidence of TdP cardiac arrhythmia. Based on these aforementioned mechanisms, since posaconazole is metabolized via CYP3A4 and voriconazole via CYP3A4, CYP2C9, and CYP2C19, a possible drug interaction could affect the clearance and, finally, plasma concentrations of both drugs [1,18].

In our patient, the co-administered drugs were tigecycline, doripenem, colistin, intravenous immune globulin, lansoprazole, and metoclopramide. Among these drugs, only metoclopramide has been related to cardiac adverse effects such as supraventricular tachycardia, atrial-ventricular block, and QT prolongation, but it was not administered simultaneously with posaconazole. Moreover, our patient was treated with lansoprazole during the cardiac incident. Lansoprazole may augment plasma concentrations of drugs metabolized by CYP3A4 (such as posaconazole and voriconazole).

We believe that our case report provides a meaningful addition to the literature on use of antifungal agents and severe cardiac events, like prolonged QT syndrome and development of lethal cardiac arrhythmias. Although our institution lacked financial resources to measure antifungal agent plasma levels, we think that the cardiac events in our case may have been due to posaconazole administration or to a posaconazole–voriconazole interaction, as no other related drug or clinical conditions related to these incidents existed.

We believe this is the first published report identifying posaconazole as being solely responsible for a patient's cardiac events. Regarding the use of posaconazole, an analysis from 428 patients with refractory invasive fungal infection or febrile neutropenia who received long-term posaconazole treatment showed a generally favorable safety profile of the medication. The results from this phase II/III open-label clinical trial indicated

that long-term therapy with posaconazole did not increase the risk of any individual adverse event, and no unique adverse event was observed with longer exposure to posaconazole [8].

## Conclusions

Although posaconazole is considered a safe and effective antifungal medication, its administration may be complicated by occurrence of long QT syndrome and associated lethal arrhythmias. Close cardiac monitoring and modification of the coexisting risk factors predisposing to cardiac incidents are indicated when posaconazole is administered. Drug interactions should also be taken into account when therapeutic decisions are made, because concomitant administration of medications that have metabolism related to cytochrome P450 may contribute to these cardiac incidents.

## Acknowledgements

We thank our patient for her willingness to provide consent for this report.

## Statement

All authors declare that they have not received funding from any source. All expenses were covered by personal contributions.

## References:

1. Chang M, Chagan L: Posaconazole (Noxafil), an extended-spectrum oral triazole antifungal agent. *Pharm Ther*, 2008; 33: 391–426
2. Krishna G, Sansone-Parsons A, Martinho M et al: Posaconazole plasma concentrations in juvenile patients with invasive fungal infection. *Antimicrob Agents Chemother*, 2007; 51: 812–18
3. Metcalf SC, Dockrell DH: Improved outcomes associated with advances in therapy for invasive fungal infections in immunocompromised hosts. *J Infect*, 2007; 55: 287–99
4. Pitisuttithum P, Negroni R, Graybill JR et al: Activity of posaconazole in the treatment of central nervous system fungal infections. *J Antimicrob Chemother*, 2005; 56: 745–55
5. Sansone-Parsons A, Krishna G, Simon J et al: Effects of age, gender, and race/ethnicity on the pharmacokinetics of posaconazole in healthy volunteers. *Antimicrob Agents Chemother*, 2007; 51: 495–502
6. Courtney R, Pai S, Laughlin M et al: Pharmacokinetics, safety, and tolerability of oral posaconazole administered in single and multiple doses in healthy adults. *Antimicrob Agents Chemother*, 2003; 47: 2788–95
7. Krieter P, Flannery B, Musick T et al: Disposition of posaconazole following single-dose oral administration in healthy subjects. *Antimicrob Agents Chemother*, 2004; 48: 3543–51
8. Raad II, Graybill JR, Bustamante AB et al: Safety of long-term oral posaconazole use in the treatment of refractory invasive fungal infections. *Clin Infect Dis*, 2006; 42: 1726–34
9. Owens RC, Nolin TD: Antimicrobial-associated QT interval prolongation: points of interest. *Clin Infect Dis*, 2006; 43: 1603–11
10. Yap G, Camm A: Drug induced QT prolongation and Torsades de Pointes. *Heart*, 2003; 89: 1363–72
11. Alkan Y, Haefeli WE, Burhenne J et al: Voriconazole-induced QT interval prolongation and ventricular tachycardia: A non-concentration-dependent adverse effect. *Clin Infect Dis*, 2004; 39: e49–52
12. Elbey MA, Cil H, Onturk E, Islamoglu Y: QTc prolongation and torsade de pointes ventricular tachycardia in a small dose voriconazole therapy. *Eur Rev Med Pharmacol Sci*, 2012; 16: 100–2
13. Eiden C, Peyrière H, Tichit R et al: Inherited long QT syndrome revealed by antifungals drug-drug interaction. *J Clin Pharm Ther*, 2007; 32: 321–24
14. Torres HA, Hachem RY, Chemaly RF et al: Posaconazole: A broad-spectrum triazole antifungal. *Lancet Infect Dis*, 2005; 5: 775–85
15. Cubeddu LX: QT prolongation and fatal arrhythmias: a review of clinical implications and effects of drugs. *Am J Ther*, 2003; 10: 452–57
16. De Ponti F, Poluzzi E, Cavalli A et al: Safety of non-antiarrhythmic drugs that prolong the QT interval or induce torsade de pointes: An overview. *Drug Saf*, 2002; 25: 263–86
17. Yap YG, Camm J: Risk of torsades de pointes with non-cardiac drugs. *BMJ*, 2000; 320: 1158–59
18. Hyland R, Jones BC, Smith DA: Identification of the cytochrome P450 enzymes involved in the N-oxidation of voriconazole. *Drug Metab Dispos*, 2003; 31: 540–47