

COLECISTECTOMIA VIDEOLAPAROSCÓPICA SIMPLIFICADA COM DUAS INCISÕES

Simplified laparoscopic cholecystectomy with two incisions

Rafael Antoniazzi **ABAID**¹, Ivan **CECCONELLO**², Bruno **ZILBERSTEIN**²

From the ¹Hospital Santa Cruz, UNISC (Santa Cruz Hospital, UNISC), Santa Cruz do Sul, RS and ²Hospital das Clínicas, Faculdade de Medicina, Universidade de São Paulo (Clinic Hospital, School of Medicine, University of São Paulo), São Paulo, SP, Brazil.

HEADINGS - Cholecystectomy, laparoscopic. Cholecystitis. Cholelithiasis. Minimally invasive surgical procedures.

Correspondence:

Rafael Antoniazzi Abaid
rafaelabaid@unisc.br

Financial source: none
Conflicts of interest: none

Received for publication: 21/01/2014
Accepted for publication: 27/02/2014

DESCRIPTORES - Colecistectomia laparoscópica. Colecistite. Colelitíase. Procedimentos cirúrgicos minimamente invasivos.

ABSTRACT – Background: Laparoscopic cholecystectomy has traditionally been performed with four incisions to insert four trocars, in a simple, efficient and safe way. **Aim:** To describe a simplified technique of laparoscopic cholecystectomy with two incisions, using basic conventional instrumental. **Technique:** In one incision in the umbilicus are applied two trocars and in epigastrium one more. The use of two trocars on the same incision, working in “x” does not hinder the procedure and does not require special instruments. **Conclusion:** Simplified laparoscopic cholecystectomy with two incisions is feasible and easy to perform, allowing to operate with ergonomics and safety, with good cosmetic result.

RESUMO – Racional: A colecistectomia videolaparoscópica vem tradicionalmente sendo realizada através de quatro incisões para inserção de quatro portais, de maneira simples, eficiente e segura. **Objetivo:** Descrever técnica de colecistectomia videolaparoscópica simplificada com duas incisões, utilizando instrumental convencional básico. **Técnica:** Na incisão da cicatriz umbilical aplicam-se dois portais e no epigástrico mais um portal. O uso de dois portais na mesma incisão, trabalhando em “x”, não dificulta a realização do procedimento e não requer instrumental especial. **Conclusão:** A colecistectomia videolaparoscópica simplificada com duas incisões é técnica de fácil execução, permitindo operar com ergonomia, segurança e com bom resultado estético.

INTRODUCTION

The evolution of laparoscopic surgery still faces many challenges. One is to become even less invasive. Laparoscopic cholecystectomy has traditionally been performed with four portals, simple, efficient and at low cost. Other ways have been described. To reduce the number of portals and achieve better cosmetic results, the authors have used wire traction in the gallbladder in place to forceps^{9,11}. Also, is described the use optical channels like work way¹⁵. Meanwhile, the operation through natural orifices (NOTES) has been used only in protocols^{7,13}. Although the new procedures try to reduce the number of portals and incisions, they increase the technical difficulties, the risk of complications and costs, which has been a barrier to its implementation. Of these procedures, the two most used are: minilaparoscopia^{10,14,4,16,7,8,9} and umbilical cholecystectomy through a single incision^{2,6,3,5,17,8,16,12, 18}.

Cholecystectomy by minilaparoscopy is very similar to conventional laparoscopic cholecystectomy, but uses smaller diameter trocar with delicate tweezers¹⁴. Thus, there is greater wear and shorter life of the device, increasing the cost. However, it has the advantage of using devices similar to conventional technique, which needs no further training. However, it requires four incisions, with an umbilical incision of 10 mm for the use of optics and removal of gallbladder^{14,1} and requires skill to do intracorporeal knot ligation of the cystic duct.

In single-incision cholecystectomy the procedure is performed by only one transumbilical incision; however, the incision is usually measured approximately 3 cm, beyond the limits of the umbilicus. It is preferably carried out with the use of a single portal and curved special clamps, which increases the cost^{5,17}. It may be accomplished with conventional instruments, but with lower angle between the clamps. Presents greater technical difficulty and longer learning curve³. As risk, may have even higher incidence of incisional hernia. Often this technique is used with a secondary incision in the right flank or right hypochondrium to better expose the operative field with additional traction⁵, which takes away the advantage of the single portal.

With the aim of reducing the number of incisions without using special materials and without increasing the technical difficulty, the authors propose a hybrid simplified laparoscopic technique for cholecystectomy with two incisions.

TECHNIC

The procedure is performed under general anesthesia and the patient supine in slight inclination position. Incision is held within the umbilicus about 15 mm. After completion of the pneumoperitoneum, abdominal incision is made for a 10 mm trocar. A second 10 mm trocar is inserted below the xiphoid process. With 30° 10 mm optical device in the epigastric portal, is possible to have vision of the insertion of a second 5 mm trocar inside the umbilical incision next to the 10 mm already inserted, penetrating the aponeurosis laterally to it (Figure 1).

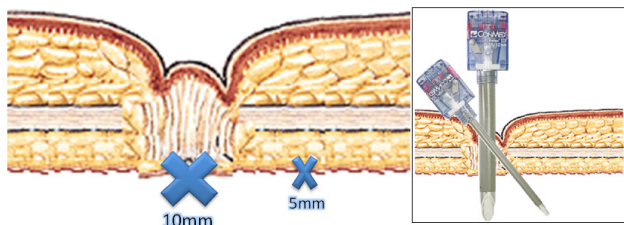


FIGURE 1 – Positioning of the two trocars in single umbilical incision

The procedure begins with the optics on the umbilicus, gripping forceps on the portal of 5 mm and a Maryland forceps in epigastric incision (Figure 2).

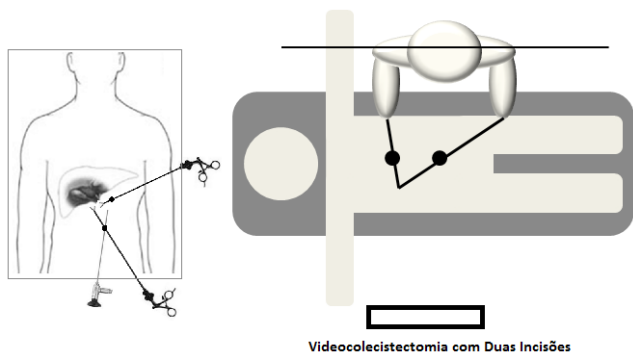


FIGURE 2 – Positioning of the instruments of labor and its ergonomic manipulation by the surgeon

A mononylon 000 with straight needle is inserted through the abdominal wall just below the right costal margin in the right midclavicular line. It transfix the body wall of the gallbladder and the needle is externalized near the site of entry into the cavity, rising and pulling the gallbladder, exposing the cisto-hepatic triangle (Calot, Figures 3 and 4).

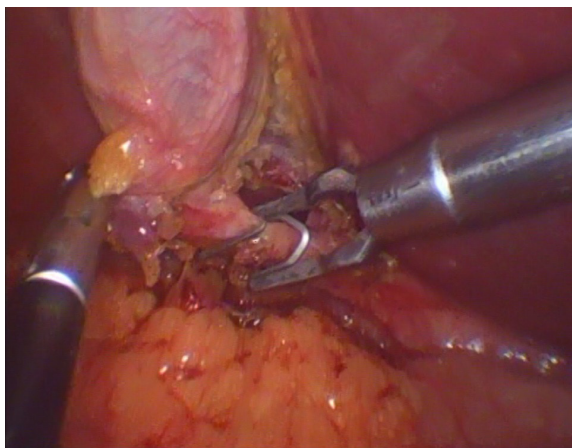


FIGURE 3 – Placement of clips closing the cystic duct

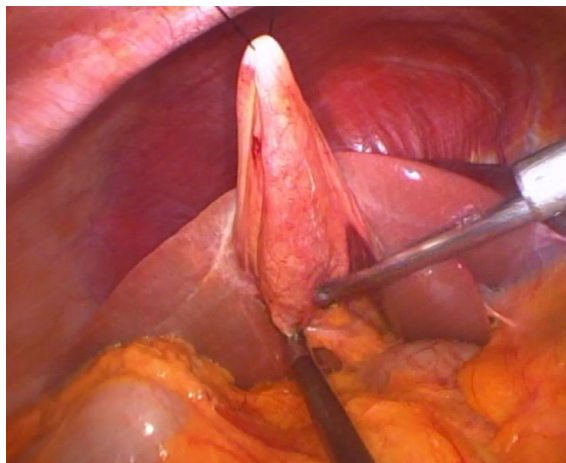


FIGURA 4 - Dissection of the gallbladder with electrocautery

The gripper is used to grip vesicular infundibulum and the trigone dissection is performed in the usual manner, through the epigastric portal. The cystic duct and artery are ligated with metal clips (Figure 3). Intraoperative cholangiography is conducted through intracath type 14G by transfixion of the abdominal wall (Figure 5). Then the gallbladder is dissected from the liver bed with hook electrocautery. The wire pulling the gallbladder is removed only at the moment when it is placed inside the extractor bag and withdrawn through the hole created for the epigastric portal.

RESULTS

This procedure was applied to 10 sequential patients, one male and nine female, mean age 38 years (21-62), with a mean operative time of 66 minutes (42-88) without complications. In three patients the clinical findings were of acute cholecystitis with intervention in emergency. In seven the procedure was elective. All patients were discharged within 24 hours.

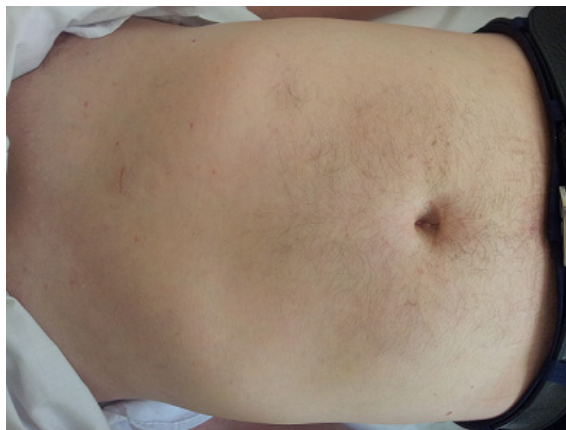


FIGURA 5 - Insertion of the catheter in the cystic duct cholangiography and final aspect of the operation after 60 days

DISCUSSION

The procedure uses only basic conventional material. No ancillary puncture is used. The first trocar insertion is performed according to the conventional technique, as used in any laparoscopic operation. The two subsequent punctures are made with direct visualization. The wire traction is applied on the body of the gallbladder, near the infundibulum, to achieve higher elevation next to liver. The handling of vesicular

infundibulum is accomplished through the trocar inserted 5 mm from the umbilicus. Due to not be much need to move this instrument, there is little impact on umbilical portal instruments. In addition, 30° optics is used medially, while the clamp pulls inferoanterolaterally the infundibulum. Thus, the portals work in "X" manner, allowing adequate freedom of movement of the instruments (Figure 2). The dissection is performed with complete freedom by the right hand of the surgeon, just as in conventional laparoscopic technique. Thus, dissection and ligation of the cystic duct and artery are performed in the conventional manner (Figure 3) with two clamps working at an angle of 90°. Thus, the surgeon is also free to insert the cholangiography catheter in the cystic duct (Figure 5). The gallbladder is dissected from the liver bed easily, but at the end of the dissection can be lower traction on the vesicle.

It should be mentioned that some difficulties may occur, such as bile leakage due to the use of thread traction in the gallbladder, the draw of the gallbladder at the end of its detachment, loss of gas in the collision between the umbilical portals. Routinely, the gallbladder is made empty at the beginning of the procedure, minimizing the leakage of bile. When there is a collision, the simple repositioning of portals solves the problem, i.e, the optic changes positions with tweezers posteriorly and vice-versa.

When compared to the technique using a single incision, it uses the same concept of reducing the incisions; however, the use of only two instruments in the umbilicus greatly reduces the incidence of collision of the device, allowing greater freedom of movement. The main difference is the use of a second incision to the working instrument of the surgeon that determines perfect triangulation between the clamps, allowing safe dissection in a similar manner to the conventional technique. No special equipment is necessary, even special abilities. It should also be noted that it is common in the art of using a single incision cholecystectomy, who use ancillary material such as endoloop or auxiliary tweezers in the right upper quadrant, making the hybrid technique and therefore eventually add more punches and thereby decreasing the possible aesthetic advantages of this procedure.

From the aesthetic point of view, this technique is superior to the conventional one, since only involves two scars (umbilical and epigastric) with the advantage of avoiding two incisions: one in subcostal site and another on the right (Figure 5).

The use of the traction instrument over gallbladder infundibulum in umbilicus allows the surgeon to work with shoulders and elbows in straight position; so, in more ergonomic way than the conventional technique (Figure 6).

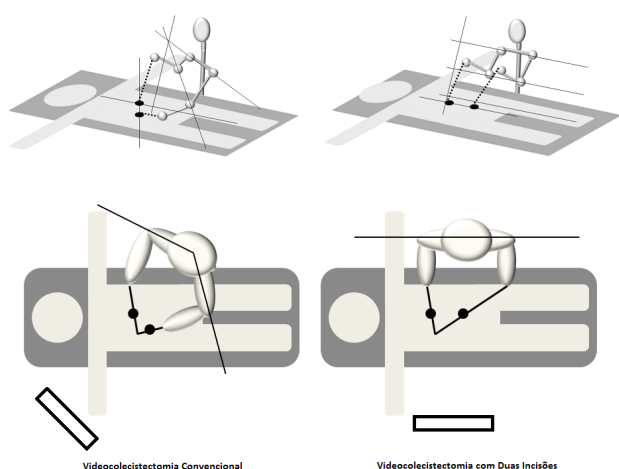


FIGURE 6 - Comparison of positioning and handling of surgical instruments in laparoscopic operation with four and two incisions, demonstrating its application on ergonomic and comfortable way

CONCLUSION

A simplified technique of laparoscopic cholecystectomy with two incisions is feasible, safe and with superior cosmetic results compared to conventional cholecystectomy.

REFERENCES

- Carvalho GL, Silva FW, Silva JSN, de Albuquerque PPC, Coelho RDMC, Vilaça TG, et al. Needlescopic clipless cholecystectomy as an efficient, safe, and cost-effective alternative with diminutive scars: the first 1000 cases. *Surg Laparosc Endosc Percutan Tech*. 2009;19(5):368–72.
- Cuesta M a, Berends F, Veenhof A a F a. The "invisible cholecystectomy": A transumbilical laparoscopic operation without a scar. *Surg Endosc* [Internet]. 2008 May;22(5):1211–3.
- Garijo Alvarez J, Sánchez López JD, González Elosua T, Gascón Hove M, García-Sancho Téllez L, Del Castillo Díez F, et al. [Laparoscopic transumbilical cholecystectomy. Results with the gel device and literature review]. *Cirugía española* [Internet]. 2010 May;87(5):293–8.
- Gurusamy K, Junnarkar S, Farouk M, Davidson BR. Meta-analysis of randomized controlled trials on the safety and effectiveness of day-case laparoscopic cholecystectomy. 2008;161–8.
- Hirano Y. Single-incision laparoscopic cholecystectomy: Single institution experience and literature review. *World J Gastroenterol* [Internet]. 2010;16(2):270.
- Hong TH, You YK, Lee KH. Transumbilical single-port laparoscopic cholecystectomy: scarless cholecystectomy. *Surg Endosc* [Internet]. 2009 Jun;23(6):1393–7.
- Horgan S, Mintz Y, Jacobsen GR, Sandler BJ, Cullen JP, Spivack A, et al. Video. NOTES: transvaginal cholecystectomy with assisting articulating instruments. *Surg Endosc* [Internet]. 2009 Aug;23(8):1900.
- Kojima Y, Tomiki Y, Sakamoto K. Our ideas for introduction of single-port surgery. *J Minim Access Surg* [Internet]. 2011 Jan;7(1):109–11.
- Kuroki T, Adachi T, Kitasato A, Okamoto T. Marionette Method for Laparoscopic Cholecystectomy: A New, Simple Technique. (Lc):729–31.
- Lai ECS, Fok M, Chan a SH. Needlescopic cholecystectomy: prospective study of 150 patients. *Hong Kong Med J*. 2003;9(4):238–42.
- Lomanto DMP, De Angelis LM, Ceci VM, Dalsasso GM, So JMF, Frattaroli FMM, et al. Two-Trocar Laparoscopic Cholecystectomy: A Reproducible Technique. *Surg Laparosc Endosc Percutan Tech*. 2001;
- Luna RA, Nogueira DB, Varela PS, Rodrigues Neto E de O, Norton MJR, Ribeiro L do CB, et al. A prospective, randomized comparison of pain, inflammatory response, and short-term outcomes between single port and laparoscopic cholecystectomy. *Surg Endosc* [Internet]. 2013 Apr;27(4):1254–9.
- Meining A, Spaun G, Fernández-Esparrach G, Arezzo A, Wilhelm D, Martinek J, et al. NOTES in Europe: summary of the working group reports of the 2012 EURO-NOTES meeting. *Endoscopy* [Internet]. 2013 Jan;45(3):214–7.
- Novitsky YW, Kercher KW, Czerniach DR, Kaban GK, Khera S, Gallagher-Dorval K a, et al. Advantages of mini-laparoscopic vs conventional laparoscopic cholecystectomy: results of a prospective randomized trial. *Arch Surg* [Internet]. 2005;140(12):1178–83.
- Poon C-M, Chan K-W, Ko C-W, Chan K-C, Lee DWH, Cheung H-Y, et al. Two-port laparoscopic cholecystectomy: initial results of a modified technique. *J Laparoendosc Adv Surg Tech A* [Internet]. 2002 Aug;12(4):259–62.
- Prasad A, Mukherjee KA, Kaul S, Kaur M. Postoperative pain after cholecystectomy: Conventional laparoscopy versus single-incision laparoscopic surgery. *J Minim Access Surg* [Internet]. 2011 Jan;7(1):24–7.
- Pryor AD, Tushar JR, DiBernardo LR. Single-port cholecystectomy with the TransEnterix SPIDER: simple and safe. *Surg Endosc* [Internet]. 2010 Apr;24(4):917–23.
- Saad S, Strassel V, Sauerland S. Randomized clinical trial of single-port, minilaparoscopic and conventional laparoscopic cholecystectomy. *Br J Surg* [Internet]. 2013 Feb;100(3):339–49.