

Preoperative Embolization of Cerebral Arteriovenous Malformations with Silk Suture and Particles: Technical Considerations and Outcomes

Jordan R. Conger¹, Dale Ding², Daniel M. Raper², Robert M. Starke³, Christopher R. Durst⁴, Kenneth C. Liu^{2,4}, Mary E. Jensen⁴, Avery J. Evans⁴

¹School of Medicine, University of Virginia, Charlottesville, VA, USA

²Department of Neurosurgery, University of Virginia, Charlottesville, VA, USA

³Department of Neurological Surgery, University of Miami, Miami, FL, USA

⁴Department of Radiology and Medical Imaging, University of Virginia, Charlottesville, VA, USA

Objective : Embolization of cerebral arteriovenous malformations (AVMs) is commonly performed prior to surgical resection in order to reduce intraoperative bleeding and improve the safety of resection. Although most modern embolization procedures utilize permanent embolic agents, silk suture and polyvinyl alcohol (PVA) particles may offer unique advantages for preoperative devascularization. The aims of this retrospective cohort study are to describe the technical considerations and determine the outcomes for preoperative silk suture and PVA particle embolization (SPE) of AVMs.

Materials and Methods : We performed a retrospective review of our AVM embolization database. AVM patients who underwent preoperative SPE and subsequent surgical resection were included for analysis. Baseline patient demographics, AVM characteristics, embolization and operative records, and post-treatment outcomes were reviewed.

Results : A total of 11 patients who underwent 12 preoperative SPE procedures were included for analysis. Five AVMs were ruptured (45%), and the median nidus volume was 3.0 cm³ (range: 1.3-42.9 cm³). The Spetzler-Martin grade was I-II in seven patients (64%) and III-IV in four patients (36%). The degree of nidal obliteration was less than 25% in two procedures (17%), 25-50% in one procedure (8%), 50-75% in eight procedures (67%), and greater than 75% in one procedure (8%). The rates of post-embolization AVM hemorrhage and mortality were 8% and 0%, respectively. The postoperative angiographic obliteration rate was 100%, and the modified Rankin Scale score improved or stable in 91% of patients (median follow-up duration 2 months).

Conclusion : Preoperative AVM SPE affords a reasonable risk to benefit profile for appropriately selected patients.

Keywords Endovascular procedures, Intracranial arteriovenous malformation, Intracranial hemorrhages, Microsurgery, Stroke, Vascular malformations

J Cerebrovasc Endovasc Neurosurg.
2016 June;18(2):90-99

Received : 3 July 2015

Revised : 25 March 2016

Accepted : 30 May 2016

Correspondence to Avery J. Evans

Department of Radiology and Medical Imaging,
University of Virginia, P.O. Box 800170, VA
22908, USA

Tel : 1-434-924-9719

Fax : 1-434-982-3880

E-mail : aje5u@virginia.edu

ORCID : <http://orcid.org/0000-0002-2627-446X>

This is an Open Access article distributed under the terms of the Creative Commons Attribution Non-Commercial License (<http://creativecommons.org/licenses/by-nc/3.0>) which permits unrestricted non-commercial use, distribution, and reproduction in any medium, provided the original work is properly cited.

INTRODUCTION

Treatment options for cerebral arteriovenous malformations (AVMs) have evolved rapidly over the past

two decades, although the optimal management paradigm remains controversial.³⁵⁾ Advances in microsurgical techniques and equipment, technologies for endovascular embolization, and stereotactic radiosurgery (SRS) have resulted in a number of safe and effective treatments, but selecting an appropriate treatment strategy remains challenging in many cases.¹⁻⁵⁾¹²⁻³⁰⁾³⁶⁾³⁷⁾³⁹⁻⁴¹⁾⁴⁹⁻⁵²⁾⁵⁴⁾⁵⁷⁾ Of the various interventional options for AVMs, surgical resection remains the gold standard.¹¹⁾³³⁾³⁴⁾⁴⁸⁾

Preoperative embolization is a valuable neo-adjuvant treatment that has been shown to be effective in decreasing operative time, blood loss, and morbidity and mortality.¹⁰⁾ The majority of modern AVM embolization is performed using ethylene vinyl alcohol copolymer (Onyx; ev3 Neurovascular, Irvine, California, USA).⁴³⁾ However, at our institution, we have found that more traditional embolic agents, such as silk suture and polyvinyl alcohol (PVA) particles, offer unique advantages over Onyx for preoperative devascularization of appropriately selected nidi.

The aims of this retrospective cohort study are to (1) describe our technique for silk suture and PVA particle embolization (SPE) of cerebral AVMs and (2) analyze the post-embolization and postoperative angiographic and clinical outcomes in a modern, single-center series.

MATERIALS AND METHODS

Patients selection and study design

We performed a retrospective review of all patients who underwent preoperative embolization of cerebral AVMs at the University of Virginia between January 2000 and June 2013. Inclusion criteria for the study were (1) preoperative SPE of the AVM nidus, (2) AVM surgical resection performed at our institution, (3) sufficient data to ascertain baseline patient demographics, nidus angioarchitecture, and post-treatment clinical and angiographic outcomes. Exclusion criteria were (1) patients with vascular malformations other than AVMs, (2) nidi primarily embolized with agents other than silk suture and PVA particles, and (3) AVMs surgically resected at other institutions. Concomitant

use of embolic agents other than silk suture or PVA particles, such as detachable coils, was noted. Inpatient and outpatient medical charts and imaging were reviewed for patient and AVM characteristics, pathologic details, intraoperative findings, complications, and outcomes. This study was approved by the University of Virginia institutional review board (IRB).

Embolization procedure

Selection of AVMs for pre-operative SPE was made on an individualized basis after a discussion between the neurosurgeon and neurointerventionalist regarding the nidus angioarchitecture. All cases were performed using high-resolution biplane digital subtraction angiography under general anesthesia. Access to the femoral artery was obtained in standard fashion. Intravenous heparin was intermittently administered throughout the procedure to achieve an activated clotting time (ACT) of between 250-300 seconds. The heparin was not reversed following the procedure.

A diagnostic angiogram of the bilateral internal and external carotid arteries and vertebral arteries was performed in order to define the nidus angioarchitecture, including feeding arteries, draining veins, presence of arterial or venous aneurysms, intranidal arteriovenous shunts, and/or venous strictures. After determining the most appropriate arterial branch for embolization, a microcatheter, most commonly an Echelon 10 (ev3 Neurovascular, Plymouth, MN, USA), was advanced into the target pedicle under roadmap guidance, and embolization was performed. Multiple cut portions of silk suture threads, approximately 0.5 mm in length, and PVA particles were deployed into the pedicle via the microcatheter until adequate devascularization of the targeted portion of the nidus was achieved, as deemed by the treating neurointerventionalist. Generally, the silk suture was deployed first followed by PVA particles. Control angiograms were intermittently performed after SPE of each arterial branch to assess the degree of nidal devascularization. Deployment of other embolic agents, such as Gelfoam (Pfizer, New York, NY, USA) or coils, was performed, as necessary, after initial SPE in order to improve nidus devascularization

and/or to prevent reflux of the silk suture and particles. A final control angiogram was performed after the embolization procedure to assess the residual nidus.

Baseline variables and treatment outcomes

Patient variables were gender, age, clinical presentation, and medical comorbidities. AVM variables were location, venous drainage pattern, maximum nidus diameter, nidus volume, Spetzler-Martin grade, and presence of associated arterial and venous aneurysms.⁴⁸⁾ Maximum nidus diameter was measured on pre-embolization angiography. AVMs were assumed to be ellipsoid and the volume was calculated accordingly. The embolization variable was the embolic agent used. Surgical variables were amount of intraoperative blood loss and duration of procedure.

Treatment outcomes were stratified by post-embolization and post-surgical outcomes. Post-embolization outcomes were degree of AVM nidus obliteration,

modified Rankin Scale (mRS) after embolization (prior to surgery), and procedural complications. Post-embolization angiograms were assessed for the volume of residual nidus compared to the pre-embolization angiogram. The degree of AVM obliteration was categorized as < 25%, 25-50%, 50-75%, and > 75%. Post-surgical outcomes were degree of AVM nidus obliteration (based on postoperative angiography), postoperative complications, and mRS at the most recent clinical follow-up. All imaging studies were reviewed by a neurosurgeon and neuroradiologist at our institution. Categorical variables were reported as a frequency, and continuous variables were reported as a median and range.

RESULTS

Study population and clinical presentation

A total of 17 AVM patients underwent 24 SPE pro-

Table 1. Patient and AVM characteristics (N = 11)

	Number		Number
Patient characteristics		AVM Characteristics	
Female (%)	8 (73%)	Supratentorial (%)	10 (91%)
Median age at diagnosis (range)	32 (13-74)	Right sided (%)	9 (82%)
Clinical presentation		Location	
Headache	8 (73%)	Occipital	4 (36%)
Visual deficit	8 (73%)	Frontal	3 (27%)
Sensory deficit	6 (55%)	Parietal	1 (9%)
ICH	5 (45%)	Parieto-occipital	1 (9%)
Seizure	3 (27%)	Temporal	1 (9%)
Incidental finding	2 (18%)	Cerebellar	1 (9%)
Motor weakness	1 (9%)	Eloquent location	7 (64%)
Syncope	1 (9%)	Venous drainage	
mRS at Baseline		Superficial and deep	7 (64%)
0	0	Superficial	4 (36%)
1	5 (45%)	Median nidus diameter (range, cm)	2.4 (1.6-7.3)
2	2 (18%)	Median nidus volume (range, cm ³)	3.0 (1.3-42.9)
3	0	Spetzler-Martin grade	
4	2 (18%)	I	0
5	2 (18%)	II	7 (64%)
6	0	III	2 (18%)
Comorbidities		IV	2 (18%)
Smoking	4 (36%)	V	0
Hypertension	3 (27%)	Associated aneurysm	
Hypercholesterolemia	3 (27%)	Arterial	2 (18%)
Prior AVM hemorrhage	5 (45%)	Nidus	4 (36%)
Prior AVM treatments (number of patients)		Venous	5 (45%)
Embolization	3		
Gamma knife	2		

ICH = intracranial hemorrhage; AVM = arteriovenous malformation

cedures during the study period. Six patients (12 SPE procedures) were excluded for subsequent treatment with SRS (four patients) or undergoing surgery at another institution (two patients). This yielded 11 patients who underwent 12 preoperative SPE procedures for analysis. The patient and AVM characteristics are summarized in Table 1. Eight patients were female (73%). The median age of all patients was 32 years (range 13 to 74 years) at the time of initial SPE. The most frequent clinical symptoms at presentation were headache and visual deficit, each in eight patients (72%), sensory deficit in six patients (55%), intracranial hemorrhage (ICH) in five patients (45%; two cases each of intracerebral and intraventricular hemorrhage, one case of subarachnoid hemorrhage), and seizure in three patients (27%). Medical comorbidities included smoking in four patients (36%) and hypertension and hypercholesterolemia each in 3 patients (27%). The mRS scores at presentation were 2 or lower in seven patients (64%) and 3 or greater in four patients (36%). Three patients (27%) underwent prior embolization treatment with material other than silk and PVA particles, and two patients (18%) underwent prior Gamma Knife SRS.

AVM Characteristics

AVMs were supratentorial in 10 cases (91%). They were localized to the right side in nine cases (82%), to the left side in one case (9%), and in the midline in one case (9%). The most common AVM locations were occipital in four cases (36%) and frontal in three cases (27%). Seven nidi were located in eloquent areas (64%), and seven nidi had a component of deep venous drainage (64%). The Spetzler-Martin grade was II in seven patients (64%) and III and IV each in two patients (18%). AVMs were associated with arterial and venous aneurysms in six (55%) and five (45%) cases, respectively.

AVM embolization outcomes with silk suture and PVA particles

The embolization procedural details and outcomes

Table 2. Embolization outcomes and complications (N = 12)

	Number
Embolitic agent	
4-0 Silk suture	10 (83%)
3-0 Silk suture	2 (17%)
PVA (150-250 microns)	7 (58%)
PVA (250-350 microns)	5 (42%)
PVA (350-500 microns)	5 (42%)
PVA (500-700 microns)	1 (8%)
Onyx 18	1 (8%)
Coils	7 (58%)
AVM Obliteration	
0-25%	2 (17%)
25-50%	1 (8%)
50-75%	8 (67%)
75-100%	1 (8%)
mRS after embolization*	
0	0
1	4 (33%)
2	2 (17%)
3	0
4	3 (25%)
5	3 (25%)
6	0
mRS compared to baseline	
Improved	1 (8%)
Unchanged	10 (83%)
Worsened	1 (8%)
Complications	
Hemorrhage [†] (%)	1 (8%)
Weakness [†] (%)	1 (8%)

PVA = polyvinyl alcohol; AVM = arteriovenous malformation; mRS = modified Rankin Scale.
 *mRS determined at latest date after embolization, before surgical resection.
[†]The complications of hemorrhage and weakness occurred in the same patient.

are summarized in Table 2. In the 12 SPE procedures, the degree of AVM obliteration was < 25% in two cases (17%), 25-50% in one case (8%), 50-75% in eight cases (67%), and > 75% in one case (8%). The arterial pedicle was occluded with coils after SPE in seven cases (58%). Post-embolization complications consisted of ICH, with accompanying hemiparesis, in one patient (8%). There were no cases of post-embolization ischemia, based on clinical or radiologic assessments. Post-embolization mRS was improved in one patient (8%), unchanged in 10 patients (83%), and worsened in one patient (8%).

AVM surgical outcomes

The details and outcomes of the AVM surgical procedures are summarized in Table 3. Of the 11 patients who underwent surgical resection at our institution,

Table 3. Microsurgical outcomes and complications (N = 11)

	Number
Median EBL (mL, range)	600 (200-4500)
Median operative duration (minutes, range)	326 (237-579)
Obliteration number (%)	11 (100%)
Clinical follow-up duration (months, range)	2 (1-156.5)
mRS at last follow-up	
0	1 (9%)
1	4 (36%)
2	2 (18%)
3	1 (9%)
4	2 (18%)
5	0
6	1 (9%)
mRS compared to baseline	
Improved	6 (55%)
Unchanged	4 (36%)
Worsened	1 (9%)
Complications	
Seizure (n, %)	1 (9%)
Weakness (n, %)	2 (18%)
Sensory change (n, %)	1 (9%)
Visual deficit (n, %)	5 (45%)
Ataxia	1 (9%)
UTI	1 (9%)
Meningitis	1 (9%)
DVT	1 (9%)
Death (n, %)	1 (9%)
Interventions Post Surgery (number of patients)	1 (9%)
PEG tube	2 (18%)
Botox chemodeneration	

mRS = modified Rankin Scale; DVT = deep vein thrombosis; UTI = urinary tract infection; PEG = percutaneous endoscopic gastrostomy; Botox = botulinum toxin

at a median interval of one day (range 1 to 3 days) after the most recent SPE embolization, the median estimated intraoperative blood loss was 600 mL (range 200 to 4,500 mL), and the median operative duration was 326 minutes (range 237 to 579 minutes). Based on postoperative angiography (Fig. 1), complete AVM obliteration was achieved in all cases (100%).

At the most recent clinical follow-up (median duration 2 months, range 1 to 156.5 months), the mRS score was 0 in one patient (9%), 1 in four patients (36%), 2 in two patients (18%), 3 in one patient (9%), 4 in two patients (18%), and 6 in one patient (9%). Compared to baseline, six patients (55%) showed improvement from their mRS score, four patients (36%) were unchanged, and one patient (9%) worsened. Postoperative surgical and medical complications included visual deficit in five patients (45%), weakness

in two patients (18%), and seizures, sensory changes, ataxia, urinary tract infection, meningitis, deep vein thrombosis, and death each in one patient (9%). Additional interventions performed after AVM resection included botulinum toxin chemodeneration in two patients (18%), and percutaneous endoscopic gastrostomy tube placement in one patient (9%).

DISCUSSION

Preoperative AVM embolization confers a number of potential advantages.^{6,7)} By reducing intraoperative blood loss during AVM surgical resection, preoperative embolization may improve the safety of these procedures by potentially decreasing the technical difficulty of resection and operative duration.¹⁰⁾ Embolic agents can be used to mark arterial feeding vessels, which can be difficult to differentiate from arterialized draining veins intraoperatively. Preoperative embolization also devascularizes the deep portions of an AVM nidus, which are difficult to access intraoperatively and are not typically encountered until the later stages of AVM dissection. Premature intraoperative hemorrhage from the deep portion of a nidus can be difficult to control. Thus, preoperative embolization may facilitate AVM circumdissection and extirpation.

In addition to silk suture and PVA particles, cyanoacrylates (e.g. NBCA) and Onyx are two embolic agents used to treat AVMs. NBCA was approved in 2000 after it was shown to be equivalent to PVA for AVM embolization.³⁸⁾ While embolization with NBCA may provide a more thorough and durable nidus devascularization than SPE, NBCA embolization carries a risk of microcatheter tip entrapment within the embolic cast, which can precipitate AVM hemorrhage upon forcible withdrawal of the microcatheter.^{8,56)} Additionally, if NBCA is deployed too rapidly, the target artery may become occluded prior to adequate nidus penetration. Furthermore, the draining vein can become occluded before adequate nidus penetration is achieved and arteriovenous shunting is halted, causing a significant

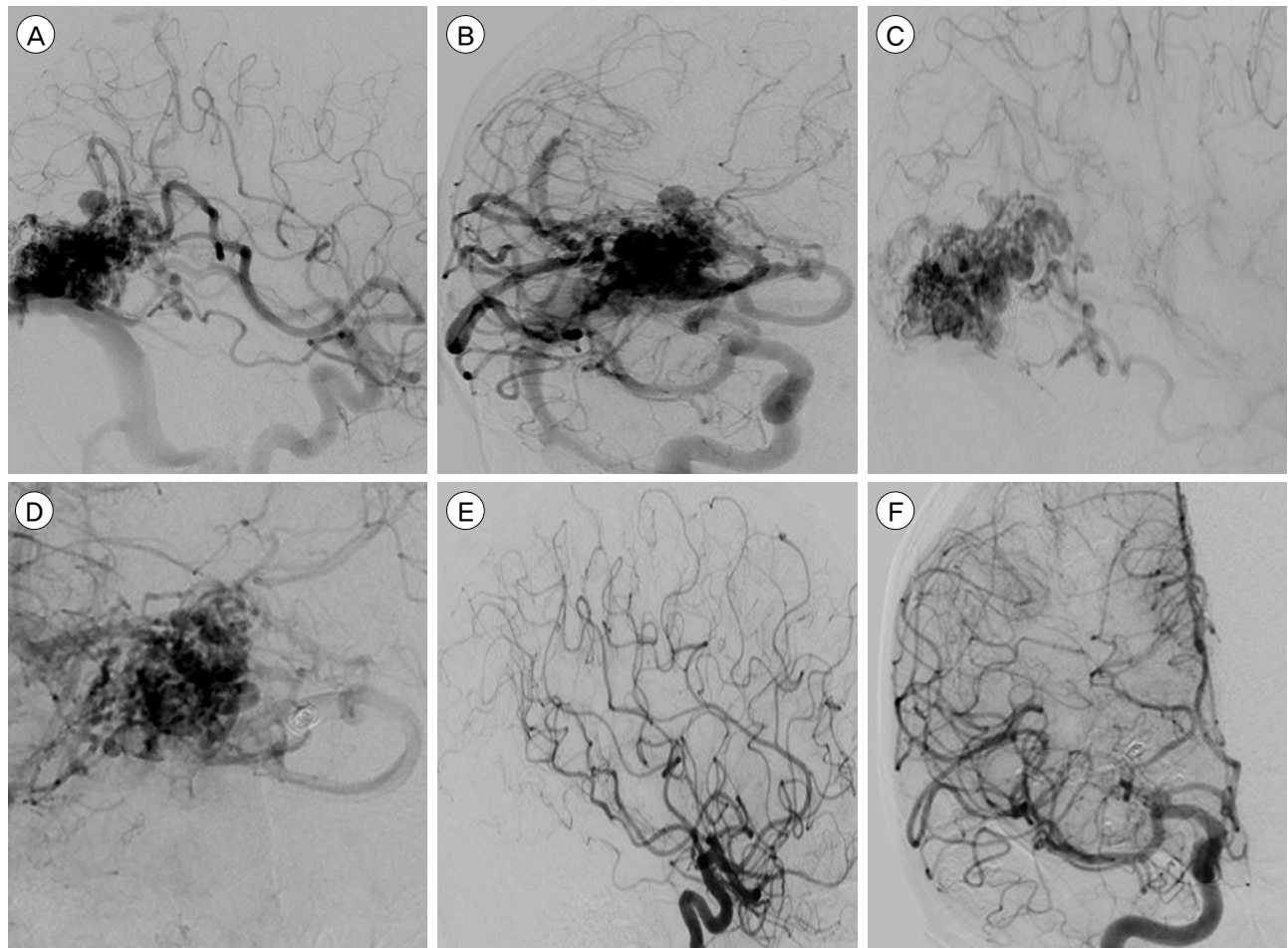


Fig. 1. Cerebral angiography, (A) lateral and (B) AP views of a right internal carotid artery (ICA) injection, shows a 2.9x1.6x1.7 cm nidus in the posterior occipitotemporal region with a 7 mm intranidal aneurysm. The arterial supply is from the branches of the right middle cerebral artery (MCA) and posterior cerebral artery (PCA), through an enlarged fetal posterior communicating artery, and venous drainage is strictly superficial into the superior sagittal and right transverse sinuses. This Spetzler-Martin grade II arteriovenous malformation (AVM) was embolized through the right PCA branch feeding artery with 4-0 silk suture, 350-500 μ m polyvinyl alcohol particles, and a single 2x6 hydrocoil. The MCA branch feeder could not be safely embolized due to en passage supply to normal brain parenchyma. Post-embolization angiography, (C) lateral and (D) AP views of a right ICA injection, shows less than 25% AVM devascularization, but significantly reduced arterial supply from the embolized PCA branch. Postoperative angiography, (E) lateral and (F) AP views of a right ICA injection, performed six months after surgical resection, shows no evidence of residual nidus.

increase in intranidal pressure, thereby incurring a much higher risk of rupture.

Onyx is a permanent liquid embolic agent that is dissolved in dimethyl sulfoxide (DMSO). Once DMSO diffuses into the blood, Onyx precipitates and leads to vascular occlusion.⁵³⁾ Although Onyx may provide superior AVM devascularization compared to either NBCA or silk suture and PVA particles, its risks should be noted. There have been reports linking DMSO to vessel necrosis and neuronal swelling.⁴⁴⁾ Similar to NBCA, there is also an unavoidable risk of microcatheter en-

trapment with Onyx embolization, although new microcatheters with detachable tips may lessen the concern for this complication.³²⁾⁵⁵⁾ Finally, although AVM embolization with NBCA and Onyx can be curative, there remains a small risk of recurrence even after complete angiographic obliteration. Since no single embolic agent, or combination of agents, has been accepted as a clear favorite for AVM devascularization, the nature of each individual nidus and the goals of embolization should be considered when determining the embolic agent of choice for a particular case.

Future developments in endovascular technology may further improve the safety of modern embolic agents.

In this study, we report the detailed outcomes of 11 AVM patients who underwent 12 preoperative SPE procedures. The proportion of patients who presented with AVM rupture was 45%, which is slightly higher than prior silk suture embolization series.^{9,45)} One patient, who had a ruptured AVM, experienced post-embolization hemorrhage (8%). In comparison, the rates of AVM hemorrhage after Onyx embolization are as high as 12.5% for ruptured, and 1.6% for unruptured AVMs.³²⁾ Although complete AVM occlusion can rarely be achieved with SPE and a significant degree of devascularization may be challenging for SPE of large AVMs, the degree of volume reduction was at least 50% for the majority of SPE procedures (75%). Surgical AVM resection resulted in complete obliteration in all patients (100%), with worsened post-operative mRS in only one patient (9%). Additionally, 64% of patients were functionally independent at a median follow-up duration of two months. Therefore, multimodality AVM management with preoperative SPE and subsequent surgical resection remains a viable combined approach in the modern era.

Reports of AVM embolization with PVA and silk suture are relatively sparse in the literature, due to an overall preference for NBCA and Onyx by many neurointerventionalists. Schmutz et al. reported a series in which silk suture was the main embolic agent in 73 AVM patients, and reported a 1.4% post-embolization hemorrhage rate.⁴⁵⁾ Histopathological analysis of four patients who underwent silk suture embolization showed an absence or mild amounts of perivascular inflammation and vasculitis.⁴⁶⁾ In addition to its relatively favorable clinical and histopathological profile, silk suture has a number of definite advantages as an embolic agent.^{9,47)} Silk suture is inexpensive, readily available, easy to manipulate, allows for continuous radiographic monitoring of the microcatheter during and after embolization, and does not interfere with the use of other embolic agents. There

is no risk of microcatheter entrapment, as with cyanoacrylates and Onyx.^{8,32,55)} The relatively large cross section of silk suture decreases the risk of inadvertent premature occlusion of a draining vein, although there is limited data to show that the rate of post-embolization AVM hemorrhage is lower with silk suture compared to other embolic agents.

Nidal embolization with PVA particles and silk suture can be performed from a proximally located microcatheter, so that the microcatheter does not have to be positioned within the nidus to proceed with silk suture embolization.⁹⁾ Therefore, less microguidewire and microcatheter navigation are necessary to perform AVM embolization with PVA particles and silk suture, which may reduce the risk of vascular injury to feeding arteries. However, we avoided embolization of arterial pedicles with an en passage branch or terminal feeding vessel located distal to the microcatheter tip, in order to avoid inadvertent ischemic complications. Whereas Onyx, cyanoacrylates, and microcoils stiffen an AVM nidus, thereby impairing surgical manipulation, silk suture devascularizes the nidus and marks the feeding arteries without significantly affecting its inherent maneuverability and tactile response.^{9,42,47)} Furthermore, we have not found silk suture embolization to result in significant arachnoid scarring, which can occur to a significant extent with permanent agents such as Onyx. This preserves the dissection plane between the AVM and the normal brain parenchyma, thus facilitating surgical resection. A disadvantage of silk suture is its radiolucency, so one cannot readily track the distribution of silk suture during and after embolization. The use of radiopaque silk sutures with platinum markers has been proposed to overcome this limitation, although its clinical implications have not been thoroughly evaluated.³¹⁾

The interpretation of our results is limited, in part, by the study design as a retrospective, single-center cohort study. Thus, our study is subject to the selection biases of the neurointerventionalists and neu-

rosurgeons at our institution. The cohort size is relatively small, which prohibits rigorous statistical analysis for predictors of favorable outcome and complications. Without an equivalent cohort of non-embolized AVMs or nidus embolized with other agents, we are unable to assess the comparative effectiveness of SPE. Additionally, we are unable to determine if specific angioarchitectural patterns or nidus morphologies are more suited for devascularization with SPE. Larger cohorts of preoperative SPE of AVMs with longer follow-up durations are needed to fully characterize the role of this approach in the modern management of AVM patients.

CONCLUSION

In our experience, preoperative AVM embolization with silk suture and PVA particles affords a reasonable risk to benefit profile. Although larger studies are necessary to define the role of these embolic agents in the overall management of AVMs, we believe they can be employed with relative technical ease and favorable clinical safety prior to surgical resection of nidus in appropriately selected patients.

Disclosure

The authors report no conflict of interest concerning the materials or methods used in this study or the findings specified in this paper.

REFERENCES

1. Awad AJ, Walcott BP, Stapleton CJ, Ding D, Lee CC, Loeffler JS. Repeat radiosurgery for cerebral arteriovenous malformations. *J Clin Neurosci*. 2015 Jun;22(6):945-50.
2. Buell TJ, Ding D, Starke RM, Webster Crowley R, Liu KC. Embolization-induced angiogenesis in cerebral arteriovenous malformations. *J Clin Neurosci*. 2014 Nov;21(11):1866-71.
3. Chen CJ, Chivukula S, Ding D, Starke RM, Lee CC, Yen CP, et al. Seizure outcomes following radiosurgery for cerebral arteriovenous malformations. *Neurosurg Focus*. 2014 Sep;37(3):E17.
4. Cohen-Inbar O, Ding D, Chen CJ, Sheehan JP. Stereotactic radiosurgery for deep intracranial arteriovenous malformations, part 1: Brainstem arteriovenous malformations. *J Clin Neurosci*. 2016 Feb;24:30-6.
5. Cohen-Inbar O, Ding D, Sheehan JP. Stereotactic radiosurgery for deep intracranial arteriovenous malformations, part 2: Basal ganglia and thalamus arteriovenous malformations. *J Clin Neurosci*. 2016 Feb;24:37-42.
6. Crowley RW, Ducruet AF, Kalani MY, Kim LJ, Albuquerque FC, McDougall CG. Neurological morbidity and mortality associated with the endovascular treatment of cerebral arteriovenous malformations before and during the Onyx era. *J Neurosurg*. 2015 Jun;122(6):1492-7.
7. Crowley RW, Ducruet AF, McDougall CG, Albuquerque FC. Endovascular advances for brain arteriovenous malformations. *Neurosurgery*. 2014 Feb;74 Suppl 1:S74-82.
8. Debrun GM, Aletich VA, Shownkeen H, Ausman J. Glued Catheters during Embolisation of Brain AVMs with Acrylic Glue. *Interv Neuroradiol*. 1997 Mar 30;3(1):13-9.
9. Dehdashti AR, Muster M, Reverdin A, de Tribolet N, Ruefenacht DA. Preoperative silk suture embolization of cerebral and dural arteriovenous malformations. *Neurosurg Focus*. 2001;11(5):e6.
10. DeMeritt JS, Pile-Spellman J, Mast H, Moohan N, Lu DC, Young WL, et al. Outcome analysis of preoperative embolization with N-butyl cyanoacrylate in cerebral arteriovenous malformations. *AJNR Am J Neuroradiol*. 1995 Oct;16(9):1801-7.
11. Ding D, Liu KC. Predictive Capability of the Spetzler-Martin versus supplementary grading scale for microsurgical outcomes of cerebellar arteriovenous malformations. *J Cerebrovasc Endovasc Neurosurg*. 2013 Dec;15(4):307-10.
12. Ding D, Quigg M, Starke RM, Xu Z, Yen CP, Przybylowski CJ, et al. Radiosurgery for temporal lobe arteriovenous malformations: effect of temporal location on seizure outcomes. *J Neurosurg*. 2015 Oct;123(4):924-34.
13. Ding D, Quigg M, Starke RM, Yen CP, Przybylowski CJ, Dodson BK, et al. Cerebral arteriovenous malformations and epilepsy, Part 2: predictors of seizure outcomes following radiosurgery. *World Neurosurg*. 2015 Sep;84(3):653-62.
14. Ding D, Sheehan JP, Starke RM, Durst CR, Raper DM, Conger JR, et al. Embolization of cerebral arteriovenous malformations with silk suture particles prior to stereotactic radiosurgery. *J Clin Neurosci*. 2015 Oct;22(10):1643-9.
15. Ding D, Starke RM, Kano H, Lee JY, Mathieu D, Pierce J, et al. Stereotactic radiosurgery for Spetzler-Martin Grade III arteriovenous malformations: an international multicenter study. *J Neurosurg*. 2016 Apr 15:1-13. [Epub ahead of print]
16. Ding D, Starke RM, Kano H, Mathieu D, Huang P, Kondziolka D, et al. Radiosurgery for cerebral arteriovenous malformations in a randomized trial of unruptured brain arteriovenous malformations (ARUBA)-eligible patients: a multicenter study. *Stroke*. 2016 Feb;47(2):342-9.
17. Ding D, Starke RM, Liu KC, Crowley RW. Cortical plasticity in patients with cerebral arteriovenous malformations. *J Clin Neurosci*. 2015 Dec;22(12):1857-61.
18. Ding D, Starke RM, Quigg M, Yen CP, Przybylowski CJ, Dodson BK, et al. Cerebral Arteriovenous Malformations and Epilepsy, Part 1: Predictors of Seizure Presentation. *World Neurosurg*. 2015 Sep;84(3):645-52.
19. Ding D, Starke RM, Yen CP, Sheehan JP. Radiosurgery

- for cerebellar arteriovenous malformations: does infratentorial location affect outcome? *World Neurosurg.* 2014 Jul-Aug;82(1-2):e209-17.
20. Ding D, Xu Z, Shih HH, Starke RM, Yen CP, Sheehan JP. Stereotactic radiosurgery for partially resected cerebral arteriovenous malformations. *World Neurosurg.* 2016 Jan;85:263-72.
 21. Ding D, Xu Z, Starke RM, Yen CP, Shih HH, Buell TJ, et al. Radiosurgery for cerebral arteriovenous malformations with associated arterial aneurysms. *World Neurosurg.* 2016 Mar;87:77-90.
 22. Ding D, Xu Z, Yen CP, Starke RM, Sheehan JP. Radiosurgery for cerebral arteriovenous malformations in elderly patients: effect of advanced age on outcomes after intervention. *World Neurosurg.* 2015 Sep;84(3):795-804.
 23. Ding D, Xu Z, Yen CP, Starke RM, Sheehan JP. Radiosurgery for unruptured cerebral arteriovenous malformations in pediatric patients. *Acta Neurochir (Wien).* 2015 Feb;157(2):281-91.
 24. Ding D, Yen C, Starke RM, Xu Z, Sheehan JP. Effect of prior hemorrhage on intracranial arteriovenous malformation radiosurgery outcomes. *Cerebrovasc Dis.* 2014 Dec 24;39(1):53-62.
 25. Ding D, Yen CP, Starke RM, Xu Z, Sheehan JP. Radiosurgery for ruptured intracranial arteriovenous malformations. *J Neurosurg.* 2014 Aug;121(2):470-81.
 26. Ding D, Yen CP, Starke RM, Xu Z, Sun X, Sheehan JP. Outcomes following single-session radiosurgery for high-grade intracranial arteriovenous malformations. *Br J Neurosurg.* 2014 Oct;28(5):666-74.
 27. Ding D, Yen CP, Starke RM, Xu Z, Sun X, Sheehan JP. Radiosurgery for Spetzler-Martin Grade III arteriovenous malformations. *J Neurosurg.* 2014 Apr;120(4):959-69.
 28. Ding D, Yen CP, Xu Z, Starke RM, Sheehan JP. Radiosurgery for low-grade intracranial arteriovenous malformations. *J Neurosurg.* 2014 Aug;121(2):457-67.
 29. Ding D, Yen CP, Xu Z, Starke RM, Sheehan JP. Radiosurgery for patients with unruptured intracranial arteriovenous malformations. *J Neurosurg.* 2013 May;118(5):958-66.
 30. Ding D, Yen CP, Xu Z, Starke RM, Sheehan JP. Radiosurgery for primary motor and sensory cortex arteriovenous malformations: outcomes and the effect of eloquent location. *Neurosurgery.* 2013 Nov;73(5):816-24.
 31. Guglielmi G, Benati A, Perini S. Endovascular embolization with radiopaque silk threads: a feasibility study in Swine. *Interv Neuroradiol.* 2006 Jun 15;12(2):109-12.
 32. Katsaridis V, Papagiannaki C, Aimar E. Curative embolization of cerebral arteriovenous malformations (AVMs) with Onyx in 101 patients. *Neuroradiology.* 2008 Jul;50(7):589-97.
 33. Kim H, Abla AA, Nelson J, McCulloch CE, Bervini D, Morgan MK, et al. Validation of the supplemented spetzler-martin grading system for brain arteriovenous malformations in a multicenter cohort of 1009 surgical patients. *Neurosurgery.* 2015 Jan;76(1):25-33.
 34. Lawton MT, Kim H, McCulloch CE, Mikhak B, Young WL. A supplementary grading scale for selecting patients with brain arteriovenous malformations for surgery. *Neurosurgery.* 2010 Apr;66(4):702-13; discussion 13.
 35. Mohr JP, Parides MK, Stapf C, Moquete E, Moy CS, Overbey JR, et al. Medical management with or without interventional therapy for unruptured brain arteriovenous malformations (ARUBA): a multicentre, non-blinded, randomised trial. *Lancet.* 2014 Feb 15;383(9917):614-21.
 36. Moosa S, Chen CJ, Ding D, Lee CC, Chivukula S, Starke RM, et al. Volume-staged versus dose-staged radiosurgery outcomes for large intracranial arteriovenous malformations. *Neurosurg Focus.* 2014 Sep;37(3):E18.
 37. Mouchtouris N, Jabbour PM, Starke RM, Hasan DM, Zanaty M, Theofanis T, et al. Biology of cerebral arteriovenous malformations with a focus on inflammation. *J Cereb Blood Flow Metab.* 2015 Feb;35(2):167-75.
 38. n BCATI. N-butyl cyanoacrylate embolization of cerebral arteriovenous malformations: results of a prospective, randomized, multi-center trial. *AJNR Am J Neuroradiol.* 2002 May;23(5):748-55.
 39. Oermann EK, Ding D, Yen CP, Starke RM, Bederson JB, Kondziolka D, et al. Effect of Prior Embolization on Cerebral Arteriovenous Malformation Radiosurgery Outcomes: A Case-Control Study. *Neurosurgery.* 2015 Sep;77(3):406-17.
 40. Oermann EK, Rubinsteyn A, Ding D, Mascitelli J, Starke RM, Bederson JB, et al. Using a Machine Learning Approach to Predict Outcomes after Radiosurgery for Cerebral Arteriovenous Malformations. *Sci Rep.* 2016 Feb;6:21161.
 41. Przybylowski CJ, Ding D, Starke RM, Yen CP, Quigg M, Dodson B, et al. Seizure and anticonvulsant outcomes following stereotactic radiosurgery for intracranial arteriovenous malformations. *J Neurosurg.* 2015 Jun;122(6):1299-305.
 42. Purdy PD, Batjer HH, Risser RC, Samson D. Arteriovenous malformations of the brain: choosing embolic materials to enhance safety and ease of excision. *J Neurosurg.* 1992 Aug;77(2):217-22.
 43. Saatci I, Geyik S, Yavuz K, Cekirge HS. Endovascular treatment of brain arteriovenous malformations with prolonged intranidal Onyx injection technique: long-term results in 350 consecutive patients with completed endovascular treatment course. *J Neurosurg.* 2011 Jul;115(1):78-88.
 44. Sampei K, Hashimoto N, Kazekawa K, Tsukahara T, Iwata H, Takaichi S. Histological changes in brain tissue and vasculature after intracarotid infusion of organic solvents in rats. *Neuroradiology.* 1996 Apr;38(3):291-4.
 45. Schmutz F, McAuliffe W, Anderson DM, Elliott JP, Eskridge JM, Winn HR. Embolization of cerebral arteriovenous malformations with silk: histopathologic changes and hemorrhagic complications. *AJNR Am J Neuroradiol.* 1997 Aug;18(7):1233-7.
 46. Schneider BF, Eberhard DA, Steiner LE. Histopathology of arteriovenous malformations after gamma knife radiosurgery. *J Neurosurg.* 1997 Sep;87(3):352-7.
 47. Song JK, Eskridge JM, Chung EC, Blake LC, Elliott JP, Finch L, et al. Preoperative embolization of cerebral arteriovenous malformations with silk sutures: analysis and clinical correlation of complications revealed on computerized tomography scanning. *J Neurosurg.* 2000 Jun;92(6):955-60.
 48. Spetzler RF, Martin NA. A proposed grading system for arteriovenous malformations. *J Neurosurg.* 1986 Oct;65(4):476-83.
 49. Starke RM, Kano H, Ding D, Lee JY, Mathieu D, Whitesell J, et al. Stereotactic radiosurgery for cerebral arteriovenous malformations: evaluation of long-term outcomes in a

- multicenter cohort. *J Neurosurg.* 2016 Mar 4:1-9. [Epub ahead of print]
50. Starke RM, Sheehan JP, Ding D, Liu KC, Kondziolka D, Crowley RW, et al. Conservative management or intervention for unruptured brain arteriovenous malformations. *World Neurosurg.* 2014 Nov;82(5):e668-9.
 51. Starke RM, Yen CP, Chen CJ, Ding D, Mohila CA, Jensen ME, et al. An updated assessment of the risk of radiation-induced neoplasia after radiosurgery of arteriovenous malformations. *World Neurosurg.* 2014 Sep-Oct;82(3-4):395-401.
 52. Starke RM, Yen CP, Ding D, Sheehan JP. A practical grading scale for predicting outcome after radiosurgery for arteriovenous malformations: analysis of 1012 treated patients. *J Neurosurg.* 2013 Oct;119(4):981-7.
 53. Taki W, Yonekawa Y, Iwata H, Uno A, Yamashita K, Amemiya H. A new liquid material for embolization of arteriovenous malformations. *AJNR Am J Neuroradiol.* 1990 Jan-Feb;11(1):163-8.
 54. van Beijnum J, van der Worp HB, Buis DR, Al-Shahi Salman R, Kappelle LJ, Rinkel GJ, et al. Treatment of brain arteriovenous malformations: a systematic review and meta-analysis. *JAMA.* 2011 Nov 9;306(18):2011-9.
 55. Weber W, Kis B, Siekmann R, Jans P, Laumer R, Kuhne D. Preoperative embolization of intracranial arteriovenous malformations with Onyx. *Neurosurgery.* 2007 Aug;61(2):244-52; discussion 52-4.
 56. Wikholm G. Occlusion of cerebral arteriovenous malformations with N-butyl cyano-acrylate is permanent. *AJNR Am J Neuroradiol.* 1995 Mar;16(3):479-82.
 57. Yen CP, Ding D, Cheng CH, Starke RM, Shaffrey M, Sheehan J. Gamma Knife surgery for incidental cerebral arteriovenous malformations. *J Neurosurg.* 2014 Nov;121(5):1015-21.