



# Unexpected airway foreign body during general anesthesia

Naotaka Kishimoto, Yutaka Tanaka, Shigenobu Kurata, Kenji Seo

Division of Dental Anesthesiology, Faculty of Dentistry & Graduate School of Medical and Dental Sciences, Niigata University, Niigata, Japan

**Keywords:** Airway; Aspiration; Foreign Bodies; Hypoxemia; General anesthesia; Obstruction.



This is an Open Access article distributed under the terms of the Creative Commons Attribution Non-Commercial License (<http://creativecommons.org/licenses/by-nc/4.0/>) which permits unrestricted non-commercial use, distribution, and reproduction in any medium, provided the original work is properly cited.



Dear Editor:

Airway foreign body aspiration (FBA) may not present with typical clinical symptoms in children younger than 3 years, making it difficult to detect if not witnessed [1,2]. If general anesthesia is induced without knowledge of FBA, the patient's condition may deteriorate owing to airway obstruction. Here we report the case of a 15-month-old boy in whom bronchofiberscopic imaging revealed a foreign body (FB) in the right main bronchial bifurcation. Written informed consent was obtained from the patient's parent. The patient was orotracheally intubated after the induction of general anesthesia for a palatoplasty. Approximately 30 min later, decreased arterial oxygen saturation (94%) and decreased breath sounds in the right lung were observed. Suspecting partial obstruction of the tube by sputum or an asthma attack, the anesthesiologist performed endotracheal suctioning and administered inhaled procaterol; however, the breath sounds in the right lung remained attenuated. An FB was detected when the anesthesiologist examined the inside of the trachea using a bronchofiberscope (Fig. 1A). The presence of an intubation tube with a 4.0-mm internal

diameter made it difficult to remove the foreign body. Therefore, after switching to a laryngeal mask airway, an otolaryngologist removed the FB using a bronchofiberscope and forceps. The excised specimen was identified as an FB consisting of facial tissues (Fig. 1B). The patient's family had observed tissues in his mouth several times; thus, the foreign object was assumed to have been in his airway preoperatively. A previous study reported that hypoxemia was observed immediately postoperative in a pediatric patient with repeated respiratory infections before surgery; the determined cause was FBA [2]. When children have repeat respiratory infections, FBA should be suspected [3]. In the present case, only slight nasal discharge was observed preoperatively, with no other respiratory symptoms. Therefore, making the preoperative diagnosis of FBA is extremely difficult. When anesthesiologists encounter unexpected respiratory problems in children, it is important that they consider the possibility of FBA and perform a detailed examination using a bronchofiberscope if identifying the cause is difficult.

Received: January 31, 2024 • Revised: February 2, 2024 • Accepted: February 4, 2024

Corresponding Author: Naotaka Kishimoto, Division of Dental Anesthesiology, Faculty of Dentistry & Graduate School of Medical and Dental Sciences, Niigata University, 2-5274, Gakkocho-dori, Chuo-ku, Niigata 951-8514, Japan

Tel: +81-25-227-2972 Fax: +81-25-227-0812 E-mail: [kishimoto@dent.niigata-u.ac.jp](mailto:kishimoto@dent.niigata-u.ac.jp)

Copyright© 2024 Journal of Dental Anesthesia and Pain Medicine

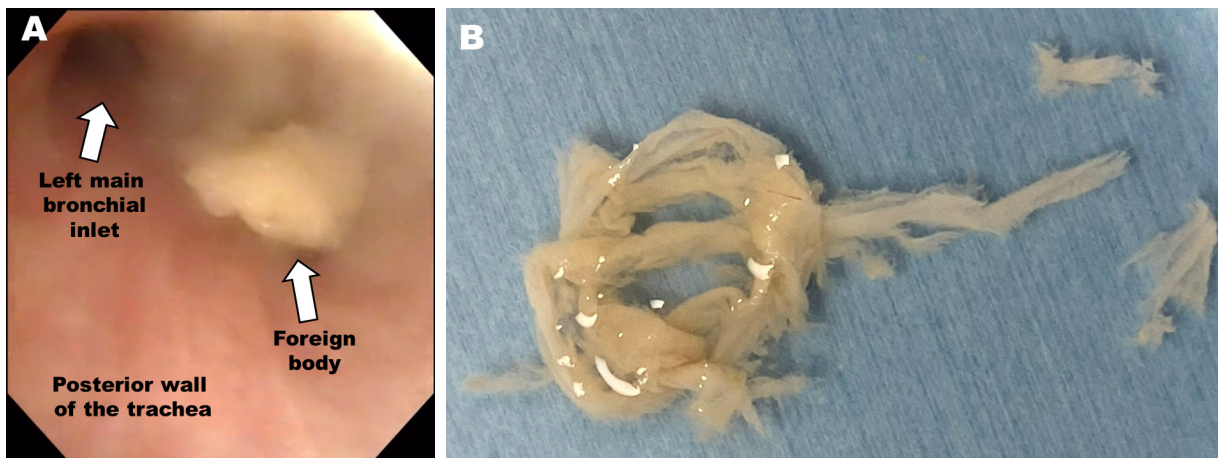


Fig. 1. Airway foreign body found during general anesthesia. (A) The foreign body was located near the right main bronchial bifurcation. (B) The extracted foreign body.

**AUTHOR ORCID*s***

**Naotaka Kishimoto:** <https://orcid.org/0000-0002-8716-5056>  
**Yutaka Tanaka:** <https://orcid.org/0009-0007-9537-2884>  
**Shigenobu Kurata:** <https://orcid.org/0009-0006-1689-475X>  
**Kenji Seo:** <https://orcid.org/0000-0001-9126-9344>

**AUTHOR CONTRIBUTIONS**

**Naotaka Kishimoto:** Writing - original draft  
**Yutaka Tanaka:** Writing - review & editing  
**Shigenobu Kurata:** Writing - review & editing  
**Kenji Seo:** Supervision

**ACKNOWLEDGMENTS:** We thank Jane Charbonneau, DVM from Edanz (<https://jp.edanz.com/ac>), and Editage ([www.editage.co.kr](http://www.editage.co.kr)) for editing the manuscript draft.

**DECLARATIONS OF INTEREST:** None

**FUNDING:** None

**REFERENCES**

1. Keil O, Schwerk N. Foreign body aspiration in children - being safe and flexible. *Curr Opin Anaesthesiol* 2023; 36: 334-9.
2. Senturk O, Unal D, Selvi O. Hypoxia during general anesthesia? Unknown foreign body aspiration. *J Clin Anesth* 2016; 33: 176-8.
3. Wu Y, Dai J, Wang G, Li Y, Li H, Wu C, et al. Delayed diagnosis and surgical treatment of bronchial foreign body in children. *J Pediatr Surg* 2020; 55: 1860-5.