

The effectiveness of L2 nerve root block for the management of patients who are suffering from chronic low back and referred pain

Hyung-Woo Lim, Yong-Hyun Cho, Sun-Hee Kim, Dong-Hyun Lee, and Seung-Hyun Kang

Department of Anesthesiology and Pain Medicine, Seoul Sungsim General Hospital, Seoul, Korea

It is not easy to identify the exact pain-producing structures in degenerative spinal diseases. Intervertebral disc, facet joint and sacroiliac joint have been widely known as major causes of chronic low back pain (LBP) and referred pain. The afferent sympathetic fibers that pass through the L2 spinal nerve root are the cardinal pathway of sensation from the above three structures. Here, we discuss the effectiveness of L2 nerve root block for patients who are suffering from LBP and referred pain with compound causes.

Nakamura et al. [1] stated that discogenic back pain is a visceral pain that is projected to the somatic dermatome of the corresponding spinal nerve which has synapse with the sympathetic afferent fibers from the visceral organs. According to a study by Murata et al. [2] and an animal study by Suseki et al. [3], facet joints and sacroiliac joints have double sensory transmissions with somatic nerves and sympathetic nerves, and afferent sympathetic nerves pass through the L2 nerve root. It is not easy to judge from imaging tests whether the cause of chronic LBP is due to intervertebral disc degeneration, facet arthritis, or sacroiliac arthritis [4]. In addition, the causes of the pain are not independent but rather coexist in many different segments. If one nerve root block could control chronic LBP from multiple lesions, it would be an ideal primary treatment for chronic LBP patients for which surgery is not indicated.

This study received permission from the ethics committee and written consent from all the patients. Outpatients with chronic LBP for at least 4 weeks or patients who had repeated

LBP in the past were chosen for the study. An orthopedic surgeon chose the patients. Fifty patients each for the experiment and control groups were randomly chosen. Before the procedure, LBP was assessed using a 100-point visual analog scale (VAS). An anesthesiologist blindly decided whether to perform a L2 root block or a sham block. The nerve root block was done blindly by one anesthesiologist while the post-procedure assessments were done blindly by another anesthesiologist.

In the experiment group, the L2 nerve root was blocked with 0.25% bupivacaine 2 ml on the side of dominant pain. In the control group, only the skin was locally anesthetized with 2% lidocaine to exclude the dry needling effect. The patient lay in the prone position and the predominantly painful side where the block was to be performed was raised by a 30° angle. A 22-gauge spinal needle was advanced below the L2 vertebral pedicle under fluoroscopic guidance (Fig. 1). If the area innervated by the L2 nerve root was stimulated, the needle was withdrawn by 2 mm and 0.25% bupivacaine 2 ml was injected. Pain was assessed using a 100-point VAS score by direct verbal question before and 5 minutes after the procedure and over the phone at the 1st, 3rd, 5th, 7th, and 30th day after the procedure. Other conventional treatments except for pharmacotherapy, were not allowed and patients who required additional treatments were excluded from the study.

Student t-test and chi-square test were used for statistical analysis to analyze the homogeneity between the experiment and control group. Repeated measure ANOVA was used to

Corresponding author: Yong-Hyun Cho, M.D., Department of Anesthesiology and Pain Medicine, Seoul Sungsim General Hospital, Chungryangri-dong, Dongdaemun-gu, Seoul 130-867, Korea. Tel: 82-2-966-1616, Fax: 82-2-964-0743, E-mail: anesthecho@naver.com

© This is an open-access article distributed under the terms of the Creative Commons Attribution Non-Commercial License (<http://creativecommons.org/licenses/by-nc/3.0/>), which permits unrestricted non-commercial use, distribution, and reproduction in any medium, provided the original work is properly cited.

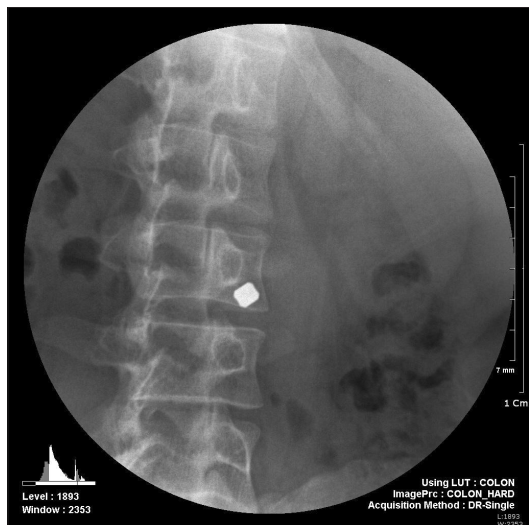


Fig. 1. A 22-gauge spinal needle was advanced below the L2 vertebral pedicle under the fluoroscopic guide.

analyze the changes in the repeated assessments of the two groups before and after the procedure and to analyze the differences between them.

The final number of patients was 48 in the experiment group (96%) and 38 in the control group (76%). Most excluded patients were unsatisfied with the level of pain decrease so they required other kinds of management. When comparing before and up to 7 days after the procedure, both groups had significant pain reduction (P : experiment group = 0.000, control group = 0.000). On the 30th day, there was no significance in pain reduction in the control group (P : experiment group = 0.000, control group = 0.393). Pain scores in both groups that were assessed before and repeatedly after the procedure showed a significant decrease (P = 0.000), but there was a greater decrease in the experiment

group (P = 0.000). Even the control group, initially experienced a significant decrease in pain after the procedure. However, this is considered to be a placebo effect. In fact, the placebo effect has a great effect in drug treatment and invasive treatment [5]. To exclude pain reduction from the placebo effect, the data were taken 6 times in 30 days after the procedure and compared. The duration of pain reduction was much longer than the 8-hour effect of bupivacaine in the experiment group. We assumed the reasons were that the sympathetic nerves are more sensitive to local anesthetics and they have a sympathetic reset effect resulting in desensitization of hyper-activated perception. It is also attributable to the placebo effect and natural improvement according to the passage of time.

In the present study, local anesthetics were used without steroids. The purpose of this procedure is to block and desensitize the pathway. Thus, it has nothing to do with the control of inflammation.

This study has some limitations. The sample size was not large enough. Moreover, 12 patients were excluded from the control group, which is a much larger number than the 2 patients who were excluded from the experiment group. Another limitation was that assessments were made on the phone; thus, it was difficult to perform a more precise and complicated assessment.

The L2 nerve root block is an effective procedure for pain reduction not only in patients with discogenic LBP but also in patients with chronic LBP due to various complex etiologies such as facet joint pathology or sacroiliac joint pathology, regardless of the involved segments. Side effects from using steroids do not need to be considered since this procedure relies on the blockage of the pain pathway and steroid usage is unnecessary. Therefore, it is deemed as one of the best and safest first-line treatments for patients that do not respond to simple pharmacologic management.

References

1. Nakamura SI, Takahashi K, Takahashi Y, Yamagata M, Moriya H. The afferent pathways of discogenic low-back pain. Evaluation of L2 spinal nerve infiltration. *J Bone Joint Surg Br* 1996; 78: 606-12.
2. Murata Y, Kato Y, Miyamoto K, Takahashi K. Clinical study of low back pain and radicular pain pathways by using l2 spinal nerve root infiltration: a randomized, controlled, clinical trial. *Spine (Phila Pa 1976)* 2009; 34: 2008-13.
3. Suseki K, Takahashi Y, Takahashi K, Chiba T, Tanaka K, Morinaga T, et al. Innervation of the lumbar facet joints. Origins and functions. *Spine (Phila Pa 1976)* 1997; 22: 477-85.
4. DePalma MJ, Ketchum JM, Saullo T. What is the source of chronic low back pain and does age play a role? *Pain Med* 2011; 12: 224-33.
5. Nikfar S, Abdollahi M, Salari P. The efficacy and tolerability of exenatide in comparison to placebo; a systematic review and meta-analysis of randomized clinical trials. *J Pharm Pharm Sci* 2012; 15: 1-30.